

# Adrenal Vein Sampling in the Young – Necessary or Not?

## Authors

Eleftheria Gkaniatsa<sup>1,2</sup>, Oskar Ragnarsson<sup>1,2,3</sup>

## Affiliations

- 1 Department of Endocrinology, Sahlgrenska University Hospital, Sweden
- 2 Department of Internal Medicine & Clinical Nutrition, Institute of Medicine, Sahlgrenska Academy, University of Gothenburg, Sweden
- 3 Wallenberg Center for Molecular and Translational Medicine, University of Gothenburg, Sweden

## Key words

primary aldosteronism, adrenal vein sampling, mineralocorticoid receptor antagonist, adrenalectomy, clinical guidelines

received 23.12.2022

revised 19.05.2023

accepted 23.05.2023

published online 17.07.2023

## Bibliography

Exp Clin Endocrinol Diabetes 2023; 131: 435–437

DOI 10.1055/a-2099-3525

ISSN 0947-7349

© 2023. Thieme. All rights reserved.

Georg Thieme Verlag, Rüdigerstraße 14,  
70469 Stuttgart, Germany

## Correspondence

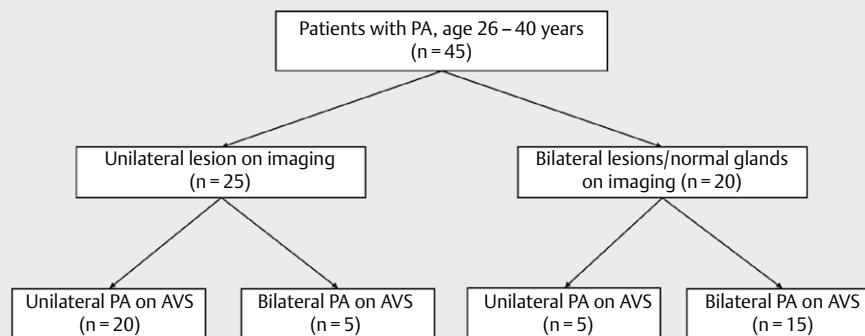
Oskar Ragnarsson  
Department of Endocrinology  
Blå stråket 5  
Sahlgrenska University Hospital  
SE 413 45  
Gothenburg  
Sweden  
Tel.: +46 31-342 1000  
oskar.ragnarsson@medic.gu.se

## ABSTRACT

Current clinical guidelines from the US Endocrine Society state that adrenal venous sampling (AVS) may not be necessary in patients younger than 35 years with marked aldosteronism and a solitary adrenal adenoma on imaging. At the time when the guidelines were published, only one study supported the statement, a study that included 6 patients younger than 35 years, all of whom had unilateral adenoma on imaging and unilateral primary aldosteronism (PA), according to AVS. Since then, to our knowledge, four additional studies have been published that provide data on concordance between conventional imaging and AVS among patients younger than 35 years. In these studies, 7 of 66 patients with unilateral disease on imaging had bilateral disease, according to AVS. We find it, therefore, reasonable to conclude that imaging studies alone inaccurately predict laterality in a significant number of young patients with PA and that available data challenge the current clinical guidelines.

Adrenal venous sampling (AVS) is recommended for patients with primary aldosteronism (PA) who are considered to be candidates for surgery to distinguish between unilateral and bilateral aldosterone overproduction and thereby to identify those who are suitable for unilateral adrenalectomy [1]. In fact, by using conventional imaging alone, the specificity for diagnosing unilateral PA in a patient with unilateral adenoma is only 57% [2]. Current clinical guidelines from the US Endocrine Society, however, state that AVS may not be necessary in patients younger than 35 years who have marked aldosteronism (i.e., p-aldosterone > 831 pmol/L and spontaneous hypokalemia) and a solitary unilateral adrenal adenoma on imaging [1]. As a support for the statement, references for five studies are provided [3–7]. Three of these studies do not specifically provide any data from young patients with PA [3–5], and one study provides only data on patients younger than 40 years, where one of 6 patients with unilateral ade-

noma on imaging had bilateral PA according to AVS [6]. Thus, at the time when the guidelines were published, only one study supported that young patients can skip AVS; in that study, imaging was accurate in demonstrating unilateral PA in all six patients younger than 35 years [7], and the quality of the evidence was considered to be very low [1]. However, only adrenalectomized patients were included in the study, with some patients possibly having unilateral adenoma on imaging, but with bilateral PA on AVS, and therefore not treated surgically, may not have been included. In addition, of interest was that imaging inaccurately supported unilateral PA in 6 of 15 patients aged between 35 and 40 years [7]. In this context, it should be mentioned that in 2014, an international expert consensus statement questioned whether patients with PA younger than 40 years actually need AVS in the presence of unilateral adenoma on imaging [8]. However, in a recent meta-analysis, the sensitivity for diagnosing unilateral PA on CT



► **Fig. 1** Flowchart showing the results from adrenal imaging and adrenal vein sampling (AVS) in 45 patients aged between 26–40 years that were diagnosed at the Sahlgrenska University Hospital between 2005 and 2019.

in patients 40 years or younger was 71 %, and the specificity was only 79 %, meaning that 21 % of the patients might have undergone unnecessary adrenalectomy if AVS would not have been used [2].

Since the current clinical guidelines from the US Endocrine Society were launched in 2016, four additional studies have been published that provide data on concordance between conventional imaging and AVS among patients younger than 35 years [9–12]. In addition, one further study has reported surgical outcomes following adrenalectomy in patients < 35 years where the diagnosis of unilateral PA was based on AVS or only imaging [13].

In a study from Japan by Umakoshi et al. [9], three of 30 patients younger than 35 years at diagnosis, all with hypokalemia, plasma aldosterone > 440 pmol/L, and unilateral adenoma on CT, had bilateral PA according to AVS. In addition, 8 of 39 patients aged between 35 and 40 years had unilateral adenoma and bilateral PA on AVS. In another large multicenter study [13] comprising 60 adrenalectomized patients aged < 35 years, adrenalectomy was, according to the Primary Aldosteronism Surgical Outcomes (PASO) criteria [14], biochemically successful in 8 patients, partial in 1 and absent in 2, of 11 patients with a unilateral adrenal mass on imaging where AVS had not been performed preoperatively. However, 5 of these 11 patients had severe phenotype, all with complete biochemical success postoperatively. Also, all 26 patients who had undergone AVS preoperatively had complete biochemical success following adrenalectomy, both patients with (n = 17) and without (n = 9) severe phenotype [13].

We have recently analyzed data from 45 patients 40 years or younger that underwent AVS at our institution between 2005 and 2019 [10]. Of 25 patients with unilateral adenoma on imaging, 5 had bilateral PA according to AVS (► **Fig. 1**). Similarly, 5 of 20 patients with either bilateral lesions or normal adrenal glands had unilateral PA according to AVS (► **Fig. 1**). Interestingly, two of five patients with unilateral adenoma and bilateral PA on AVS were treated surgically with unilateral adrenalectomy [10]. Postoperatively, one had partial, and in the other, absent biochemical success according to PASO [14]. This contrasts with the study by Umakoshi et al., where five patients with unilateral adenoma on imaging and bilateral PA on AVS were treated surgically. Four of these had complete biochemical success, and one had partial success [9].

In our study, 16 of 45 patients were 35 years or younger at diagnosis [10]. Of these sixteen patients, two had discordant results between imaging and AVS, one had unilateral adenoma on imaging (19 mm) and bilateral PA, according to AVS, and one had apparently normal adrenal glands on imaging and unilateral PA according to AVS.

We are aware of two more recently published studies that addressed the same topic [11, 12]. In these studies, two of 13 and one of seven patients younger than 35 years, respectively, had a well-defined adenoma on CT and bilateral PA according to AVS.

Thus, to our knowledge, only six studies have been published to date that have investigated whether conventional imaging alone can distinguish unilateral from bilateral PA among patients younger than 35 years (► **Table 1**) [7, 9–13]. Taken together, 7 of 66 patients with unilateral disease on imaging had bilateral disease, according to AVS. In addition, in the study by Williams et al. [14], 2 of 11 patients ≤ 35 years with a unilateral adrenal mass on imaging, who did not undergo AVS preoperatively, had absent biochemical success following adrenalectomy.

Although based on data from a limited number of patients, we find it reasonable and fair to conclude that imaging studies alone inaccurately predict laterality in a significant proportion of young patients with PA, or 10 % to be more exact. The available data, therefore, challenge the current clinical guidelines suggesting that AVS may not be necessary in young adults with PA [1].

There are more reasons why we question the current guidelines. First, complications in connection with AVS are rare and most often mild [15–17]. For instance, in a large international study with information from 2604 AVS conducted at 20 centers, the overall rate of adrenal vein rupture, a dreaded and serious complication, was only 0.6 % [17]. We, therefore, consider it less harmful to perform an AVS in young patients with PA rather than to perform potentially unnecessary unilateral adrenalectomy. The major limitation of AVS, however, is that it is a technically demanding procedure with a low success rate in non-specialized centers, and is not widely available. Second, PA is still an uncommon disease in young patients, the proportion being 3–8 % [7, 9–11]. Thus, with current guidelines, only a small number of patients would be spared from AVS. Third, exceptions to the main recommendation, i. e., that young patients with visible adrenal adenoma do not need AVS pose a risk

► **Table 1** Summary of currently available studies that have examined the concordance between conventional adrenal imaging and adrenal venous sampling (AVS) and or surgical outcome, in patients aged 35 years or younger with primary aldosteronism.

Author, year, country	Main findings
<b>Lim, 2014, USA</b>	Five patients ≤ 35 years; imaging and AVS concordant in all. Only adrenalectomized patients included.
<b>Umakoshi, 2018, Japan</b>	Three of 30 patients ≤ 35 years with unilateral disease on imaging had bilateral disease on AVS.
<b>Williams, 2018, International</b>	Two of 11 patients ≤ 35 years with a unilateral adrenal mass on imaging, did not undergo AVS preoperatively, had absent biochemical success following adrenalectomy. All five patients with severe phenotype and an adrenal mass on imaging had complete biochemical success.
<b>Gkaniatsa, 2021, Sweden</b>	One of 11 patients ≤ 35 years with unilateral disease on imaging had bilateral disease on AVS.
<b>Lee, 2021, Korea</b>	Two of 13 patients ≤ 35 years with unilateral disease on imaging and severe phenotype had bilateral disease on AVS.
<b>Kaur, 2022, New Zealand</b>	One of 7 patients ≤ 35 years with unilateral disease on imaging had bilateral disease on AVS.

that the guidelines can be interpreted “liberally” and used to justify bypassing AVS in, e. g., slightly older patients, patients with “suspected” small nodules and/or patient who do not quite meet the criteria for marked aldosteronism (e. g., p-aldosterone > 831 pmol/L and spontaneous hypokalemia).

So, in our opinion, AVS should be performed in young adults with PA at centers that have access to an experienced interventionist, just as in patients who are 35 or 40 years or older. However, given the limited access to AVS in general, new methods for identifying patients with unilateral disease are urgently needed. One promising alternative is <sup>11</sup>C-methomidate PET-CT [18], although its diagnostic value in young patients with PA has not yet been investigated.

## Conflict of Interest

The authors declare that they have no conflict of interest.

## References

- Funder JW, Carey RM, Mantero F et al. The Management of Primary Aldosteronism: Case Detection, Diagnosis, and Treatment: An Endocrine Society Clinical Practice Guideline. *J Clin Endocrinol Metab* 2016; 101: 1889–1916. DOI: 10.1210/jc.2015-4061
- Zhou Y, Wang D, Jiang L et al. Diagnostic accuracy of adrenal imaging for subtype diagnosis in primary aldosteronism: Systematic review and meta-analysis. *BMJ Open* 2020; 10: e038489. DOI: 10.1136/bmjopen-2020-038489
- Young WF, Stanson AW, Thompson GB et al. Role for adrenal venous sampling in primary aldosteronism. *Surgery* 2004; 136: 1227–1235. DOI: 10.1016/j.surg.2004.06.051
- Tan YY, Ogilvie JB, Triponez F et al. Selective use of adrenal venous sampling in the lateralization of aldosterone-producing adenomas. *World J Surg* 2006; 30: 879–885. discussion 886-877. DOI: 10.1007/s00268-005-0622-8
- Minami I, Yoshimoto T, Hirono Y et al. Diagnostic accuracy of adrenal venous sampling in comparison with other parameters in primary aldosteronism. *Endocr J* 2008; 55: 839–846. DOI: 10.1507/endocrj.k07e-164
- Riester A, Fischer E, Degenhart C et al. Age below 40 or a recently proposed clinical prediction score cannot bypass adrenal venous sampling in primary aldosteronism. *J Clin Endocrinol Metab* 2014; 99: E1035–E1039. DOI: 10.1210/jc.2013-3789
- Lim V, Guo Q, Grant CS et al. Accuracy of adrenal imaging and adrenal venous sampling in predicting surgical cure of primary aldosteronism. *J Clin Endocrinol Metab* 2014; 99: 2712–2719. DOI: 10.1210/jc.2013-4146
- Rossi GP, Auchus RJ, Brown M et al. An expert consensus statement on use of adrenal vein sampling for the subtyping of primary aldosteronism. *Hypertension* 2014; 63: 151–160. DOI: 10.1161/Hypertensionaha.113.02097
- Umakoshi H, Ogasawara T, Takeda Y et al. Accuracy of adrenal computed tomography in predicting the unilateral subtype in young patients with hypokalaemia and elevation of aldosterone in primary aldosteronism. *Clin Endocrinol (Oxf)* 2018; 88: 645–651. DOI: 10.1111/cen.13582
- Gkaniatsa E, Sakinis A, Palmer M et al. Adrenal venous sampling in young patients with primary aldosteronism. Extravagance or irreplaceable? *J Clin Endocrinol Metab* 2021; 106: e2087–e2095. DOI: 10.1210/clinem/dgab047
- Kaur R, Young S. Discordant imaging: Adrenal vein sampling in almost half of patients with primary aldosteronism and a unilateral adrenal adenoma. *Intern Med J* 2022. DOI: 10.1111/imj.15752
- Lee SH, Kim JW, Yoon HK et al. Diagnostic accuracy of computed tomography in predicting primary aldosteronism subtype according to age. *Endocrinol Metab (Seoul)* 2021; 36: 401–412. DOI: 10.3803/EnM.2020.901
- Williams TA, Burrello J, Sechi LA et al. Computed tomography and adrenal venous sampling in the diagnosis of unilateral primary aldosteronism. *hypertension* 2018; 72: 641–649. DOI: 10.1161/hypertensionaha.118.11382
- Williams TA, Lenders JWM, Mulatero P et al. Outcomes after adrenalectomy for unilateral primary aldosteronism: An international consensus on outcome measures and analysis of remission rates in an international cohort. *Lancet Diabetes Endocrinol* 2017; 5: 689–699. DOI: 10.1016/S2213-8587(17)30135-3
- Jakobsson H, Farmaki K, Sakinis A et al. Adrenal venous sampling: The learning curve of a single interventionalist with 282 consecutive procedures. *Diagn Interv Radiol* 2018; 24: 89–93. DOI: 10.5152/dir.2018.17397
- Araujo-Castro M, Paja Fano M, Gonzalez Boillos M et al. Adrenal venous sampling in primary aldosteronism: Experience of a Spanish multicentric study (Results from the SPAIN-ALDO Register). *Endocrine* 2022; 78: 363–372. DOI: 10.1007/s12020-022-03122-8
- Rossi GP, Barisa M, Allolio B et al. The Adrenal Vein Sampling International Study (AVIS) for identifying the major subtypes of primary aldosteronism. *J Clin Endocrinol Metab* 2012; 97: 1606–1614. DOI: 10.1210/jc.2011-2830
- Wu X, Senanayake R, Goodchild E et al. [(11)C]metomidate PET-CT versus adrenal vein sampling for diagnosing surgically curable primary aldosteronism: A prospective, within-patient trial. *Nat Med* 2023; 29: 190–202. DOI: 10.1038/s41591-022-02114-5