Accepted Manuscript online: 2023-07-19 Article published online: 2023-11-07

Original Article

Preliminary Experience with Continuous Submucosal Anastomosis in Small-Diameter Hepaticojejunostomy during Single-Port Laparoscopic Choledochal Cyst Surgery in Children

Yingming Tang[1] Jie Zhang[1] Miao Luo[1] Fei Li[1] Huang Huang[1] Zhou Zhou[1] Xia Fan[1] Zhijie Qin[1] Guoqing He[1] Yize Zhuang[1]

[1] Department of Pediatric Surgery, Guizhou Provincial People's Hospital, Guizhou, China

Eur J Pediatr Surg

Address for correspondence Yize Zhuang, MMed, Department of Pediatric Surgery, Guizhou Provincial People's Hospital No. 83, Zhongshan East Road, Nanming District, Guiyang City, Guizhou 550002, China (e-mail: rrigxx@163.com).

Abstract

Purpose Hepaticojejunostomy anastomosis (HJA) is the most challenging aspect in single-port laparoscopic choledochal cystectomy and Roux-en-Y hepaticojejunostomy (SPCH) in children, especially in small-diameter anastomoses (diameters less than 5 mm), which are more susceptible to anastomotic stricture. We developed the continuous submucosal technique for HJA (CS-HJA) to lessen postoperative complications. The purpose of this study is to introduce our preliminary experiences with CS-HJA.

Methods We retrospectively analyzed all available clinical data of children who underwent SPCH surgery between March 2020 and October 2022. We operated with CS-HJA on 10 children who were diagnosed with small-diameter hepaticojejunostomy (diameter less than 5 mm). Data collection mainly included demographic information, imaging data, perioperative details, and postoperative outcomes. Ten patients were included in this study. The average patient age was 55.2 months; the age range was 3 to 120 months, and the average weight was 11.6 kg; male–female ratio was 1:9. The choledocho had fusiform dilatation in five cases and cystic dilatation in five cases. There was no dilatation of the left and right hepatic ducts or intrahepatic bile ducts in all patients. All patients had no dilatation of the left and right hepatic ducts or intrahepatic bile ducts. All patients underwent a single-port laparoscopic bile-intestinal anastomosis using a submucosal jejunal anastomosis technique. Analysis of the duration of the bile-intestinal anastomosis, the length of the child's stay in the hospital after surgery, the intraoperative complications, and the postoperative complications was performed.

Results All the 10 patients underwent successful SPCH by CS-HJA technique. The average length of time for hepaticojejunostomy ranged from 22 to 40 minutes, and the postoperative hospital stay was 5.2 to 9.2 days. There were no instances of bile leakage following the operation. At 17 to 30 months of follow-up, there was no abdominal pain or jaundice, and the reexamination of transaminases, bilirubin, and amylase were

Keywords
- continuous submucosal anastomosis
- single-port laparoscopic surgery
- choledochal cyst
- hepaticojejunostomy

received
April 11, 2023
accepted after revision
June 14, 2023
accepted manuscript online
July 19, 2023

DOI https://doi.org/10.1055/a-2133-5202.
ISSN 0939-7248.

normal. Ultrasonography showed no bile duct stricture or dilated bile ducts, and the incision is elegant, and the families of the patients were satisfied.

Conclusion In SPCH surgery in children, the CS-HJA technique is safe and feasible for small-diameter hepaticojejunostomy.

Introduction

Choledochal cysts (CDC) are the most common congenital malformation found in the biliary tract and are characterized by cystic or fusiform dilatation of the common bile duct. In particular, Asian populations have a high incidence of CDCs.[1,2] Patients with CDCs may experience cyst perforation, recurrent pancreatitis, cancer, or even severe cholestasis without receiving effective treatment, which can then result in liver cirrhosis, portal hypertension, and ultimately liver failure.[3] Surgery is the primary treatment option for CDCs and typically involves choledochal cystectomy, cholecystectomy, and hepaticojejunostomy.[4] Robotic surgery and laparoscopic surgery are two minimally invasive procedures commonly used to treat CDCs. Currently, laparoscopic surgery is the most mainstream surgical approach in China and worldwide.[5] Single-port laparoscopic CDC excision and Roux-en-Y hepaticoenterostomy (SPCH) have the advantages of being less traumatic and more cosmetic beneficial. Therefore, it is becoming more widely adopted.[6] One of the most challenging aspects of this procedure is the hepaticojejunostomy, particularly when the anastomosis's diameter is less than 5 mm. In SPCH, it was very complicated for the surgeon to perform the procedure without an assistant and in the absence of an adequately exposed surgical field during the procedure. Anastomoses with a diameter of less than 5 mm between the bile duct and jejunum are particularly challenging for the surgeon to complete. The unsuitable anastomosis was vulnerable to complications like stricture and biliary fistula. In our department, a retrospective analysis of 54 SPCH was performed in our department alone between March 2020 and October 2022. Among these cases,10 children had a choledochal diameter of less than 5 mm, and all used the submucosal jejunal anastomosis technique, and in this study, we present our experiences and discuss the relevant technical points.

Materials and Methods

Study Population

The study was conducted in accordance with the Declaration of Helsinki (revised in 2013) and was approved by the Ethics Committee of Guizhou Provincial People's Hospital with approval No. (2022) 083A01. As this was a retrospective analysis, individual consent was not obtained.

We retrospectively analyzed all available clinical data of children who underwent single-hole laparoscopic CDC resection between March 2020 and October 2022. To be included in the study, patients needed to meet the following criteria: (1) The presence of CDC was confirmed through preoperative history, physical examination, B-ultrasound, computed tomography (CT), or magnetic resonance cholangiopancreatography (MRCP). (2) The procedure was successfully completed under general anesthesia, and the choledocho diameter was determined to be less than 5 mm, both before and during surgery. All patients underwent successful SPCH by continuous submucosal anastomosis hepaticojejunostomy (CS-HJA) technique. (3) The patients did not have any serious organ dysfunction, and their coagulation function was normal.

Exclusion criteria for the study included subsequent operations, cyst perforation, and malignant transformation of the CDC prior to the operation.

Procedure of the Continuous Submucosal Anastomosis in Hepaticojejunostomy

The patient was placed in the human font position with the laparoscopic monitor placed on the upper right side of the patient and the operator standing between the patient's legs. The umbilicus was incised longitudinally, the subcutaneous tissue was separated into the abdominal cavity, and a 5-mm trocar was inserted in the middle of the umbilical fossa and established pneumoperitoneum pressure of 8 to 12 mm Hg (1 mm Hg = 0.133 kPa). The subcutaneous tissues on both sides of the light source trocar were bluntly freed, and a 3-mm trocar was inserted at a distance of 1.0 to 1.5 cm from both sides of the light source trocar (►**Fig. 1**). A 3/0 sliding suture is used to suspend the base of the gallbladder and the anterior wall of the common hepatic duct or the hepatic round ligament to expose the hilar region, respectively. The gallbladder is peeled from the base to the neck with an electrocoagulation hook. If the cyst was large, decompression was performed and the distal end of the CDC was suspended. An electric hook was used close to the cyst wall to dissect the anterior and posterior walls. After that, the distal end would be dissected to the proximal pancreaticobiliary junction and ligated with a 5–0 synthetic clip or dissociation directly. The CDC is completely removed by traction of the CDC from the bottom to the top freeing the posterior wall of the CDC to the choledochal. If there is a right hepatic artery riding across the choledochal, the ectopic anterior right hepatic artery is repositioned posterior to the anastomosis (►**Fig. 2**). The jejunum was extracted through an umbilical incision 10 to 15 cm from the Treitz ligament. Roux-en-Y jejunojejunostomy is constructed extracorporeally by use a 5/0 polydioxanone suture (PDS) suture. The pneumoperitoneum is reconstructed, Roux-en-Y loop jejunum was lifted up to the hepatic hilum through the right mesentery of transverse colon. The intestinal wall opposite to the mesentery of the biliary loop is opened according to the diameter of the common hepatic duct. The posterior wall was sutured

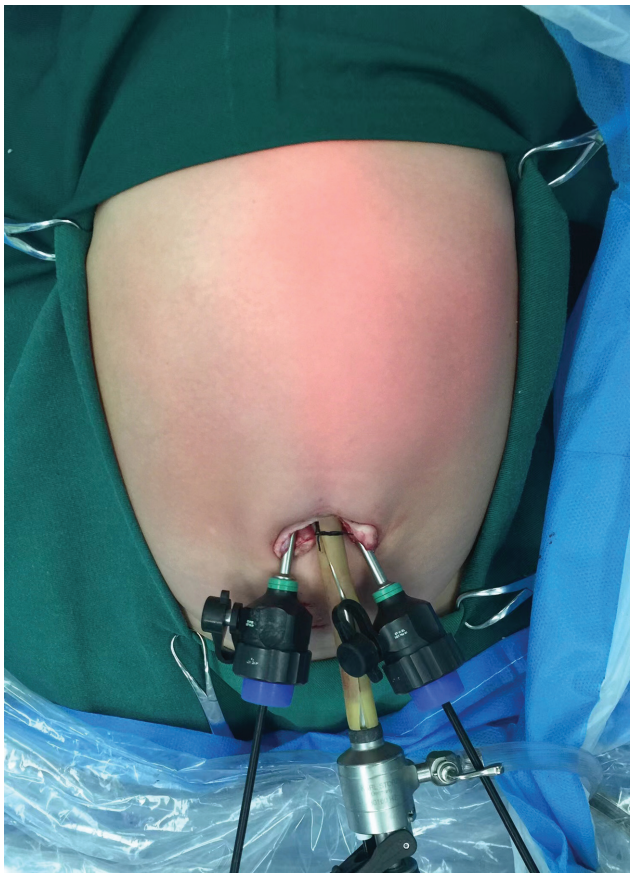

Fig. 1 Transumbilical single-incision with three ports and two transcutaneous suture retractions in single-port laparoscopic surgery.

preferentially with a double-needle 5/0 PDS suture. Through the submucosa at the right margin of the posterior lateral wall of the Roux-en-Y loop jejunum and exiting through serosal layer (►**Fig. 3A**). Then, the needle was injected from the outside to the inside at the 3 o' clock position of the hepatic duct. Repeated continuous submucosal anastomosis the wall of hepatic duct and the jejunum to the 9 o' clock position. To fully expose the visual field, the suture is not closed at this point (►**Fig. 3B**). The suture of the anterior wall of the anastomosis in intestinal duct was entered from the serosal layer and exited from the submucosa (►**Fig. 3C**), whereas the bile duct was exited from the inside to the outside side. The anterior wall of the hepatic duct was continuously sutured to the 9 o' clock position, and the last two stitches were knotted to complete the hepaticojejunostomy (►**Fig. 3D**). The needle distance of CS-HJA is controlled at 0.8 to 1.2 mm, and the side distance is 1.2 to 2.5 mm.

Intraoperative and Postoperative Observations and Recording Indicators

After the restoration of intestinal function, a liquid diet was initiated. Discharge would be authorized only when the patient was able to eat regularly without experiencing abdominal pain or other issues. Demographic information, as well as clinical manifestation, cyst type, cyst diameter, surgery time, anesthesia time, perioperative bleeding, transfusion, time to resume oral intake, length of hospital stay, and postoperative problems were tracked and documented. The postoperative follow-up plan: monthly review within 6 months after surgery, then at an interval of 3 months, and once every 3 to 6 months after 1 year, including physical examination, abdominal ultrasound, laboratory tests, and abdominal CT or MRCP, if necessary. The presence of postoperative complications will be evaluated based on the results of the examination.

Statistical Analyses

The statistical information was imported into Excel 2007 and evaluated with the SPSS 23.0 program. The standard deviation and the mean were used to express numerical variables, whereas counts (*N*) and percentages (%) were used to express categorical variables.

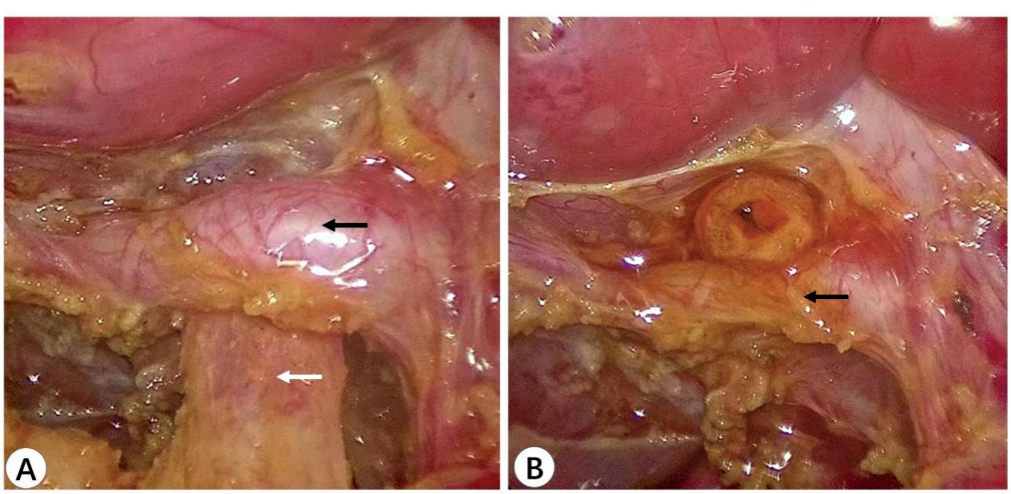

Fig. 2 (**A**) Right hepatic artery (*black arrow*) riding across the common hepatic duct (*white arrow*). (**B**) Right hepatic artery placed posterior to the anastomosis (*black arrow*).

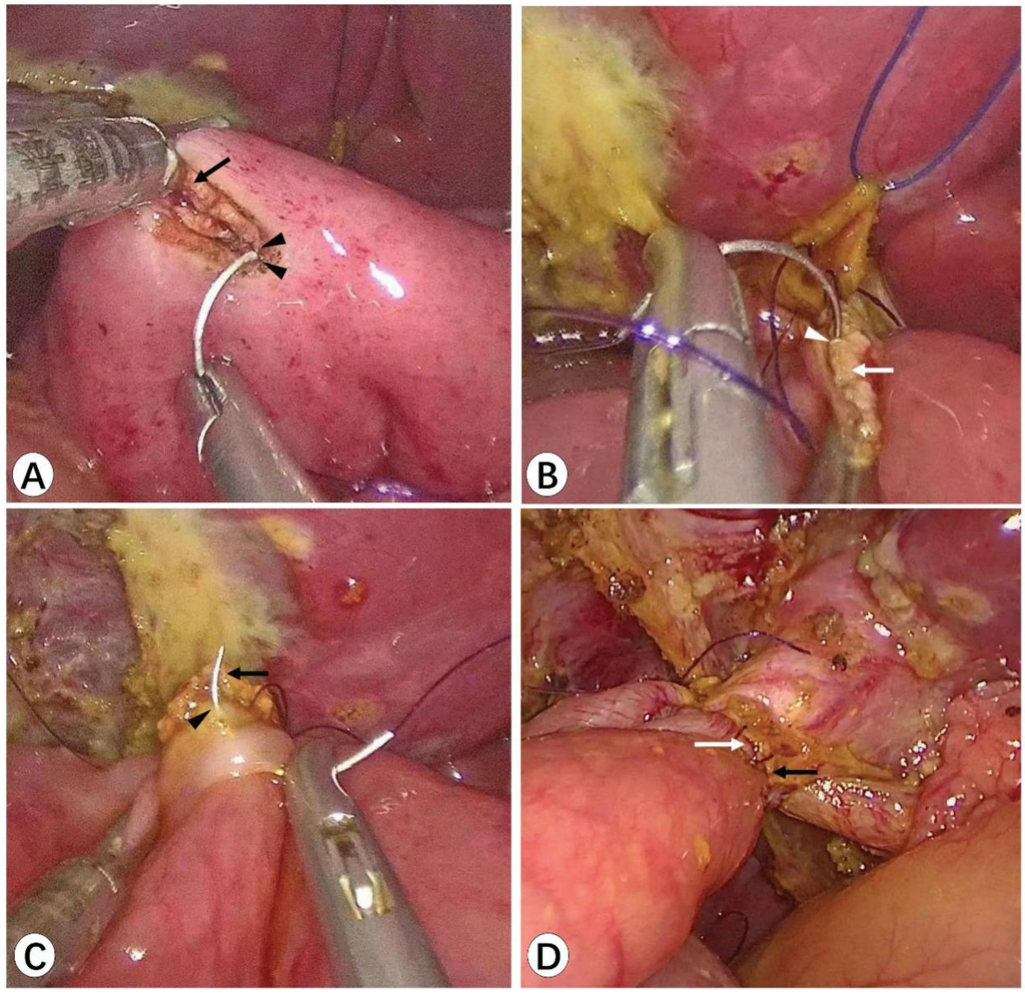

Fig. 3 Technique of continuous submucosal anastomosis in hepaticojejunostomy (CS-HJA). (**A**) The first stitch of the posterior wall anastomosis was entered from the submucosal layer on the right side of the jejunostomy (*shown in triangle*, *arrow* shows the serosal layer). (**B**) Repeated continuous submucosal anastomosis the wall of hepatic duct and the jejunum (mucosal layer *shown in triangle*). (**C**) In the anterior anastomotic stoma, the stitch was entered from the serosal layer and was exited from the submucosal layer (*shown in triangle*, *black arrow* shows the mucosal layer). (**D**) Appearance of the bile-intestinal anastomosis (*black arrow* shows the posterior wall, *white arrow* shows the anterior wall).

Results

The CS-HJA technique was successfully employed in all 10 children to perform SPCH surgery, without any intraoperative complications. The baseline data of the 10 children are shown in ►**Table 1**. Five of them were Todani type Ia, and five were Todani type Ic. The ectopic right hepatic artery was found to be riding across the common hepatic duct in two children, and the ectopic anterior right hepatic artery was repositioned behind the anastomosis. The mean duration of bile-intestinal anastomosis was 27.8 minutes, ranging from 20.4 to 34.3 minutes, and the average hospital stay was 7.04 days, ranging from 5.2 to 9.2 days; no bile leakage occurred after surgery, and the preoperative direct bilirubin of 207.2 µmol/L was reduced to 63.7 µmol/L in one child at discharge, and the direct bilirubin returned to normal on reexamination 1 week after discharge. The remaining nine children were discharged with normal bilirubin levels. During the 17- to 30-month follow-up period, the patients did not experience abdominal pain or jaundice. Reexamination of transaminases, bilirubin, and amylase were normal. Ultrasound showed no bile duct stones and dilated intrahepatic bile ducts with anastomotic stenosis, perioperative details and postoperative outcomes are presented in ►**Table 2**.

Discussion

CDCs are congenital biliary diseases characterized by the dilation of both intrahepatic and extrahepatic bile ducts. The most common type is type I, which involves the dilatation of the extrahepatic bile duct,[7] and the incidence of CDCs is lower in Europe and North America.[8] They are more common in Asia, with a hospitalization rate of up to 1:1000. According to international literature, the male-to-female ratio of CDCs is approximately 3 to 4:1, although this ratio varies in different regions.[9] Approximately 60% of CDCs are diagnosed within the first year after birth. The main clinical manifestations include the triad of abdominal pain, abdominal mass, and jaundice. Surgical resection is the recommended

Table 1 Characteristics of the patients

$N = 10$	Sex (M/F)	Age (mo)[a]	Weight (kg)[a]	WBC (10^9/L)[a]	Cyst type	Diameter of anastomotic (mm)[a]	(Pre/postoperative) DBIL (μmoL/h)[a]	(Pre/postoperative) ALT (U/L)[a]	(Pre/postoperative) r-GT (U/L)[a]	Date of operation
Case 1	Female	3	6	6.37	Ic	5	5.2/5.8	72/32	238/206	June 5, 2020
Case 2	Female	120	29	11.38	Ia	4	4.3/9.1	60/31	169/156	June 28, 2020
Case 3	Female	48	15	12.19	Ic	5	8.9/11.5	282/23	171/143	June 29, 2020
Case 4	Male	84	16	7.16	Ia	3	10.4/4.6	212/113	217/187	November 10, 2020
Case 5	Female	48	16	9.82	Ic	5	7.5/7.4	56/23	187/134	December 24, 2020
Case 6	Female	28	10	8.9	Ia	2.6	6.9/14.9	10/38	294/276	January 5, 2021
Case 7	Female	36	19	6.79	Ic	5	4.6/10.1	13/50	164/196	January 29, 2021
Case 8	Female	29	13	7.14	Ia	3.5	12/11.4	11.6/45	238/206	February 2, 2021
Case 9	Female	120	41	5.58	Ic	5	50.3/30.4	385/121	164/196	March 26, 2021
Case 10	Female	36	12	10.88	Ia	5	207.2/63.7	146/39	511/513	May 25, 2021
$N = 10$	3/7	55.2 ± 43.6	11.6 ± 4.1	8.62 ± 2.33	5/5	4.1 ± 1.2	38.4 ± 73.23/ 15.99 ± 19.67	124.26 ± 119.98/ 51.5 ± 36.99	241.3 ± 111.89/ 211.6 ± 114.79	

Abbreviations: ALT, alanine transferase; DBIL, direct bilirubin; r-GT, r-glutamyl transpeptidase; WBC, white blood cell count.
[a]Mean, standard deviation.

Table 2 Intraoperative and postoperative outcomes and complications

$N = 10$	Operation time (min)[a]	CS-HJA time (min)[a]	Bleeding (mL)[a]	Transfusion rate	Conversion to open surgery	Time to water (d)[a]	Time to solids diet (d)[a]	Complications	Hospital stay (d)[a]	Drainage tube (yes/no)	View data (yes/no)	Follow-up duration (mo)[a]
Case 1	125	22.5	10	0	0	0.5	–	0	6.4	Yes	Yes	29
Case 2	290	20.4	18	0	0	1	2	0	9.2	Yes	Yes	29
Case 3	240	40	25	0	0	1.5	3.8	0	7.3	Yes	Yes	30
Case 4	215	32.4	20	0	0	1.3	2.7	0	8	Yes	Yes	26
Case 5	250	21.4	20	0	0	1.5	3.7	0	5.2	Yes	Yes	24
Case 6	170	24	5	0	0	1.4	3.5	0	6.5	Yes	Yes	17
Case 7	200	22.4	22	0	0	1.6	2.9	0	6.3	Yes	Yes	24
Case 8	220	34.3	20	0	0	1.6	3.6	0	7.6	Yes	Yes	18
Case 9	225	32	15	0	0	1.8	3.5	0	7.2	Yes	Yes	19
Case 10	240	26	5	0	0	2	3.7	0	8.0	Yes	Yes	18
$N = 10$	218.5 ± 59.99	27.8 ± 6.86	15.5 ± 7.08	0 (0.00%)	0 (0.00%)	1.51 ± 0.42	3.34 ± 0.71	0 (0.00%)	7.04 ± 1.48	(10/0)	(10/0)	22.8 ± 4.74

Abbreviation: CS-HJA, continuous submucosal anastomosis in hepaticojejunostomy.
[a]Mean, standard deviation.

treatment upon diagnosis.[10] Currently, the main surgical approaches for CDCs include open surgery, laparoscopic surgery, and robotic surgery. Laparoscopic and robot-assisted surgeries have more advantages in terms of cosmetics and faster recovery and provide better vision in the narrow space for surgeries involving structures such as the bile duct, portal vein, and hepatic artery.[10] However, Da Vinci robot surgery requires advanced hospital equipment and incurs higher costs, making it less commonly performed in China. Single-incision laparoscopic surgery, on the other hand, has been recognized as a "minimally invasive and scarless" surgical technique and has been developed the fastest in China. However, single-incision laparoscopic surgery is a difficult technique, and the learning curve is long. Surgeons need to fight against the narrow field of view and the poor "chopstick effect." Since the first report of laparoscopic CDC resection and hepaticojejunostomy by Diao et al[11] for the treatment of pediatric CDCs, our team has been performing this surgery for 10 years since January 2013, completing about 215 cases, accumulating valuable experience, and publishing relevant papers.[12,13] The common complications after CDC excision are bile duct strictures. In a long-term follow-up study conducted by Stringer, which included 41 subjects, the incidence of anastomotic strictures was 10%. The anastomotic diameters in this study ranged from 6 to 25 mm with a median width of 8 mm.[14] However, follow-up data for smaller anastomotic diameters are rarely reported. In clinical practice, we often encounter type I CDCs in children, where the anastomosis required after cyst excision is usually the normal opening of the hepatic duct. Currently, there is no unified standard for the diameter of the hepatic and bile ducts in children. Zhang et al[15] measured the bile duct diameters of 343 children using ultrasound and found that the normal diameter of the bile duct in children is positively correlated with age. Japanese scholars suggest that a bile duct diameter of 5 mm should be used as the boundary for bile duct dilatation.[16] For choledochoenterostomy with an anastomotic diameter less than 5 mm under laparoscopy, the small anastomosis may make the anastomosis difficult to operate, and postoperative stricture is more likely to occur. Studies have demonstrated that the incidence of anastomotic stricture is the highest when the diameter of the anastomosis is less than 5 mm.[17,18] This suggests that the incidence of stricture may be higher for anastomoses with a diameter less than 5 mm. This may be directly related to the anastomotic technique. For smaller anastomoses, overly dense suturing can cause anastomotic stricture, whereas looser suturing can cause anastomotic fistula. Therefore, higher technical requirements are needed for such anastomoses. Currently, with advancements in laparoscopic techniques, some scholars propose a method for choledochoenterostomy with an anastomotic diameter less than 5 mm. The proximal wall of the cyst should be retained to form a "trumpet mouth" to increase the diameter of the anastomosis to more than 1 cm, in order to prevent anastomotic stricture.[19] However, the remaining diseased extrahepatic bile duct may increase the risk of long-term cancer. Stringer et al recommended a surgical method of longitudinal splitting of the anterior wall of the hepatic duct, fixing the hepatic duct to the hepatic portal.[20] This approach is employed when the diameter of the hepatic duct is small, followed by choledochoenterostomy. Chang et al[21] treated 47 patients with CDCs by burying the jejunal loop into the hepatic portal, and no postoperative complications such as cholangitis, bile duct stones, or anastomotic stricture occurred. Zhang et al[22] longitudinally split the anterior wall of the small hepatic duct in the anterior direction and intermittently performed anastomosis under the suspension of both ends. During a 3-year follow-up, ultrasound reexamination showed no signs of bile duct stenosis or dilation in four of the patients.[21] These follow-up data indicate that the above methods are beneficial for bile drainage in patients with portal biliary dilation or a low-convergence position of the left and right hepatic ducts and can prevent postoperative bile duct stones and anastomotic strictures. However, in children without portal biliary dilation and with a high-convergence position of the left and right hepatic ducts. After the resection of a cyst, the small cut ends of the liver ducts tend to sink deeply into the hepatic portal, resulting in increased difficulty when performing operations such as hepatic portal expansion or separation to reach the convergence of the left and right liver ducts. Moreover, animal experiments have shown that using simple end-to-end anastomosis in diameters greater than 8 mm can lead to the formation of annular scars and bile duct stenosis.[21] Therefore, we realize that solving the problem of anastomotic stenosis not only requires enlarging the diameter of the anastomosis but also changing the method of anastomosis.

Based on our nearly 10 years of experience in laparoscopic common bile duct cyst resection, we have developed a comprehensive anastomosis plan called the CS-HJA to address small anastomotic sites (diameter $\leq$ 5 mm). According to our current follow-up results, the effect of this method is quite ideal, and it is especially suitable for single-incision laparoscopic operations without an assistant. This article aims to summarize and share our preliminary experience in suturing techniques for small-diameter biliary anastomosis under single-incision laparoscopy.

Not Suturing the Mucosal Layer of the Intestinal Wall

The technique of nonclosure anastomosis involves suturing the submucosal layer directly to the serosal layer of the intestinal wall while excluding the mucosal layer of the small intestine (►Fig. 4). This type of suturing can protect the mucosa from damage, preserve the blood supply to the submucosa, and ensure a smooth and even mucosal apposition, which is beneficial for the healing of the anastomotic site and reduces scar formation. The apposition of the small intestinal serosal layer and the hepatic duct wall confines the fibrous scar tissue formed after healing to the space between the serosa of the small intestine and the outer wall of the hepatic duct, minimizing the risk of anastomotic stricture. The physical strength and stability of the anastomosis mainly depend on the submucosal muscular layer and the serosal layer of the intestine; therefore, excluding mucosal layer suturing does not compromise the strength of the anastomosis nor increase the risk of anastomotic fistula.

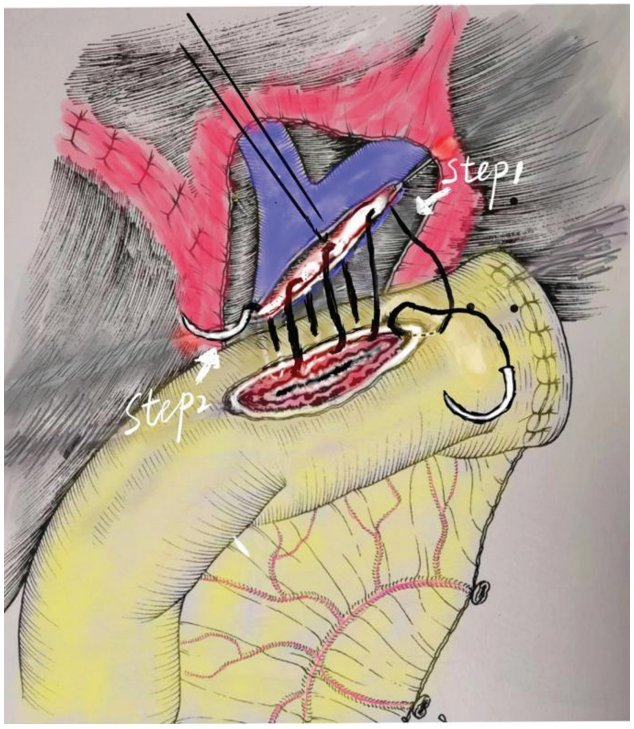

Fig. 4 Step 1 to step 2: the posterior wall of the anastomosis was sutured by avoiding the mucosal layer of the small intestine.

Order of Anastomosis

Performing hepaticojejunostomy without an assistant can be particularly challenging. To overcome this, we made modifications to a 5–0 PDS suture, adjusting it to a final length of approximately 20 cm for the anastomosis. The suturing process begins at the 3 o' clock position and proceeds clockwise to the 9 o' clock position to close the posterior wall. Similarly, the anterior wall is closed counterclockwise from 3 o' clock position to 9 o' clock position using another needle. Precise positioning of the anastomosis is crucial to facilitate the anastomosis process. A 20-cm suture line is used that does not interfere with the procedure and knot-tying. PDS suture is smooth and easy to absorb, effectively reducing the inflammatory response. We use continuous suturing and complete one side of the bile duct before knotting. This allows for enough space to be retained during suturing, ensures clear vision, maintains neat stitch spacing, and ensures that the cutting force of each stitch on the anastomosis is the same after knotting. By avoiding discrepancies in tension between stitches, the risk of leakage is minimized.

Invaginating Anastomosis

During the suturing process, we ensure a margin that is approximately twice the distance between needles, meaning that the needle distance for biliary anastomosis is 0.8 to 1.2 mm, and the margin is 1.2 to 2.5 mm. The lateral wall of the common bile duct, which measures 1.5 to 2.5 mm, is aligned with the serosal layer of the jejunum. After the suture is tightened, a portion of the bile duct is invaginated into the anastomotic site, promoting secure healing and reducing the occurrence of bile leakage and scarring. Because postoperative stricture of the anastomotic site is not only related to the diameter of the anastomotic site, but also to factors such as repeated postoperative cholangitis (►**Fig. 5**).

Handling of the Right Hepatic Artery

During the operation of two patients in this group, it was observed that the right hepatic artery crossed in front of the hepatic duct. Addressing the ectopic anterior placement of the right hepatic artery is crucial as it has been reported that failure to do so can lead to biliary obstruction; it is recommended to fully mobilize the artery and place it behind the anastomotic site.

However, our study has certain limitations. Firstly, the inclusion criteria for this study were limited to the use of single-port laparoscopic CDC excision. Secondly, the summary included children with an anastomotic diameter of less than 5 mm, resulting in a relatively small sample size. Thirdly, our study was retrospective and had a short follow-up period, highlighting the need for further research

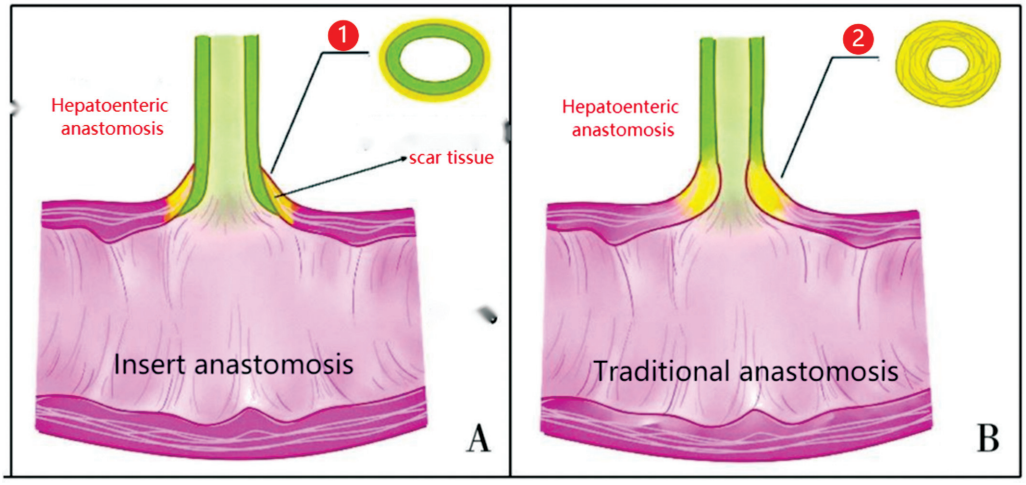

Fig. 5 (A) Insertion suture: scar tissue is staggered at the anastomosis to avoid anastomotic stenosis. (B) Conventional end-to-side suture: anastomotic scar to stenosis.

with larger, multicenter studies, and longer-term follow-up to validate the benefits of this anastomotic technique in children with CDCs and a diameter of less than 5 mm. Nevertheless, based on our collective experience thus far, the CS-HJA anastomotic technique appears to be a safe and feasible approach for these children's surgeries.

Conflict of Interest

None declared.

References

1 Qu X, Cui L, Xu J. Laparoscopic surgery in the treatment of children with choledochal cyst. Pak J Med Sci 2019;35(03):807–811
2 Wen Z, Cheng W, Liang Q, et al. Laparoscopic management of choledochal cysts associated with aberrant hepatic ducts. J Laparoendosc Adv Surg Tech A 2019;29(08):1060–1066
3 de Vries JS, de Vries S, Aronson DC, et al. Choledochal cysts: age of presentation, symptoms, and late complications related to Todani's classification. J Pediatr Surg 2002;37(11):1568–1573
4 Ishibashi H, Shimada M, Kamisawa T, et al; Japanese Study Group on Congenital Biliary Dilatation (JSCBD) Japanese clinical practice guidelines for congenital biliary dilatation. J Hepatobiliary Pancreat Sci 2017;24(01):1–16
5 Pandey V, Srivastava V, Panigrahi P, Kumar R, Sharma SP. Modified laparoscopic excision of choledochal cyst: technique and early results. J Indian Assoc Pediatr Surg 2021;26(05):311–316
6 Wang Z, Guan XS, Yu JK, Zhong W. Modified single-port versus multiport laparoscopic choledochal cysts excision and Roux-en-Y hepaticojejunostomy: a retrospective comparative cohort study. Transl Pediatr 2022;11(11):1831–1839
7 Rubalcava NS, Overman RE, Pilkington M, et al. Laparoscopic choledochal cyst resection using a novel articulating instrument in pediatric patients. J Pediatr Surg Case Rep 2021;70:101888
8 Balanescu L, Moga A, Balanescu R, Strimbu T, Cardoneanu A. Our experience with cyst excision and hepaticoenterostomy for choledocal cyst: a single center case review of 16 patients. Medicina (Kaunas) 2022;58(03):416
9 Katabi N, Pillarisetty VG, DeMatteo R, Klimstra DS. Choledochal cysts: a clinicopathologic study of 36 cases with emphasis on the morphologic and the immunohistochemical features of premalignant and malignant alterations. Hum Pathol 2014;45(10):2107–2114
10 Xie X, Li Y, Li K, Wang Q, Xiang B. Total robot-assisted choledochal cyst excision using da Vinci surgical system in pediatrics: report of 10 cases. J Pediatr Surg 2021;56(03):553–558
11 Diao M, Li L, Dong N, et al. Single-incision laparoscopic Roux-en-Y hepaticojejunostomy using conventional instruments for children with choledochal cysts [J]. Surg Endosc 2012;26(06):1784–1790. Doi: 10.1007/s00464-011-2110-6
12 Tang Y, Li F, He G. Comparison of single-incision and conventional laparoscopic cyst excision and Roux-en-Y hepaticojejunostomy for children with choledochal cysts. Indian J Surg 2016;78(04):259–264
13 Li F, Jie L, Hang H. Efficacy analysis of applying single-incision laparoscopy for choledochal cyst. Zhonghua Xiaoerwaike Zazhi 2021;42(07):604–609
14 Stringer MD. Wide hilar hepaticojejunostomy: the optimum method of reconstruction after choledochal cyst excision. Pediatr Surg Int 2007;23(06):529–532
15 Zhang Y, Wang XL, Li SX, et al. Ultrasonographic dimensions of the common bile duct in Chinese children: results of 343 cases. J Pediatr Surg 2013;48(09):1892–1896
16 Hamada Y, Ando H, Kamisawa T, et al. Diagnostic criteria for congenital biliary dilatation 2015. J Hepatobiliary Pancreat Sci 2016;23(06):342–346
17 Sheng Q, Lv Z, Xu W, Xiao X, Liu J, Wu Y. Reoperation after cyst excision with hepaticojejunostomy for choledochal cysts: our experience in 18 cases. Med Sci Monit 2017;23:1371–1377
18 Urushihara N, Fukumoto K, Nouso H, et al. Hepatic ductoplasty and hepaticojejunostomy to treat narrow common hepatic duct during laparoscopic surgery for choledochal cyst. Pediatr Surg Int 2015;31(10):983–986
19 Cai DT, Gao ZG, Zhang YB, et al. Analysis of middle/long-term complications after laparoscopic choledochal cyst radical excision: a summary of treatment experiences. Zhonghua Xiaoerwaike Zazhi 2019;40(05):440–446
20 Stringer MD. Laparoscopic management of choledochal cysts: is a keyhole view missing the big picture? Pediatr Surg Int 2017;33(06):651–655
21 Chang XP, Tang ST, Cao GQ, et al. Laparoscopic widened-porta embedding anastomosis for choledochal cysts with a narrow portal bile duct. Linchuang Xiaoer Waike Zazhi 2019;18(07):552–558
22 Zhang YB, Gao ZG, Chen QJ, et al. Paroscopy for congenital biliary dilatation with a small diameter of common hepatic duct or accessory hepatic ducts. Linchuang Xiaoer Waike Zazhi 2021;20(11):1054–1058

