Accepted Manuscript online: 2023-07-21 Article published online: 2024-03-05

How a Robotic Visualization System Can Facilitate Targeted Muscle Reinnervation

Vesta Brauckmann, MD[1,*] Jorge R. Mayor, MD[1,*] Luisa Ernst, BSc[2] Jennifer Ernst, MD[1]

[1] Department of Trauma Surgery, Hannover Medical School, Hannover, Germany
[2] Study Program Medical Engineering, Technologies and Development Processes, Furtwangen University, Tuttlingen, Germany

Address for correspondence Jennifer Ernst, MD, Department of Trauma Surgery, Hannover Medical School, Carl-Neuberg-Str. 1, 30625 Hannover, Germany (e-mail: ernst.jennifer@mh-hannover.de).

J Reconstr Microsurg Open 2024;9:e19–e26.

Abstract

Background Innovations in medical technologies have impacted surgery sustainably in the last decades. To enable and further improve microsurgical outcomes, different loupes and optic-based microscopes have been proposed in recent years. In amputation surgery continuous progress and prosthetic developments have provided amputees with an improved degree of function and quality of life.

Herein, we present a 17-year-old patient who suffered a traumatic loss of the left upper limb and underwent target muscle reinnervation surgery facilitated by a three-dimensional (3D) robotic exoscope system.

Methods The rerouting of the distal ends of the arm nerves (TMR) was performed in the upper limb of a traumatic transhumeral amputee patient using a 3D robotic exoscope system (RS, RoboticScope, BHS Technologies, Innsbruck, Austria). Perioperative data was collected and compared to standard. Users' perspective evaluation of the system during the surgical procedure was done using a 5-point Likert scale.

Results Operation time was 311 minutes, the robotic system was used for 101 minutes. Overall users' evaluation revealed a 4.5 for the selected items on the Likert scale. The evaluation showed similar results in the evaluation of the system by the main and assistant surgeons. No special training was required beforehand. The bimanual control allowed for improved personal freedom in the surgical field at a comfortable position. The imaging of colors will need future improvements until an authentic representation of in situ structures is achieved.

Conclusion Major advantages of a robotic scope 3D exoscope system are improved image quality, ergonomic position, and increased accessibility in a wider operating field due to system-implied features. Another benefit is digital documentation and simultaneous education through the possibility of capturing images and videos, as well as easy transportation in between operating rooms without risk to harm the vulnerable optic. Digital microscopes are still associated with high acquisition costs, and they are not yet implemented as standard of care due to limited experience.

Keywords
- robotic surgery
- computer-assisted surgery
- image-guided surgery
- TMR
- transhumeral amputation
- targeted muscle reinnervation

* *These authors contributed equally to this research article and retain the first authorship.*

received November 11, 2022
accepted after revision June 8, 2023
accepted manuscript online July 21, 2023

DOI https://doi.org/10.1055/a-2134-8633.
ISSN 2377-0813.

There is an increasing trend in the number of limb amputations.[1] Continuous progress in amputation surgery and prosthetic development have provided the patients with an improved degree of function and overall quality of life. However, regaining a high level of function remains a challenge.

Target muscle reinnervation (TMR) describes a nerve transfer technique in which residual (motor) nerves from the amputated limb are transferred by an end-to-end epineural coaptation to the motor branches of muscle targets, acting as biological amplifiers of the amputated nerve signals. These myoelectric signals allow for an intuitive control of multiple joints in advanced prosthesis.[2,3] Patients who undergo TMR also profit from a relief in neuroma and phantom limb pain.[4] This is a great advantage, as around 25% of the major limb amputees will suffer from chronic pain caused by painful residual limb neuromas. The proportion of patients with neuroma pain after suffering a traumatic amputation may be as high as 70%.[5]

Microsurgical interventions as described above require visual magnification of the surgical field. The use of virtual microscopes has been on the rise in recent years with constant strive for improvement. Typical applications are in the fields of neuro- and spine surgery, ophthalmic surgery, ear-nose-throat (ENT) surgery, endodontics, as well as plastic and reconstructive surgery.[6] The use of a three-dimensional (3D) exoscope camera system has been described in microvascular free flap surgery and in many neurosurgical procedures.[7–10] Robotic microscopes are available from different manufacturers with different features, for example, voice control.[11] The common goal is to enhance surgical performance through revelation of more details with better image resolution and depth perception. However, the application of robotic-assisted methods in surgery is still in its infancy, and as a result, it is still limited.[12] Recently, a novel 3D robotic exoscope system (RoboticScope [RS], BHS Technologies, Innsbruck, Austria) has been developed. The RS includes a digital, 3D camera that transmits real-time, high-resolution images to two micromonitors placed in front of the surgeon's eye. The RS system has been evaluated in the surgical procedures of lymphovenous anastomosis,[13] in diverse surgical settings of otorhinolaryngology, such as cochlear implants and oncological surgery,[14,15] and in the neurosurgical resection of intracranial tumors.[8]

To the best of our knowledge, we are the first to describe the use of the system for TMR surgery. Furthermore, we evaluate the impact of the described advantages of the innovative visualization approach for upper limb TMR surgery.

Case Description

Bomb attacks and further explosive weapons in urban areas have inflicted a wide range of civilian deaths and severe injuries, including children during ongoing wars. Herein, we present a 17-year-old patient who suffered a traumatic loss of the nondominant left upper limb after a bomb explosion. At the point of the accident the patient was a healthy individual with an early childhood developmental disorder as only comorbidity. After debridement, including irrigation to condition the wound and control the infection of the residual limb, we treated the patient in our department of trauma surgery performing a TMR with the use of a 3D robotic exoscope system.

The patient was transferred within a humanitarian help framework after a bomb attack in early April 2022. The patient suffered a traumatic amputation of the left upper arm and a soft tissue injury with shrapnel spraying in the left-lateral thigh and left knee. The mother and the sister were also present during this attack, the sister standing to his left side died. Before the treatment in our clinic the patient was stabilized in his home country. After arrival at our facility, debridement, irrigation, and exploration of the wound followed immediately. A vacuum-assisted closure (VAC) system was implemented to foster cleaning and granulation at both injury sites. The microbiological results of the intraoperative samples showed bacterial contamination of the wounds with *Acinetobacter baumannii* (3MRGN), *Enterococcus faecalis*, and *Corynebacterium striatum*. The second and third look was carried out at day 5 and 7 after admission including debridement and VAC change. An antibiotic therapy with meropenem and colistin was initiated at day 3. At day 20 a split-skin graft to the wound of the left thigh was performed and the injury of the lateral knee could be closed. Finally, 5 weeks after amputation and 29 days after admission and control of the infection at the residual limb, the nerves at upper arm were rerouted (TMR) with the use of a 3D visualization robotic scope system. Subsequently, an additional oral antibiosis was given for further 7 days (amoxicillin and clavulanic acid).

Methods

Intraoperative 3D Visualization

The RoboticScope (BHS Technologies GmbH), a 3D visualization system, was used. The three main components of the system are the head-mounted display (HMD), the 6-axis robotic arm, and a full digital camera unit. The HMD weighs approximately 0.5 kg and is available also for the assisting surgeon. The resolution of the camera system is specified with merged 4K 4,928 × 2,056 pixels, extended full high definition at high dynamic range (HD)/(HDR +). The working distance measures 400 to 600 mm with a magnification factor of 2.7 to 30.1 at a magnification range of 11.1. The system can be controlled by the surgeon's head movements and a foot pedal. The user interface describes a surface displaying in the field of view of the surgeon (►**Fig. 1**).

It differentiates between primary and secondary functions. Primary functions are located on the inner function ring and are the tools that are considered most important for surgery, such as adjustment of the working area including zoom, orbit view, free view, as well as focus at different depth. Secondary adjustments are adjustment of light intensity, capturing of images, two-dimensional viewing mode, saving of a position, change of the working distance, and lastly the possibility to lift the HMD eye pieces up and to continue operation without additional robotic visualization.

For the surgery the robotic arm was covered in sterile drapes. The main surgeon and the assistant surgeons were

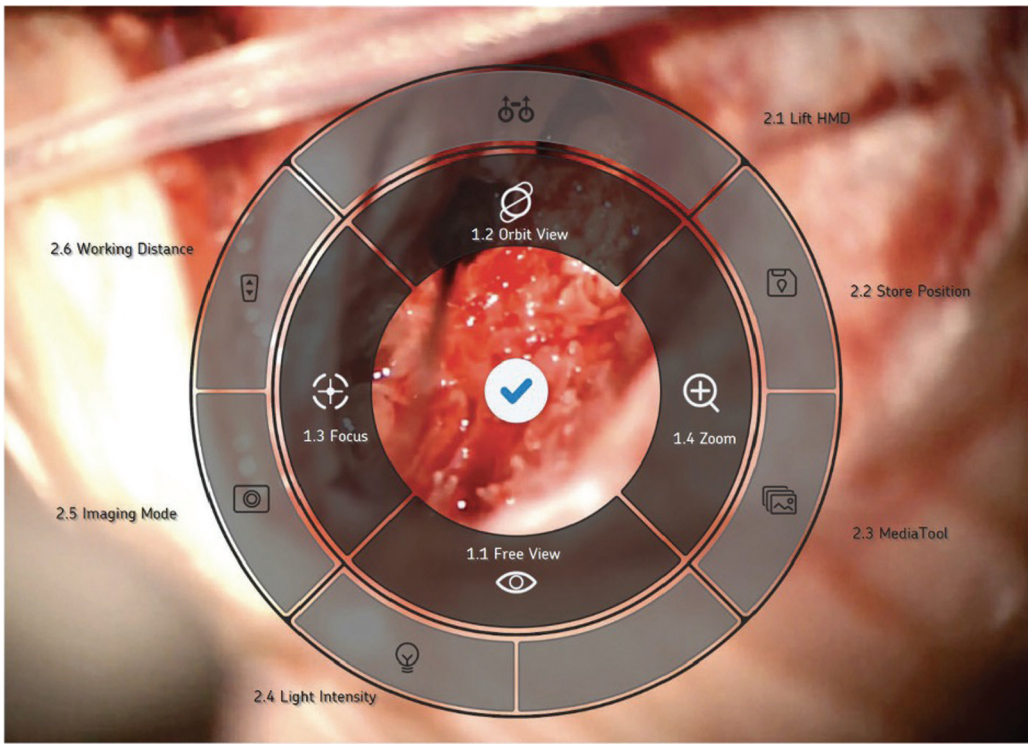

Fig. 1 User interface of the RoboticScope.[26]

introduced to the system in a 15-minute session right before surgery. Introduction included: general donning and doffing of the HMD, personal adaptations of the HMD, as well as guidance through the user interface. The workflow was repeated in dry run exercises, until the (assistant) surgeon felt comfortable enough to perform the planned nerve transfer with the robotic visualization system.

Experience of the Operating Team

See ►**Table 1**.

Description of the Surgical Procedure

The procedure was performed in supine position with the arm on an additional table ensuring that hyperextension of the shoulder can expose the posterior arm. The patient was put under general anesthesia without long-acting muscle relaxants to allow for intraoperative nerve stimulation. The marked preoperative sites of the Hoffmann–Tinel signs over the median nerve (MN), radial nerve (RN), and ulnar nerve (UN) end-neuromas were marked again after VAC dressing was removed. The VAC removal revealed the distal end of the 21-cm-long residual humerus bone (►**Fig. 2**).

After irrigation, debridement, and resection of heterotopic ossifications at the bone-end and osteotomy of the distal part of the humerus bone, three neuromas were macroscopically visible: medially the UN, lateral to UN the MN, and dorsal to the humerus bone the distal part of the RN. After marking the perineurium at distal nerve ends with 6-0

Table 1 Previous education, motivation, and expectations of the surgeons

	Surgeon 1	Surgeons 2 and 3
• Specialty	Board-certified plastic surgeon	Residents in trauma surgery
• Time since board certification/experience	2.5 years	2nd and 4th year of residency
• Further surgical skills	Senior soft tissue sarcoma surgeon; certified DaVinci System surgeon; experiences in super-microsurgery	None
• Skills in amputations surgery	TMR, TSR, RPNI, osseointegration, residual limb revision surgery, amputations	None
• Current field of activity	Amputation surgery	According to curriculum
• Motivation	Widen the skills in microsurgery	Experience assisting in microsurgical procedures
• Expectations	Improve course and precision of the surgery, further knowledge in innovative technologies	Learn about possibilities in microsurgery

Abbreviations: RPNI, regenerative peripheral nerve interface; TMR, targeted muscle reinnervation; TSR, targeted sensory reinnervation.

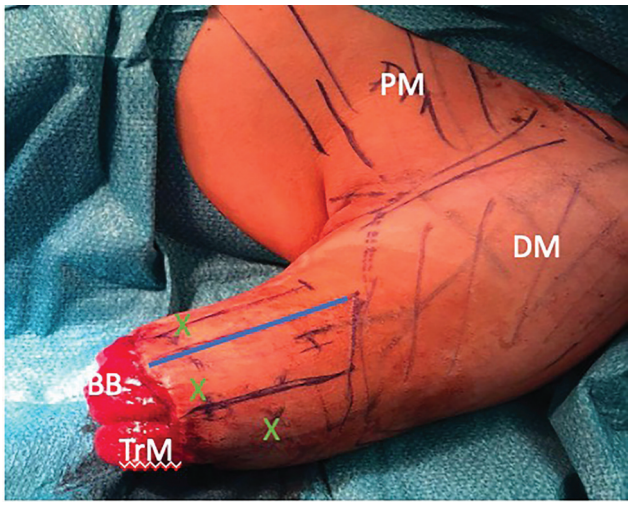

Fig. 2 Depicting the operating field: 21 cm long residual arm. X depicts the location of the Hoffmann–Tinel (HT) signs from medial to lateral ulnar nerve (UN), median nerve (MN), and radial nerve (RN); PM, pectoralis major muscle; DM, deltoid muscle; *blue line*, planned ventral incision line; BB, biceps and brachial muscle bellies; TrM, triceps muscle, lateral head.

polypropylene sutures, a 12-cm anterior incision along the previously marked raphe between the long and the short heads of the biceps brachii muscle bellies exposed the subcutaneous fat layer. Then, a proximally based adipofascial flap of approximately 2×6 cm centered on the raphe was mobilized proximally. Following, the identification of the raphe between the muscle heads was easy. For details of the TMR surgery, please see Gart et al.[16] Furthermore, the residual brachialis muscle could be identified. At this point of the surgery the surgeon and the assistant surgeon put on the HMD and step-by-step dissection between the two heads of the biceps revealed the motor branches of the musculocutaneous nerve (MCN) to each head of the biceps muscle bellies. Following, the MCN continuation into the motor branch to the brachialis (MCN-Br) was identified and marked with nerve loops after electrical stimulation and verification (►**Fig. 3**).

Once the MCN motor entry points have been identified, attention turned to the identification of the MN and the UN by transposing the short head of the biceps medially to reveal the medial aspect of the humerus. A long-distance damaged UN was found up to the level of the axillary fold. MN und UN distal neuroma nerve ends were dissected at the level of healthy fascicles. The preparation at the medial aspect of the arm revealed and no residual head of the long triceps muscle belly. Thus, no further posterior incision was made to identify the RN motor branches to the triceps muscle bellies and to transpose the distal RN to them, as the remaining triceps muscle bellies needed to be maintained for the myosignal for elbow extension and the UN was damaged up to the axillary fold.

After all the structures of interest were identified, the remaining MN was carefully transposed deep to the short head of the biceps into the space between the biceps muscle bellies. Then, the native MN motor branch to the short head was dissected approximately 5 mm before entering the muscle belly. The proximal end of the dissected motor nerve was further shortened to move it away from the nerve coaptation site to prevent it from reinnervation. The transposed MN segment was then coapted to the motor nerve entry point using 8-0 polypropylene suture. The end-to-end epineural sutures were stabilized by fibrin glue. In the same manner the UN was transposed and coapted to the motor branches of the brachialis muscle. To protect the coaptation from tension, an additional suture was used to let the neighboring epimysium secure the nerve coaptation site.

To prevent neuroma pain the distal RN was cut back to healthy fascicles, buried into a denervated part of the lateral triceps muscle depth by an epineural-epimysial suture using 6-0 polypropylene.

To improve the myosignaling of the short biceps muscle, the belly was detached at the coracoid through a 0.8-cm skin incision right above the coracoid process. Then, the elevated

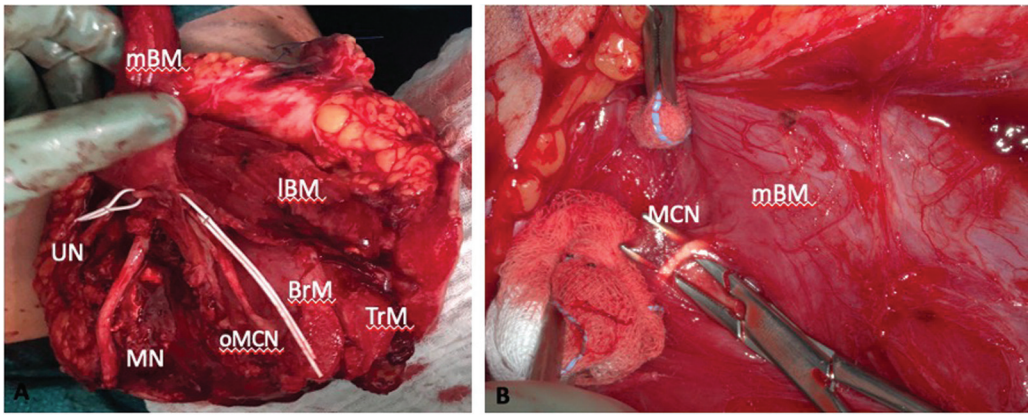

Fig. 3 (**A**) The medial biceps belly head (mBM) is elevated, to its right is the lateral BM (lBM). The two white loops are located around the musculocutaneous nerve (MCN) branches to the medial head (*left*) and lateral biceps muscle head (*right*). Short, distally damaged ulnar nerve (UN); median nerve (MN) and original MCN (oMCN) to brachial muscle (BrM). TrM, muscle belly of triceps muscle. (**B**) MCN motor branch to the mBM. The pinky color of the muscle is captured in (**B**). The surgeon needed a certain time (ca. 20 minutes) to adapt to the tending toward pinky shades of the muscle and nerves when using the RoboticScope (RS).

adipofascial flap was placed between the long and the short heads of the biceps to spatially disconnect the future myoelectric signals. As beginning with the closure of the anterior incision the HMD was demounted. The subcutaneous tissues are closed in standard fashion, and the skin is closed with staples and epicutaneous white VAC sponge.

Evaluation of the System

After performing the surgery with the 3D robotic exoscope system, the introduction and the system was evaluated by a 7-item questionnaire using a 5-point Likert scale (1 = not at all, 5 = to a great degree).

Results

Perioperative Data

Operation time was 311 minutes. The time of video tracking was 1:41:13 hours, showing action of the RS for 101 minutes of the total operating time.

The preparation of the surgical setup took 11.43 minutes for sterile covering of the RS, the booting of the RS, connecting the HMD to the RS, and adjusting the HMD to the surgeons' head. The HMD was adaptable to the surgeons' head circumference and pupillary distance once. The high-resolution 3D camera of RS was easily placed sterile over the surgical field.

The HMD-implemented motion sensor worked properly, and no delay was reported by the main surgeon. Same was reported for the hands-free change of the exoscope position via head movements. Within this procedure, the surgeon reported 100% control of the RS at all times of the surgery.

The HMD camera pictures were transferred real-time to the monitor allowing for education of the operating room audience. This tool was used for 1:41:13 hours.

The access and controlling of the HMD control menu were easy. The robot arm was set to the basic position by pressing a single button for more than 10 times allowing for panorama view of the entire operating area (residual upper arm and axillary fold). The function "OrbitView" (OV) was the most used function. OV allowed the alteration of view angles could easily and reliably be controlled via head movements, and the body position could be maintained during the whole procedure. The function enabled different view angles and directions without losing focus of a previously focused area allowing to view alternating the donor and recipient nerve at distances.

Thus, the possible range of magnification enabled a detailed depiction of the peripheral nerves as well as a good overview of the operation site. The image resolution was good, and high degrees of magnification did not result in a loss of resolution due to the full optical zoom. Although we noticed an unauthentic pinky shade of the nerves and muscle. The accompanying representative was able to guide the operating team through the menu to adapt lighting resulting in a change of color settings for a more vivid and natural imaging allowing an easier identification of the small motor nerve branches. The light intensity could be changed in fine nuances. The picture of the operation site occasionally

Fig. 4 The RoboticScope (BHS Technologies GmbH, Innsbruck, Austria) in surgery. Both—surgeon and assistant surgeon—wear the head-mounted display (HMD) comfortably attached to the head. The HMD weighs approximately 0.5 kg and was felt comfortable due to the helmet design and individual adaptions.

did not lack any brightness, but the light of the operating room needed to be switched off to improve the focus on the operating field.

During the entire surgery the weight of the HMD felt comfortable. The overall positioning and handling of the RS was convenient. The outcome of the patient was good. There were no intra- or postoperative complications (►**Fig. 4**; ►**Tables 2** and **3**).

Discussion

The innovative imaging approach for peripheral nerve microsurgery worked synergistically. The postoperative evaluation was unanimous; both from the primary surgeon and assistant surgeons. While no special training was required beforehand, a certain learning and adaptation curve to depicted colors was described of necessity for operating the device.

We have found that especially the HMD-implemented motion sensors and the feature of OV allow an enormous bimanual control and free body movement with change of position without any disruption of view or workflow interruption. The most used function was therefore the OV. The possibility of saving fixed positions and the change of the working distance of the system at different times during the

Table 2 Evaluation of the 3D robotic exoscope system

Item	Not at all	To a small degree	To a moderate degree	To a considerable degree	To a great degree
Intraoperative handling of the system				1,2,3	
Ergonomic setting (comfortableness)					1,2,3
Realistic quality of image			1,2,3		
Interface use in workflow				1,2,3	
Usefulness of preoperative introduction					1,2,3
Intuitive use of the interface				1,2,3	
Quality of support/guidance from company representatives					1,2,3

Abbreviations: 3D, three-dimensional; RS, RoboticScope.
Note: The 7-item questionnaire shows a very similar evaluation of the RS by both surgeon (1) and assistant surgeons (2, 3).

Table 3 Comparison between two TMR surgeries with (patient X) and without the use of the RS (Y)

Patient	Side	Length humerus (cm)	Nerve matrix	Duration of surgery (min)	
X	Right	20.4	• Median nerve medial biceps muscle • Distal radial nerve lateral triceps muscle • Ulnar nerve brachialis muscle	253	Revision
Y	Left	X	• VAC removal • Irrigation and debridement • Removal of HO • Osteomy: shortening of humerus stump (1 cm) • Median nerve medial biceps brachii muscle • Radial nerve buried to triceps muscle (long head) • Ulnar nerve to brachialis muscle • Myoplasty	311	Primary TMR

Abbreviations: HO, heterotopic ossification; RS, RoboticScope; TMR, targeted muscle reinnervation; VAC, vacuum-assisted closure.
Note: The longer operating time of 58 minutes can be referred to the additional steps needed to shape the residual arm stump.

surgery enabled a rapid change within the situs and may allow for shorter operating after repetitive use of the system. During TMR surgery the operating field requiring magnification is very wide: the motor entry points of the MCN are usually found at the junction between the proximal and the middle thirds of the muscle, and the motor entry point into the brachialis is found at the junction of the middle and the distal thirds of the brachialis muscle at different depth. Thus, the dynamic 3D zooming was rated very beneficial and differs mainly to the functioning of conventional microscopes which require manual adjustments of settings and position at often unfavorable angles.

The reliable function of the hand motion sensors and OV features facilitated the dynamic exploration of the identified neuromas (donor nerve) and motor entry points into the biceps (recipient nerves) while not having to remove the hands from the operating field.

Furthermore, the easy lift of the HMD eye pieces up by a head movement allows it to work without additional robotic visualization still at an ergonomic and comfortable working position and freedom of movement at any time of the surgery without doffing the whole system. The weight of the HMD (485 g) was not felt heavy and did not cause headache or neck pain in contrast to other reports.[17] A considerably featured characteristic of the system is thus an ergonomic working position with improved personal comfort and freedom of surgical movement.[8] To understand why this is of interest is to understand the ergonomic habits of surgeons. Especially regarding microsurgery, a major issue is the high susceptibility to musculoskeletal pain due to the use of heavy magnification leading to high atlantoaxial strain. This, in combination with persistent neck (hyper-) flexion and static positions has been shown to induce chronic pain in the neck and shoulders in 87% of surveyed microsurgeons.[18] Discomfort and musculoskeletal pain are attributed to poor posture, especially in the cervical angle and in general to nonergonomic surgical setups.[18] Several publications have appeared in the recent years documenting as high as 70% of surgeons suffering from musculoskeletal pain going beyond the operating room and thus affecting personal lives, with even higher numbers of affected plastic surgeons with almost 80%.[19] The implementation of an heads-up approach is considered to reduce heads-down fatigue, it may be achieved with the use of digital visualization.[6,14] Reports of this approach have described it as a more comfortable and consistent working environment, being preferred in over

90% of surgeons, who have tried both approaches.[20–22] Another issue to consider is the controlled distance using the HMD. The wide focal distance allows for an unobstructed working space and can be seen as further measure when personal protection against infections in microsurgery is not entirely feasible.[23] Also, the distance and use of light-emitting diode illumination was shown to reduce heat generation and thus burns of the patient.[6,8] Moreover, the additional external monitor enables viewers to follow the procedure which in turn aids in resident training and further education.[6,12]

The aforementioned surgical procedures, for example, in neurosurgery, have reported good outcomes with no intra- or postoperative complications and comparable operating time similar to our results, one reason for immediate comparable operating times might be the lack of necessity to adjust eyepieces and objective distance when moving the operating field. However, the benefits of deploying robotics in most settings remain contested. The advantages of using robotic systems in most cases are up for debate since documented clinical cases are few.[8,10,12,20]

Experiences in neurosurgery and ENT surgery have shown an unnatural color representation of the digital display comparable to what we experienced with depicting nerve tissue.[14,20] In agreement with those publications we have also noted that even though secondary adjustments of light intensity are possible, the colors displayed are not always comparable to living tissue,[14] which is especially relevant for differentiation of nerves and blood vessels. However, one point to consider is that digital systems do allow for updates, and with that upgrade, one might be able to adjust the color visualization in near future.

Reported disadvantages were the large volume and weight of the 3D exoscope systems with possible difficulties of moving between the operating rooms.[6] The RS system provides wheels and can be easily moved between the operating rooms. Furthermore, a considerable point is the reduced risk of damage related to transportation of the system in comparison to a conventional microscope as visualization in 3D exoscopes relies on camera systems which are less fragile than optical systems. The transport ability allows for a commune use of the system in different operating rooms and for use by different specialties at one hospital and targets another drawback considering the high acquisition costs, especially since digital microscopes are not yet implemented as standard of care due to limited experiences and cases.[8,12,24]

This is comparable to the use of robotic-assisted surgery systems for (peripheral nerve) surgery, which were shown to improve the virtual reality visualization, tremor filtration, and allow for minimally invasive approaches and ergonomics, but at limited clinical advantage regarding operating time and costs. The main reasons which prohibit the prevalence of the robotic surgical systems in (peripheral nerve) surgery are the high cost of the robotic system and a long learning curve of the surgeon and his team. Up to 30% of the robotic approaches to peripheral nerves fail or need to be converted to open approach, thus making the comparison limited. The use of 3D exoscope systems seem not to require a long learning curve or impact the duration of the surgery.[12,24]

Evaluation of 3D exoscope systems such as the RS as an alternative to the operative microscope needs to be investigated in controlled setups as simulation settings allowing to objectify the results. The effect of 3D visualization on depth effect, visualization, magnification, illumination of the operating field, and ergonomics, precision, and operating time of the surgeon needs to be analyzed to identify further indications for the use of 3D exoscope systems.[25]

Conclusion

The 3D robotic exoscope system provides advantages in terms of enhanced workflow with higher efficacy for peripheral nerve surgery at the upper extremity and increased comfort of the surgeon during the microsurgical steps of the TMR procedure. The overall quality of the intraoperative digital imaging was rated not inferior to that of traditional optical microscopes including resolution, focus, and lightening. The colors of the depicted operating field need further improvement. It needs to be further clarified if the RS benefits in clinical routine and if the robot can dramatically increase the operation precision in different indications. The RS added value by facilitating nerve transfers, education, and ergonomics of the surgeon with reduced physical discomfort. The herein used 3D robotic exoscope system is a promising device that might represent a valuable and possibly superior alternative to conventional tools for intraoperative visualization. Although the use of robotic-assisted techniques in clinical settings is still very limited, we believe that when used appropriately, its deployment in the future will offer great benefits to both surgeons and patients.

Conflict of Interest
None declared.

References

1 Ziegler-Graham K, MacKenzie EJ, Ephraim PL, Travison TG, Brookmeyer R. Estimating the prevalence of limb loss in the United States: 2005 to 2050. Arch Phys Med Rehabil 2008;89(03): 422–429
2 Kuiken TA, Barlow AK, Hargrove L, Dumanian GA. Targeted muscle reinnervation for the upper and lower extremity. Tech Orthop 2017;32(02):109–116
3 Wimalawansa SM, Lygrisse D, Anderson SR, et al. Targeted muscle reinnervation in partial hand amputations. Plast Reconstr Surg Glob Open 2021;9(05):e3542
4 Valerio IL, Dumanian GA, Jordan SW, et al. Preemptive treatment of phantom and residual limb pain with targeted muscle reinnervation at the time of major limb amputation. J Am Coll Surg 2019; 228(03):217–226
5 Souza JM, Cheesborough JE, Ko JH, Cho MS, Kuiken TA, Dumanian GA. Targeted muscle reinnervation: a novel approach to postamputation neuroma pain. Clin Orthop Relat Res 2014;472(10): 2984–2990
6 Ma L, Fei B. Comprehensive review of surgical microscopes: technology development and medical applications. J Biomed Opt 2021;26(01):1–74

7 Piatkowski AA, Keuter XHA, Schols RM, van der Hulst RRWJ. Potential of performing a microvascular free flap reconstruction using solely a 3D exoscope instead of a conventional microscope. J Plast Reconstr Aesthet Surg 2018;71(11):1664–1678
8 Piloni M, Bailo M, Gagliardi F, Mortini P. Resection of intracranial tumors with a robotic-assisted digital microscope: a preliminary experience with robotic scope. World Neurosurg 2021;152: e205–e211
9 Gonen L, Chakravarthi SS, Monroy-Sosa A, et al. Initial experience with a robotically operated video optical telescopic-microscope in cranial neurosurgery: feasibility, safety, and clinical applications. Neurosurg Focus 2017;42(05):E9
10 Maurer S, Prinz V, Qasem LE, et al. Evaluation of a novel three-dimensional robotic digital microscope (Aeos) in neurosurgery. Cancers (Basel) 2021;13(17):4273
11 Sun X, Okamoto J, Masamune K, Muragaki Y. Robotic technology in operating rooms: a review. Curr Robot Rep 2021;2(03): 333–341
12 Chen LWY, Goh M, Goh R, et al. Robotic-assisted peripheral nerve surgery: a systematic review. J Reconstr Microsurg 2021;37(06): 503–513
13 Scaglioni MF, Meroni M, Fritsche E, Linder T, Rajan G. Use of the BHS robotic scope to perform lymphovenous anastomosis. Microsurgery 2021;41(03):298–299
14 Riepl R, Greve J, Schild LR, et al. Application of a new computer-assisted robotic visualization system in cochlear implantation-Proof of concept. Int J Med Robot 2021;17(05):e2301
15 Schär M, Röösli C, Huber A. Preliminary experience and feasibility test using a novel 3D virtual-reality microscope for otologic surgical procedures. Acta Otolaryngol 2021;141(01):23–28
16 Gart MS, Souza JM, Dumanian GA. Targeted muscle reinnervation in the upper extremity amputee: a technical roadmap. J Hand Surg Am 2015;40(09):1877–1888
17 Rossi-Moussuti F, Timo E, Germann M. Barges-Coll J. Robotic-assisted minimally invasive transforaminal interbody fusion (TLIF) using a new hands-free 3D digital microscope with head-mounted-display (HMD): technical note. Intl J Clin Images Med Rev 2021;1(01):1004
18 Lakhiani C, Fisher SM, Janhofer DE, Song DH. Ergonomics in microsurgery. J Surg Oncol 2018;118(05):840–844
19 Khansa I, Khansa L, Westvik TS, Ahmad J, Lista F, Janis JE. Work-related musculoskeletal injuries in plastic surgeons in the United States, Canada, and Norway. Plast Reconstr Surg 2018;141(01): 165e–175e
20 Boehm F, Schuler PJ, Riepl R, Schild L, Hoffmann TK, Greve J. Performance of microvascular anastomosis with a new robotic visualization system: proof of concept. J Robot Surg 2022;16(03):705–713
21 Eckardt C, Paulo EB. Heads-up surgery for vitreoretinal procedures: an experimental and clinical study. Retina 2016;36(01): 137–147
22 Minoda R, Miwa T. Non-microscopic middle ear cholesteatoma surgery: a case report of a novel head-up approach. Otol Neurotol 2019;40(06):777–781
23 Troisi L, Pajardi GE. How SARS-CoV-2 has changed the activities in a regional hand surgery centre in Italy. J Hand Microsurg 2020;12 (02):132–132
24 Tan YPA, Liverneaux P, Wong JKF. Current limitations of surgical robotics in reconstructive plastic microsurgery. Front Surg 2018; 5:22
25 Hafez A, Haeren RHL, Dillmann J, Laakso A, Niemelä M, Lehecka M. Comparison of operating microscope and exoscope in a highly challenging experimental setting. World Neurosurg 2021;147: e468–e475
26 RoboticScope What if. Accessed August 3, 2023, at: https://www.bhs-technologies.com/wp-content/uploads/2021/12/BHS_Broschuere-A4-download.pdf