

# Cold snare polypectomy for duodenal adenomas in familial adenomatous polyposis: a prospective international cohort study




## Authors

Arthur S. Aelvoet<sup>1,2,3</sup>, John G. Karstensen<sup>4,5</sup>, Barbara A.J. Bastiaansen<sup>1,2,3</sup>, Monique E. van Leerdam<sup>6,7</sup>, Francesc Balaguer<sup>8</sup>, Michal Kaminski<sup>9</sup>, Roel Hompes<sup>10,2</sup>, Patrick M.M. Bossuyt<sup>11</sup>, Luigi Ricciardiello<sup>12,13</sup>, Andrew Latchford<sup>14,15</sup>, Rodrigo Jover<sup>16</sup>, Maria Daca-Alvarez<sup>8</sup>, Maria Pellisé<sup>8</sup>, Evelien Dekker<sup>1,2,3</sup>, European FAP Consortium

## Institutions

- 1 Department of Gastroenterology and Hepatology, Amsterdam UMC location University of Amsterdam, Amsterdam, the Netherlands
- 2 Cancer Center Amsterdam, Amsterdam, the Netherlands
- 3 Amsterdam Gastroenterology Endocrinology Metabolism, Amsterdam, the Netherlands
- 4 Gastrounit, Copenhagen University Hospital – Amager and Hvidovre, Danish Polyposis Registry, Hvidovre, Denmark
- 5 Department of Clinical Medicine, University of Copenhagen, Copenhagen, Denmark
- 6 Department of Gastrointestinal Oncology, Netherlands Cancer Institute, Amsterdam, the Netherlands
- 7 Department of Gastroenterology and Hepatology, Leiden University Medical Center, Leiden, the Netherlands
- 8 Department of Gastroenterology, Institut d'Investigacions Biomèdiques August Pi i Sunyer (IDIBAPS), Centro de Investigación Biomédica en Red de Enfermedades Hepáticas y Digestivas (CIBEREHD), University of Barcelona, Hospital Clínic de Barcelona, Barcelona, Spain
- 9 Department of Oncological Gastroenterology and Department of Cancer Prevention, Maria Skłodowska-Curie National Research Institute of Oncology, Warsaw, Poland
- 10 Department of Surgery, Amsterdam UMC location University of Amsterdam, Amsterdam, the Netherlands
- 11 Department of Epidemiology and Data Science, Amsterdam UMC location University of Amsterdam, Amsterdam, the Netherlands
- 12 Policlinico di Sant'Orsola, IRCCS Azienda Ospedaliero-Universitaria di Bologna, Bologna, Italy
- 13 Department of Medical and Surgical Sciences, University of Bologna, Bologna, Italy
- 14 Polyposis Registry, St Mark's Hospital, Harrow, United Kingdom
- 15 Department of Surgery and Cancer, Imperial College London, London, United Kingdom

- 16 Instituto de Investigación Biomédica ISABIAL, Universidad Miguel Hernández, Servicio de Medicina Digestiva, Hospital General Universitario de Alicante, Alicante, Spain

## Keywords

Familial adenomatous polyposis, Duodenal polyposis, Endoscopic resection

received 12.6.2023

accepted after revision 28.8.2023

accepted manuscript online 4.9.2023

## Bibliography

Endosc Int Open 2023; : –  
 DOI 10.1055/a-2165-7436  
 ISSN 2364-3722  
 © 2023. The Author(s).

The Author(s). This is an open access article published by Thieme under the terms of the Creative Commons Attribution License, permitting unrestricted use, distribution, and reproduction so long as the original work is properly cited. (<https://creativecommons.org/licenses/by/4.0/>)

Georg Thieme Verlag KG, Rüdigerstraße 14, 70469 Stuttgart, Germany

## Corresponding author

Prof. Evelien Dekker, Amsterdam UMC location University of Amsterdam, Department of Gastroenterology and Hepatology, Meibergdreef 9, 1105 AZ Amsterdam, the Netherlands  
 e.dekker@amsterdamumc.nl

## ABSTRACT

**Background and study aims** In patients with familial adenomatous polyposis (FAP), endoscopic resection of duodenal adenomas is commonly performed to prevent cancer and prevent or defer duodenal surgery. However, based on studies using different resection techniques, adverse events (AEs) of polypectomy in the duodenum can be significant. We hypothesized that cold snare polypectomy (CSP) is a safe technique for duodenal adenomas in FAP and evaluated its outcomes in our centers.

**Patients and methods** We performed a prospective international cohort study including FAP patients who underwent CSP for one or more superficial non-ampullary duodenal adenomas of any size between 2020 and 2022. At that time, this technique was common practice in our centers for superficial duodenal adenomas. The primary outcome was the occurrence of intraprocedural and post-procedural AEs.

**Results** In total, 133 CSPs were performed in 39 patients with FAP (1–18 per session). Median adenoma size was 10 mm (interquartile range 8–15 mm), ranging from 5 to 40 mm; 27 adenomas were  $\geq 20$  mm (20%). Of the 133 polypectomies, 109 (82%) were performed after submucosal in-

jection. Sixty-one adenomas (46%) were resected en bloc and 72 (54%) piecemeal. Macroscopic radical resection was achieved for 129 polypectomies (97%). Deep mural injury type II occurred in three polyps (2%) with no delayed perforation after prophylactic clipping. There were no clinically significant bleeds, perforations or other post-procedural AEs. Histopathology showed low-grade dysplasia in all 133 adenomas.

**Conclusions** CSP for (multiple) superficial non-ampullary duodenal adenomas in FAP seems feasible and safe. Long-term prospective research is needed to evaluate whether protocolized duodenal polypectomies prevent cancer and surgery.

## Introduction

Familial adenomatous polyposis (FAP) is an inherited disorder resulting in the development of numerous colorectal adenomas, requiring colectomy at a young age to prevent colorectal cancer [1]. Nearly all patients with FAP also develop adenomas in the duodenum. The life-time risk for duodenal cancer is 4% to 10% [2,3,4,5], and this cancer accounts for one of the most common FAP-related causes of death [6].

Conventionally, extensive duodenal polyposis is considered a criterion for prophylactic duodenectomy to prevent malignant transformation; however, treatment burden for duodenectomy is high with significant morbidity (Clavien-Dindo III/IV 16%–53%) and mortality (0%–2%) risks [7,8]. With the technical advance in endoscopic resection made over the last two decades, many centers with expertise in FAP have started to perform endoscopic polypectomy in the duodenum. In an attempt to either prevent duodenal cancer and prevent or defer the need for surgical duodenectomy, many centers with expertise in FAP have started to perform endoscopic polypectomies in the duodenum.

Several studies shown that endoscopic treatment of duodenal adenomas resulted in downstaging of duodenal polyposis graded by Spigelman stage [9,10,11]. And because the Spigelman stage is associated with duodenal cancer risk, performing polypectomies might indeed reduce this risk. In one study, 74% of patients were free from duodenal surgery at 89 months after polypectomy [9]. This potential advantage, however, should be weighed against the risk of complications of endoscopic treatment.

In the large bowel, current guidelines advice cold snare polypectomy (CSP) for non-pedunculated colorectal polyps < 10 mm and accumulating evidence suggests that CSP might also be effective and safe in 10- to 19-mm and even larger colorectal polyps [12]. Compared to cautery-based techniques, CSP is associated with a lower risk of delayed bleeding, perforation, and post-polypectomy syndrome and a shorter procedure time [13,14,15,16], which is favorable in a condition such as FAP in which multiple polyps often are removed in one session.

Compared to the colon, the complication risk of polypectomy in the duodenum is higher, presumably due to the thinner wall and increased vascularity. In two retrospective studies in FAP that included different resection techniques, the risk of perforation after endoscopic polypectomy in the duodenum was 2% to 3% and the risk of delayed bleeding 13% to 20% [9,10]. All delayed bleedings in Roos et al. occurred after polypectomy of large adenomas, all >20 mm. This considerable risk of adverse events (AEs) indicates a need for careful selection of lesions that can be safely resected, as well as a discussion about the preferred resection technique for duodenal adenomas in FAP. A few studies assessed the safety of CSP for duodenal adenomas. In a study including 10 patients with FAP, 332 CSPs were performed, mainly on polyps <10 mm (97%), and no (serious) AEs occurred, except for one intra-procedural bleed managed with hemoclips [17]. The same authors confirmed the safety of CSP in a recent update including 2413 CSPs [11]. In the sporadic setting, studies have shown that complications after duodenal CSP are rare (delayed bleeding 0%–4%, perforation 0%–4%), including comparative studies showing that these risks are higher after hot snare polypectomy (HSP) (delayed bleeding 8.7%–16.8%, perforation 1.4%–5.9%) [18,19,20,21,22]. A recently published European guideline, however, still recommends HSP for duodenal adenomas >5 mm [23].

We aimed to evaluate the safety of CSP for superficial non-ampullary duodenal adenomas in a consecutive series of patients with FAP in our expert centers.

## Patients and methods

### Study design and subjects

From 2020 on, centers that participate in the European FAP Consortium have collected findings of endoscopic surveillance of patients with FAP in a prospectively maintained database. One of the aims of this prospective database is to study the safety and efficacy of endoscopic resection techniques for duodenal adenomas. For this study, we evaluated all CSPs for non-ampullary duodenal adenomas performed between 2020 and 2022 during one or more sessions in patients with FAP. A diagnosis of FAP was defined as having a constitutional pathogenic

variant of the *APC* gene and/or having more than 100 colorectal adenomas and a family history of FAP.

The study was approved by the institutional review boards of all participating hospitals. All included patients gave informed consent prior to data collection. The study was registered at ClinicalTrials.gov (NCT04677998).

### CSP procedure

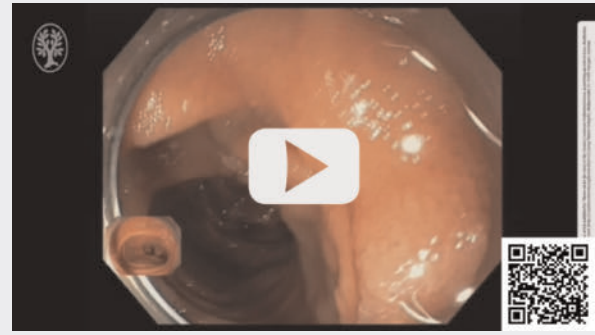In the centers of the European FAP Consortium, the aim of duodenal polypectomy, apart from cancer prevention, is to prevent endoscopically unmanageable disease in the future, thereby obviating the need for duodenal surgery. The indications for performing polypectomy of non-ampullary duodenal adenomas are: adenomas  $\geq 10$  mm and adenomas  $\geq 5$  mm when in total more than 20 duodenal adenomas are present. All superficial adenomas are resected using CSP, while more protruding lesions are resected using HSP. Duodenal polypectomies were performed under sedation (propofol or midazolam plus fentanyl) by endoscopists with expertise in FAP on dedicated endoscopy lists in tertiary referral centers. Patients on vitamin K antagonists or direct-acting anticoagulants temporarily discontinued these drugs. Single-agent antiplatelet use was continued or discontinued depending on local protocols. Gastroscopes, duodenoscopes or pediatric colonoscopes were used for the included procedures. CO<sub>2</sub> insufflation was used.

The procedure included assessment of the duodenum and stomach after which the adenomas with an indication for polypectomy were removed during one or multiple procedures, depending on the number and complexity of the lesions. The location, morphology, and size of the adenoma was assessed by the endoscopist prior to polypectomy, with or without narrow band imaging at the discretion of the endoscopists. Whether the submucosa was injected to lift the lesion, with or without adrenaline, was also left to the discretion of the endoscopist. Submucosal lifting and CSP was referred to as cold endoscopic mucosal resection (EMR) in some previous studies [20, 22]. Most lesions of 5 to 9 mm were resected en bloc with CSP and lesions  $\geq 10$  mm with piecemeal CSP. The post-polypectomy site was carefully inspected to rule out residual adenomatous tissue and to check for hemostasis and deep mural injury. Hemoclips were placed at the endoscopist's discretion. Post-procedural clinical admission for observation was not routinely planned for all patients, but left to the discretion of the treating endoscopist and local protocols. Standard prescription of prophylactic proton pump inhibitors was not advised, but left to the discretion of the treating endoscopist. No standard post-procedural dietary restrictions were advised. ► **Video 1** shows an en bloc CSP followed by a piecemeal CSP during the same session in a patient with extensive duodenal polyposis.

### Follow-up

Patients were evaluated 2 to 4 weeks after the procedure at the outpatient clinic or via a telephone consultation, to ensure that possible AEs were identified, discussed, and evaluated. Follow-up endoscopy was scheduled after 3 to 6 months when macroscopic resection was incomplete, high-grade dysplasia was

### ► VIDEO



► **Video 1** An en bloc CSP followed by a piecemeal CSP in the same session in a patient with extensive duodenal polyposis.

present in the resected adenoma and/or when there were other lesions in the duodenum and/or stomach that required intervention. Otherwise, follow-up endoscopy was scheduled after 1 year. During follow-up endoscopy, the polypectomy scar(s) were assessed to detect recurrences.

### Outcome

The primary outcome was the occurrence of procedure-related AEs occurring within 30 days after CSP. AEs were evaluated using the validated Adverse Events in GI Endoscopy classification [24]. Deep mural injury was scored according to the Sydney classification system [25].

### Statistical analysis

Descriptive statistics were used for this study. Continuous variables are presented as means with standard deviation for normally-distributed variables and as medians with interquartile ranges (IQRs) for skewed-distributed variables. Categorical variables are presented as numbers and percentages. All analyses were performed using SPSS 26 (IBM Corp. Released 2019. IBM SPSS Statistics for Windows, Version 26.0. Armonk, New York, United States: IBM Corp).

## Results

### Patient characteristics and included procedures

Thirty-nine consecutive FAP patients from three centers underwent CSP for a total of 133 superficial non-ampullary duodenal adenomas. During the same time period, 25 duodenal adenomas were resected with HSP. One patient underwent combined CSP and HSP of a large duodenal adenoma which, on histopathology, appeared to be an adenocarcinoma.

Patient characteristics are presented in ► **Table 1**. The median age at (first) CSP was 47. Of the 39 patients, 22 (56%) had undergone an endoscopic duodenal polypectomy before entering the study. The total number of CSPs per patient in the study period varied from one to 22 with a maximum of 18 CSPs per session. No patients were on anticoagulants at time of CSP.

**► Table 1** Patient characteristics.

	39 FAP patients
Female sex, n (%)	26 (67%)
Proven APC mutation, n (%)	38 (97%)
Age at FAP diagnosis (median)	22 (IQR 17–29)
History of (procto)colectomy	35 (90%)
History of duodenal polypectomy	22 (56%)
Age at (first) CSP (median)	47 (IQR 37–56)
Number of CSP sessions	
▪ One session	36 (92%)
▪ Two sessions	3 (8%)
Number of CSPs (median)	2 (IQR 1–4, range 1–22)
Anticoagulants use at time of CSP	0

FAP, familial adenomatous polyposis; IQR, interquartile range; CSP, cold snare polypectomy.

► **Table 2** summarizes the characteristics of the lesions and procedure outcomes. The median adenoma size was 10 mm (IQR 8–15). Fifty percent of the lesions were between 10 and 19 mm and 20% were ≥20 mm. Nearly all adenomas were located in D2 (69%) or D3 (26%) and had a flat elevated (IIa) (63%) or sessile (Is) (37%) appearance. Prior to CSP, most adenomas (82%) were submucosally lifted. Sixty-one lesions (46%) were resected en bloc and 72 (54%) piecemeal, resulting in a macroscopic radical resection rate of 97%. Most common difficulties during CSP were an unstable view (13%) and difficult location (5%). In 8% of lesions, hemoclips were prophylactically placed to prevent delayed bleeding or perforation.

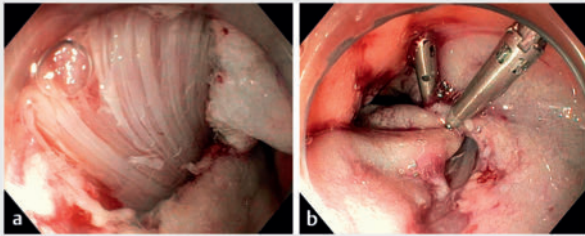
In terms of intraprocedural AEs, no bleeding or perforation occurred. Three CSPs (2%) in three different patients resulted in full exposure of the muscularis propria, classified as deep mural injury type II (n=3). All three cases of muscularis propria exposure occurred after submucosal lifting and piecemeal resection for adenomas measuring 25, 20, and 45 mm, with the use of a dedicated cold snare. In two lesions there was a suspicion of submucosal scarring, which might have been caused by previous biopsies. All three resection sites were prophylactically closed with hemoclips to prevent delayed perforation, which did not occur (► **Fig. 1**). All three patients were admitted for observation.

After eight of 42 polypectomy sessions (19%), the patients were admitted for one or two nights due to either the resection of large adenomas (n=3) or a high number of resected adenomas (n=5). These admissions were planned and, therefore, not counted as AEs. Also, in the three cases of deep mural injury, the admission was had been planned prior to the procedure because of the number or size of the lesion(s). No delayed complications were observed either during the admission period nor the 4-week follow-up. Histology showed a tubular adenoma in 90% of lesions and tubulovillous adenoma in 10%. All lesions

**► Table 2** Adenoma characteristics and procedure outcomes in patients with FAP.

	CSP (n = 133)
Size of adenoma (median, IQR)	
▪ 5–9 mm	40 (30%)
▪ 10–19 mm	66 (50%)
▪ 20–39 mm	24 (18%)
▪ 40 mm	3 (2%)
Location of adenoma	
▪ Bulb/D1	5 (4%)
▪ D2	92 (69%)
▪ D3	35 (26%)
▪ D4	1 (1%)
Morphology (Paris classification)	
▪ IIa	84 (63%)
▪ Is	49 (37%)
Submucosal injection to lift lesion	109 (82%)
Adrenalin in submucosal injection	93 (70%)
Adjuvant snare tip soft coagulation	2 (2%)
En bloc resection	61 (46%)
Piecemeal resection	72 (54%)
Macroscopic radical resection	129 (97%)
Difficulties during CSP	
▪ Difficult location	6 (5%)
▪ Incomplete lifting	2 (2%)
▪ Unstable frontal view	17 (13%)
▪ Side-viewing endoscope needed	4 (3%)
Adverse events	
▪ Intra-procedural bleeding	0
▪ Perforation	0
▪ Delayed bleeding	0
▪ Deep mural injury type II	3 (2%)
▪ Other adverse events	0
Prophylactic clip placement	10 (8%)
Histology	
▪ Tubular adenoma	120 (90%)
▪ Tubulovillous adenoma	13 (10%)
Grade of dysplasia	
▪ Low-grade dysplasia	133
▪ High-grade dysplasia	0

FAP, familial adenomatous polyposis; IQR, interquartile range; CSP, cold snare polypectomy.



► **Fig. 1** Deep mural injury type III with **a** damaged circular muscle layer, **b** prophylactically clipped.

contained low-grade dysplasia; no high-grade dysplasia or cancer was detected.

## Discussion

In this multicenter study, we investigated the safety of CSP for the removal of superficial non-ampullary duodenal adenomas in FAP. We demonstrated that, in experienced hands, CSP is a safe technique, regardless of the size or number of adenomas resected during the same procedure.

Our series confirms the safety of CSP for duodenal adenomas because no bleeding or perforation was observed. ► **Table 3** summarizes the available series on duodenal CSP in the sporadic and FAP setting showing the occurrence of intraprocedural bleeding (0%-90%), delayed bleeding (0%), and perforation (0%). These studies included CSPs with (cold EMR) and without submucosal lifting. Because the AE rate was low in all studies, we cannot state whether lifting results in fewer AEs. In the present study, most adenomas were lifted before CSP, and adenomas that were resected without lifting had a maximum size of 15 mm. We cannot draw any conclusions about larger lesions, but it might be hypothesized that performing CSP without lifting for larger adenomas might result in an increased risk of AEs.

The only AE that occurred was deep mural injury type II during three procedures. In two of these lesions, there was a suggestion of submucosal scarring, which might have been caused by previous biopsies and might increase the risk of AEs and non-radical resection. Numbers are too small to further study this in the present series. In our current endoscopic surveillance protocol, we do not advise taking routine biopsies to prevent submucosal scarring [26]. Another factor that might increase the AE risk is the morphology of the adenoma. Resecting more bulky adenomas might result in a higher risk of bleeding, which is the reason to perform HSP for these adenomas in our current practice.

Two studies retrospectively compared CSP to HSP, showing that AEs occurred less frequently after CSP [19, 20], with intraprocedural bleeding occurring in 10% to 13% after HSP, delayed bleeding in 9% to 17%, and perforation in 1% to 10%. However, because these studies were both retrospective and might suffer from selection bias, one should be careful about drawing conclusions. No detailed information on lesion morphology was provided, and superficial lesions may have been resected using CSP and the bulkier lesions with HSP. Moreover, CSP has recently been introduced as a resection technique in the duodenum. Trivedi et al. showed that HSP was used for all but one lesion in polypectomies between 2006 and 2012, whereas most lesions were resected using CSP between 2018 and 2021. This timing is relevant due to the evolution of hemostatic techniques, which were not available or widely used in the early years of duodenal polypectomy for FAP. Therefore, it is difficult to compare bleeding rates between the two techniques. Besides, the resection technique will be based on polyp morphology, introducing another bias. A randomized trial would eliminate most of these biases, but it is questionable whether a randomized trial is necessary or ethically justifiable, with such positive current data on CSP.

In terms of efficacy, evaluating adenoma recurrences after duodenal polypectomy might be of importance. In this study, we did not report on recurrences after CSP. FAP patients under-

► **Table 3** Series on duodenal cold snare polypectomy.

Author, year	Setting	Design	N of CSPs	Adenoma size*	Intraprocedural bleeding	Delayed bleeding	Perforation
Choksi 2015 [27]	Sporadic	Retrospective	15	24 mm	0	1 (7%)	0
Maruoka 2017 [21]	Sporadic	Prospective	30	4 mm	27 (90%) <sup>†</sup>	0	0
Hamada 2018 [17]	FAP	Prospective	332	NR	1 (3%)	0	0
Dang 2021 [18]	Sporadic	Retrospective	43	26.5 mm	0	0	0
Trivedi 2022 [19]	Sporadic	Retrospective	41	12 mm	4 (10%)	0	0
Repici 2022 [20]	Sporadic	Retrospective	33	31.5 mm	0	0	0
Wang 2023 [22]	Sporadic	Prospective	50	30 mm	1 (2%)	2 (4%)	2 (4%)
Present series	FAP	Prospective	133	10 mm	0	0	0

\*Mean or median

<sup>†</sup>Also bleedings that stopped spontaneously were counted as intraprocedural bleeding in this study  
CSP, cold snare polypectomy; FAP, familial adenomatous polyposis; NR, not reported.



going duodenal polypectomy usually have numerous adenomas and sometimes multiple adenomas are removed during the same procedure. We believe that this clinical setting does not lend itself to studying adenoma recurrence, because this is clinically less relevant, given that patients usually have multiple duodenal adenomas and should undergo regular surveillance endoscopies anyway. This is in contrast to the sporadic setting, in which usually one polyp is removed in an otherwise normal duodenum and surveillance might be terminated after complete removal. Two studies in the sporadic setting comparing CSP to HSP did not find a difference in recurrence rate [19, 20]. Polyp size was found to be a predictor of recurrence in univariate analysis [19]. Removing adenomas  $\geq 5$  mm rather than  $\geq 10$  mm as recommended by current guidelines might result in fewer recurrences and more en bloc resections. It could also prevent unmanageable duodenal disease with multiple large adenomas, which may require more complex polypectomies in the future. Takeuchi et al. [11] introduced a different endoscopic approach, called intensive downstaging polypectomy for duodenal polyposis in FAP, in which all large and small duodenal adenomas are resected, mostly using CSP. It resulted in downstaging of duodenal polyposis in most patients (71%). However, whether removing adenomas  $< 5$  mm results in a lower risk of developing duodenal cancer is debatable. This intensive strategy with frequent endoscopies including a high number of polypectomies results in a burden for the patients and potentially also an increased complication risk. Although future studies will have to guide the trade-off between safety and efficacy of CSP in terms of recurrence and feasibility, taking into account lesion size and morphology, we believe CSP is the preferred method for resecting (multiple) superficial duodenal adenomas in FAP. Whereas in the past data from retrospective studies were used for counseling, reporting on different resection techniques combined, we are now able to more accurately inform patients about risks before they undergo CSP.

## Conclusions

We demonstrated the safety of CSP in FAP patients, but not its efficacy in preventing cancer and surgery. Long-term prospective data from a large FAP cohort are needed to evaluate whether protocolized removal of duodenal adenomas is an effective strategy and, more specifically, which adenomas should be removed. As a European consortium, we hope to provide such data in future years.

## Conflict of Interest

• Arthur S. Aelvoet: none to declare. • John G. Karstensen: JGK consultancy for SNIPR BIOME, Boston Scientific, and AMBU and speakers fee from Norgine. • Barbara A.J. Bastiaansen: speakers' fee from Olympus, Tillotts Pharma AG and Ovesco Endoscopy AG. • Monique van Leerdam: review and editorial fee from Elsevier • Francesc Balaguer: FB has received an honorarium for consultancy from Sysmex, CPP Pharmaceuticals, and One-Two Therapeutics, speaker's fees from Norgine, and editorial fee from Elsevier. • Michal Kaminski: speaker's fee from Olympus, Fujifilm, Boston Scientific, Medtronic, AlfaSigma, IPSEN, consultancy fee from Olympus, ERBE, AlfaSigma. • Roel

Hompes: none to declare. • Patrick M.M. Bossuyt: none to declare. • Luigi Ricciardiello: consultancy and unrestricted research grant from SLA Pharma AG. • Andrew Latchford: none to declare. • Rodrigo Jover: consultancy for CPP Pharmaceuticals • Maria Daca-Alvarez: none to declare. • Maria Pellise: endoscopic equipment on loan of FujiFilm, research grant from FujiFilm, ZiuZ and Casen Recordati, consultancy for FujiFilm, Olympus and speakers' fee from Olympus, Medtronic and FujiFilm. • Evelien Dekker: endoscopic equipment on loan of FujiFilm and Olympus, research grant from FujiFilm, consultancy for FujiFilm, Olympus, Ambu and InterVenn, and speakers' fee from Olympus, GI Supply, Norgine, IPSEN, PAION and FujiFilm.

## Funding

KWF Kankerbestrijding 13676  
<http://dx.doi.org/10.13039/501100004622>

## Clinical trial

Trial registry: ClinicalTrials.gov (<http://www.clinicaltrials.gov/>)  
Registration number (trial ID): NCT04677998  
Type of Study: Prospective

## References

- [1] Bussey HJR. Familial polyposis coli: family studies, histopathology, differential diagnosis and results of treatment. Baltimore: John Hopkins University Press; 1975
- [2] Lepistö A, Kiviluoto T, Halttunen J et al. Surveillance and treatment of duodenal adenomatosis in familial adenomatous polyposis. *Endoscopy* 2009; 41: 504–509 doi:10.1055/s-0029-1214719
- [3] Björk J, Akerbrant H, Iselius L et al. Periampullary adenomas and adenocarcinomas in familial adenomatous polyposis: cumulative risks and APC gene mutations. *Gastroenterology* 2001; 121: 1127–1135 doi:10.1053/gast.2001.28707
- [4] Bülow S, Christensen IJ, Højen H et al. Duodenal surveillance improves the prognosis after duodenal cancer in familial adenomatous polyposis. *Colorectal Dis* 2012; 14: 947–952 doi:10.1111/j.1463-1318.2011.02844.x
- [5] Groves CJ, Saunders BP, Spigelman AD et al. Duodenal cancer in patients with familial adenomatous polyposis (FAP): results of a 10 year prospective study. *Gut* 2002; 50: 636–641
- [6] Ghorbanoghli Z, Bastiaansen BA, Langers AM et al. Extracolonic cancer risk in Dutch patients with APC (adenomatous polyposis coli)-associated polyposis. *J Med Genet* 2018; 55: 11–14
- [7] Walsh RM, Augustin T, Aleassa EM et al. Comparison of pancreas-sparing duodenectomy (PSD) and pancreatoduodenectomy (PD) for the management of duodenal polyposis syndromes. *Surgery* 2019; 166: 496–502 doi:10.1016/j.surg.2019.05.060
- [8] Aelvoet AS, Bastiaansen BA, Fockens P et al. Pancreas-preserving total duodenectomy for advanced duodenal polyposis in patients with familial adenomatous polyposis: short and long-term outcomes. *HPB (Oxford)* 2022; 24: 1642–1650
- [9] Roos VH, Bastiaansen BA, Kallenberg FGJ et al. Endoscopic management of duodenal adenomas in patients with familial adenomatous polyposis. *Gastrointest Endosc* 2021; 93: 457–466
- [10] Moussata D, Napoleon B, Lepilliez V et al. Endoscopic treatment of severe duodenal polyposis as an alternative to surgery for patients with familial adenomatous polyposis. *Gastrointest Endosc* 2014; 80: 817–825

- [11] Takeuchi Y, Hamada K, Nakahira H et al. Efficacy and safety of intensive endoscopic intervention for multiple duodenal adenomas in patients with familial adenomatous polyposis: A prospective cohort study. *Endoscopy* 2023; 55: 515–523
- [12] Ferlitsch M, Moss A, Hassan C et al. Colorectal polypectomy and endoscopic mucosal resection (EMR): European Society of Gastrointestinal Endoscopy (ESGE) Clinical Guideline. *Endoscopy* 2017; 49: 270–297 doi:10.1055/s-0043-102569
- [13] Horiuchi A, Nakayama Y, Kajiyama M et al. Removal of small colorectal polyps in anticoagulated patients: a prospective randomized comparison of cold snare and conventional polypectomy. *Gastrointest Endosc* 2014; 79: 417–423 doi:10.1016/j.gie.2013.08.040
- [14] Paspatis GA, Tribonias G, Konstantinidis K et al. A prospective randomized comparison of cold vs hot snare polypectomy in the occurrence of postpolypectomy bleeding in small colonic polyps. *Colorectal disease: the official journal of the Association of Coloproctology of Great Britain and Ireland* 2011; 13: E345–E348 doi:10.1111/j.1463-1318.2011.02696.x
- [15] Ichise Y, Horiuchi A, Nakayama Y et al. Prospective randomized comparison of cold snare polypectomy and conventional polypectomy for small colorectal polyps. *Digestion* 2011; 84: 78–81 doi:10.1159/000323959
- [16] Rex DK, Anderson JC, Pohl H et al. Cold versus hot snare resection with or without submucosal injection of 6- to 15-mm colorectal polyps: a randomized controlled trial. *Gastrointest Endosc* 2022; 96: 330–338 doi:10.1016/j.gie.2022.03.006
- [17] Hamada K, Takeuchi Y, Ishikawa H et al. Safety of cold snare polypectomy for duodenal adenomas in familial adenomatous polyposis: a prospective exploratory study. *Endoscopy* 2018; 50: 511–517 doi:10.1055/s-0043-124765
- [18] Dang DT, Suresh S, Vance RB et al. Outcomes of cold snare piecemeal EMR for nonampullary small-bowel adenomas larger than 1 cm: a retrospective study. *Gastrointest Endosc* 2022; 95: 1176–1182
- [19] Trivedi M, Klapheke R, Youssef F et al. Comparison of cold snare and hot snare polypectomy for the resection of sporadic nonampullary duodenal adenomas. *Gastrointest Endosc* 2022; 96: 657–664 doi:10.1016/j.gie.2022.05.007
- [20] Repici A, Capogreco A, Spadaccini M et al. Cold versus hot EMR for large duodenal adenomas. *Gut* 2022; 71: 1763–1765 doi:10.1136/gutjnl-2022-327171
- [21] Maruoka D, Matsumura T, Kasamatsu S et al. Cold polypectomy for duodenal adenomas: a prospective clinical trial. *Endoscopy* 2017; 49: 776–783 doi:10.1055/s-0043-107028
- [22] Wang H, Sidhu M, Gupta S et al. Cold snare EMR for the removal of large duodenal adenomas. *Gastrointest Endosc* 2023; 97: 1100–1108 doi:10.1016/j.gie.2023.01.040
- [23] Vanbiervliet G, Moss A, Arvanitakis M et al. Endoscopic management of superficial nonampullary duodenal tumors: European Society of Gastrointestinal Endoscopy (ESGE) Guideline. *Endoscopy* 2021; 53: 522–534 doi:10.1055/a-1442-2395
- [24] Nass KJ, Zwager LW, van der Vlugt M et al. Novel classification for adverse events in GI endoscopy: the AGREE classification. *Gastrointest Endosc* 2022; 95: 1078–1085 doi:10.1016/j.gie.2021.11.038
- [25] Burgess NG, Bassan MS, McLeod D et al. Deep mural injury and perforation after colonic endoscopic mucosal resection: a new classification and analysis of risk factors. *Gut* 2017; 66: 1779–1789 doi:10.1136/gutjnl-2015-309848
- [26] Aelvoet AS, Pellisé M, Bastiaansen BAJ et al. Personalized endoscopic surveillance and intervention protocols for patients with familial adenomatous polyposis: the European FAP Consortium strategy. *Endosc Int Open* 2023; 11: E386–E393
- [27] Choksi N, Elmunzer BJ, Stidham RW et al. Cold snare piecemeal resection of colonic and duodenal polyps  $\geq 1$  cm. *Endosc Int Open* 2015; 3: E508–E513