

Recurrent Venous Thromboembolism in Patients on Anticoagulation: An Update Based on the Revised AWMF S2k Guideline

Robert Klamroth¹ Hanno Riess² Jan Beyer-Westendorf³ Birgit Linnemann⁴

¹Department of Internal Medicine and Vascular Medicine, Vivantes Hospital in Friedrichshain, Berlin, Germany

²Department of Haematology, Oncology and Tumour Immunology, Charité – University Medicine Berlin, Berlin, Germany

³Department for Hematology, Medical Faculty, University Hospital Carl Gustav – Carus, Dresden, Germany

⁴Department for Cardiology III – Angiology, University Hospital of the Johannes – Gutenberg University, Mainz, Germany

Address for correspondence Priv. Doz. Dr. med. Robert Klamroth, MD, Klinik für Innere Medizin – Angiologie und Hämostaseologie, Zentrum für Gefäßmedizin, Hämophiliezentrum/ Gerinnungssprechstunde, Vivantes Klinikum im Friedrichshain, Landsberger Allee 49, 10249 Berlin, Germany (e-mail: robert.klamroth@vivantes.de).

Hamostaseologie 2024;44:150–154.

Abstract

In the recently updated German S2k Guideline “Diagnostics and Therapy of Venous Thrombosis and Pulmonary Embolism,” a new chapter was incorporated about recurrent venous thromboembolism (VTE) in patients on anticoagulation treatment. Despite the high efficacy of anticoagulation in most patients, approximately 2% experience a recurrent VTE event while receiving anticoagulant drugs. The proper diagnosis of the recurrent VTE is important and possible only with the knowledge of localization and thrombus burden of the primary VTE event. Possible reasons for recurrent VTE events in patients on anticoagulation are non-adherence to medication, sub-therapeutic drug levels due to resorption disorders or drug interactions, or concomitant disease with high thrombogenicity. Cancer is the most common underlying disease, but it is important to investigate and understand possible other causes whenever a breakthrough VTE event occurs. This results in the recommendation that in patients with VTE recurrence on therapeutic anticoagulation, in particular, the presence of malignant disease, antiphospholipid syndrome, and rare diseases like paroxysmal nocturnal hemoglobinuria or Behçet’s disease should be considered. For VTE recurrence during heparin therapy, heparin-induced thrombocytopenia type II needs to be ruled out, even if platelet counts are within the normal range. Although the mechanisms of recurrence on anticoagulation can be evaluated in a certain degree, clinical evidence for the management of recurrent VTE in anticoagulated patients is minimal and mainly based on expert opinion. Switching anticoagulant medication and intensifying anticoagulant treatment are possible options.

Keywords

- ▶ venous thromboembolism
- ▶ recurrent thrombosis
- ▶ anticoagulation

Background

Patients treated with anticoagulant therapy after venous thromboembolism (VTE) have an effectively reduced risk of thromboembolic complications such as recurrent VTE

events. The recently updated German S2k Guideline “Diagnostics and Therapy of Venous Thrombosis and Pulmonary Embolism”¹ offers guidance on how to diagnose and treat patients with recurrent VTE on anticoagulant therapy because despite the high efficacy of anticoagulation,

received

August 15, 2023

accepted after revision

September 7, 2023

© 2024. Thieme. All rights reserved.

Georg Thieme Verlag KG,

Rüdigerstraße 14,

70469 Stuttgart, Germany

DOI <https://doi.org/10.1055/a-2173-7729>.

ISSN 0720-9355.

approximately 2% of all patients on anticoagulation treatment experience a recurrent VTE event.²

The reasons for recurrence might be a low adherence to the prescribed antithrombotic regimen or anticoagulation is not able to interrupt the procoagulant effect properly. In any case, a diagnostic workup of possible causes is recommended because patients who develop recurrent thromboembolic events despite anticoagulation are at risk of further thromboembolic events which potentially can be fatal. The main causes for the so-called VTE breakthrough events include subtherapeutic drug levels and comorbidities. Concerning the underlying diseases, the main causes for recurrent VTE on anticoagulation are cancer and antiphospholipid syndrome, but several other conditions are possible and should be considered.³

Diagnostic Considerations

In case of suspected recurrent VTE, it is important to confirm the correct diagnosis of a new acute VTE. For this, a detailed description of the primary VTE event is necessary because in about half of the VTE patients, thrombotic or embolic residues are expected to be present 6 months or longer after the start of anticoagulation, which may cause problems to distinguish between residual clot burden from the index event and a new thromboembolic event.^{4,5} Consequently, a safe diagnosis of VTE recurrence can only be based on comparisons with imaging results of the index event and its follow-up examinations. The guideline recommends in the case of clinical suspicion of ipsilateral recurrent thrombosis the following: recurrence of thrombosis should be considered certain if thrombi are detected in venous vessel segments that were not affected by the initial thrombosis or for which complete recanalization has been documented before.¹

Data on the negative predictive value of a D-dimer level in the normal range to rule out recurrent VTE during anticoagulation are very limited. Still, the determination of D-dimer levels in patients with suspected recurrent VTE can be helpful because normal D-dimer levels are at least unlikely in patients with new clinically relevant recurrence of VTE.⁶ At the same time, the diagnosis of VTE recurrence should not be based on increased D-dimer values alone, since D-dimer testing lacks specificity for VTE. The significance of elevated D-dimer levels in patients on anticoagulation without a recurrent thrombotic event remains unclear.

Pathogenetic Considerations

In patients with recurrent VTE on anticoagulation, the regular intake of the anticoagulant in the correct dosage should be evaluated. The medical history and occasional coagulation checks or anticoagulant level determinations are helpful to check adherence to therapy. It may also be helpful to evaluate plausibility of prescription intervals. Adherence to the prescribed treatment is an important issue in anticoagulated patients.

The presence of possible relevant drug–drug interactions that may reduce anticoagulant drug levels or clinical efficacy

should also be considered. Any co-medication—prescription and nonprescription—should be evaluated thoroughly. For the individual substances—apixaban, dabigatran, edoxaban, and rivaroxaban—we refer to the respective product information or product monograph or the guidance tables for direct oral anticoagulants (DOACs) interactions in the European Heart Rhythm Association (EHRA) consensus document.⁷ The additive effects of polypharmacy, which exists in 40 to 80% of all older people, remain difficult to assess in individual cases.⁸ If there is reasonable doubt about efficacy or safety, drug levels (preferably trough levels) can be determined to verify that DOAC levels are within the expected range.⁹

In cases of VTE recurrence during heparin therapy, hereditary or acquired antithrombin deficiency and heparin-induced thrombocytopenia (HIT) should be ruled out.

In DOAC-treated patients, the possibility of poor enteric absorption should be considered, especially in patients with known disorders of the gastrointestinal tract such as gastric bypass surgery or short-bowel syndrome. In individual cases, lower plasma levels can also be detected when DOAC was taken independently of an accompanying meal.⁷ Inadequate enteral absorption can be detected by measuring the DOAC peak level approximately 2 to 3 hours after observed tablet intake.⁹

In patients with assumed adherence to the prescribed anticoagulation in the correct dosage, a further evaluation of comorbidities as a possible cause for recurrent VTE is necessary. There are several underlying diseases which cause activation of coagulation with high thrombogenicity despite anticoagulation. Most common is the presence of (hitherto unknown) malignant disease or antiphospholipid antibodies. VTE recurrence despite adequate anticoagulation has also been documented for previously undetected and therefore untreated paroxysmal nocturnal hemoglobinuria (PNH) or Behçet's disease.^{10,11} VTE recurrences in patients receiving anticoagulation can occur also in patients with vascular anomalies or venous compression. An overview of possible causes of recurrent VTE on anticoagulant therapy is given in [Fig. 1](#).

Management Strategies

Systematic studies on the management of patients with recurrent VTE under therapeutic anticoagulation are lacking. Recommendations mainly are based on expert opinion and consensus.¹⁰

Different therapeutic options are possible in individual cases. In the acute situation of a confirmed recurrent VTE, the management principles of VTE treatment apply as they do in the case of an initial VTE diagnosis. More details about the initial treatment of acute VTE are available in the publication by Linnemann et al.²³ and by Opitz et al.²⁴, in this issue. As a general rule, non-adherent patients and patients on an inadequate dosage of the prescribed anticoagulant medication should be treated like patients with a first VTE event, but a change of the previously used anticoagulant may not be needed, since treatment failure was not caused by a drug

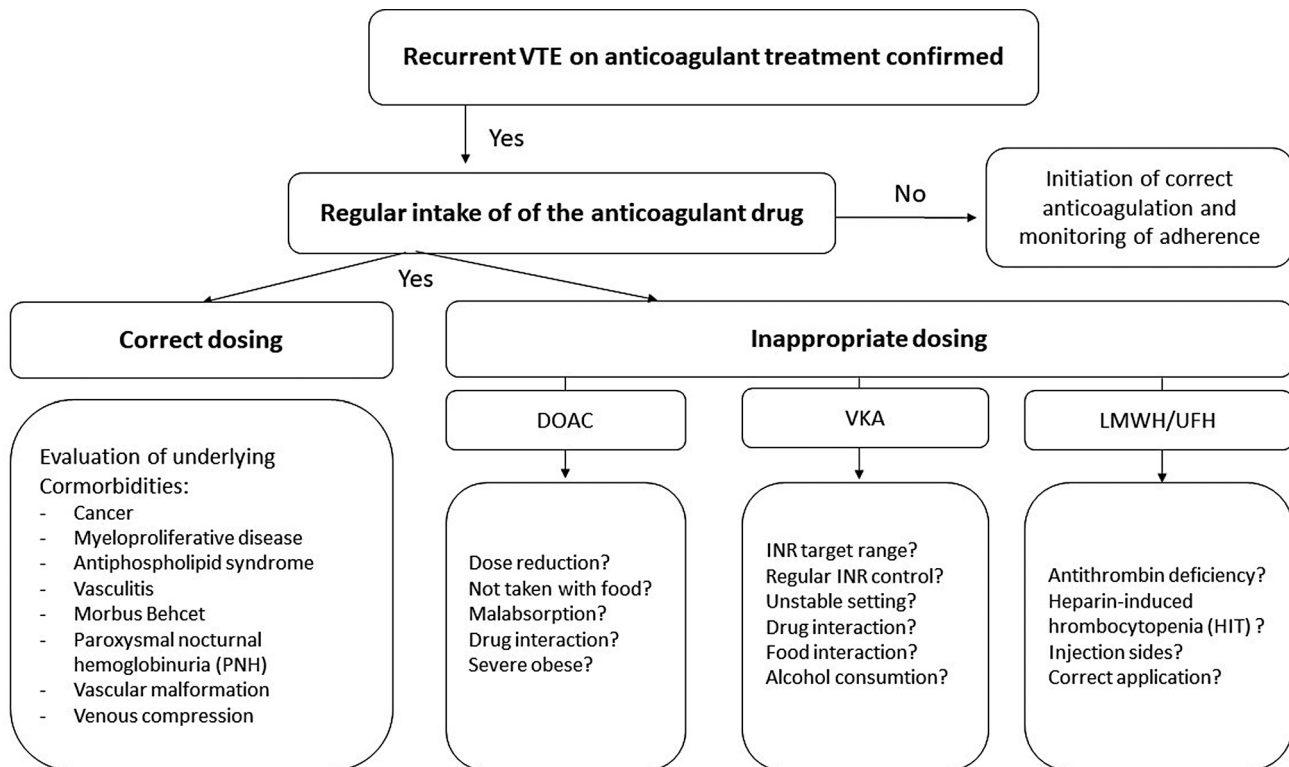


Fig. 1 Recurrent VTE in patients on anticoagulation and possible causes (modified after Linnemann et al.¹ and Schulman¹⁰). DOAC, direct oral anticoagulant; INR, international normalized ratio; LMWH, low-molecular-weight heparin; UFH, unfractionated heparin; VKA, vitamin K antagonist, VTE, venous thromboembolism.

failure itself. Intensified information and instructions may be helpful to increase adherence to the anticoagulation protocol.

In contrast to non-adherent or underdosed patients, patients with breakthrough thrombosis despite adequate anticoagulation may often require adjustment of treatment type or dosage. Although the specific cause for breakthrough thrombosis may be highly individual or may remain unexplained, certain general management strategies can be recommended.

Patients with cancer have VTE recurrences more frequently on anticoagulation than patients without cancer mainly due to an activated coagulation system.^{12,13} In a meta-analysis of VTE treatment with DOACs in patients with cancer, 5% had recurrent VTE within the first 6 months.¹⁴ The publication by Rézig et al. in this issue addresses the special aspects of anticoagulation in patients with malignant disease. In patients with recurrent VTE on anticoagulation, re-screening for occult or recurrent cancer is recommended.¹⁵

In patients with a confirmed VTE recurrence during vitamin K antagonists (VKAs) treatment, several options to modify the anticoagulation regimen are possible and suggested in **Table 1**. After ruling out insufficient dosage and non-compliance with the previous treatment (INR values in the target range? Regular INR controls?), a different anticoagulant (e.g., apixaban or rivaroxaban, alternatively low-molecular-weight heparin [LMWH] or fondaparinux) should be used for the initial treatment of acute VTE recurrence. After switching to another anticoagulant regimen, oral administration of vitamin K depending on the current INR value can be taken into account for a more rapid reversal of the

anticoagulant VKA effect to reduce the risk of bleeding complications from overlapping anticoagulant effect of different drugs.

In patients with a confirmed VTE recurrence during therapeutic anticoagulation with LMWH, a switch to oral treatment can be considered in case of irregular subcutaneous application. In patients with reliable application of LMWH, continuation of this treatment with a higher dose (dose increase of 20–25%) is recommended based on prospective case series and expert opinion.¹³

For patients with a confirmed VTE recurrence during therapeutic anticoagulation with the DOACs, apixaban, dabigatran, edoxaban, or rivaroxaban recommendations based on clinical evidence are not available, yet. After ruling out non-compliance, malabsorption and relevant drug–drug interactions treatment can be continued with an increased initial dose of apixaban or rivaroxaban or a switch to LMWH—possibly with an increased dose—is another option. In these patients, the monitoring of DOAC plasma level could be helpful to determine whether trough levels are within the expected range.⁹ There is no clinical evidence for a combination of different anticoagulant drugs.

In patients with VTE recurrence during the secondary-prophylaxis phase on low-dose apixaban (2×2.5 mg/d) or rivaroxaban (1×10 mg/d), the usual full-therapeutic dosages of the DOACs are recommended for initial therapy, maintenance therapy, and prolonged secondary prophylaxis. A correspondingly higher dosage of these drugs as well as a fully therapeutic dosage (apixaban 2×5 mg/d; rivaroxaban 1×20 mg/d) is then recommended for maintenance therapy

Table 1 Options for patients with confirmed VTE recurrence on anticoagulation

| Pretreatment | | Therapeutic options |
|-------------------------------------|--------------------------|---|
| No full therapeutic anticoagulation | VKA: INR < 1.5 | VKA with target INR 2.0–3.0 or switch to apixaban, dabigatran, edoxaban or rivaroxaban (DOAC) |
| | Apixaban: 2 × 2.5 mg/d | Apixaban 2 × 10 mg/d for 7 d followed by 2 × 5 mg/d or switch to an alternative DOAC |
| | Rivaroxaban: 1 × 10 mg/d | Rivaroxaban 2 × 15 mg/d for 21 d, followed by 1 × 20 mg/d or Switch to an alternative DOAC |
| Full therapeutic anticoagulation | LMWH | LMWH: 120–125% (DOAC) |
| | VKA: INR 2.0–3.0 | LMWH: 120–125%, DOAC (VKA with higher target INR: 2.5–3.5 or 3.0–4.0) |
| | DOAC | LMWH: 120–125% Switch to an alternative DOAC (VKA with target INR: 2.0–3.0 or higher) (DOAC in higher doses, e.g., apixaban: 2 × 10 mg/d, rivaroxaban: 2 × 15 mg/d) |
| Antiphospholipid syndrome | DOAC | VKA with target INR: 2.0–3.0 or 2.5–3.5 |
| | VKA: INR 2.0–3.0 | VKA with higher target INR (2.5–3.5 or 3.0–4.0) (if necessary, addition of ASA) |
| Cancer | VKA: INR 2.0–3.0 | LMWH or apixaban, edoxaban, rivaroxaban (DXI) |
| | LMWH | LMWH: 120–125% or DXI |
| | DOAC | LMWH: 120–125% (DXI at higher dosage: apixaban: 2 × 10 mg/d, rivaroxaban: 2 × 15 mg/d) |

Abbreviations: ASA, acetylsalicylic acid; DOAC, direct oral anticoagulant; DXI, direct anti-Xa inhibitor; INR, international normalized ratio; LMWH, low-molecular-weight heparin; VTE, venous thromboembolism; VKA, vitamin K antagonist.

Source: Modified from Linnemann et al.¹

and further secondary prophylaxis. In patients with VTE recurrence on anticoagulation, the use of a vena cava filter should be avoided as the first option. The updated guideline recommends that implantation of a vena cava filter should be reserved for individual cases with a high risk of pulmonary embolism and contraindications for anticoagulation or in which pulmonary embolism events occur despite adequate anticoagulation.¹

In general, patients with confirmed antiphospholipid syndrome (APS) have a higher risk of recurrent VTE in comparison to patients without antiphospholipid antibodies. Several randomized controlled trials compared DOACs with VKA therapy (target INR: 2.0–3.0).^{16–18} Patients with triple-positive APS (positive laboratory results for lupus anticoagulants, anti-cardiolipin antibodies and anti-β₂-glycoprotein I-antibodies) treated with DOACs for VTE have a higher risk of thromboembolic events compared with patients treated with VKA. Therefore, in patients with confirmed triple-positive APS, a switch to VKA treatment with a target INR of 2 to 3 is recommended. If these patients develop recurrent VTE on VKA therapy, intensification of the oral anticoagulation to a higher target INR (e.g., 3.0–4.0) or the additional administration of antiplatelet therapy (e.g., aspirin 100 mg/day) is recommended.^{19,20}

For APS patients who develop recurrent thrombotic events despite an increase in INR to 3.0 to 4.0, the additional administration of ASA 100 mg per day or a switch to high-dose LMWH with anti-Xa peak levels of 1.6 to 2.0 IU/mL with once-daily administration or 0.8 to 1.0 IU/mL with twice-daily administration can be discussed.²⁰ For cases with very

high antiphospholipid antibody titers, additional administration of hydroxychloroquine (2 × 200 mg/d) is an option,^{20,21} but potential side-effects need to be taken into account. In patients with secondary APS, the activity of the underlying disease should be determined and intensification of treatment considered if necessary.

Patients with chronic inflammatory disorders (e.g., Behçet's disease, chronic inflammatory bowel disease) also have an increased risk of VTE recurrence on anticoagulation. In this case, further diagnostics and therapy intensification should be considered, as successful treatment of the underlying disease usually also leads to a reduction in the risk of thrombosis.^{10,22}

Conclusion

Recurrent VTE in patients who are receiving anticoagulation is rare, and new symptoms should be evaluated properly with the knowledge of localization and thrombus burden of the first VTE event. Once a VTE recurrence is established, the recently updated German S2k Guideline “Diagnostics and Therapy of Venous Thrombosis and Pulmonary Embolism” recommends for patients with confirmed VTE recurrence during therapeutic anticoagulation to check adherence to therapy and whether they are treated with an adequate dosage, or whether there is a resorption disorder or a relevant drug interaction with possible weakening of anticoagulant effects. In patients with VTE recurrence on therapeutic anticoagulation, in particular the presence of malignant disease, antiphospholipid syndrome, and rare

diseases like paroxysmal nocturnal hemoglobinuria or Behçet's disease should be considered. The recommendations regarding continued management are usually weak because of the low-quality level of evidence. Depending on the individual patient's case, switching to a different anticoagulant medication and intensifying anticoagulant treatment are possible options.

Conflicts of Interest

R.K. received research grants from Bayer, CSL Behring, Leo Pharma, Octapharma and honoraria from Bayer, CSL Behring, Daiichi Sankyo, Leo Pharma, Novo Nordisk, Octapharma, Pfizer, Sanofi, Takeda, Viatriis.

H.R. received honoraria from Bayer, Bristol-Myers Squibb/Pfizer, Viatriis.

J.B.W. received research grants from Bayer, Daiichi Sankyo, LEO, Pfizer, Alexion, AstraZeneca and honoraria from Bayer, Daiichi Sankyo, LEO, Pfizer, Alexion, AstraZeneca, Norgine, Sanofi.

B.L. received honoraria from Bayer, Bristol-Myers Squibb, Daiichi Sankyo, LEO Pharma, Lumira DX, Pfizer, Sanofi, Viatriis.

References

- Linnemann B, Blank W, Doenst T, et al. Diagnostics and Therapy of Venous Thrombosis and Pulmonary Embolism. The revised AWMF S2k Guideline. *Vasa*. 2023 Oct; 52(S111): 1–146. PMID: 37904504. DOI: 10.1024/0301-1526/a001089
- van Es N, Coppens M, Schulman S, Middeldorp S, Büller HR. Direct oral anticoagulants compared with vitamin K antagonists for acute venous thromboembolism: evidence from phase 3 trials. *Blood* 2014;124(12):1968–1975
- van Es J, Cheung YW, van Es N, et al. Short-term prognosis of breakthrough venous thromboembolism in anticoagulated patients. *Thromb Res* 2020;187:125–130
- Nijkeuter M, Hovens MMC, Davidson BL, Huisman MV. Resolution of thromboemboli in patients with acute pulmonary embolism: a systematic review. *Chest* 2006;129(01):192–197
- Donadini MP, Ageno W, Antonucci E, et al. Prognostic significance of residual venous obstruction in patients with treated unprovoked deep vein thrombosis: a patient-level meta-analysis. *Thromb Haemost* 2014;111(01):172–179
- Ageno W, Squizzato A, Wells PS, Büller HR, Johnson G. The diagnosis of symptomatic recurrent pulmonary embolism and deep vein thrombosis: guidance from the SSC of the ISTH. *J Thromb Haemost* 2013;11(08):1597–1602
- Steffel J, Collins R, Antz M, et al. External Reviewers. 2021 European Heart Rhythm Association Practical Guide on the use of non-vitamin K antagonist oral anticoagulants in patients with atrial fibrillation. *Europace* 2021;23(10):1612–1676
- Wiggins BS, Dixon DL, Neyens RR, Page RL II, Gluckman TJ. Select drug-drug interactions with direct oral anticoagulants: JACC review topic of the week. *J Am Coll Cardiol* 2020;75(11):1341–1350
- Douxflis J, Adcock DM, Bates SM, et al. 2021 Update of the International Council for Standardization in Haematology Recommendations for laboratory measurement of direct oral anticoagulants. *Thromb Haemost* 2021;121(08):1008–1020
- Schulman S. How I treat recurrent venous thromboembolism in patients receiving anticoagulant therapy. *Blood* 2017;129(25):3285–3293
- Hillmen P, Muus P, Dührsen U, et al. Effect of the complement inhibitor eculizumab on thromboembolism in patients with paroxysmal nocturnal hemoglobinuria. *Blood* 2007;110(12):4123–4128
- Khorana AA, Noble S, Lee AYY, et al. Role of direct oral anticoagulants in the treatment of cancer-associated venous thromboembolism: guidance from the SSC of the ISTH. *J Thromb Haemost* 2018;16(09):1891–1894
- Carrier M, Prandoni P. Controversies in the management of cancer-associated thrombosis. *Expert Rev Hematol* 2017;10(01):15–22
- Li A, Garcia DA, Lyman GH, Carrier M. Direct oral anticoagulant (DOAC) versus low-molecular-weight heparin (LMWH) for treatment of cancer associated thrombosis (CAT): a systematic review and meta-analysis. *Thromb Res* 2019;173:158–163
- Rézig S, Mao RL, Couturand F, Lacut K, Delluc A. Incidence of cancer after a second unprovoked venous thromboembolic event. *Thromb Haemost* 2019;119(03):490–495
- Cohen H, Hunt BJ, Efthymiou M, et al. RAPS Trial Investigators. Rivaroxaban versus warfarin to treat patients with thrombotic antiphospholipid syndrome, with or without systemic lupus erythematosus (RAPS): a randomised, controlled, open-label, phase 2/3, non-inferiority trial. *Lancet Haematol* 2016;3(09):e426–e436
- Pengo V, Denas G, Zoppellaro G, et al. Rivaroxaban vs warfarin in high-risk patients with antiphospholipid syndrome. *Blood* 2018;132(13):1365–1371
- Ordi-Ros J, Sáez-Comet L, Pérez-Conesa M, et al. Rivaroxaban versus vitamin K antagonist in antiphospholipid syndrome: a randomized noninferiority trial. *Ann Intern Med* 2019;171(10):685–694
- Bauersachs R, Langer F, Kalka C, et al. Treatment of the antiphospholipid syndrome with direct oral anticoagulants. Position statement of German societies. *Vasa* 2019;48(06):483–486
- Arachchillage DRJ, Laffan M. What is the appropriate anticoagulation strategy for thrombotic antiphospholipid syndrome? *Br J Haematol* 2020;189(02):216–227
- Petri M. Use of hydroxychloroquine to prevent thrombosis in systemic lupus erythematosus and in antiphospholipid antibody-positive patients. *Curr Rheumatol Rep* 2011;13(01):77–80
- Rodger MA, Le Gal G, Anderson DR, et al. REVERSE II Study Investigators. Validating the HERDOO2 rule to guide treatment duration for women with unprovoked venous thrombosis: multinational prospective cohort management study. *BMJ* 2017;356:j1065
- Linnemann B, Beyer-Westendorf J, Espinola-Klein C, et al. Management of Lower-Extremity Deep Vein Thrombosis – An Update based on the revised AWMF S2k guideline. *Hamostaseologie* 2024;44:97–110
- Opitz CF, Meyer FJ. Pulmonary embolism – an update based on the revised AWMF-S2k guideline. *Hamostaseologie* 2024;44:111–118