

EUS-guided laser lithotripsy for pancreatic duct stones after failed conventional pancreatic endotherapy

OPEN
ACCESS

Authors

James Emmanuel¹, Deborah Chew Chia Hsin², Wan Zaharatul Ashikin Bt Wan Abdullah², Lee Tiong See²

Institutions

- 1 Gastroenterology and Hepatology, Queen Elizabeth Hospital, Kota Kinabalu, Malaysia
- 2 Gastroenterology and Hepatology, Hospital Selayang, Batu Caves, Malaysia

Key words

Stones, Pancreas, Intervention EUS

received 5.2.2023

accepted after revision 22.9.2023

accepted manuscript online 06.10.2023

Bibliography

Endosc Int Open 2024; 12: E135–E138

DOI 10.1055/a-2187-7263

ISSN 2364-3722

© 2024. The Author(s).

This is an open access article published by Thieme under the terms of the Creative Commons Attribution-NonDerivative-NonCommercial License, permitting copying and reproduction so long as the original work is given appropriate credit. Contents may not be used for commercial purposes, or adapted, remixed, transformed or built upon. (<https://creativecommons.org/licenses/by-nc-nd/4.0/>)

Georg Thieme Verlag KG, Rüdigerstraße 14,
70469 Stuttgart, Germany

Corresponding author

MBBS James Emmanuel, Queen Elizabeth Hospital,
Gastroenterology and Hepatology, Kota Kinabalu, Malaysia
sentulian83@gmail.com

ABSTRACT

The central dogma of pain in patients with chronic pancreatitis revolves around the pathophysiology of ductal hypertension owing to stones that obstruct the pancreatic duct. Conventional modalities available to decompress the pancreatic duct are occasionally limited by failed selective pancreatic duct cannulation during endoscopic retrograde cholangiopancreatography. We describe a novel endoscopic approach of EUS-guided laser lithotripsy to assist in pancreatic duct (PD) stone fragmentation in two symptomatic patients with underlying chronic pancreatitis who had failed PD cannulation and extracorporeal shock wave lithotripsy (ESWL). In both cases, a 365-micrometer Light-Trail TracTip Holmium laser fiber was advanced within a 19G endoscopic ultrasound aspiration needle (Expect Slimline (SL), Boston Scientific, Marlborough, Massachusetts, United States) under endoscopic ultrasound (EUS) guidance to fragment the PD stones. There were no procedure-related complications encountered and follow-up after 1 month of the procedure revealed significant reduction in abdominal pain scores. To the best of our knowledge, these are the first reported cases of EUS-guided laser lithotripsy performed for PD stones. Our approach of performing laser lithotripsy under EUS guidance obviates the need for an ESWL procedure; however, it is technically more challenging and requires precision to avoid injury to the pancreas. Further prospective studies are required to evaluate the safety and efficacy of this novel approach and its applicability as either a rescue procedure or in tandem with conventional pancreatic endotherapy modalities.

Introduction

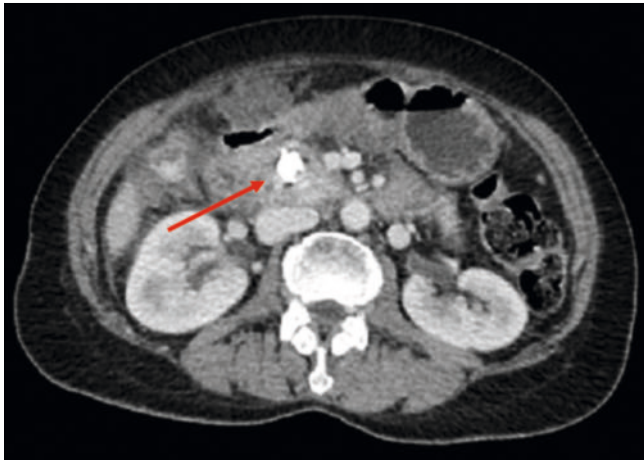The central dogma of pain in patients with chronic pancreatitis revolves around the pathophysiology of ductal hypertension owing to stones that obstruct the pancreatic duct (PD) [1]. The aim of endoscopic treatment is to decompress the PD through stent placement, stricture dilatation, stone fragmentation, and removal [2]. We describe a novel endoscopic approach of endoscopic ultrasound (EUS)-guided laser lithotripsy to assist in PD stone fragmentation in two patients with under-

lying chronic pancreatitis following failure of selective pancreatic duct cannulation.

Cases

Case 1: Pancreaticolithiasis at the head of the pancreas

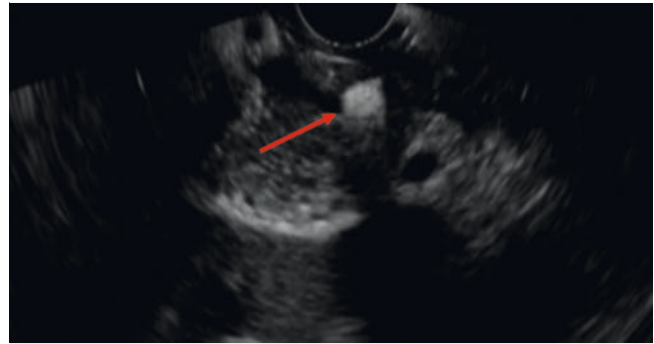
A 60-year-old woman with a past medical history of bronchial asthma presented with epigastric pain radiating to her back associated with vomiting for 1 day. On clinical examination, the patient was hemodynamically stable with tenderness over



► **Fig. 1** Pancreatic duct stone at the head of the pancreas on CT imaging.

the epigastric region. Biochemical parameters were notable for a deranged liver function test with total bilirubin, 2.3 mg/dL; aspartate aminotransferase (AST), 462 U/L; alanine aminotransferase (ALT), 241 U/L; and alkaline phosphatase (ALP), 136 U/L. Amylase levels were elevated at 686 U/L. Abdominal computed tomography (CT) revealed evidence of choledocholithiasis and pancreaticolithiasis at the head of the pancreas measuring 10 × 8 mm. (► **Fig. 1**).

We proceeded with an EUS which revealed a dilated main PD with the presence of a stone at the head of the pancreas. In addition, there was evidence of choledocholithiasis noted on the EUS imaging. Endoscopic retrograde cholangiopancreatography (ERCP) was performed followed by biliary stone clearance. The patient underwent a series of extracorporeal shock wave lithotripsy (ESWL) procedures to fragment the PD stones; however, repeated imaging revealed that the stone size had not regressed. Attempts to ramp up energy voltage during ESWL to enhance stone fragmentation resulted in the patient developing abdominal pain and, therefore, the procedure was aborted. Because the ESWL procedure was performed during the COVID-19 pandemic, and owing to the shortage of anesthetists for elective procedures, we were unable to utilize general anesthesia as a modality for pain management. In addition, failed PD cannulation during a follow-up ERCP limited other modalities of endotherapy. The echoendoscope was advanced into D1 of the duodenum and the main PD was localized. EUS-guided antegrade pancreatography performed from D1 using a 19G EUS aspiration needle (Expect Slimline (SL), Boston Scientific, Marlborough, Massachusetts, United States) excluded strictures and confirmed the presence of a filling defect at the level of the head of the pancreas. On EUS imaging, the pancreatic stone was then identified and we proceeded with EUS-guided laser lithotripsy.



► **Fig. 2** Pancreatic duct stone on EUS.

Case 2: Pancreaticolithiasis at the body of the pancreas

A 48-year-old man with a history of Type 2 diabetes mellitus and significant alcohol consumption presented with progressive abdominal pain for 6 months. Liver function test results were as follows, total bilirubin, 7.5 mg/dL; AST 60 U/L; ALT 109 U/L; and ALP 529 U/L. Ultrasound imaging revealed a dilated PD with the presence of a stone within. We proceeded with EUS, which confirmed pancreatic parenchymal calcifications with the presence of a stone measuring 8×8 mm at the level of the body of the pancreas (► **Fig. 2**). In addition, a distal common bile duct stricture resulting in proximal biliary dilatation was noted during the EUS examination. ERCP and stenting of the biliary system was performed. However, as in our first case, the patient developed pain during ESWL and a subsequent attempt at pancreatic endotherapy was not feasible due to failure in selective wire-guided cannulation of the PD. Hence, we decided to proceed with EUS-guided laser lithotripsy of the PD stone. The echoendoscope was advanced into the stomach and an EUS-guided antegrade pancreatography was performed at the level of the corpus of the stomach. The pancreatogram excluded a PD stricture and confirmed the presence of a filling defect at the level of the anastomosis body of the pancreas (► **Fig. 3**). On EUS imaging, the pancreatic stone was identified and we proceeded with EUS-guided laser lithotripsy (► **Fig. 4a**).

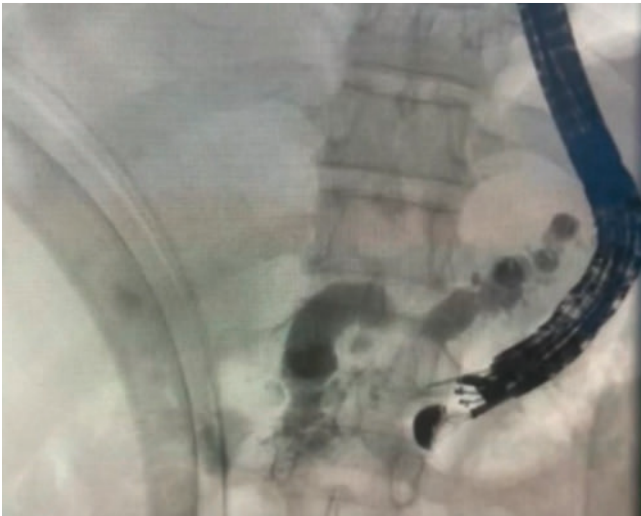Procedure description

Pre-procedure

After discussion with both patients, a reattempt at ERCP was not pursued following the failure of selective PD cannulation due to the relatively large size of the stone, which would have been difficult to extract without prior fragmentation.

Procedure

The procedure was performed with the patient in the supine position under conscious sedation using a combination of intravenous midazolam and pethidine. A Fujinon EG 580UT linear echoendoscope with a 3.8-mm working channel was used in both cases. Both patients were given rectal nonsteroidal anti-inflammatory drugs prior to the procedure.

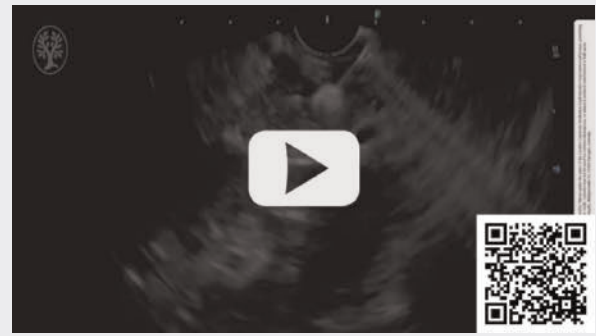

► **Fig. 3** EUS-guided pancreatogram.

EUS-guided holmium laser lithotripsy procedure

A 19G EUS aspiration needle (Expect Slimline (SL), Boston Scientific, Marlborough, Massachusetts, United States) was used to puncture the PD at an area with minimal intervening pancreatic parenchyma and in the same trajectory of the center of the visualized stone. In order to ensure correct targeting of the stone, it was essential to maintain scope stability and to avoid excessive torquing during the procedure. We performed EUS-guided pancreatography, which excluded the presence of a PD stricture. The position of the fine-needle biopsy needle was then approximated to displace the stone from the intervening PD wall to avoid injury due to the energy emitted by the laser fiber. We then advanced a 365-micrometer LightTrail TracTip Holmium laser fiber through the 19G needle under EUS guidance and using holmium laser technology (Auriga XL Ho:YAG; Lynton Surgical, Cheshire, UK). With energy levels of 4W and 800 mJ at a frequency of 5Hz, the PD stone was fragmented.

VIDEO

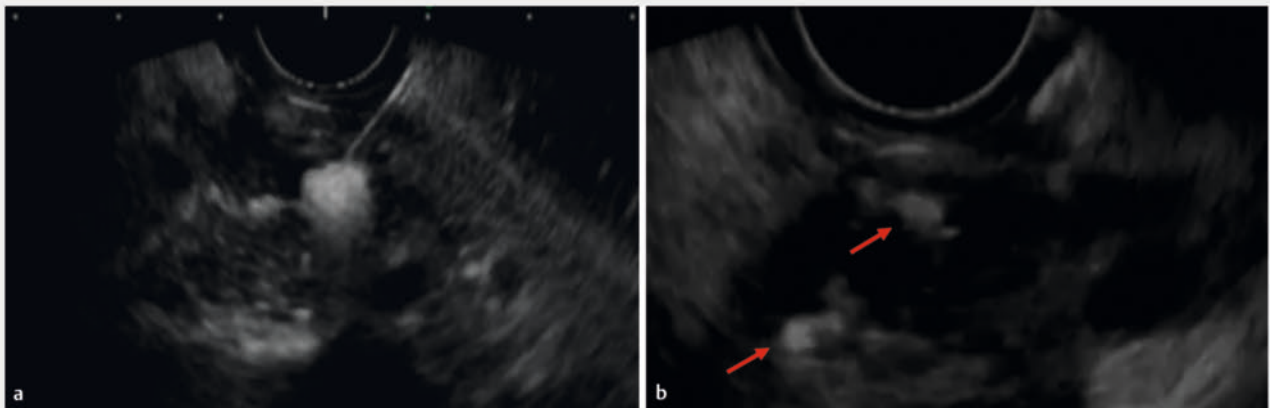


► **Video 1** Pancreatic duct stone fragmentation.

The tip of the needle was then redirected using the elevator and the stone was further fragmented using laser lithotripsy (► **Video 1**). Stone fragmentation was visualized during the EUS procedure and on fluoroscopy upon completion of the procedure (► **Fig. 4b**). Following the procedure, there was no evidence of contrast retention within the PD.

Post-procedure

Both patients tolerated the procedure well and there were no procedure-related complications. Hydration with Ringer's lactate was administered post-procedure. They were both discharged a day after the procedure. Follow-up 1 month after the procedure revealed significant reduction in abdominal pain scores in both patients. Repeat EUS and CT imaging following the procedure revealed no evidence of residual PD stones. A recent phone call follow-up has revealed that both patients have had no recurrence of abdominal pain.



► **Fig. 4** **a** EUS-guided laser lithotripsy. **b** Successful pancreatic duct stone fragmentation.

Discussion

Pancreaticolithiasis is a sequelae of chronic pancreatitis and results in ductal hypertension, which is the primary cause of pain in affected patients. The objective of endoscopic and surgical interventions is to expel the stones and reduce ductal hypertension, which in turn alleviates pain.

European Society of Gastrointestinal Endoscopy (ESGE) guidelines state that ESWL is recommended in clearance of radiopaque obstructive main PD (MPD) stones >5 mm located in the head/body of the pancreas and endoscopic retrograde cholangiopancreatography (ERCP) for MPD stones that are radiolucent or <5 mm [3]. Nevertheless, as illustrated in our cases, the application of ESWL was limited by patient pain threshold on voltage escalation.

Selective PD cannulation during ERCP can be challenging even in the hands of experienced endoscopists, as illustrated in both our cases that necessitated an alternative approach. The advent of EUS-guided pancreatic endotherapy has expanded the endoscopic armamentarium for patients with pancreaticolithiasis when retrograde access fails. In 2018, a novel approach that entailed performing an EUS-pancreaticogastrostomy (EUS-PG) followed by antegrade pancreatoscopy via PG and intraductal lithotripsy was described as an endoscopic alternative to relieve ductal obstruction in obstructing pancreaticolithiasis [4]. In this two-step procedure, stone fragmentation and expulsion were performed after a 2-month interval to allow for pancreaticogastrostomy tract maturation.

Our approach of performing laser lithotripsy under EUS guidance obviates the need for an ESWL procedure; however, it is technically more challenging. Because EUS only provides 2D imaging, the procedure requires precision and caution to avoid injury to the pancreas and neighboring structures. Both procedures carry a risk of pancreatitis; however, theoretically there is a higher risk of collateral injury to adjacent organs in patients undergoing ESWL due to the effect of the shock wave pulses on the tissues themselves or from cavitation-induced injury. Complications that have been reported with ESWL include perirenal hematoma, bowel perforation, splenic rupture, and lung trauma [5].

It is noteworthy that the success of EUS-guided laser lithotripsy is largely dependent on the size and number of PD stones. PD stones will ideally require fragmentation to fine particles to permit spontaneous expulsion. Higher stone burden may require repeated sessions to achieve clearance.

Conclusions

To the best of our knowledge, these are the first reported cases of EUS-guided laser lithotripsy performed for PD stones in patients with chronic pancreatitis. Further prospective studies are required to evaluate the safety and efficacy of this novel approach and its applicability as either a rescue procedure or in tandem with conventional pancreatic endotherapy modalities.

Conflict of Interest

The authors declare that they have no conflict of interest.

References

- [1] Prichard D, Byrne MF. Endoscopic ultrasound guided biliary and pancreatic duct interventions. *World J Gastrointest Endosc* 2014; 6: 513 doi:10.4253/wjge.v6.i11.513
- [2] Chapman CG, Waxman I, Siddiqui UD. Endoscopic ultrasound (EUS)-guided pancreatic duct drainage: the basics of when and how to perform EUS-guided pancreatic duct interventions. *Clin Endosc* 2016; 49: 161–167 doi:10.5946/ce.2016.011
- [3] Dumonceau JM, Delhaye M, Tringali A et al. Endoscopic treatment of chronic pancreatitis: European Society of Gastrointestinal Endoscopy (ESGE) guideline—updated August 2018. *Endoscopy* 2019; 51: 179–193
- [4] James TW, Baron TH. Antegrade pancreatoscopy via EUS-guided pancreaticogastrostomy allows removal of obstructive pancreatic duct stones. *Endosc Int Open* 2018; 6: E735–E738 doi:10.1055/a-0607-2484
- [5] Tandan M, Reddy DN. Extracorporeal shock wave lithotripsy for pancreatic and large common bile duct stones. *World J Gastrointest Endosc* 2011; 17: 4365 doi:10.3748/wjg.v17.i39.4365