



# Combined Application of a Novel Robotic System and Exoscope for Microsurgical Anastomoses: Preclinical Performance

Kai J. Wessel, MD, MSc<sup>1,2</sup> Isa Wendenburg<sup>1,2</sup> Shaghayegh Gorji, MD<sup>1,2</sup> Alexander Dermietzel, MD<sup>1,2,3</sup>  
Matthias M. Aitzetmueller, MD, PhD<sup>1,2,3</sup> Charalampos Varnava, MD<sup>1,2,3</sup> Philipp Wiebringhaus, MD, MHBA<sup>1,2,3</sup>  
Marie-Luise Klietz, MD<sup>1,2,3</sup> Tobias Hirsch, MD<sup>1,2,3</sup> Maximilian Kueckelhaus, MD, MBA<sup>1,2,3</sup>

<sup>1</sup>Department of Plastic and Reconstructive Surgery, Institute of Musculoskeletal Medicine, University Hospital Muenster, Muenster, Germany

<sup>2</sup>Department of Plastic, Reconstructive and Aesthetic Surgery, Hand Surgery, Fachklinik Hornheide eV, Muenster, Germany

<sup>3</sup>Division of Plastic Surgery, Department of Trauma, Hand and Reconstructive Surgery, University Hospital Muenster, Muenster, Germany

**Address for correspondence** Kai J. Wessel, MD, MSc, Department of Plastic and Reconstructive Surgery, Institute of Musculoskeletal Medicine, University Hospital Muenster, Muenster 48149, Germany (e-mail: kjwessel@muenster.de).

J Reconstr Microsurg Open 2023;8:e88–e96.

## Abstract

**Background** The concept of robotic microsurgery is becoming increasingly known as several robotic systems tailored to the specific needs of microsurgery are being introduced. Training with these devices is essential to draw conclusions about their potential clinical utility. This study describes the training and learning curve of experienced microsurgeons and complete novices using such a robotic surgical system in combination with an exoscope.

**Methods** Four experienced microsurgeons and three complete novices performed a total of 62 manual and robot-assisted anastomoses. The time for anastomosis completion and surgeon's satisfaction with the anastomosis and with the robotic system were recorded. The anastomoses' quality was assessed using the Structured Assessment of Microsurgery Skills (SAMS) and the Anastomosis Lapse Index (ALI). The Rapid Entire Body Assessment (REBA) was used for ergonomics evaluation.

**Results** All expert microsurgeons and novices improved their performance during training. The average anastomosis time decreased significantly, while satisfaction with the anastomosis and robotic system increased significantly over time. Multiple SAMS score parameters increased significantly throughout robotic but not manual training and the ALI score demonstrated more errors in the manual group. The REBA score displayed a significantly lower risk for musculoskeletal disorders in the robotic group.

**Conclusion** Currently, the first clinical applications of robotic surgical systems specifically designed for microsurgery are being reported. The introduction of such systems into clinical practice can be expected to have a steep learning curve, as demonstrated in our study. Meanwhile, robotic systems for microsurgical procedures may hold great potential for improvement of surgical quality and ergonomics.

## Keywords

- ▶ robotics
- ▶ microsurgery
- ▶ anastomosis
- ▶ learning curve
- ▶ ergonomics

received  
March 26, 2023  
accepted after revision  
July 31, 2023  
accepted manuscript online  
October 26, 2023

DOI <https://doi.org/10.1055/a-2199-2584>.  
ISSN 2377-0813.

© 2023. The Author(s).

This is an open access article published by Thieme under the terms of the Creative Commons Attribution-NonDerivative-NonCommercial-License, permitting copying and reproduction so long as the original work is given appropriate credit. Contents may not be used for commercial purposes, or adapted, remixed, transformed or built upon. (<https://creativecommons.org/licenses/by-nc-nd/4.0/>)

Thieme Medical Publishers, Inc., 333 Seventh Avenue, 18th Floor, New York, NY 10001, USA

Robot-assisted surgery has evolved over the past decades and has become part of routine clinical practice in many disciplines. In plastic surgery, its application has been attempted to decrease donor site morbidity through less invasive latissimus dorsi and deep inferior epigastric perforator flap harvest using da Vinci multiport and single-port systems.<sup>1-4</sup> Several groups are performing robotic-assisted mastectomies with immediate implant-based reconstruction<sup>5-8</sup> or with immediate manual microsurgical reconstruction.<sup>9,10</sup> Currently, robotic assistance is also gaining momentum in the field of microsurgery as several robotic systems tailored for microsurgery are being certified for clinical use in Europe and first clinical outcomes are being reported.<sup>11,12</sup> The main features of such systems for improvement of microsurgical performance are motion scaling and tremor elimination, while being configured for open microsurgery. The only currently commercially available system, the Symani by MMI (Pisa, Italy), additionally offers wristed microsurgical and supermicrosurgical instruments, adding distal motion axes for an improved range of motion compared with conventional microsurgical instruments. As this system is operated by a telemetric control, the combination with an exoscope or robotic microscope potentially offers improved ergonomics for the microsurgeon.<sup>13</sup> Training with devices for robotic assistance is essential to draw conclusions about their potential clinical utility in microsurgical applications. Therefore, this study describes the training of experienced microsurgeons and complete novices in microsurgery and their respective learning curves using such a combination of a robotic microsurgical system with an exoscope.

## Methods

### Setup

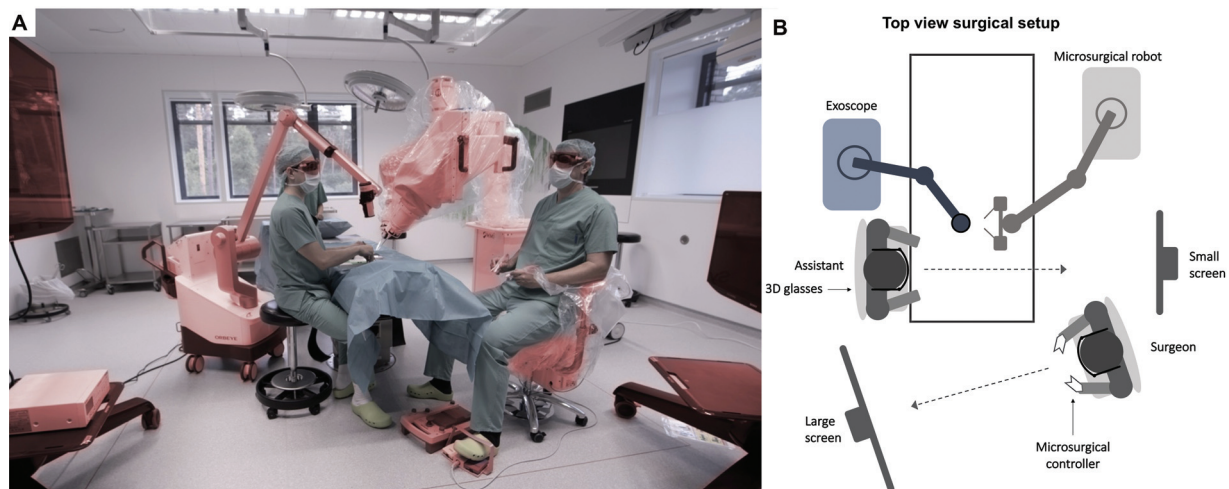
Microsurgical training was performed at the microsurgery laboratory of our clinic. The Symani system (MMI) was used

to perform robot-assisted microsurgical anastomoses. The Symani system offers wristed microsurgical and supermicrosurgical instruments, motion scaling between 7× and 20×, tremor filtration, and an increased range of motion through additional distal motion axes. The surgeon is seated on a highly ergonomic chair and operates the system via forceps-like wired controllers in his/her hands that can be moved and rotated freely in an ergonomic position. All movements are transferred to two robotic slave arms with high precision and in real time. The operating unit can be flexibly positioned above the desired operating field.

In this study, the use of the Symani was combined with an ORBEYE exoscope (Olympus, Tokyo, Japan) to ultimately benefit from the ergonomic advantages of both systems. The slim robotic camera arm can be located precisely in the desired position and the images are depicted on two light-emitting diode screens in 4K-three-dimensional (3D) quality. 3D glasses were supplied to the operating team and the procedures were recorded in 4K-3D quality for further video analyses. During the performance of microsurgical procedures, the Symani operating unit and the ORBEYE camera were positioned right next to the operating table, leaving enough space for an assistant surgeon and surgical nurse, if required. When combining the two systems, the operating surgeon was discharged from the operating table and seated in a comfortable position (see ►Fig. 1A,B, showing the setup in the operating room). Manual anastomoses were performed using conventional microsurgical instruments (S&T, Switzerland) and the ORBEYE exoscope.

### Study Population

Four experienced microsurgeons with extensive experience in free flap reconstruction and three complete novices (medical students), which never had performed an anastomosis prior to this study, participated in the robotic and manual microsurgical training. To be included in this study,



**Fig. 1** Illustration of the surgical setup. (A) Photograph of the operating room showing the positioning of two surgeons, the microsurgeon robot, and the exoscope (red). The main surgeon is seated ergonomically and discharged from the operating table. The microsurgeon robot is operated via hand-held controllers and a foot pedal. An assistant surgeon is seated at the surgical site operating manually. Both surgeons are wearing three-dimensional (3D) glasses enabling 4K-3D vision of the operating area on a large and small screen, recorded by the exoscope. (B) Schematic top view of the surgical setup.

novices had to attest that no previous microsurgical training was performed, ensuring equal preconditions for robot-assisted and manual procedures. Participants received a systematic introduction into the use of the utilized robotic systems and medical students were additionally introduced into the basic principles of microsurgical suturing techniques and anastomoses. Each experienced microsurgeon performed 5 robot-assisted microvascular end-to-end anastomoses on 2.0-mm diameter silicone vessels (WetLab, Japan) with 8 stitches of 8–0 sutures (BEAR Medic Corporation, Japan), followed by 3 end-to-end anastomoses on 1.0-mm diameter silicone vessels (WetLab) with 6 stitches of 10–0 sutures (BEAR Medic Corporation). Each novice alternately performed 5 manual and 5 robot-assisted anastomoses on 2.0-mm diameter silicone vessels with 8 stitches of 9–0 sutures (BEAR Medic Corporation). Silicone vessels were stabilized with a microvascular clamp on a foam platform. Exoscope magnification and Symani motion scaling factor were up to the participants' choice.

### Data Collection and Processing

During each microvascular anastomosis, the time to complete the anastomosis was recorded. After finishing each anastomosis, participants had to fill out a questionnaire evaluating their subjective satisfaction with the anastomosis and satisfaction with the Symani system performance on a numeric rating scale from 1 to 10 (10 representing the best rating). Experienced microsurgeons further evaluated the performance of the ORBEYE exoscope compared with a conventional microscope after their first and fifth procedure using a modified questionnaire of Will et al.<sup>14</sup> regarding the following aspects: team interaction and communication, freedom of movement, back and neck tenderness, intra-operative tremor, muscle fatigue, optical detail, microsurgical handling, depth and 3D structure visualization, operative comfort, and overall satisfaction (1 = significantly worse, 2 = worse, 3 = equal, 4 = better, 5 = significantly better).

To analyze microsurgical skills, the last anastomosis performed on 2.0 and 1.0 mm vessels by experienced microsurgeons and the first and last anastomosis performed on 2.0 mm vessels by novices was videorecorded. Deidentified and blinded videos were evaluated by an experienced microsurgeon according to a modified version of the Structured Assessment of Microsurgery Skills (SAMS) by van Mulken et al.<sup>15,16</sup> The modified SAMS evaluates dexterity (steadiness, instrument handling, tissue handling), visuospatial ability (suture placement, knot technique), and operative flow (steps, motion, speed) on a numeric rating scale from 1 to 5 (5 representing excellent skills). Additionally, a mean score, overall performance, and indicative skill were determined.

To further evaluate the quality of microvascular anastomoses, the Anastomosis Lapse Index (ALI) was applied. The last manual and robot-assisted anastomosis performed by novices was cut longitudinally and photographed from the inside. Deidentified and blinded photographs were analyzed by a reviewer to identify the total number and specific types of errors, that were previously described by Ghanem et al (anastomosis line disruption, backwall or sidewall catch,

oblique stitch causing distortion, bite leading to tissue infoldment, partial thickness stitch, unequal distancing of sutures, visible tear in vessel wall, strangulation of tissue edges, thread in lumen, large edge overlap).<sup>17</sup>

Posture analysis was performed using the Rapid Entire Body Assessment (REBA) approach.<sup>18</sup> Novices were photographed from the side when performing their last manual and robot-assisted anastomosis, followed by standardized analysis of neck, trunk, leg, upper arm, lower arm, and wrist position and calculation of the total REBA score, also taking the load, coupling score, and activity score into consideration.

### Statistical Analysis

Statistical analysis was performed using GraphPad Prism software version 6.0 (GraphPad Software Inc., USA). In all plots and bar charts, dots represent individual values with arithmetic mean and standard deviation or standard error of the mean as indicated. Statistical significance was assessed for anastomosis time, subjective satisfaction, SAMS scores, ALI scores, and REBA scores using a two-way analysis of variance test (repeated measures with matched values, corrected for multiple comparisons with Tukey and Sidak test, 95% confidence interval). *p*-Values of less than 0.05 were considered statistically significant.

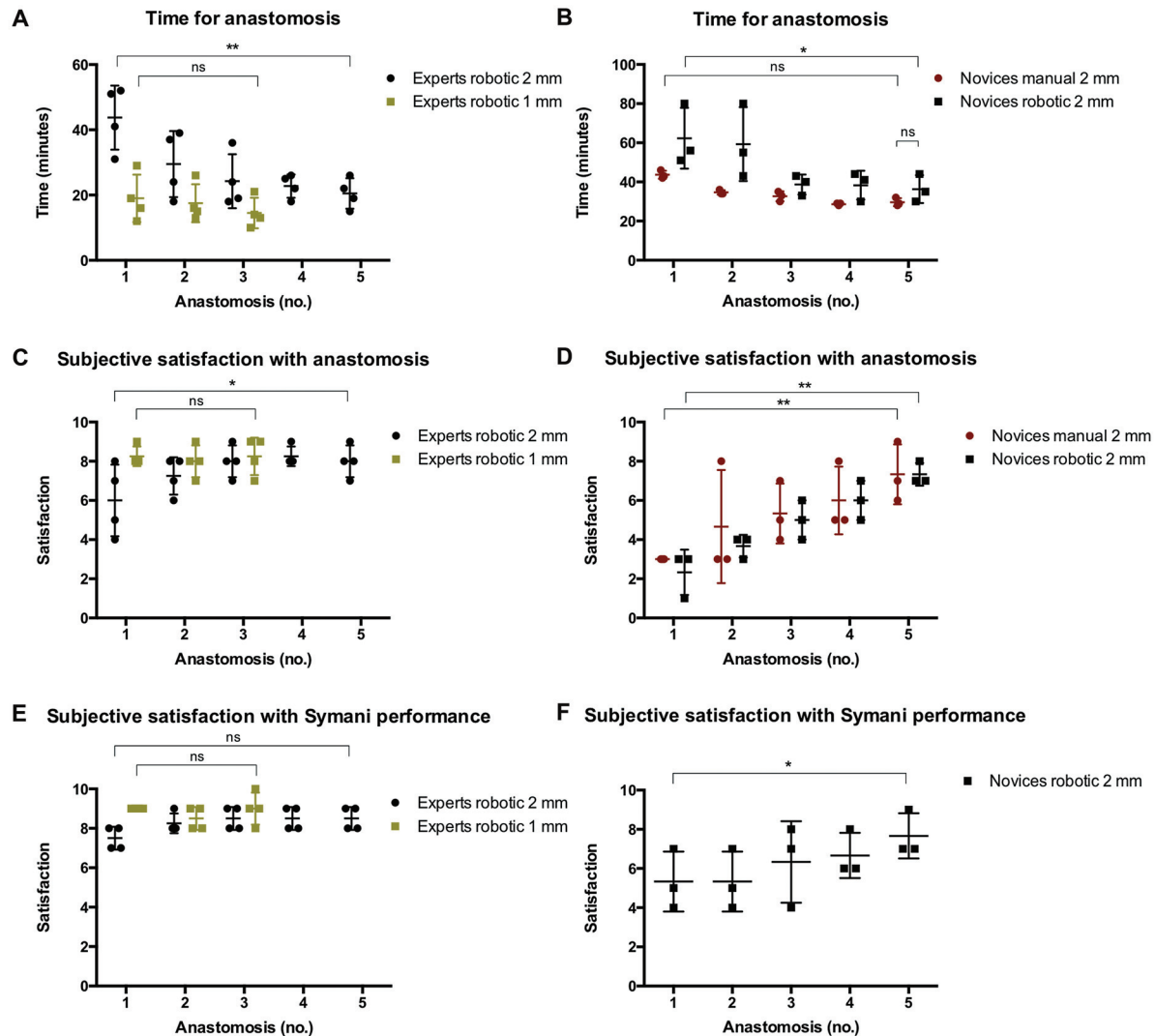
## Results

### Assessment of Surgical Time and Subjective Satisfaction

Experienced microsurgeons performed five 2-mm diameter anastomoses followed by three 1-mm diameter anastomoses on artificial vessels with the microsurgical robot. Novices alternately performed five manual and five robot-assisted 2-mm diameter anastomoses on artificial vessels. The surgical time needed to complete each anastomosis was tracked and participants evaluated their satisfaction with each anastomosis and the Symani system performance on a scale from 1 (minimum) to 10 (maximum).

The mean time for robot-assisted anastomoses of experts significantly decreased from 44 to 20.5 minutes on 2-mm diameter vessels and from 19 to 14.5 minutes on 1-mm diameter vessels (►Fig. 2A). Novices also showed a significant decrease in mean surgical time from 62 to 36 minutes when performing robot-assisted anastomoses and a decrease from 44 to 30 minutes when performing manual anastomoses (►Fig. 2B). Furthermore, there was no significant difference between mean anastomosis time of the final robot-assisted and manual anastomosis performed by novices.

Consistent with a significant reduction of the anastomosis time, experts' mean subjective satisfaction with the anastomosis significantly increased from 6 to 8 points on 2-mm vessels and was constantly at a high level of 8 points on 1-mm vessels (►Fig. 2C). Novices' mean satisfaction with the anastomosis increased even more from 2 to 7 points when using the microsurgical robot and from 3 to 7 points when performing manual anastomoses, both being significant (►Fig. 2D). Experts' mean satisfaction with the Symani performance was constantly at a high level between 8 and



**Fig. 2** Time for anastomosis and subjective outcome measures. Experienced microsurgeons ( $n = 4$ ) performed five 2-mm diameter and subsequently three 1-mm diameter robot-assisted anastomoses on artificial vessels. Novices ( $n = 3$ ) alternately performed five manual and five robot-assisted anastomoses on artificial 2-mm diameter vessels. (A) Scatter plot depicts the time in minutes experts and (B) novices needed to complete each anastomosis. (C) After each anastomosis experts and (D) novices evaluated their subjective satisfaction with the anastomosis on a scale from 1 (minimum) to 10 (maximum). (E) The subjective satisfaction with the Symani performance was evaluated by experts and (F) novices likewise. Dots represent individual values with mean and standard deviation (ns, statistically not significant; \* $p < 0.05$ ; \*\* $p < 0.01$ ).

9 points on 2- and 1-mm vessels (►Fig. 2E) and novices' mean satisfaction with the Symani performance significantly increased from 5 to 8 points (►Fig. 2F). Overall, the data show a significant improvement of surgical time and satisfaction with the outcome upon robotic and manual microsurgical training. Even though manual anastomoses were performed faster than robotic anastomoses in the beginning by novices, the steep learning curve of robot-assisted anastomoses led to comparable results at the end of the training.

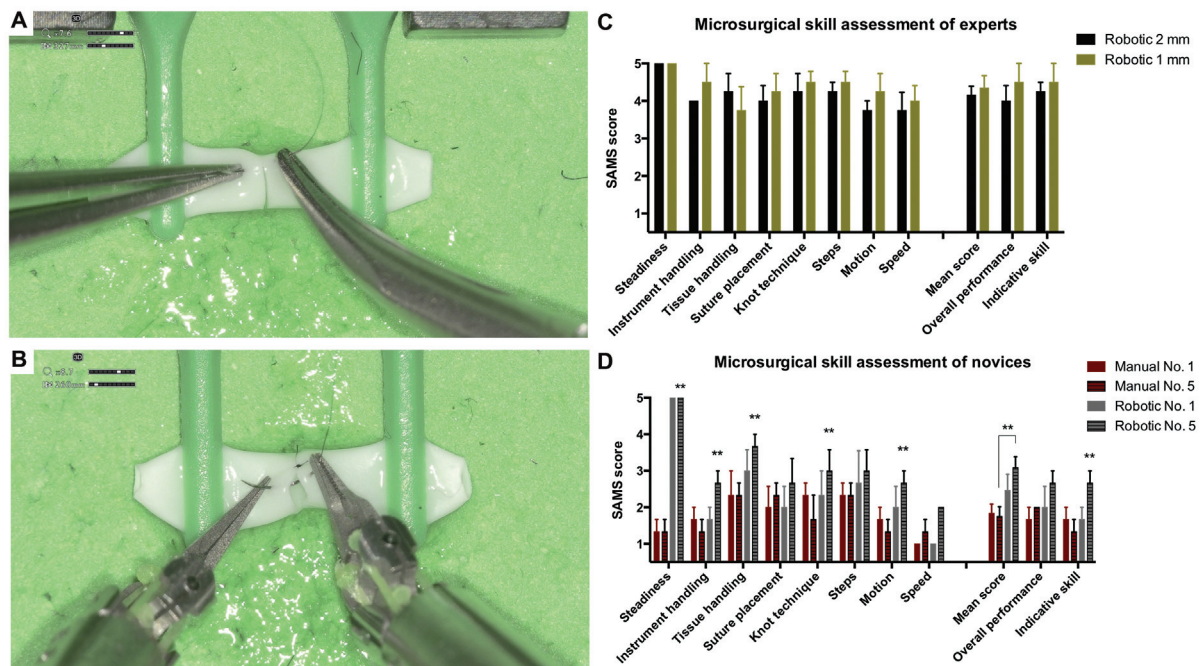
### Microsurgical Skills and Anastomosis Quality

To objectively analyze the acquisition of microsurgical skills, the final robot-assisted anastomosis of experts on 2- and 1-mm vessels and the first and fifth manual and robot-assisted anastomosis of novices on 2-mm vessels were videorecorded (►Fig. 3A,B). An experienced microsurgeon

evaluated the performance in a blinded fashion according to a modified version of the SAMS.<sup>15</sup>

Experienced microsurgeons demonstrated proficient skills on 2- and 1-mm vessels with mean SAMS evaluations ranging from 3.75 (motion) to 5 (steadiness) depending on the respective category (►Fig. 3C). Remarkably, no significant differences were detectable when comparing the performance on 2- and 1-mm vessels. However, apart from "tissue handling," the mean SAMS evaluation of each category even appeared to be slightly higher on smaller vessels. Novices consistently showed lower SAMS scores than experts when performing manual and robot-assisted anastomoses. Nevertheless, they clearly improved their skills throughout the training (►Fig. 3D). While the SAMS scores of manual anastomoses only increased slightly, a strong increase was detectable comparing the first and fifth robot-assisted

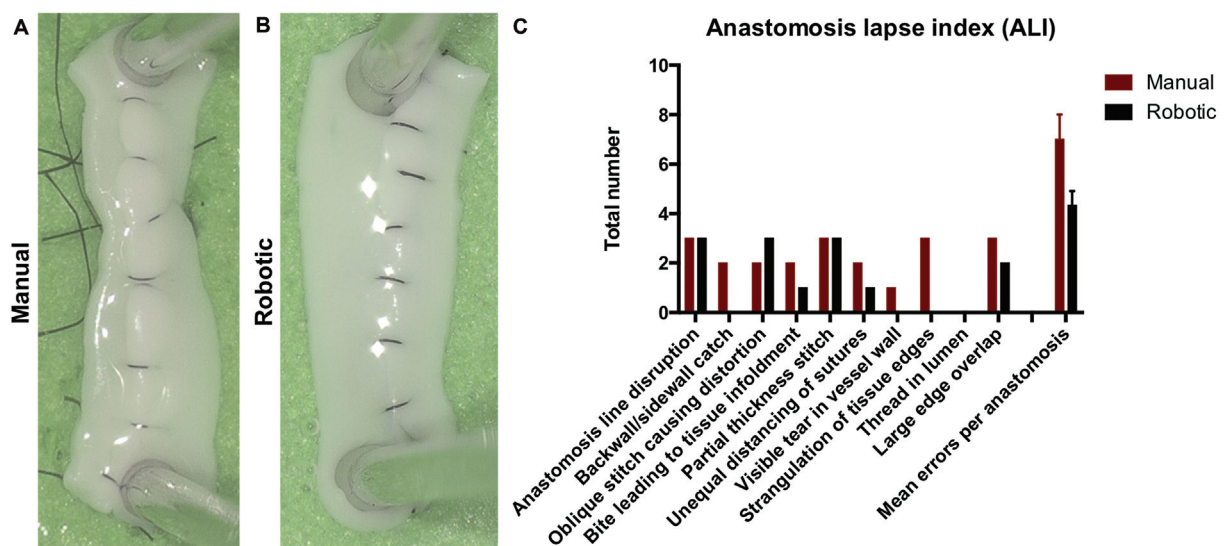




**Fig. 3** Structured Assessment of Microsurgery Skills (SAMS). The performance of microsurgical anastomoses was videorecorded, and microsurgical skills were evaluated in a blinded fashion by an experienced microsurgeon according to a modified version of the SAMS score. Representative images of a manual (A) and robot-assisted (B) procedure are depicted. (C) The SAMS score was evaluated for the final robot-assisted anastomosis performed by experts on 2- and 1-mm diameter vessels ( $n = 4$ ). (D) SAMS scores for novices were assessed upon performance of the first and fifth manual and robot-assisted anastomosis, to analyze the learning process ( $n = 3$ ). Bar charts represent mean scores with standard error of the mean (s.e.m.) of individual SAMS categories and summative assessments. Asterisks indicate significant results comparing the fifth manual and fifth robot-assisted anastomosis performed by novices ( $*p < 0.05$ ;  $**p < 0.01$ ).

anastomosis. Moreover, apart from “suture placement,” “steps,” and “speed,” microsurgical skill evaluation showed significantly better results in the final robot-assisted compared with the final manual anastomosis.

To further evaluate anastomosis quality, novices' final anastomoses were photographed from the luminal side and the ALI was applied (►Fig. 4A,B). Out of 10 previously classified distinct error types,<sup>17</sup> “backwall or sidewall catch,”



**Fig. 4** Anastomosis Lapse Index (ALI). The fifth manual and robot-assisted anastomosis performed by novices was cut longitudinally to assess the ALI, quantifying the anastomosis quality ( $n = 3$ ). Representative luminal images of manual (A) and robot-assisted anastomoses (B) are depicted. (C) Bar chart represents the total number of each classified error type upon all three manual and robot-assisted anastomoses. Mean errors per anastomosis were calculated with standard deviation.

“bite leading to tissue infoldment,” “unequal distancing of sutures,” “visible tear in vessel wall,” “strangulation of tissue edges,” and “large edge overlap” occurred more often upon manual anastomoses (►Fig. 4C). On the other hand, “oblique stitch causing distortion” occurred more often upon robot-assisted anastomoses, while “anastomosis line disruption” and “partial thickness stitch” occurred with equal frequency. On average, 7 errors occurred on manual anastomoses and 4.3 errors occurred on robot-assisted anastomoses, suggesting an advantage for novices using the microsurgical robot after training.

### Ergonomics and Communication

After completion of their first and fifth robot-assisted anastomosis, experienced microsurgeons evaluated the combined application of the microsurgical robot with an exoscope compared with the conventional approach, performing manual anastomoses with a conventional surgical microscope, using a standardized questionnaire.<sup>14</sup> “Team interaction and communication,” “freedom of movement,” “back or neck tenderness,” “intraoperative tremor,” “muscle fatigue,” and “operative comfort” were evaluated better or significantly better compared with the conventional approach (►Fig. 5). On the other hand, “depth and 3D

structure visualization” and “microsurgical handling” were evaluated equal, while “optical detail” was evaluated slightly worse. None of the criteria was evaluated significantly worse.

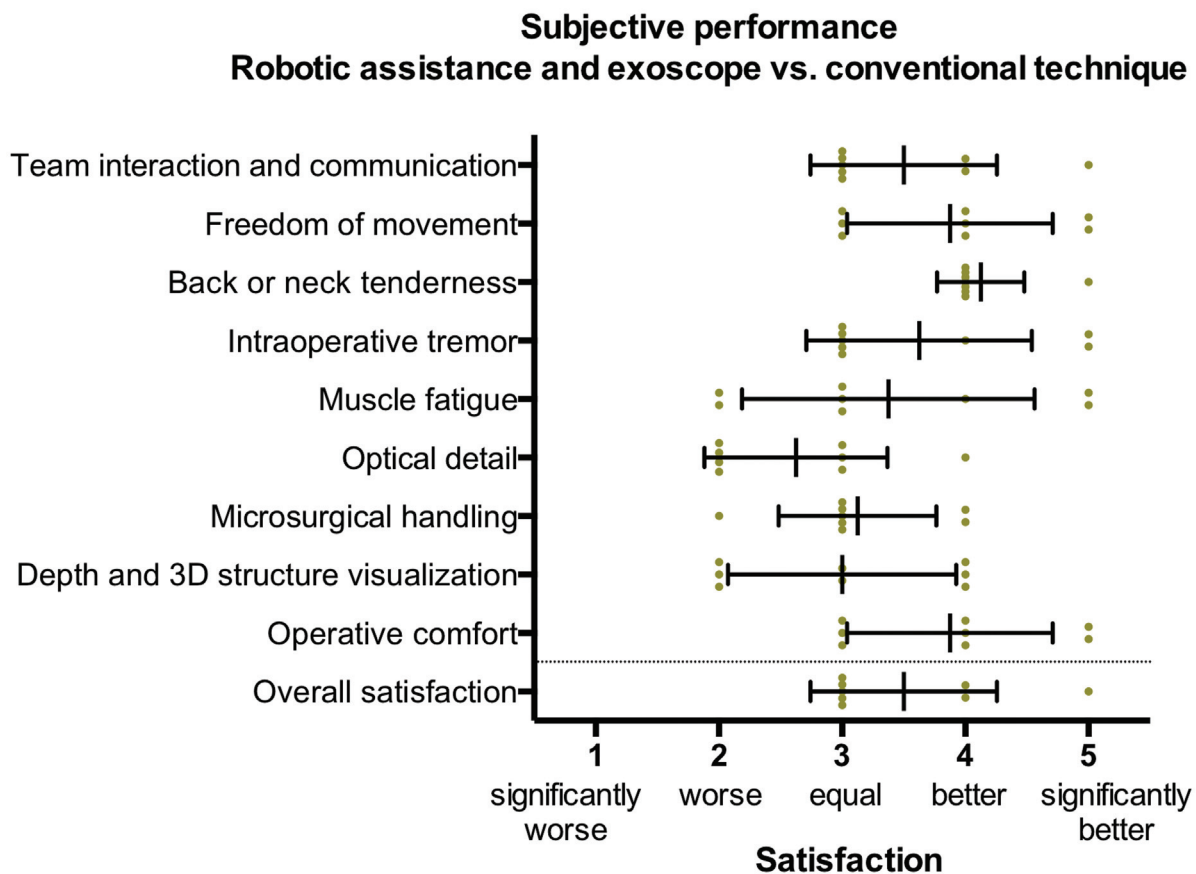
Furthermore, novices were photographed when performing their final robot-assisted and manual anastomosis for posture analysis using the REBA (►Fig. 6A,B). Mean REBA scores for neck, trunk, leg, upper arm, and lower arm positioning were higher when performing manual anastomoses relative to robot-assisted anastomoses (►Fig. 6C).

Consequently, the total REBA score was significantly better during robotic performance, resulting in medium ergonomic risk upon manual anastomoses, compared with low ergonomic risk upon robot-assisted anastomoses (►Fig. 6D).

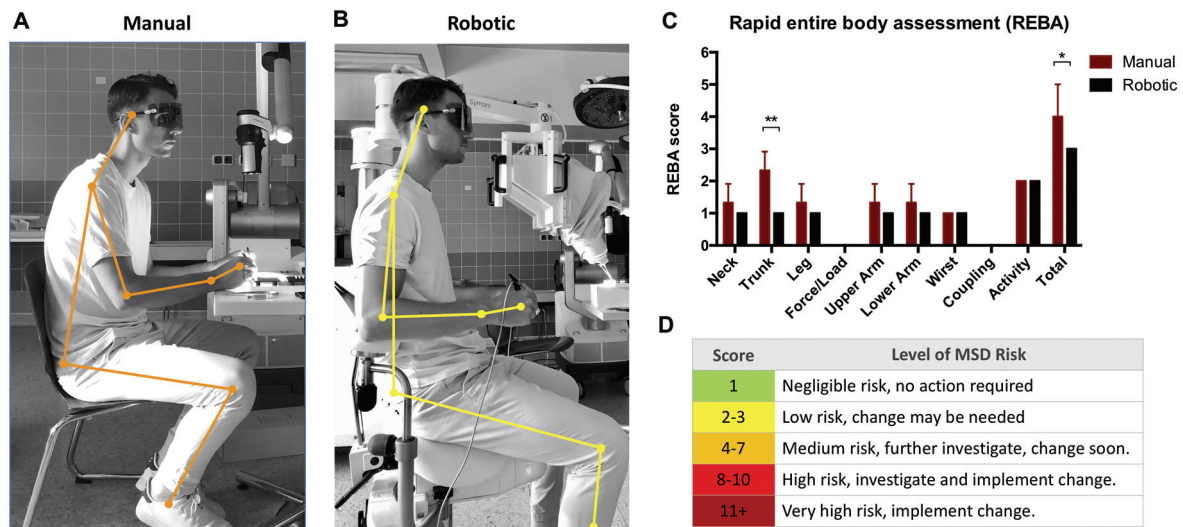
### Discussion

This study is analyzing the learning curve of expert microsurgeons and complete novices during training with a novel system for robotic microsurgery. The training facility setup allowed for a reproducible evaluation of microsurgical skills and ergonomics with objective and subjective assessments.

Performing robotic anastomoses demonstrated a fast learning curve for experts and novices alike. This reflects



**Fig. 5** Ergonomics and communication. Experienced microsurgeons evaluated the combined application of the microsurgical robot and exoscope relative to the conventional technique (manual anastomosis with conventional surgical microscope) after their first and fifth anastomosis ( $n = 8$ ), according to a standardized questionnaire. Dots represent individual values with mean and standard deviation.



**Fig. 6** Rapid Entire Body Assessment (REBA). Novices were photographed for posture analysis when performing their fifth manual (A) and robot-assisted anastomosis (B) ( $n = 3$ ). Representative images with color-coded auxiliary lines are depicted. (C) Bar chart represents mean REBA scores of distinct body parts with standard deviation ( $*p < 0.05$ ;  $**p < 0.01$ ). (D) Table shows REBA scores and the related level of musculoskeletal disorder (MSD) risk with the respective color code.

several aspects exclusive for the robotic handling during the anastomosis: (1) getting used to the wristed instruments' additional axes and learning how to make use of it; (2) learning a specific suturing technique that is circumventing crossing of forceps and needle holder; and (3) most efficient robot-specific moves for suture handling during knot tying.

Improved subjective satisfaction with the anastomosis and the robot performance underscores these findings.

The combination of a mostly remotely operated exoscope with the telemetrically operated microsurgery robot enables an almost complete disconnection from the operating field. The subjective comparison of ergonomics and communication to a setup with conventional microscope and manual anastomosis revealed better performance especially in terms of ergonomics, which was objectively confirmed through the REBA score. Combining the microsurgery robot with a robotic microscope/exoscope has the potential to fully remotely control instruments and visualization, as optic's orbital repositioning can also be remotely operated.<sup>19</sup>

According to the modified SAMS score, the expert surgeons achieved high scores following SAMS training. Despite tissue handling, scores were even higher in the smaller 1-mm vessels. These results are very encouraging since the authors believe that supermicrosurgical applications like performance of lymphovenous anastomosis (LVA) and perforator-to-perforator anastomosis may be the applications benefiting the most from robotic assistance. The novices demonstrated higher scores comparing first and last robotic anastomoses, which is also reflected in subjective ratings. However, this improvement could not be reproduced in manual anastomoses, despite improved subjective performance. While improvement was also noted in reviewing the anastomosis for SAMS score evaluation, changes were not significant enough to lead to SAMS score improvements in its current form.

The lower number of errors in anastomosis quality evaluated by the ALI score at the end of training further underscores performance of the robotic assistance. Therefore, as demonstrated via assessment of multiple angles of objective and subjective measures, novices improved significantly faster in anastomosis quality upon robotic assistance. These results stand in contrast to a preclinical study evaluating another system for robotic microsurgery,<sup>15</sup> where microsurgical skills were rated lower in the robotic group. However, a recent preclinical study using a conventional operating microscope with robotic assistance with the Symani system for microsurgical anastomosis also showed better precision for novice users compared with the manual approach.<sup>20</sup> Even though the results suggest improved microsurgical skill acquisition and anastomosis quality upon robotic assistance, especially for novices lacking microsurgical experience, manual microsurgical training should not be neglected. Building expertise in manual microsurgery is key to avoid dependence on robotic assistance, which can only be applied to selected cases and to guarantee the development of advanced manual skills as well.

Speed of anastomosis on the other hand was not higher in the robotic anastomoses group. Novices and experts did show a reduction in time needed for anastomosis completion, but speed was generally faster in the novice manual group as well as the clinical speed for arterial anastomosis performed by experts. These findings are in line with a previous study evaluating the learning curve of another robotic microsurgery system.<sup>15</sup> In consideration of a realistic clinical setup, additional time will be needed for robot placement prior to anastomosis. Therefore, a benefit in terms of initial anastomosis speed should not be anticipated for the clinical setting. However, there are aspects that may potentially result in faster surgical speed utilizing robotic



assistance. Facilitating anastomosis of even smaller vessels may also decrease free flap pedicle length, leading to faster elevation speeds and recipient site preparation. In terms of LVAs, performing multiple anastomoses is physically demanding. Improved ergonomics may lead to less fatigue and result in improved performance during case progression.

Another benefit may be lower morbidity at donor and recipient sites due to smaller vessel diameters and length.

During training it was noticed that surgeons were using different suturing techniques. While the manufacturer recommends using a specific technique for robotic anastomoses that requires switching the instrument in between knots, some surgeons preferred a technique not switching the thread-holding instrument, therefore requiring less switches between instruments. Further studies should investigate the optimal technique for suturing to further enhance speed and quality.

The lack of touch sensation has been discussed in preliminary clinical reports.<sup>12</sup> While this concern seems valid in the eye of expert microsurgeons, our subjective and objective quality assessment measures did not raise a similar concern. The “see-feel” of artificial vessels seemed to be sufficient to circumvent related problems such as vessel wall tear or thread rupture, while related scores indicated even better performance with robotic assistance.

An additional feature of the custom robotic microsurgical instruments is the needle holder's cutting feature. It reduces necessary interventions by the assisting surgeon or, if the anastomosis should be performed without assistance, eliminated the need for a switch of instruments.

While clinical data using robotic assistance for microsurgical and supermicrosurgical procedures is still limited, first outcome reports demonstrate feasibility, safety, and non-inferiority in clinical application.<sup>21–23</sup>

## Conclusion

Summarizing, our preclinical results imply great potential for the application of robotic assistance for microsurgery. While expert microsurgeons showed a fast learning curve and high satisfaction with anastomosis quality and robotic performance, novices demonstrated higher anastomosis quality and better ergonomics with robotic assistance. Our preclinical findings need to be confirmed within the clinical setting.

### Funding

This study received funding from Recovery Assistance for Cohesion and the Territories of Europe (REACT-EU) x EFRE-0802073.

### Conflict of Interest

None declared.

## References

- Winocour S, Tarassoli S, Chu CK, Liu J, Clemens MW, Selber JC. Comparing outcomes of robotically assisted latissimus dorsi harvest to the traditional open approach in breast reconstruction. *Plast Reconstr Surg* 2020;146(06):1221–1225
- Selber JC. The robotic DIEP flap. *Plast Reconstr Surg* 2020;145(02):340–343
- Choi JH, Song SY, Park HS, et al. Robotic DIEP flap harvest through a totally extraperitoneal approach using a single-port surgical robotic system. *Plast Reconstr Surg* 2021;148(02):304–307
- Gundlapalli VS, Ogunleye AA, Scott K, et al. Robotic-assisted deep inferior epigastric artery perforator flap abdominal harvest for breast reconstruction: a case report. *Microsurgery* 2018;38(06):702–705
- Toesca A, Peradze N, Galimberti V, et al. Robotic nipple-sparing mastectomy and immediate breast reconstruction with implant: first report of surgical technique. *Ann Surg* 2017;266(02):e28–e30
- Lai HW, Chen ST, Lin SL, et al. Robotic nipple-sparing mastectomy and immediate breast reconstruction with gel implant: technique, preliminary results and patient-reported cosmetic outcome. *Ann Surg Oncol* 2019;26(01):42–52
- Sarfati B, Struk S, Leymarie N, et al. Robotic nipple-sparing mastectomy with immediate prosthetic breast reconstruction: surgical technique. *Plast Reconstr Surg* 2018;142(03):624–627
- Joo OY, Song SY, Park HS, Roh TS. Single-port robot-assisted prosthetic breast reconstruction with the da Vinci SP Surgical System: first clinical report. *Arch Plast Surg* 2021;48(02):194–198
- Kuo WL, Huang JJ, Huang YT, et al. Robot-assisted mastectomy followed by immediate autologous microsurgical free flap reconstruction: techniques and feasibility in three different breast cancer surgical scenarios. *Clin Breast Cancer* 2020;20(01):e1–e8
- Huang JJ, Chuang EYH, Cheong DCF, Kim BS, Chang FCS, Kuo WL. Robotic-assisted nipple-sparing mastectomy followed by immediate microsurgical free flap reconstruction: Feasibility and aesthetic results - case series. *Int J Surg* 2021;95:106143
- van Mulken TJM, Schols RM, Scharmga AMJ, et al. First-in-human robotic supermicrosurgery using a dedicated microsurgical robot for treating breast cancer-related lymphedema: a randomized pilot trial. *Nat Commun* 2020;11(01):757
- Lindenblatt N, Grünherz L, Wang A, et al. Early experience using a new robotic microsurgical system for lymphatic surgery. *Plast Reconstr Surg Glob Open* 2022;10(01):e4013
- Aitzetmüller MM, Klietz M-L, Dermietzel AF, Hirsch T, Kückelhaus M. Robotic-assisted microsurgery and its future in plastic surgery. *J Clin Med* 2022;11(12):3378
- Will PA, Hirche C, Berner JE, Kneser U, Gazyakan E. Lymphovenous anastomoses with three-dimensional digital hybrid visualization: improving ergonomics for supermicrosurgery in lymphedema. *Arch Plast Surg* 2021;48(04):427–432
- van Mulken TJM, Boymans CAEM, Schols RM, et al. Preclinical experience using a new robotic system created for microsurgery. *Plast Reconstr Surg* 2018;142(05):1367–1376
- Chan W, Niranjana N, Ramakrishnan V. Structured assessment of microsurgery skills in the clinical setting. *J Plast Reconstr Aesthet Surg* 2010;63(08):1329–1334
- Ghanem AM, Al Omran Y, Shatta B, Kim E, Myers S. Anastomosis Lapse Index (ALI): a validated end product assessment tool for simulation microsurgery training. *J Reconstr Microsurg* 2016;32(03):233–241
- Hignett S, McAtamney L. Rapid Entire Body Assessment (REBA). *Appl Ergon* 2000;31(02):201–205
- Dermietzel A, Aitzetmüller M, Klietz M-L, et al. Free flap breast reconstruction using a novel robotic microscope. *J Plast Reconstr Aesthet Surg* 2022;75(07):2387–2440
- Ballestín A, Malzone G, Menichini G, Lucattelli E, Innocenti M. New robotic system with wristed microinstruments allows



- precise reconstructive microsurgery: preclinical study. *Ann Surg Oncol* 2022;29(12):7859–7867
- 21 van Mulken TJM, Wolfs JAGN, Qiu SS, et al. One-year outcomes of the first human trial on robot-assisted lymphaticovenous anastomosis for breast cancer-related lymphedema. *Plast Reconstr Surg* 2022;149(01):151–161
- 22 Barbon C, Grünherz L, Uyulmaz S, Giovanoli P, Lindenblatt N. Exploring the learning curve of a new robotic microsurgical system for microsurgery. *JPRAS Open* 2022;34:126–133
- 23 Innocenti M, Malzone G, Menichini G. First-in-human free flap tissue reconstruction using a dedicated microsurgical robotic platform. *Plast Reconstr Surg* 2023;151(05):1078–1082