




A Rare Case of Obstructive Shock due to Cardiac Tamponade in a Term Pregnancy

Megan Masten, MD¹ Haya Kaliounji, BS² Josephine Chou, MD, MS³ Alexis Tumolo, MD³
Jonathan S. Hirshberg, MD⁴ Lauren Sayres, MD⁵ 

¹Department of Obstetrics and Gynecology, University of Colorado, Aurora, Colorado

²School of Medicine, University of Colorado, Aurora, Colorado

³Department of Medicine, Division of Cardiology, University of Colorado, Aurora, Colorado

⁴Department of Medicine, Division of Pulmonary Sciences and Critical Care Medicine, University of Colorado, Aurora, Colorado

Address for correspondence Lauren Sayres, MD, Department of Obstetrics and Gynecology, Division of Maternal-Fetal Medicine, University of Colorado, 12631 East 17th Avenue, Office B198, Aurora, CO 80045 (e-mail: lauren.sayres@cuanschutz.edu).

⁵Department of Obstetrics and Gynecology, Division of Maternal-Fetal Medicine, University of Colorado, Aurora, Colorado

AJP Rep 2023;13:e94–e97.

Abstract

Obstructive shock due to cardiac tamponade is a rare, life-threatening occurrence in the peripartum period. Etiologies include preeclampsia, infection, autoimmune conditions, and malignancy. Early recognition of the underlying disease process allows for multidisciplinary treatment and a favorable outcome.

A 33-year-old presented for cardiac tamponade identified in the peripartum period. She was diagnosed with preeclampsia with severe features immediately prior to her repeat cesarean delivery and received magnesium prophylaxis. Postoperatively, she developed hypotension, tachycardia, and shortness of breath and was found to have a pericardial effusion with tamponade physiology. She underwent pericardial drain placement which was initially successful. However, she had recurrent symptomatic tamponade and thus a pericardial window was performed resulting in improvement of her symptoms. Workup revealed pericardial inflammation possibly secondary to a viral source, and she was successfully treated with anti-inflammatory therapy.

We hypothesize that this patient's cardiac tamponade was caused by inflammatory pericarditis exacerbated by severe preeclampsia. Preeclampsia is a disease characterized by cardiovascular remodeling and fluid shifts in other compartments and thus is theorized to have contributed to this patient's effusion. Cardiac tamponade should be considered in the differential for any parturient presenting with hypotension and shortness of breath.

Keywords

- ▶ cardiac tamponade
- ▶ pericardial effusion
- ▶ pericarditis
- ▶ obstructive shock
- ▶ preeclampsia

Clinically insignificant, transient pericardial effusions have been described in up to 40% of healthy women in the third trimester, likely due to hypoalbuminemia and volume retention.^{1–3} However, progression of a pericardial effusion to

cardiac tamponade is a rare occurrence, particularly in pregnancy, as pregnant women are suspected to tolerate larger effusions than their nonpregnant counterparts due to increased gestational blood volume.⁴ Contributing factors

received

March 2, 2023

accepted

October 19, 2023

accepted manuscript online

October 27, 2023

DOI <https://doi.org/10.1055/a-2200-3497>.

ISSN 2157-6998.

© 2023. The Author(s).

This is an open access article published by Thieme under the terms of the Creative Commons Attribution-NonDerivative-NonCommercial-License, permitting copying and reproduction so long as the original work is given appropriate credit. Contents may not be used for commercial purposes, or adapted, remixed, transformed or built upon. (<https://creativecommons.org/licenses/by-nc-nd/4.0/>)

Thieme Medical Publishers, Inc., 333 Seventh Avenue, 18th Floor, New York, NY 10001, USA

may include preeclampsia, infection, autoimmune conditions, malignancy, and iatrogenic effect. Herein, we present an unusual case of a pericardial effusion resulting in cardiac tamponade and life-threatening obstructive shock in the peripartum period.

Case Presentation

This is a 33-year-old gravida 4 para 3013 transferred to our tertiary care hospital for a higher level of care. The day prior to transfer, she had undergone a scheduled repeat cesarean section and bilateral tubal ligation at 37 weeks for fetal malpresentation in the setting of Duffy antibody isoimmunization. She had a history of preeclampsia with severe features in her first pregnancy. During the current pregnancy, she had presented at 35 weeks with edema and proteinuria with a urine protein/creatinine ratio of 1.5; she was normotensive with otherwise unremarkable workup at that time.

Upon presentation for scheduled delivery, she reported a headache, shortness of breath, and peripheral edema. Vital signs were notable for a heart rate in the 180s and blood pressures of 150s/100s. She was afebrile with normal oxygen saturation. Workup revealed an elevated creatinine of 1.1 mg/dL and elevated aspartate aminotransferase and alanine aminotransferase of 166 and 132 U/L, respectively. A urine protein/creatinine ratio was not repeated given its prior elevation. She was diagnosed with preeclampsia with severe features and started on magnesium for seizure prophylaxis. Her vital signs improved such that her team was comfortable proceeding with delivery, and she underwent a low transverse cesarean section with tubal ligation under spinal anesthesia. Estimated blood loss was 1,475 mL with hemostasis achieved surgically; she did not receive uterotonics aside from standard dosing of prophylactic Pitocin.

Initial Presentation and Management of Tamponade

Within 1 hour of delivery, the patient developed worsening shortness of breath, hypotension to the 40s/20s, tachycardia to the 120s, and otherwise normal vital signs. The differential diagnosis included amniotic fluid embolism, pulmonary embolism, myocardial infarction, cardiac failure, cardiac tamponade, sepsis, high spinal placement, and magnesium toxicity.

Immediate bloodwork included a hemoglobin of 13.4 g/dL, a magnesium level of 4.2 mg/dL, an elevated brain natriuretic peptide of 2,470 pg/mL, and an elevated C-reactive protein (CRP) of 32 mg/L. Electrocardiogram showed a normal sinus rhythm with right axis deviation. A chest X-ray revealed a mildly enlarged cardiac silhouette. Transthoracic echocardiogram (TTE) demonstrated a moderate pericardial effusion with early tamponade physiology. Given this finding, additional bloodwork was sent, which resulted negative for antiphospholipid antibodies, antinuclear antibodies, rheumatoid factor, antineutrophil cytoplasmic antibodies, Coxsackievirus antibodies, and a panel of respiratory viruses. Notably, her thyroid stimulating hormone level was elevated to 9.2 mIU/L

with a low free thyroxine level of 0.6 ng/dL; she had no history of thyroid dysfunction until this juncture.

She was given phenylephrine, albumin, and crystalloid resuscitation and placed in Trendelenburg position. She was transferred to the intensive care unit for ongoing care. The cardiology team was consulted and performed an ultrasound-guided pericardiocentesis and placement of a pericardial drain approximately 10 hours after her initial presentation. The pericardial fluid was found to be exudative by Light's criteria and ultimately negative for malignancy by cytology or organisms by culture. She demonstrated early signs of recovery including normalization of vitals and production of approximately 20 mL/hour serous fluid via the pericardial drain, which was an appropriate output per the team caring for her. She was maintained on a 24-hour course of magnesium sulfate.

On postoperative day 1, she was transferred to our institution's cardiac intensive care unit for a higher level of care due to new chest pain. A repeat TTE was reassuring with near resolution of the pericardial effusion. She was started on ibuprofen for presumed pericarditis, nifedipine for hypertension, and levothyroxine for hypothyroidism. Over the next several days, her chest pain resolved, her pericardial drain output decreased, and her drain was ultimately clamped and removed. Her vital sign disturbances and acute kidney injury and transaminitis had resolved. She was discharged on postoperative day 5 in stable condition.

Readmission for Worsening Symptomatology

Six days later, the patient represented for increasing shortness of breath. She was readmitted to our cardiac intensive care unit. She was found to have a leukocytosis of $16 \times 10^9/L$, thrombocytosis of $798 \times 10^9/L$, and an increased CRP of 82 mg/L. TTE showed an anterior pericardial effusion that increased in size relative to a TTE performed at the time of discharge from her initial admission. Computed tomography angiography was negative for pulmonary embolism. It was determined that she had worsening pericarditis, and she was started on colchicine in addition to her previously prescribed ibuprofen.

That night, hypotension and tachycardia recurred. A TTE showed increasing pericardial effusion and decreased biventricular systolic function with ventricular interdependence concerning for recurrent tamponade; see ► **Fig. 1**. A pericardial window was performed without complication. During the procedure, her pericardium was noted to be thickened with a rind. Pathology demonstrated edematous fibroconnective tissue with mixed acute on chronic inflammation, degenerating peripheral blood elements, and proteinaceous material. Immunostaining was negative for syndecan-1 (CD138) and immunoglobulin G4. Cytology of the pericardial fluid revealed neutrophils, lymphocytes, and red blood cells and was negative for malignant cells. Aerobic, anaerobic, and fungal cultures and Gram and acid-fast stains of the fluid were negative. The pericardial drain output was 85 mL over postprocedural day 1 and gradually ceased until the drain could be removed on postprocedural day 5. The patient was

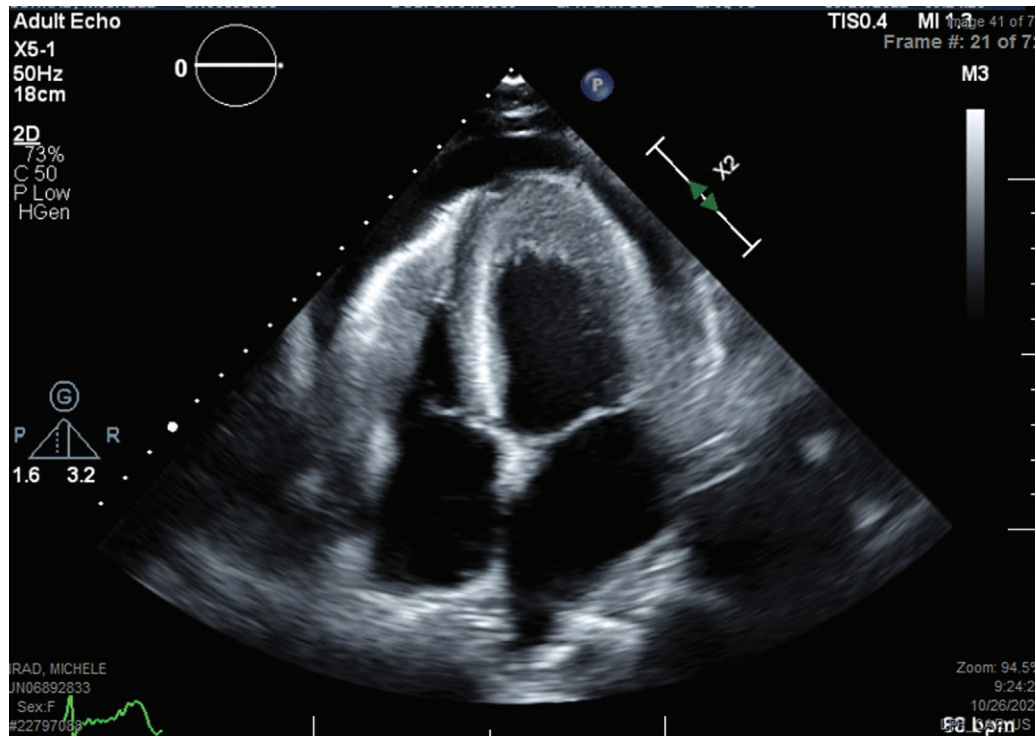


Fig. 1 Apical view of the heart via transthoracic echocardiography demonstrates a moderate circumferential pericardial effusion with early diastolic collapse of the right ventricular free wall.

discharged the following day on ibuprofen and colchicine with a plan for close outpatient cardiology care.

During this admission, cardiac magnetic resonance imaging revealed acute constrictive pericarditis. The pericardium was thickened with a complex effusion and diffuse adhesions. Pericardial inflammation was demonstrated on short tau inversion recovery and late gadolinium enhancement imaging. Exaggerated interventricular dependence was consistent with constrictive physiology. In contrast, there was minimal left ventricular involvement with a normal ejection fraction and no enhancement of the ventricular myocardium to suggest myocarditis.

Outpatient Surveillance

The patient presented to clinic a week later with ongoing mild symptoms. Steroids were prescribed to further reduce inflammation with good effect. She is planned for continued outpatient monitoring with serial inflammatory markers and echocardiography and a repeat cardiac MRI in approximately 3 months.

Discussion

We present an unusual case of life-threatening obstructive shock due to cardiac tamponade in a term pregnancy. Specifically, we address the timely evaluation, resuscitation, and ongoing management necessary to reduce the morbidity and mortality of this condition. Our review of the literature suggests that while asymptomatic pericardial effusions may occur in late pregnancy, there are only 13 case reports of

peripartum cardiac tamponade.^{5–17} Reported etiologies are diverse and include autoimmune, infectious, neoplastic, and iatrogenic causes, and all should be considered when encountering a similar patient presentation. A singular case reported by Matsuki et al was presumed attributable to preeclampsia with severe features as the patient presented with severe hypertension and proteinuria and no other etiology for pericardial effusion was identified.⁹

We hypothesize that the etiology of pericardial effusion leading to tamponade in our patient was inflammatory—possibly viral—pericarditis exacerbated by severe preeclampsia. Intraoperative findings, pathology and cytology reports, and cardiac MRI data were consistent with inflammation and a possibly infectious process of the pericardium. Notably, autoimmune and bacterial workup were negative, and viral sources for pericarditis cannot always be reliably identified. Prompt treatment with anti-inflammatories as an adjunct to pericardial drain placement appeared to improve her pathology, further corroborating a diagnosis of inflammatory pericarditis, and ultimately will ideally prevent progression to chronic constrictive pericarditis.¹⁸

We surmise that preeclampsia was a significant contributing factor to the development of her pericardial effusion. Preeclampsia is a disease characterized by maternal endothelial dysfunction, vasoconstriction, vascular permeability, oxidative stress, and inflammation.¹⁹ More commonly described maternal clinical manifestations include pulmonary or cerebral edema. Cardiac manifestations from the increased systemic vascular resistance that defines preeclampsia include concentric left ventricular hypertrophy, left ventricular diastolic dysfunction, left atrial enlargement,

and increased right ventricular systolic pressures.^{20,21} A series of 56 pregnant women found that pericardial effusions occur more frequently among patients with pregnancy-induced hypertension relative to healthy counterparts (31 vs. 17%, $p < 0.01$).²² Thus, it may be extrapolated that an inflammatory pericardial effusion was exacerbated by the cardiovascular remodeling and dysfunction of preeclampsia and resulted in tamponade in our patient.

While this patient's workup was notable for hypothyroidism, several consulting teams agree that this mild degree of disease was unlikely to have explained her presentation.

It should be noted that this patient had an initial improvement followed by a worsening of her condition requiring an additional procedure and medications. It is possible that her initial pericardial drain and ibuprofen were sufficient to temporize but not fully treat the likely underlying viral etiology of her disease. As such, more definitive management with pericardial window, colchicine, and steroids were what afforded her full recovery. Additionally, edema and other sequelae of preeclampsia can often worsen in the initial postpartum period, taking weeks to completely resolve. Her secondary decompensation may have coincided with this expected natural history of preeclampsia.

Ultimately, the care of this patient required a multidisciplinary team of maternal fetal medicine, cardiology, and critical care subspecialists. Astute, timely investigation into this rare presentation of cardiac tamponade allowed this patient to receive appropriate treatment and recover from her disease. Although less common than distributive and hypovolemic shock, etiologies of obstructive shock should be considered in a peripartum patient with shortness of breath or hypotension. A low threshold for workup of similarly presenting pregnant patients is warranted, as urgent treatment can mitigate adverse outcomes both in the acute period and long-term. As clinician-scientists, we urge further translational research efforts to better understand both the acute and long-term cardiovascular consequences of preeclampsia.

Conflict of Interest

None declared.

Acknowledgments and Informed Consent

The authors are grateful to the patient whose case is summarized within; she provided written consent for this case report.

References

- Haiat R, Halphen C. Silent pericardial effusion in late pregnancy: a new entity. *Cardiovasc Intervent Radiol* 1984;7(06):267–269
- Abduljabbar HS, Marzouki KM, Zawawi TH, Khan AS. Pericardial effusion in normal pregnant women. *Acta Obstet Gynecol Scand* 1991;70(4–5):291–294
- Enein M, Zina AA, Kassem M, el-Tabbakh G. Echocardiography of the pericardium in pregnancy. *Obstet Gynecol* 1987;69(06):851–853
- Imazio M, Brucato A, Rampello S, et al. Management of pericardial diseases during pregnancy. *J Cardiovasc Med (Hagerstown)* 2010;11(08):557–562
- Simpson WG, DePriest PD, Conover WB. Acute pericarditis complicated by cardiac tamponade during pregnancy. *Am J Obstet Gynecol* 1989;160(02):415–416
- Yousif PA, Sudhakar S, Malemud C, Blumenthal DE. Cardiac tamponade as initial presentation of systemic lupus erythematosus in third-trimester pregnancy. *Am J Case Rep* 2022;23:e936273–1–e936273–6
- Romagano MP, Patel K, Williams S, Apuzzio JJ. Evaluation and treatment of cardiac tamponade in a pregnant patient. *Case Rep Obstet Gynecol* 2020:8703980
- Aznaouridis K, Lazaros G, Tousoulis D, Toutouzias K. Neoplastic cardiac tamponade in a pregnant woman. *Eur Heart J* 2020;41(16):1610
- Matsuki R, Nakago S, Takaoka H, Oishi T, Kotsuji F. Cardiac tamponade in pregnancy during the treatment of severe pre-eclampsia: report of a case. *J Obstet Gynaecol Res* 2014;40(03):826–828
- Kinthala S, Fakoory M, Greaves T, Kandamaran L, Thomas H, Moe S. Subcapsular liver hematoma causing cardiac tamponade in HELLP syndrome. *Int J Obstet Anesth* 2012;21(03):276–279
- Azimi NA, Selter JG, Abott JD, et al. Angiosarcoma in a pregnant woman presenting with pericardial tamponade—a case report and review of the literature. *Angiology* 2006;57(02):251–257
- Ansari E, Karas BJ, Jiang L. A case of tamponade complicating pregnancy. *Clin Cardiol* 2005;28(02):71
- Shattuck B, Livingstone J. A case of cardiac tamponade due to an isolated abscess in the ascending aorta of a pregnant woman with a history of intravenous substance abuse. *Forensic Sci Med Pathol* 2017;13(02):226–229
- Allali F, Alami M, Doghmi N, Mohatane A, Benomar M, Hajjaj-Hassouni N. Scleroderma complicated with tamponade during pregnancy. *Joint Bone Spine* 2005;72(04):341–343
- Rifaie O, Samir S, Nammias W. Cardiac tamponade after mitral valvuloplasty in a pregnant woman. *Acta Cardiol* 2010;65(06):699–701
- Averbuch M, Bojko A, Levo Y. Cardiac tamponade in the early postpartum period as the presenting and predominant manifestation of systemic lupus erythematosus. *J Rheumatol* 1986;13(02):444–445
- Ketata W, Msaad S, Feki W, Gargouri I, Ayadi H, Ayoub A. [Postpartum pericardic tamponade revealing systemic lupus erythematosus]. *Rev Pneumol Clin* 2009;65(05):306–308
- Imazio M, Brucato A, Maestroni S, et al. Risk of constrictive pericarditis after acute pericarditis. *Circulation* 2011;124(11):1270–1275
- Ives CW, Sinkey R, Rajapreyar I, Tita ATN, Oparil S. Preeclampsia-pathophysiology and clinical presentations: JACC state-of-the-art review. *J Am Coll Cardiol* 2020;76(14):1690–1702
- Vaught AJ, Kovell LC, Szymanski LM, et al. Acute cardiac effects of severe pre-eclampsia. *J Am Coll Cardiol* 2018;72(01):1–11
- Birukov A, Wiesemann S, Golic M, et al. Myocardial evaluation of post-preeclamptic women by CMR: is early risk stratification possible? *JACC Cardiovasc Imaging* 2020;13(05):1291–1293
- Yuan L, Duan Y, Cao T. Echocardiographic study of cardiac morphological and functional changes before and after parturition in pregnancy-induced hypertension. *Echocardiography* 2006;23(03):177–182