

Single-operator cholangioscopy system for management of acute cholecystitis secondary to choledocholithiasis ▶

OPEN
ACCESS

Authors

Liyang Tao^{1,2}, Hongguang Wang^{1,2}, Qingmei Guo^{1,2}

Institutions

- 1 Department of Gastroenterology, Jilin People's Hospital, Jilin, China
- 2 Digestive Endoscopy Center, Jilin People's Hospital, Jilin, China

Key words

Stones, Cholangioscopy

received 28.8.2023

accepted after revision 27.10.2023

accepted manuscript online 30.10.2023

Bibliography

Endosc Int Open 2023; 11: E1138–E1142

DOI 10.1055/a-2201-6871

ISSN 2364-3722

© 2023. The Author(s).

This is an open access article published by Thieme under the terms of the Creative Commons Attribution-NonDerivative-NonCommercial License, permitting copying and reproduction so long as the original work is given appropriate credit. Contents may not be used for commercial purposes, or adapted, remixed, transformed or built upon. (<https://creativecommons.org/licenses/by-nc-nd/4.0/>)

Georg Thieme Verlag KG, Rüdigerstraße 14,
70469 Stuttgart, Germany

Corresponding author

Prof. Hongguang Wang, Jilin People's Hospital, Digestive Endoscopy Center, No. 36, Zhongxing Street, Changyi District, 132000 Jilin, China
wanghongguang1817@163.com

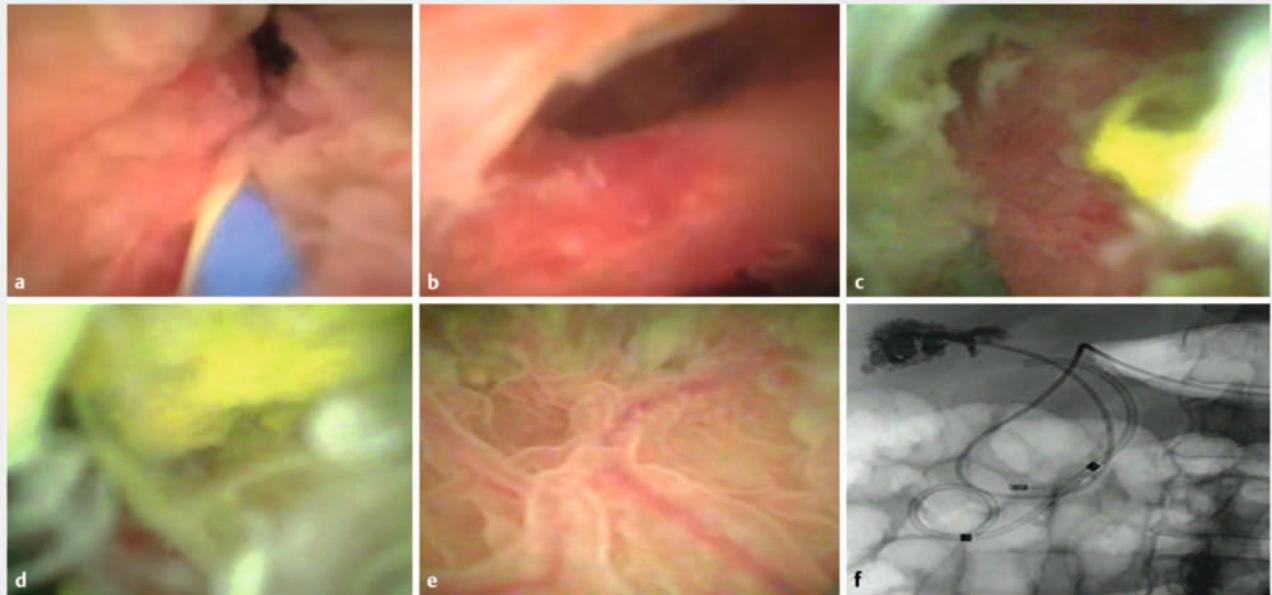
ABSTRACT

This study aimed to investigate the safety and efficacy of endoscopic retrograde cholangiopancreatography (ERCP) + EyeMax (single-operator cholangioscopy system; SOC) (i. e., ERCP+SOC) for the treatment of choledocholithiasis-associated acute cholecystitis. Twenty-five patients were evaluated between January 2022 and June 2023. The success rate (technical + clinical), procedure time, postoperative recovery, postoperative length of hospital stay, and complications rates were recorded. The procedure and clinical success rates were 92% (23/25) and 96% (24/25), respectively. The mean procedure time was 36.6±10 minutes (standard deviation [SD]). The average postoperative hospitalization was 2±0.8 days. No adverse events such as bleeding, perforation, or bile leakage occurred. Cholecystitis did not recur during the 2 to 18 months of follow-up. ERCP+SOC may be a feasible, safe, and effective alternative treatment for acute cholecystitis secondary to choledocholithiasis. ERCP+SOC was able to simultaneously resolve both biliary tract and gallbladder problems via natural orifice endoscopy. Its advantages included no skin wound, reduced postoperative pain, quick recovery, limited to no exposure to x-rays, and a short hospital stay.

Introduction

Acute cholecystitis is a common abdominal emergency caused by inflammation of the cystic duct mainly due to obstruction, bacterial invasion, and/or infection [1]. Open cholecystectomy + common bile duct lithotomy was the preferred treatment for acute cholecystitis secondary to choledocholithiasis for decades [2]. More recently, this was largely replaced by minimally invasive laparoscopic cholecystectomy + common bile duct lithotomy and endoscopic retrograde cholangiopancreatography (ERCP) + laparoscopic cholecystectomy. This combined ap-

proach has become the standard of care wherever the resources and expertise are available [3]. However, emergency cholecystectomy is complicated by a both a high complication rate (55%–66%) and mortality rate of between 14% and 30% [4]. Percutaneous transhepatic gallbladder drainage (PTGD) was introduced to reduce the risk of surgery and associated complications. Typically, emergent minimally invasive drainage of bile is used to control gallbladder inflammation followed by ERCP to manage common bile duct stones followed by elective cholecystectomy.



► **Fig. 1** **a** SOC view of the common bile duct, which shows slightly hyperemic and edematous mucosa at the end of the common bile duct. **b** SOC imaging of the opening of the cystic duct, which shows obviously hyperemic and edematous mucosa. **c** Large amount of pus and bile mud attached to the gallbladder wall is seen after entering into the gallbladder under guidewire guidance. **d** The yellow soft texture stones in the gallbladder cavity can be seen before the lavage. **e** Fluid in the gallbladder cavity is suctioned by negative pressure, and the structure of the gallbladder wall and the shape of the blood vessels are clearly observed. **f** X-ray image of indwelling nasobiliary drainage in the gallbladder cavity and indwelling pigtail-type plastic stent in the bile duct.

EyeMax (Nanwei Medical Technology Co., Ltd., Nanjing, China) is a single-operator cholangioscopy system (SOC). It is a novel fiber optic direct vision system designed for the management of bile duct stones and for the evaluation of biliary stricture [5]. The EyeMax system provides both imaging for endoscopic procedures of the pancreatobiliary system as well as working channels for other diagnostic and therapeutic accessories. Two EyeMax systems are currently available, the CDS11001 model with an instrument channel diameter ≥ 1.8 mm and Nnewi effective working length of 2200 ± 50 mm. The maximum insertion outer diameter ≤ 4.2 mm and the maximum field of view angle is $120^\circ \pm 18^\circ$. The other model, which was used in this study (model CDS22001), has an instrument channel diameter of ≥ 1.0 mm and an effective working length of 2200 ± 50 mm. The maximum outer diameter of the maximum part is ≤ 3.2 mm with a maximum field of view angle of $120^\circ \pm 18^\circ$. The CDS2201 model was used because it can easily pass through the spiral structure of the gallbladder neck.

Herein, we describe the use of the SOC system to treat acute cholecystitis secondary to choledocholithiasis. The instrument allowed direct vision of the gallbladder and biliary ducts, directed irrigation, as well as lithotripsy, if needed. The purpose of this study was to investigate the safety and efficacy of ERCP+SOC system for the treatment of acute cholecystitis secondary to choledocholithiasis.

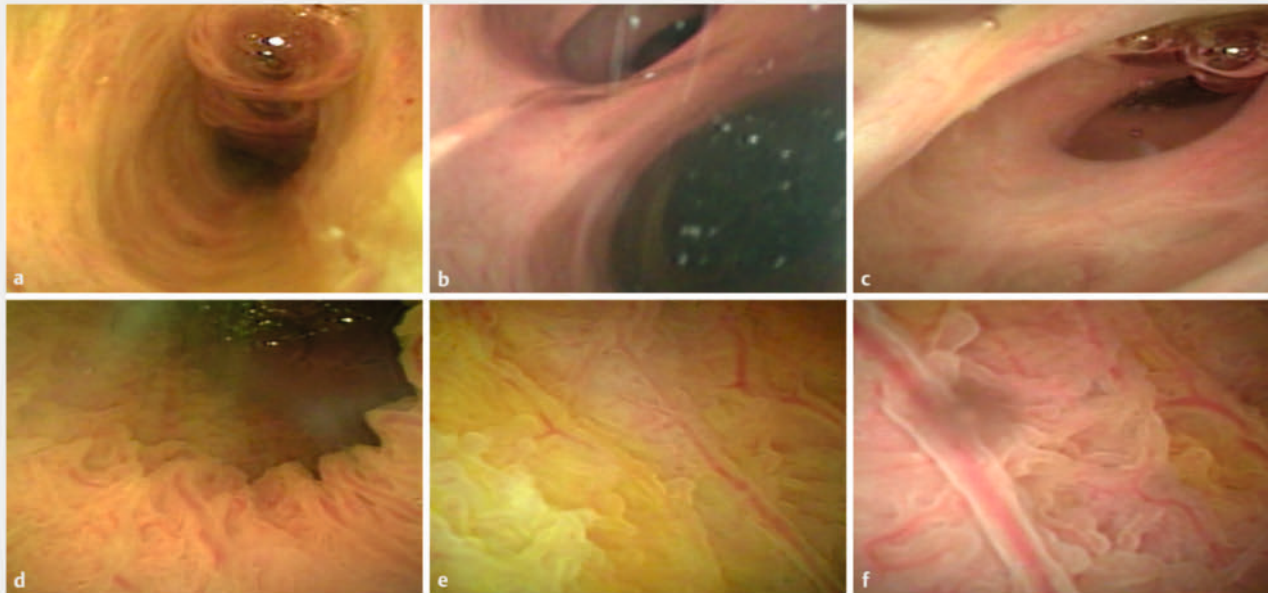
Patients and methods

Study design and protocol

Twenty-five patients with acute cholecystitis secondary to choledocholithiasis admitted to our hospital between January 2022 and June 2023 were studied. The inclusion criteria included: 1) patients with acute cholecystitis secondary to choledocholithiasis diagnosed by abdominal computed tomography (CT) or magnetic resonance cholangiopancreatography (MRCP); 2) patients with no relevant drug or surgical treatment before the procedure; 3) patients who voluntarily signed informed consent; and 4) patients with no history of previous ERCP treatment, and no disease or drug history affecting coagulation function. The exclusion criteria were: 1) patients with other biliary diseases, such as intrahepatic bile duct stones, bile duct stenosis, etc; 2) patients with upper gastrointestinal reconstruction; 3) patients with failure of multiple organs such as the heart, brain, and lungs; and 4) patients with known or suspected duodenal papilla, common bile duct, or gallbladder tumors.


Description of the technique

The procedure was done under general anesthesia with patients in the left lateral position. Endoscopic ultrasonography was performed to identify the location, number and size of common bile duct stones, gallbladder wall thickness, and the presence of gallbladder stones. The duodenoscope was introduced and advanced to the descending segment of the duodenum for intubation of the papilla. After intubation, incision and



► Fig. 2 **a** The wall of the common bile duct is smooth and there is no pus attached after the procedure (complete irrigation). **b** The upper left opening is the opening of the cystic duct without any hyperemia, edema, no pus, the lower right opening is the common hepatic canal. **c** The cervical canal of the gallbladder and the Heister valve are clearly visible. **d** The gallbladder wall is clear, and there is no pus and stone residue compared with the preoperative view. **e** The superficial vessels of the mucosa at the base of the gallbladder are multi-trunk branches. **f** The superficial blood vessels of the mucosa of the gallbladder body after drainage are clearly visible and show trunk + network branches.

► VIDEO



► Video 1 The description of SOC-assisted drainage of the gallbladder.

dilatation of the papilla was performed based on the size of the stone. Stone extraction was performed using a balloon or biliary extractor. The SOC instrument was then introduced via the endoscopy channel to identify the opening of the cystic duct. The guidewire was passed through the cystic duct into the lumen of the gallbladder, which was irrigated with a metronidazole-containing solution. Irrigation of the gallbladder, sedimentary stones, and septic bile was performed until the fluid returns were clear (► Fig. 1 and ► Fig. 2). Smaller stones were removed via SOC under direct vision. For larger stones, lithotripsy was performed followed by irrigation to clear the debris. Finally,

a pigtail-type nasobiliary tube was placed under the guidance of the guidewire for drainage (► Video 1).

Definitions

Procedure technical success was defined as successful entry into the gallbladder and placement of double pigtail stent in the gallbladder via SOC. Clinical success was defined as patient relief from symptoms (fever, abdominal pain) after the treatment with SOC, without referral to the Surgery Department for cholecystectomy.

Statistical analysis

Statistical analyses were performed using IBM SPSS Statistics 25.0 (Statistical Package for the Social Sciences, Inc, Chicago, Illinois, United States). Chi-square test or the Fisher's exact test was used for comparison of categorical data. $P < 0.05$ was statistically significant.

Results

Twenty-five patients with acute cholecystitis secondary to choledocholithiasis were included in this study. The baseline characteristics of all the included patients are summarized in ► Table 1. The procedure technical success rate was 92% (23/25) and the clinical success rate was 96% (24/25). The mean procedure time was 36.6 ± 10 minutes (standard deviation). All the patients had a significant decrease in C-reactive protein (CRP) after the procedure. The average postoperative hospitalization was 2 ± 0.8 days.

► **Table 1** Baseline characteristics of patients included in this study.

Characteristics	ERCP+SOC patients (n=25)
Age (year), (mean ± SD)	73.68 ± 13.82
Sex, (male/female)	10/13
Symptoms (d), median (IQR)	3 (1–7)
WBC (x10 ⁹ /L), median (IQR)	10.40 (8.80–13.60)
CRP (mg/L), median (IQR)	72.00 (34.00–85.60)
CT/EUS n (%)	25 (100%)
Temperature ≥ 38°C, n(%)	9 (36.00%)

ERCP, endoscopic retrograde cholangiopancreatography; SOC, standard of care; SD, standard deviation; IQR, interquartile range; WBC, white blood cell; CRP, C-reactive protein; CT, computed tomography; EUS, endoscopic ultrasound.

Technical failure occurred in two patients because SOC failed to traverse the cystic duct, which was, however, irrigated without entering the gallbladder. Currently, attempts to traverse the cystic duct are gentle to prevent possible cystic duct laceration or perforation. However, a cystic duct balloon for dilation is under development. If successful, it may overcome the bottleneck of the cystic duct and allow smooth entry of SOC. One of the patients did not achieve clinical success with SOC and subsequently underwent PTGD treatment with symptom relief.

No adverse events such as bleeding, perforation, or bile leakage were noted in any patient. There were three cases of mild cholangitis, and five cases of mild pancreatitis after the procedure, which are also conventional complications of ERCP. After the acute event improved, we placed an indwelling double pigtail stent into the gallbladder for drainage. It is generally recommended that it be drained for 3 months and up to 6 months. After 3 months, telephone follow-up of our patient was performed and clinical symptoms were observed and discussed. Ultrasound was also performed to observe the gallbladder and bile ducts, and the double pigtail stent was removed by endoscopic examination. (That typically is done at between 3 to 6 months, depending on a patient's condition.) In our patient, no recurrence of cholecystitis symptoms occurred during 2 to 18 months (12.8 ± 3.9) of follow-up.

Discussion

The treatment of common bile duct stones has gradually transitioned from traditional open to minimally invasive laparoscopic lithotomy to ERCP [6]. With the rapid development of ultrasound interventional technology, PTGD is becoming a safe and effective treatment modality for patients with acute cholecystitis [7]. However, surgical intervention is still required for the treatment of common bile duct stones. The current clinical success rate for PTGD is between 80% and 96%, and the complication rate after PTGD ranges between 4% and 17% [4, 5, 6, 7, 8]. The main complications after PTGD include biliary bleeding,

pneumothorax, biliary leakage, intra-abdominal abscess, intestinal perforation, drainage tube detachment, and duct blockage [8]. In addition, the routine drainage tube placement time after PTGD surgery is about 4 weeks, and the puncture point remains prone to infection, requiring regular dressing changes, which affects the quality of a patient's life.

A recent study by Storm et al. suggested ERCP stenting of the gallbladder as the first-line treatment for patients with acute cholecystitis who are not suitable candidates for cholecystectomy, with a technical success rate of 96% and a clinical success rate of 100% [9]. However, a traditional ERCP procedure requires long exposure to x-ray. The novel SOC system allows direct observation of the biliary tract through a digital visualization system without x-ray guidance, making it especially useful for pregnant women and for the specific populations who should not be exposed to x-rays, such as couples who are planning to conceive in near future.

At present, cholangioscopy has been widely used in the management of biliary diseases. In this study, we introduce the use of a novel SOC system for acute cholecystitis, which includes irrigation of the gallbladder under direct visualization. We also explored the effectiveness and safety of the novel SOC system along with ERCP for the treatment of acute cholecystitis secondary to choledocholithiasis. This technique is designed for patients with acute cholecystitis secondary to common bile duct stones because it can simultaneously solve the problem of the common bile duct stones and acute cholecystitis. There was an immediate decrease in postoperative CRP and a significant recovery of inflammatory indexes after the procedure. The traditional treatment option for acute cholecystitis secondary to common bile duct stones was surgery, in which the gallbladder was removed and a common bile ductotomy was performed to remove the stones. EyeMax cholangioscopy is a minimally invasive procedure to treat acute cholecystitis under direct visualization. It not only quickly relieved the symptoms of acute cholecystitis, but also allowed examination of the inner wall of the gallbladder. Therefore, the EyeMax cholangioscope has both diagnostic and therapeutic value similar to the spy-glass cholangioscope used in endoscopic retrograde appendicitis therapy for the management of acute appendicitis especially caused by obstruction [10].

However, technical difficulties in entering to the gallbladder through the spiral structure of the cystic duct remain and add to the overall procedure time. However, with further advances in technology and experience, these technical challenges are expected to be overcome or reduced.

Conclusions

In conclusion, ERCP+SOC may provide a feasible, safe, and effective alternative treatment for acute cholecystitis secondary to choledocholithiasis. ERCP + SOC was able to simultaneously resolve both biliary tract and gallbladder problems via natural orifice endoscopy. Its advantages include no skin wound, reduced postoperative pain, quick recovery, limited or no exposure to x-rays, and a short hospital stay.

Conflict of Interest

The authors declare that they have no conflict of interest.

Funding

Jilin Province Health Science and Technology Capacity Improvement Program 2021LC120

Jilin Medical and Health Guidance Program 20210409008

References

- [1] Fu Y, Pang L, Dai W et al. Advances in the study of acute acalculous cholecystitis: a comprehensive review. *Dig Dis* 2022; 40: 468–478 doi:10.1159/000520025
- [2] Loozen CS, Oor JE, van Ramshorst B et al. Conservative treatment of acute cholecystitis: a systematic review and pooled analysis. *Surg Endosc* 2017; 31: 504–515 doi:10.1007/s00464-016-5011-x
- [3] Pisano M, Allievi N, Gurusamy K et al. 2020 World Society of Emergency Surgery updated guidelines for the diagnosis and treatment of acute calculus cholecystitis. *World J Emerg Surg* 2020; 15: 61 doi:10.1186/s13017-020-00336-x
- [4] Nassar A, Elshahat I, Forsyth K et al. Outcome of early cholecystectomy compared to percutaneous drainage of gallbladder and delayed cholecystectomy for patients with acute cholecystitis: systematic review and meta-analysis. *HPB (Oxford)* 2022; 24: 1622–1633
- [5] Navaneethan U, Hasan MK, Kommaraju K et al. Digital, single-operator cholangiopancreatography in the diagnosis and management of pancreatobiliary disorders: a multicenter clinical experience (with video). *Gastrointest Endosc* 2016; 84: 649–655
- [6] Lyu Y, Cheng Y, Li T et al. Laparoscopic common bile duct exploration plus cholecystectomy versus endoscopic retrograde cholangiopancreatography plus laparoscopic cholecystectomy for cholecystocholedocholithiasis: a meta-analysis. *Surg Endosc* 2019; 33: 3275–3286 doi:10.1007/s00464-018-06613-w
- [7] Verma N, Hema HK, Gupta P et al. Role of percutaneous transhepatic biliary drainage as an adjunct to endoscopic retrograde cholangiopancreatography. *J Clin Exp Hepatol* 2022; 12: 287–292 doi:10.1016/j.jceh.2021.09.002
- [8] Turan AS, Jenniskens S, Martens JM et al. Complications of percutaneous transhepatic cholangiography and biliary drainage, a multicenter observational study. *Abdom Radiol (NY)* 2022; 47: 3338–3344 doi:10.1007/s00261-021-03207-4
- [9] Storm AC, Vargas EJ, Chin JY et al. Transpapillary gallbladder stent placement for long-term therapy of acute cholecystitis. *Gastrointest Endosc* 2021; 94: 742–748.e1
- [10] Kong LJ, Liu D, Zhang JY. Digital single-operator cholangioscope for endoscopic retrograde appendicitis therapy. *Endoscopy* 2022; 54: 396–400 doi:10.1055/a-1490-0434