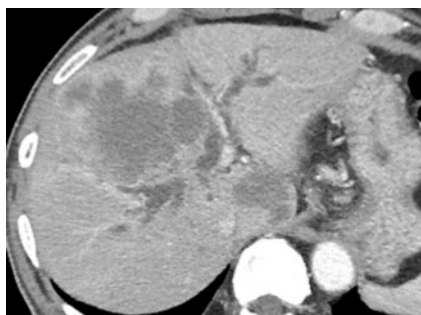
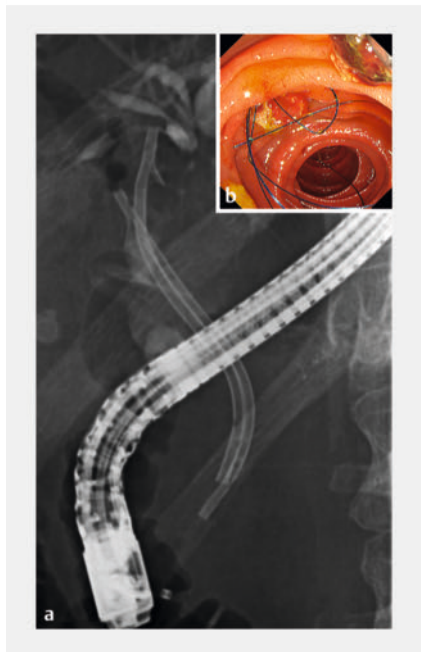

A stent-removing thread sticking adjacent to the duodenoscope elevator identified using the double-scope technique ▶

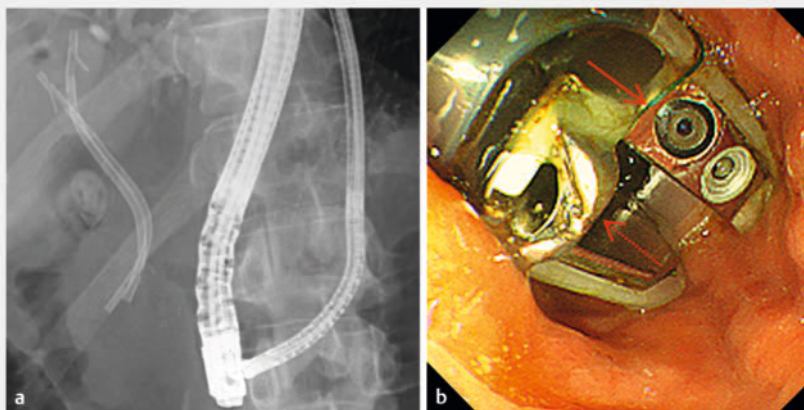
OPEN
ACCESS



▶ **Fig. 1** Abdominal computed tomography. Computed tomography revealed bilateral dilated intrahepatic bile ducts caused by gallbladder cancer, which also invaded the right lobe.



▶ **Fig. 2** Fluoroscopic image with a duodenoscopic view after inside plastic stent deployment. **a** Fluoroscopic image demonstrating double-inside plastic stent indwelling at the hilar stricture in a side-by-side position. **b** In the duodenoscopic view, four removal threads of the plastic stents were washed into the appropriate lumen.



▶ **Fig. 3** An ultra-slim endoscope confirms the locked removing thread beside the fixed elevator. **a** Fluoroscopic image demonstrating rendezvous of the duodenoscope and ultra-slim scope. **b** In the ultra-slim endoscopic view, the thread was visibly locked beside the lifted and fixed elevator. The solid red arrow indicates an impacted thread. The red dotted arrow indicates an elevator.

Plastic stents (PSs) are used in patients with malignant hilar obstruction (MHO), considering patient life expectancy and reintervention [1,2]. Some PSs are designed for suprapapillary stenting and are equipped for thread removal for reintervention [3]. Here, we present a case that illustrates rare problems caused by the removal of the thread adhering to the duodenoscope elevator identified using the double-scope technique [4].

A 65-year-old man with Bismuth type I MHO due to unresectable gallbladder cancer (▶ **Fig. 1**) underwent suprapapillary stenting in a side-by-side fashion using a dedicated PS (Through & Pass, 7F Inside Stent; Gadelius Medical, Tokyo, Japan) (▶ **Fig. 2a**, ▶ **Fig. 2b**, ▶ **Video 1**). The duodenoscope (TJF-Q290V; Olympus, Tokyo, Japan) was extubated after we washed the removing threads out of the scope channel. However, extubation suddenly became disrupted in the stomach (▶ **Video 1**). To identify the cause, a second ultra-slim esophagogastroduodenoscope was inserted along the duodenoscope. We determined that the

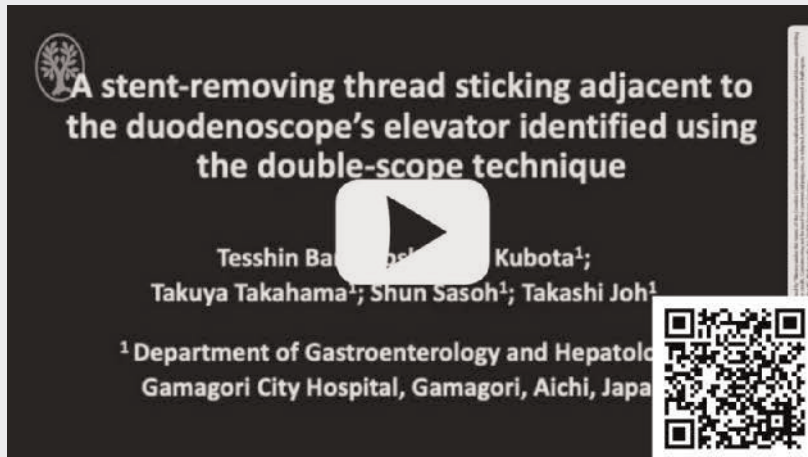thread jammed beside the immobile elevator in the lifted position (▶ **Fig. 3a**, ▶ **Fig. 3b**, ▶ **Video 1**). Finally, repetitive striking of the lifted elevator with a cannula loosened the fixed elevator and released the thread (▶ **Video 1**).

During the release of the stent-removing threads, these threads potentially fall into the slit between the scope elevator and side wall. If the operator lifts the elevator in this position, the thread jams tightly in the slit (▶ **Video 1**), which disrupts scope extubation. In this situation, we must avoid pulling the scope violently; otherwise, the impacted thread tears the papilla and duodenum upward. This event develops outside the duodenoscope view; therefore, in cases of incomprehensible disruption of scope extubation, the double-scope technique will clarify the reason.

Conflict of Interest

The authors declare that they have no conflict of interest.

VIDEO



► **Video 1** A stent-removing thread sticking adjacent to the duodenoscope elevator identified using the double-scope technique.

Bibliography

Endosc Int Open 2024; 12: E269–E270

DOI 10.1055/a-2238-1054

ISSN 2364-3722

© 2024. The Author(s).

This is an open access article published by Thieme under the terms of the Creative Commons Attribution-NonDerivative-NonCommercial License, permitting copying and reproduction so long as the original work is given appropriate credit. Contents may not be used for commercial purposes, or adapted, remixed, transformed or built upon. (<https://creativecommons.org/licenses/by-nc-nd/4.0/>)

Georg Thieme Verlag KG, Rüdigerstraße 14, 70469 Stuttgart, Germany



The authors

Tesshin Ban¹, **Yoshimasa Kubota**¹, **Takuya Takahama**¹, **Shun Sasoh**¹, **Takashi Joh**¹

¹ Department of Gastroenterology and Hepatology, Gamagori City Hospital, Gamagori, Japan

Corresponding author

Dr. Tesshin Ban

Gamagori City Hospital, Department of Gastroenterology and Hepatology, Gamagori, Japan
venzosan0204@gmail.com

References

- [1] Qumseya BJ, Jamil LH, Elmunzer BJ et al. ASGE guideline on the role of endoscopy in the management of malignant hilar obstruction. *Gastrointest Endosc* 2021; 94: 1–2 .e22
- [2] Dumonceau JM, Tringali A, Papanikolaou IS et al. Endoscopic biliary stenting: indications, choice of stents, and results: European Society of Gastrointestinal Endoscopy (ESGE) Clinical Guideline – Updated October 2017. *Endoscopy* 2018; 50: 910–930 doi:10.1055/a-0659-986430086596
- [3] Ishiwatari H, Hayashi T, Ono M et al. Newly designed plastic stent for endoscopic placement above the sphincter of Oddi in patients with malignant hilar biliary obstruction. *Dig Endosc* 2013; 25: 94–99
- [4] Nagatomo S, Minoda Y, Ihara E. Double scope recovery technique to manage procedure-related trouble during wire trimming with a Loop cutter. *Dig Endosc* 2021; 33: e83–e84 doi:10.1111/den.1395433710664