

Risk factors of early adverse events associated with endoscopic ultrasound-guided hepaticogastrostomy using self-expandable metal stent



Authors

So Nakaji^{1,2}, Hirokazu Takahashi², Wataru Yoshioka¹, Toshiyasu Shiratori¹, Shigenobu Yoshimura¹, Natsuki Kawamitsu¹, Akiko Tomonari³

Institutions

- 1 Gastroenterology, Kameda Medical Center, Kamogawa, Japan
- 2 Department of Metabolism and Endocrinology, Saga Medical School Faculty of Medicine, Saga University, Saga, Japan
- 3 Department of Gastroenterology, ParkwayHealth China, Shanghai, China

Keywords

Biliary tract, Intervention EUS, Endoscopic ultrasonography, Pancreas

received 9.10.2023

accepted after revision 4.1.2024

accepted manuscript online 08.01.2024

Bibliography

Endosc Int Open 2024; 12: E164–E175

DOI 10.1055/a-2240-1100

ISSN 2364-3722

© 2024. The Author(s).

This is an open access article published by Thieme under the terms of the Creative Commons Attribution-NonDerivative-NonCommercial License, permitting copying and reproduction so long as the original work is given appropriate credit. Contents may not be used for commercial purposes, or adapted, remixed, transformed or built upon. (<https://creativecommons.org/licenses/by-nc-nd/4.0/>)

Georg Thieme Verlag KG, Rüdigerstraße 14,
70469 Stuttgart, Germany

Corresponding author

Dr. So Nakaji, Kameda Medical Center, Gastroenterology,
Kamogawa, Japan
nakajisou1978@yahoo.co.jp

ABSTRACT

Background and study aims This retrospective study aimed to investigate risk factors for early adverse events (AEs) associated with endoscopic ultrasonography-guided hepaticogastrostomy (EUS-HGS) using self-expandable metal stents (SEMS).

Patients and methods The clinical success rate, technical success rate, and early AEs were assessed at two hospitals from 2010 to 2022. The analysis focused on risk factors associated with cholangitis, peritonitis, and SEMS migration.

Results Technical success was achieved in all cases (94/94), and clinical success was 96.8% (91/94). Post-procedural acute cholangitis occurred in 12.8% of cases (12/94). However, no statistically significant risk factors were identified for cholangitis or biliary tract infection. Peritonitis occurred in only 2.1% of cases (2/94). Univariate analysis, using a 1.5 cm cut-off for the distance between the liver and gastrointestinal tract, revealed significant risk factors: braided-type SEMS, bile duct diameter (especially >4 mm), 6 mm diameter SEMS, and tract dilation ($P=0.001$, $P=0.020$, $P=0.023$, and $P=0.046$, respectively). Adjusting the cut-offs to 2 cm underscored braided-type SEMS and tract dilation as risk factors ($P=0.002$ and $P=0.046$, respectively). With 2.5-cm cut-offs, only braided-type SEMS remained significant ($P=0.018$). Mortality within 14 and 30 days following EUS-HGS was 5.3% (5/94) and 16.0% (15/94), respectively.

Conclusions EUS-HGS using SEMS demonstrated high technical and clinical success rates. Laser-cut SEMS may be superior in preventing early AEs.

Introduction

Transpapillary bile duct drainage with endoscopic retrograde cholangiopancreatography (ERCP) is widely used in the treatment of obstructive jaundice. However, in daily practice, we sometimes encounter cases in which cannulation of the bile

duct is difficult, or in which the papilla cannot be reached after gastrointestinal tract reconstruction or due to tumor invasion. For such cases, percutaneous transhepatic bile duct drainage (PTBD) or surgery has traditionally been the alternative. With the development of endoscopic ultrasonography (EUS), EUS-guided biliary drainage (EUS-BD) was first reported by Giovan-

nini et al.[1] in 2001, in which the bile duct is approached and drained via the transgastrointestinal tract under EUS guidance. Since the publication of this report, various techniques for EUS-BD have been reported. Currently, EUS-guided hepaticogastrostomy (EUS-HGS), in which the bile ducts are drained transgastroically for biliary decompression, has become the mainstream procedure and is a new treatment option along with PTBD and surgical drainage for patients who are unable to undergo conventional biliary drainage by ERCP.

More recently, EUS-HGS has been performed not only in cases in which transpapillary drainage is difficult [2,3], but also as a first-line option as a treatment for malignant hilar bile duct obstruction [4,5,6]. Although this procedure is becoming increasingly popular especially at advanced facilities, it is still in its infancy, and many issues remain to be resolved, such as standardization of the procedure and measures to prevent adverse events (AEs). While high technical and clinical success rates have been reported, fatal AEs have also been reported [7]. To date, there have been reports of various procedure-related AE, but few have examined in detail patient characteristics and procedure details regarding risk factors for AEs. We, therefore, conducted a retrospective study to identify risk factors for early AEs associated with EUS-HGS using self-expandable metal stent (SEMS).

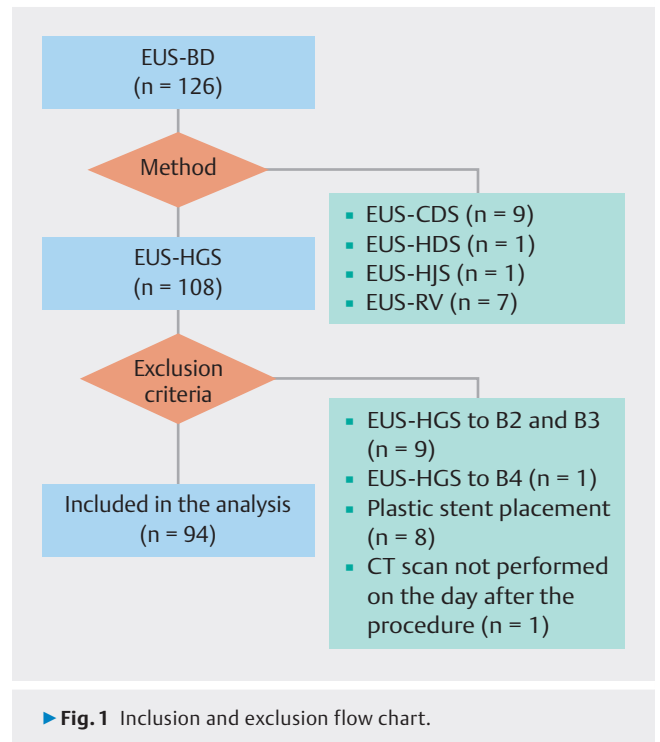
Patients and methods

Ethics statement

This study received ethics approval from the research ethics committee of each hospital involved (Registration number: 22-070 and 2023-03-04). Written informed consent for EUS-BD was obtained from each patient before the procedure, and consent for the use of data for research was obtained on an opt-out basis.

Patient recruitment and data collection

We retrospectively reviewed the medical records of patients who underwent EUS-BD at two hospitals from January 2010 to September 2022. First, we excluded cases in which EUS-choledochoduodenostomy (CDS), EUS-guided hepaticoduodenostomy (EUS-HDS), EUS-guided hepaticojejunostomy (EUS-HJS), and EUS-rendezvous (RV) were excluded. Next, cases performed simultaneously to both B2 and B3, performed to bile ducts other than B2 or B3, a plastic stent (PS) was placed, or a computed tomography (CT) scan was not performed the day after the procedure were omitted (► Fig. 1). After enrollment in our study, the following data were collected from each patient: age, sex, location of obstruction, the presence or absence of cholangitis within 14 days before EUS-HGS, and history of upper abdominal surgery. Concerning EUS-HGS procedures, the following data were collected: timing of the procedure (first-line or second-line), target bile duct, diameter of bile duct, distance of puncture route in the liver, total number of punctures, total number of device exchanges, with or without electrocautery dilation, type of SEMS, diameter of SEMS, and procedure time. In addition, the findings from the following day's CT scan were used to determine the distance between



the liver and gastrointestinal tract, free air, bile leakage, hemorrhage, and contrast medium residual in peripheral bile duct.

EUS-HGS procedure and endoscopist experience

Regarding the indication for EUS-HGS, in the early days of introduction of EUS-HGS, we performed the procedure only in cases in which biliary drainage under ERCP was not possible. In recent years, however, the indication has been expanded to include cases in which duodenal stenosis is expected to occur, cases after gastrointestinal reconstruction, and cases of malignant hilar biliary obstruction.

EUS-HGS was carried out under conscious sedation with monitoring of patient respiratory and circulatory dynamics. A curvilinear echoendoscope (GF-UCT240-AL5 or GF-UCT260; Olympus Medical Systems, Tokyo, Japan) and an ultrasound processor (EU-ME2 or EU-ME2 PREMIER PLUS; Olympus Medical Systems) were used. The puncture procedure was performed using a 19-G needle (Expect; Boston Scientific Corporation, Massachusetts, United States, or EZ Shot 3 Plus; Olympus Medical Systems, or SonoTip Pro Control; Medi-Globe GmbH, Rosenheim, Germany). Regarding dilation techniques, blunt dilation was performed using a double-lumen cannula (Uneven Double Lumen Cannula; PIOLAX, Kanagawa, Japan), a 4F tapered tip cannula (StarTip V; Olympus Medical Systems), or a dilation catheter (ES Dilator; Zeon Medical, Tokyo, Japan.). Balloon dilation was performed using a 4-mm balloon catheter (REN biliary balloon catheter; KANEKA, Osaka, Japan), and electrocautery dilation was performed using Cysto-Gastro-Set (EndoFlex GmbH, Voerde, Germany). SEMS used were 6 or 8 mm in diameter, both 12 cm in length, end-bear partially covered types (Niti-S S-type biliary stent or Spring Stopper; braided type, Tae-

woong Medical, Seoul, Korea, or Covered BileRush Advance; laser-cut type, PIOLAX).

All EUS-HGS procedures were carried out by dedicated pancreaticobiliary endoscopists experienced with over 500 ERCPs and 200 EUS fine-needle aspiration procedures after obtaining written informed consent from patients.

Data analyses and outcome measures

First, the clinical success rate, technical success rate, and early AEs that occurred within 14 days were examined in the eligible cases. Mortality was assessed at two time points: 14 and 30 days after the procedure. Next, risk factors associated with acute cholangitis and biliary peritonitis were examined as main AEs. And finally, factors associated with stent migration into the peritoneal cavity were investigated by analyzing the relationship between the distance from the gastrointestinal tract to the liver assessed by CT on the following day and patient or procedure factors.

All statistical analyses were performed using R version 4.1.0. Continuous variables were compared using the Wilcoxon rank sum test, whereas categorical variables were analyzed using the Fisher's exact test. $P < 0.05$ was considered statistically significant. For effect sizes, odds ratios (ORs) and their 95% confidence intervals (CI) were calculated for continuous variables. For continuous variables, Cohen's *d* was calculated, and the following criteria were used to interpret the effect size: values less than 0.2 were considered small, between 0.2 and 0.5 were considered small to medium, between 0.5 and 0.8 were considered medium, greater than 0.8 were considered large.

Definitions

Technical success was defined as placement of a stent in the target bile duct, while a post-procedure (within 2–4 weeks) reduction in bilirubin of 50% to 75% from pre-procedure values was defined as clinical success [8].

Regarding AEs, fever was defined as a temperature of 37.5°C or higher, and abdominal pain was defined as new or increased need for analgesics after the procedure. The diagnosis of acute cholangitis was made according to Tokyo guidelines. Biliary peritonitis was defined as abdominal pain and bile leak was confirmed by CT. Procedure time was defined as the duration from the time the endoscope screen was switched to the ultrasound image after insertion of the echoendoscope into the stomach to the time when stent placement was completed.

Results

During the study period, EUS-BD was conducted in 126 cases. EUS-HGS was performed in 101 cases, excluding 25 cases that met the exclusion criteria (EUS-CDS, $n=9$; EUS-HDS, $n=1$; EUS-HJS, $n=1$; and EUS-RV, $n=7$). After excluding 14 cases (EUS-HGS to B2 and B3 [$n=4$], B4 [$n=1$], PS placement [$n=8$], and CT scan not performed on the day after the procedure [$n=1$]), analyses were performed on 94 EUS-HGS cases (► **Fig. 1**). Patient characteristics and endoscopic procedures are summarized in ► **Table 1**. Clinical outcomes and all AEs are shown in ► **Table 2**. The technical success rate was 100% (94/94), while

► **Table 1** Patient characteristics and endoscopic procedures.

	Level	Overall
		n = 94
Age (mean (SD))		74.4 (12.1)
Sex (%)	F	44 (46.8)
	M	50 (53.2)
Location of obstruction (%)	Distal	56 (59.6)
	Hilar	38 (40.4)
Cholangitis within 14 days before EUS-HGS (%)	–	57 (60.6)
	+	37 (39.4)
History of upper abdominal surgery (%)	Cholecystectomy	5 (5.3)
	Gastrectomy	9 (9.6)
	Gastrectomy + others	1 (1.1)
	Others	23 (24.5)
	PD	6 (6.4)
	None	50 (53.2)
Timing (%)	First-line	35 (37.2)
	Second-line	59 (62.8)
Method of EUS-BD (%)	HGS	75 (79.8)
	HGS + AGS	14 (14.9)
	HGS + bridging	5 (5.3)
Puncture site (%)	Esophagus	2 (2.1)
	Stomach	92 (97.9)
Target bile duct (%)	B2	29 (30.9)
	B3	65 (69.1)
Diameter of bile duct (mm) (mean (SD))		5.8 (2.5)
Distance of puncture route in liver (cm) (mean (SD))	2.5 (2.4)	
Procedural time (min.) (mean (SD))		48.4 (26.3)
Number of punctures (mean (SD))		1.4 (0.9)
Balloon dilation (%)	–	89 (94.7)
	+	5 (5.3)
Electrocautery dilation (%)	–	88 (93.6)
	+	6 (6.4)
Type of SEMS (%)	Braided type	79 (84.0)
	Laser-cut type	15 (16.0)
Diameter of SEMS (mm) (%)	6	51 (54.3)
	8	43 (45.7)
Total number of device exchanges (mean (SD))		2.4 (0.9)

EUS-HGS, endoscopic ultrasound-guided hepaticogastrostomy; PD, pancreaticoduodenectomy; AGS, antegrade stenting; SEMS, self-expandable metal stent.

► **Table 2** Clinical outcomes and AEs.

	n = 94
Technical success (%)	94 (100.0)
Clinical success (%)	91 (96.8)
Clinical symptoms occurring within 14 days after EUS-HGS	26 (27.7)
Fever (%)	20 (21.2)
Abdominal pain (%)	11 (11.7)
Clinical diagnoses of total AEs related to EUS-HGS	30 (31.9)
AEs directly related to EUS-HGS	
Acute cholangitis (%)	12 (12.8)
Bacteremia (%)	9 (9.6)
Biliary peritonitis (%)	2 (2.1)
Bleeding (%)	2 (2.1)
Liver abscess (%)	1 (1.0)
Biliary tract infection (Cholangitis or Bacteremia or Liver abscess) (%)	18 (19.1)
AEs indirectly related to EUS-HGS	
Lethal arrhythmia (%)	2 (2.1)
Cerebral infarction (%)	1 (1.0)
Pulmonary embolism (%)	2 (2.1)
CRBSI (%)	1 (1.0)
Death within 14 days after EUS-HGS (%)	5 (5.3)
Lethal arrhythmia (%)	2 (2.1)
Cerebral infarction (%)	1 (1.0)
Cancer aggravation (%)	2 (2.1)
Death within 30 days after EUS-HGS (%)	15 (16.0)
Lethal arrhythmia (%)	2 (2.1)
Cerebral infarction (%)	1 (1.0)
Cancer aggravation (%)	12 (12.8)

AE, adverse event; EUS-HGS, endoscopic ultrasound-guided hepaticogastrostomy; CRBSI, catheter-related bloodstream infection.

the clinical success rate was 96.8% (91/94). Within 14 days after EUS-HGS, 20 of 94 patients (21.2%) experienced fever, and 11 of 94 patients (11.7%) reported abdominal pain. Clinical diagnoses of AEs directly related to EUS-HGS were acute cholangitis in 12.8% (12/94), liver abscess in 1.0% (1/94), biliary peritonitis in 2.1% (2/94), bacteremia in 9.6% (9/94), and bleeding in 2.1% (2/94) (including duplicate cases). When acute cholangitis, bacteremia, and liver abscess were combined as biliary tract infections, the overall frequency was 19.1% (18/94). All the cases could be treated conservatively and did not require additional invasive treatment. On the other hand, AEs not directly related to EUS-HGS were lethal arrhythmia in 2.1% (2/94), cerebral infarction in 1.0% (1/94), pulmonary embolism in 2.1% (2/94), and catheter-related bloodstream infection in 1.0% (1/94).

► **Table 3** CT findings on the day after EUS-HGS.

	Overall
	n = 94
Distance between liver and gastrointestinal tract (cm) (mean (SD))	1.5 (1.4)
Bile leakage (%)	2 (2.1)
Hemorrhage (%)	0 (0.0)
Free air (%)	7 (7.4)
Contrast medium residual in peripheral bile duct (%)	10 (10.6)

CT, computed tomography; EUS-HGS, endoscopic ultrasound-guided hepaticogastrostomy; SD, standard deviation.

Death occurred within 14 days after EUS-HGS in 5.3% (5/94). The causes of death were lethal arrhythmia in 2.1% (2/94), cerebral infarction in 1.0% (1/94), and cancer aggravation in 2.0% (2/94). CT findings on the day after EUS-HGS are summarized in ► **Table 3**. Among the seven cases with evidence of free air, one presented with fever, while the other two exhibited abdominal pain. The patient with fever was also diagnosed with cholangitis. All cases showed rapid improvement with conservative treatment.

Regarding risk factors, no statistically significant risk factors were identified in 12 cases (12.8%) of acute cholangitis and 18 cases (19.1%) of biliary tract infection (► **Table 4**). The incidence of peritonitis following the procedure was only 2.1% (2/94), which limited our ability to conduct detailed statistical analyses on its causes (► **Table 5**). Univariate analysis, employing a cut-off value of 1.5 cm for the distance between the liver and gastrointestinal tract as a surrogate marker for SEMS migration into the abdominal cavity, revealed several statistically significant risk factors. Specifically, braided-type SEMS, bile duct diameter (especially >4 mm), 6-mm diameter SEMS, and tract dilation exhibited statistical significance ($P=0.001$, $P=0.020$, $P=0.023$, and $P=0.046$, respectively). Adjusting the cut-offs to 2 cm underscored braided-type SEMS and tract dilation as risk factors ($P=0.002$ and $P=0.046$, respectively). With cut-offs set at 2.5 cm, only braided-type SEMS remained a statistically significant risk factor ($P=0.018$) (► **Table 6**).

Discussion

This large retrospective study, detailing the outcomes of EUS-HGS using SEMS exclusively, demonstrated a remarkable technical success rate of 100% (94/94) and a clinical success rate of 96.8% (91/94). However, it is crucial to acknowledge that 27.7% of patients (26/94) experienced clinical symptoms such as fever and abdominal pain, and the overall AE rate within 14 days after the procedure was relatively high at 33.0% (31/94). Notably, AEs directly linked to the procedure were effectively managed conservatively, indicating that the procedure safety profile extends beyond the incidence rates. It is imperative to emphasize that the mere incidence of AEs should not be solely relied upon to label the procedure as excessively dangerous.

► **Table 4** Risk factors for cholangitis and biliary tract infection associated with EUS-HGS.

	Level	Cholangitis		P value	Effect size (95%CI)	Biliary tract infection		P value	Effect size (95%CI)
		-	+			-	+		
n		82	12			76	18		
Age (median [IQR])		77.0 [69.0, 84.0]	73.0 [67.8, 83.8]	0.982	0.002 (-0.612, 0.616)	77.0 [68.5, 84.0]	75.0 [68.8, 84.5]	0.806	-0.084 (-0.605, 0.437)
Sex (%)	F	37 (45.1)	7 (58.3)	0.584		35 (46.1)	9 (50.0)	0.969	
	M	45 (54.9)	5 (41.7)		0.591 (0.136, 2.367)	41 (53.9)	9 (50.0)		1.621 (0.577, 4.555)
Location of obstruction (%)	Distal	51 (62.2)	5 (41.7)	0.299		47 (61.8)	9 (50.0)	0.513	
	Hilar	31 (37.8)	7 (58.3)		2.282 (0.567, 9.970)	29 (38.2)	9 (50.0)		1.862 (0.646, 5.364)
Cholangitis within 14 days before EUS-HGS (%)	-	52 (63.4)	5 (41.7)	0.261		46 (60.5)	11 (61.1)	1	
	+	30 (36.6)	7 (58.3)		2.403 (0.596, 10.511)	30 (39.5)	7 (38.9)		0.976 (0.340, 2.798)
History of upper abdominal surgery (%)	-	46 (56.1)	4 (33.3)	0.243		44 (57.9)	6 (33.3)	0.106	
	+	36 (43.9)	8 (66.7)		2.530 (0.618, 12.421)	32 (42.1)	12 (66.7)		2.750 (0.933, 8.102)
Target bile duct (%)	B2	23 (28.0)	6 (50.0)	0.229		22 (28.9)	7 (38.9)	0.591	
	B3	59 (72.0)	6 (50.0)		0.394 (0.094, 1.639)	54 (71.1)	11 (61.1)		0.640 (0.220, 1.865)
Diameter of bile duct (mm) (median [IQR])		5.2 [4.1, 7.0]	5.0 [4.7, 5.6]	0.843	-0.005 (-0.620, 0.608)	5.2 [4.1, 7.1]	5.0 [4.4, 5.4]	0.61	0.103 (-0.417, 0.624)
Cut-off value = 4 (%)	≤4	19 (23.2)	0 (0.0)	0.138		17 (22.4)	2 (11.1)	0.457	
	<4	63 (76.8)	12 (100.0)		∞ (0.747, ∞)	59 (77.6)	16 (88.9)		2.305 (0.482, 11.034)
Cut-off value = 5 (%)	≤5	38 (46.3)	7 (58.3)	0.64		34 (44.7)	11 (61.1)	0.323	
	<5	44 (53.7)	5 (41.7)		0.620 (0.143, 2.485)	42 (55.3)	7 (38.9)		0.583 (0.201, 1.692)
Cut-off value = 6 (%)	≤6	54 (65.9)	10 (83.3)	0.378		49 (64.5)	15 (83.3)	0.207	
	<6	28 (34.1)	2 (16.7)		0.389 (0.039, 2.014)	27 (35.5)	3 (16.7)		0.363 (0.096, 1.366)
Distance of puncture route in liver (cm) (median [IQR])	2.0 [1.6, 2.6]	2.1 [1.8, 2.4]	0.937	-0.193 (-0.807, 0.422)	2.1 [1.6, 2.6]	2.0 [1.7, 2.5]	0.927	-0.144 (-0.665, 0.377)	
Cut-off value = 1.5 (%)	≤1.5	18 (22.0)	3 (25.0)	1		17 (22.4)	4 (22.2)	1	
	<1.5	64 (78.0)	9 (75.0)		0.845 (0.184, 5.357)	59 (77.6)	14 (77.8)		1.088 (0.293, 3.468)

► **Table 4** (Continuation)

	Level	Cholangitis		P value	Effect size (95%CI)	Biliary tract infection		P value	Effect size (95%CI)
		-	+			-	+		
Cut-off value = 2 (%)	≤2	41 (50.0)	6 (50.0)	1	1.000 (0.248, 4.084)	37 (48.7)	10 (55.6)	0.793	0.759 (0.270, 2.132)
	<2	41 (50.0)	6 (50.0)			39 (51.3)	8 (44.4)		
Cut-off value = 2.5 (%)	≤2.5	60 (73.2)	10 (83.3)	0.689	0.549 (0.054, 2.884)	56 (73.7)	14 (77.8)	0.954	0.800 (0.236, 2.718)
	2.5<	22 (26.8)	2 (16.7)			20 (26.3)	4 (22.2)		
Procedural time (min.) (median [IQR])		43.0 [32.2, 60.0]	35.0 [30.2, 37.2]	0.051	-0.584 (-1.204, 0.036)	43.0 [32.0, 60.0]	37.0 [31.2, 46.8]	0.293	0.253 (-0.269, 0.775)
Total number of punctures (median [IQR])		1.0 [1.0, 2.0]	1.0 [1.0, 1.0]	0.19	-0.335 (-0.951, 0.280)	1.0 [1.0, 2.0]	1.0 [1.0, 1.0]	0.467	-0.011 (-0.532, 0.510)
Type of SEMS (%)	Braided type	68 (82.9)	11 (91.7)	0.726	0.446 (0.010, 3.550)	63 (82.9)	16 (88.9)	0.79	0.606 (0.124, 2.960)
	Laser-cut type	14 (17.1)	1 (8.3)			13 (17.1)	2 (11.1)		
Diameter of SEMS (mm) (%)	6	42 (51.2)	9 (75.0)	0.217	0.354 (0.057, 1.551)	40 (52.6)	11 (61.1)	0.699	0.707 (0.248, 2.019)
	8	40 (48.8)	3 (25.0)			36 (47.4)	7 (38.9)		
Total number of device exchanges (median [IQR])		2.0 [2.0, 3.0]	2.0 [2.0, 2.0]	0.13	0.469 (-0.149, 1.087)	2.0 [2.0, 3.0]	2.0 [2.0, 2.0]	0.279	0.264 (-0.258, 0.786)
Cut-off value = 1 (%)	1 (Without dilation)	12 (14.6)	2 (16.7)	1	0.857 (0.167, 4.406)	12 (15.8)	2 (11.1)	0.894	1.500 (0.305, 7.385)
	≤2	70 (85.4)	10 (83.3)			64 (84.2)	16 (88.9)		
Cut-off value = 2 (%)	≤2	47 (57.3)	10 (83.3)	0.16	0.269 (0.055, 1.304))	43 (56.6)	14 (77.8)	0.165	0.372 (0.112, 1.236))
	≤3	35 (42.7)	2 (16.7)			33 (43.4)	4 (22.2)		
Cut-off value = 3 (%)	≤3	72 (87.8)	12 (100.0)	0.436	0.276 (0.152, 5.018)	67 (88.2)	17 (94.4)	0.724	0.438 (0.052, 3.698)
	≤4	10 (12.2)	0 (0.0)			9 (11.8)	1 (5.6)		
Contrast medium residual in peripheral bile duct (%)	-	72 (87.8)	12 (100.0)	0.436	0.276 (0.152, 5.018)	68 (89.5)	16 (88.9)	1	1.062 (0.206, 5.491)
	+	10 (12.2)	0 (0.0)			8 (10.5)	2 (11.1)		

EUS-HGS, endoscopic ultrasound-guided hepaticogastrostomy; SEMS, self-expandable metal stent; IQR, interquartile range.

Comparative analysis with existing studies involving more than 50 cases of EUS-HGS reveals varying incidence rates for AEs, including peritonitis (or abdominal pain), cholangitis (or

sepsis, bacteremia, or transient fever), hemorrhage, and liver abscess, ranging from 1.1% to 24%, 2.1% to 24%, 0.9% to 6.3%, and 0.9% to 1.8%, respectively [9, 10, 11, 12, 13]. However, it is

► **Table 5** Risk factors for peritonitis associated with EUS-HGS.

	Level	Biliary peritonitis		P value	Effect size (95%CI)
		-	+		
n		92	2		
Age (median [IQR])		76.5 [67.8, 84.0]	82.5 [81.2, 83.8]	0.339	0.682 (-0.7401, 2.105)
Sex (%)	F	42 (45.7)	2 (100.0)	0.419	0 (0, 4.663)
	M	50 (54.3)	0 (0.0)		
Location of obstruction (%)	Distal	55 (59.8)	1 (50.0)	1	1.480 (0.018, 118.663)
	Hilar	37 (40.2)	1 (50.0)		
Cholangitis within 14 days before EUS-HGS (%)	-	56 (60.9)	1 (50.0)	1	1.548 (0.019, 124.131)
	+	36 (39.1)	1 (50.0)		
History of upper abdominal surgery (%)	-	49 (53.3)	1 (50.0)	1	1.138 (0.142, 91.187)
	+	43 (46.7)	1 (50.0)		
Target bile duct (%)	B2	29 (31.5)	0 (0.0)	0.856	
Diameter of bile duct (mm) (median [IQR])		5.2 [4.2, 7.0]	4.2 [3.9, 4.6]	0.326	-0.640 (-2.063, 0.782)
Cut-off value = 4 (%)	≤4	18 (19.6)	1 (50.0)	0.865	0.248 (0.003, 20.146)
	<4	74 (80.4)	1 (50.0)		
Cut-off value = 5 (%)	≤5	43 (46.7)	2 (100.0)	0.438	0 (0, 4.869)
	<5	49 (53.3)	0 (0.0)		
Cut-off value = 6 (%)	≤6	62 (67.4)	2 (100.0)	0.832	0 (0, 11.421)
	<6	30 (32.6)	0 (0.0)		
Distance of puncture route in liver (cm) (median [IQR])		2.1 [1.6, 2.6]	1.3 [1.0, 1.6]	0.125	-0.512 (-1.933, 0.910)
Cut-off value = 1.5 (%)	≤1.5	20 (21.7)	1 (50.0)	0.927	0.283 (0.004, 22.886)
	1.5<	72 (78.3)	1 (50.0)		
Cut-off value = 2 (%)	≤2	45 (48.9)	2 (100.0)	0.475	0 (0, 5.306)
	2<	47 (51.1)	0 (0.0)		
Cut-off value = 2.5 (%)	≤2.5	68 (73.9)	2 (100.0)	0.986	0 (0, 15.680)
	2.5<	24 (26.1)	0 (0.0)		
Procedural time (min.) (median [IQR])		41.5 [31.8, 58.0]	40.5 [37.8, 43.2]	0.896	-0.305 (-1.725, 1.115)
Total number of punctures (median [IQR])		1.0 [1.0, 1.2]	1.0 [1.0, 1.0]	0.423	-0.481 (-1.903, 0.940)
Type of SEMS (%)	Braided type	77 (83.7)	2 (100.0)	1	0 (0, 28.654)
	Laser-cut type	15 (16.3)	0 (0.0)		
Diameter of SEMS (mm) (%)	6	49 (53.3)	2 (100.0)	0.552	0 (0, 6.305)
	8	43 (46.7)	0 (0.0)		
Total number of device exchanges (median [IQR])		2.0 [2.0, 3.0]	2.0 [2.0, 2.0]	0.52	0.023 (-0.590, 0.637)
Cut-off value = 1 (%)	1 (without dilation)	14 (15.2)	0 (0.0)	1	5.292 (0.296, 94.549)
	≤2	78 (84.8)	2 (100.0)		
Cut-off value = 2 (%)	≤2	55 (59.8)	2 (100.0)	0.674	0.742 (0.207, 2.667)
	<2	37 (40.2)	0 (0.0)		
Electrocautery dilation (%)	-	86 (93.5)	2 (100.0)	1	0 (0, 83.546)
	+	6 (6.5)	0 (0.0)		

► **Table 5** (Continuation)

	Level	Biliary peritonitis		P value	Effect size (95%CI)
		-	+		
Contrast medium residual in peripheral bile duct (%)	-	83 (90.2)	1 (50.0)	0.506	
	+	9 (9.8)	1 (50.0)		8.803 (0.106, 727.162)

EUS-HGS, endoscopic ultrasound-guided hepaticogastrostomy; SEMS, self-expandable metal stent; IQR, interquartile range.

essential to approach these data with caution due to differing AE definitions across studies, necessitating further comprehensive analyses for a meaningful comparison. On the other hand, a total of 5.3% of cases (5/94) resulted in fatalities within 14 days. After excluding two cases of cancer progression, three cases were attributed to cardiovascular or cerebrovascular events, not directly associated with the procedure. There was no inappropriate antithrombotic drug withdrawal in these patients [14]. Lethal arrhythmias occurred 10 and 13 days after the procedure, and cerebral infarction occurred 8 days post-procedure. No other AEs, such as abdominal pain or fever, were observed in either case. One of the two patients with a lethal arrhythmia had a history of ischemic heart disease with a background of diabetes and chronic renal disease. The patient was found in cardiac arrest early in the morning after having eaten well until dinner the previous night. The remaining patient did not have any underlying cardiovascular disease but suddenly went into cardiac arrest in the afternoon, and it was challenging to identify any other cause of death at autopsy. In the case of cerebral infarction, there was no apparent underlying cardiovascular disease, and magnetic resonance imaging revealed multiple cerebral infarctions, diagnosed as Trousseau syndrome by a neurologist. It has been reported that cancer patients are at increased risk for cardiovascular events such as deep vein thrombosis and Trousseau syndrome due to abnormalities in the coagulation-fibrinolytic system, of which pancreatic cancer is considered high-risk [15,16]. While definitive conclusions require further case accumulation, it cannot be discounted that the invasive nature of EUS-HGS, involving bleeding, might have exacerbated the pre-existing coagulation-fibrinolytic system abnormalities and contributed to these events. Moreover, 16.0% of all cases (15/94) led to mortality within 30 days. Given that 12.8% of these deaths (12/94) were attributed to cancer progression, there is a possibility that the procedure may have been excessively indicated for terminally ill patients.

Nevertheless, it is also a reality that in clinical practice, diverse factors, including the patient-family relationship and the doctor-patient relationship, might influence the indication for procedures even when their effectiveness is uncertain. This is also only one piece of real-world data.

In the analyses of various factors related to AE and EUS-HGS, acute cholangitis was not observed in patients with a bile duct diameter <4 mm, although there were no statistically significant differences. However, two cases of bacteremia, presumably caused by similar mechanisms such as cholangiovenous

and cholangiolymphatic reflux [17], were observed. Therefore, it is unlikely that bile ducts <4 mm are at a low risk for cholangitis. Residual findings of contrast medium in the peripheral bile duct on the following day's CT did not correlate with acute cholangitis. This observation suggests that the cause of acute cholangitis might be more strongly related to the procedure-induced increase in intrabiliary pressure than to peripheral bile duct obstruction due to SEMS. As reported by Ishiwatari et al. [18], sufficient aspiration of bile juice to reduce intrabiliary pressure during the procedure may play a crucial role in reducing AEs. Theoretically, it is desirable to aspirate sufficient bile juice immediately after puncture before contrast administration, or to exchange the cannula and aspirate bile with guidewire advancement without contrast after puncture. However, the former carries the risk of inadequate bile aspiration and potential dislodgment of the needle tip from the bile duct, while the latter poses the risk of misplacement of the guidewire. In a study conducted by Samanta et al. [19], emergency EUS-BD was found to be safe in 49 cases of moderate or severe cholangitis, 87.8% of which were associated with malignancy. The procedure demonstrated a technical success rate of 98.0% (48/49) and clinical success rate, leading to improvement in cholangitis, in 91.7% of cases (44/48). However, in our study, patients with a history of cholangitis within 14 days prior to EUS-HGS were more likely to develop cholangitis after the procedure, although the difference was not statistically significant ($P=0.261$, $OR=2.463$ [95% CI: 0.596–10.511]). Therefore, careful attention should be paid to avoid elevating intrabiliary pressure when performing the procedure on patients with a recent history of cholangitis.

Two main factors contribute to the development of biliary peritonitis in cases associated with EUS-HGS. First, there is a risk of bile leakage into the abdominal cavity during the procedure. In addition, there is potential for bile to escape along the stent or through its lateral hole if the stent malfunctions. To minimize the risk of the former, it is crucial to ensure effective aspiration of bile during the procedure [18]. Noteworthy is the finding by Yamamoto et al. [11], indicating that a hepatic parenchymal puncture ≥ 2.5 cm in length reduces the likelihood of post-procedure peritonitis. In our study, we documented only two cases of biliary peritonitis, which limited our ability to conduct a comprehensive statistical analysis. However, both punctures were <2 cm in length, aligning with previous research. Interestingly, none of the 15 cases where SEMS were placed without tract dilation resulted in biliary peritonitis. This underscores

► **Table 6** Risk factors for stent migration into the abdominal cavity associated with EUS-HGS.

	Level	Distance between liver and GI tract (cm)		P value	Effect size (95%CI)	Distance between liver and GI tract (cm)		P-value	Effect size (95%CI)	Distance between liver and GI tract (cm)	
		<1.5	≤1.5			<2	≤2			<2.5	2.5≤
n		51	43			63	31			71	23
Age (median [IQR])		77.0 [67.0, 83.0]	77.0 [70.0, 85.5]	0.441	0.109 (-0.302, 0.521)	77.0 [67.0, 83.0]	73.0 [70.0, 86.0]	0.449	0.126 (-0.310, 0.562)	76.0 [67.5, 83.0]	81.0 [69.5, 86.5]
Sex (%)	F	21 (41.2)	23 (53.5)	0.300	0.612 (0.248, 1.492)	30 (47.6)	14 (45.2)	1.000	1.103 (0.428, 2.874)	34 (47.9)	10 (43.5)
	M	30 (58.8)	20 (46.5)			33 (52.4)	17 (54.8)			37 (52.1)	13 (56.5)
Location of obstruction (%)	Distal	32 (62.7)	24 (55.8)	0.532	1.330 (0.537, 3.306)	39 (61.9)	17 (54.8)	0.655	1.334 (0.508, 3.484)	44 (62.0)	12 (52.2)
	Hilar	19 (37.3)	19 (44.2)			24 (38.1)	14 (45.2)			27 (38.0)	11 (47.8)
Cholangitis within 14 days before EUS-HGS (%)	-	34 (66.7)	23 (53.5)	0.211	1.729 (0.695, 4.361)	41 (65.1)	16 (51.6)	0.263	1.737 (0.663, 4.574)	46 (64.8)	11 (47.8)
	+	17 (33.3)	20 (46.5)			22 (34.9)	15 (48.4)			25 (35.2)	12 (52.2)
History of upper abdominal surgery (%)	-	23 (45.1)	27 (62.8)	0.101	0.491 (0.195, 1.204)	31 (49.2)	19 (61.3)	0.283	0.615 (0.230, 1.595)	37 (52.1)	13 (56.5)
	+	28 (54.9)	16 (37.2)			32 (50.8)	12 (38.7)			34 (47.9)	10 (43.5)
Target bile duct (%)	B2	19 (37.3)	10 (23.3)	0.181	1.945 (0.728, 5.459)	22 (34.9)	7 (22.6)	0.246	1.828 (0.632, 5.844)	24 (33.8)	5 (21.7)
	B3	32 (62.7)	33 (76.7)			41 (65.1)	24 (77.4)			47 (66.2)	18 (78.3)
Diameter of bile duct (mm) (median [IQR])		4.7 [3.8, 5.9]	5.5 [4.8, 7.5]	0.022	0.410 (-0.006, 0.825)	5.2 [4.0, 6.7]	5.5 [4.8, 7.5]	0.093	0.337 (-0.101, 0.776)	5.2 [4.1, 6.9]	5.2 [4.7, 6.9]
Cut-off value = 4 (%)	≤4	15 (29.4)	4 (9.3)	0.020	4.006 (1.135, 18.134)	16 (25.4)	3 (9.7)	0.102	3.143 (0.796, 18.313)	16 (22.5)	3 (13.0)
	4<	36 (70.6)	39 (90.7)			47 (74.6)	28 (90.3)			55 (77.5)	20 (87.0)
Cut-off value = 5 (%)	≤5	26 (51.0)	19 (44.2)	0.540	1.310 (0.539, 3.213)	31 (49.2)	14 (45.2)	0.827	1.174 (0.456, 3.060)	34 (47.9)	11 (47.8)
	5<	25 (49.0)	24 (55.8)			32 (50.8)	17 (54.8)			37 (52.1)	12 (52.2)
Cut-off value = 6 (%)	≤6	39 (76.5)	25 (58.1)	0.076	2.318 (0.884, 6.281)	45 (71.4)	19 (61.3)	0.353	1.571 (0.572, 4.267)	49 (69.0)	15 (65.2)
	6<	12 (23.5)	18 (41.9)			18 (28.6)	12 (38.7)			22 (31.0)	8 (34.8)

► **Table 6** (Continuation)

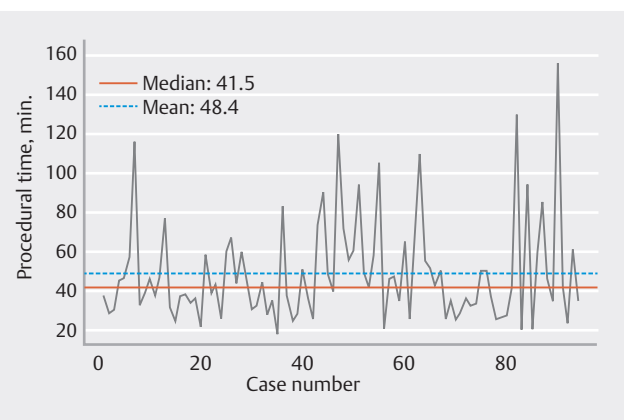
	Level	Distance between liver and GI tract (cm)		P value	Effect size (95%CI)	Distance between liver and GI tract (cm)		P-value	Effect size (95%CI)	Distance between liver and GI tract (cm)	
		<1.5	≤1.5			<2	≤2			<2.5	2.5≤
		Distance of puncture route in liver (cm) (median [IQR])				2.1 [1.6, 2.6]	2.0 [1.8, 2.5]			0.900	-0.052 (-0.463, 0.360)
Cut-off value = 1.5 (%)	≤1.5	13 (25.5)	8 (18.6)	0.466	1.490 (0.501, 4.682)	15 (23.8)	6 (19.4)	0.794	1.299 (0.411, 4.606)	16 (22.5)	5 (21.7)
	<1.5	38 (74.5)	35 (81.4)			48 (76.2)	25 (80.6)			55 (77.5)	18 (78.3)
Cut-off value = 2 (%)	≤2	25 (49.0)	22 (51.2)	1	0.919 (0.377, 2.233)	31 (49.2)	16 (51.6)	1	0.909 (0.351, 2.344)	36 (50.7)	11 (47.8)
	<2	26 (51.0)	21 (48.8)			32 (50.8)	15 (48.4)			35 (49.3)	12 (52.2)
Cut-off value = 2.5 (%)	≤2.5	37 (72.5)	33 (76.7)	0.813	0.803 (0.278, 2.250)	46 (73.0)	24 (77.4)	0.802	0.791 (0.242, 2.362)	53 (74.6)	17 (73.9)
	<2.5	14 (27.5)	10 (23.3)			17 (27.0)	7 (22.6)			18 (25.4)	6 (26.1)
Procedural time (min.) (median [IQR])		46.0 [34.0, 63.0]	38.0 [30.5, 46.5]	0.051	-0.465 (-0.882, -0.049)	45.0 [33.5, 60.5]	37.0 [30.5, 46.0]	0.052	-0.504 (-0.945, -0.062)	43.0 [32.0, 60.0]	37.0 [31.5, 45.5]
Total number of punctures (median [IQR])		1.0 [1.0, 1.0]	1.0 [1.0, 2.0]	0.522	0.058 (-0.354, 0.469)	1.0 [1.0, 1.0]	1.0 [1.0, 2.0]	0.202	0.234 (-0.203, 0.671)	1.0 [1.0, 1.0]	1.0 [1.0, 2.0]
Type of SEMS (%)	Braided type	37 (72.5)	42 (97.7)	0.001	0.064 (0.001, 0.461)	48 (76.2)	31 (100.0)	0.002	0 (0, 0.477)	56 (78.9)	23 (100.0)
	Laser-cut type	14 (27.5)	1 (2.3)			15 (23.8)	0 (0.0)			15 (21.1)	0 (0.0)
Diameter of SEMS (mm)(%)	6	22 (43.1)	29 (67.4)	0.023	0.370 (0.144, 0.920)	31 (49.2)	20 (64.5)	0.191	0.536 (0.197, 1.403)	36 (50.7)	15 (65.2)
	8	29 (56.9)	14 (32.6)	0.768		32 (50.8)	11 (35.5)	0.91		35 (49.3)	8 (34.8)
Total number of device exchanges (median [IQR])		2.0 [2.0, 3.0]	2.0 [2.0, 2.0]		-0.023 (-0.434, 0.388)	2.0 [2.0, 3.0]	2.0 [2.0, 2.0]		-0.0395 (-0.475, 0.396)	2.0 [2.0, 3.0]	2.0 [2.0, 3.0]
Tract dilation (%)	-	12 (23.5)	3 (7.0)	0.046	4.046 (0.987, 24.04)	13 (20.6)	2 (6.5)	0.046	3.726 (0.760, 36.322)	14 (19.7)	1 (4.3)
	+	39 (76.5)	40 (93.0)			50 (79.4)	29 (93.5)			57 (80.3)	22 (95.7)
Electrocautery dilation (%)	-	49 (96.1)	39 (90.7)	0.522	2.489 (0.337, 28.862)	60 (95.2)	28 (90.3)	0.64	2.124 (0.267, 16.876)	67 (94.4)	21 (91.3)
	+	2 (3.9)	4 (9.3)			3 (4.8)	3 (9.7)			4 (5.6)	2 (8.7)

EUS-HGS, endoscopic ultrasound-guided hepaticogastrostomy; GI, gastrointestinal; IQR, interquartile range; SEMS, self-expandable metal stent.

the importance of avoiding excessive ductal expansion and minimizing the need for device changes [20,21]. Laser-cut SEMs, due to their inherent characteristics, boast a slimmer delivery system compared with the braided type. This allows for placement without dilation in many cases. Nevertheless, it is worth noting that only 15 laser-cut SEMs were used in our study, suggesting caution in generalizing these results.

In EUS-HGS with SEMs, the most serious AE is migration of SEMs into the abdominal cavity [22]. Stent migration often occurs during or immediately after the procedure, although there have been reports of AEs emerging several days later [23,24].

Various methods have been reported to prevent SEM migration into the abdominal cavity. The first is to place the SEM long enough in the stomach; Nakai et al. [12,25] reported none of the SEMs migrated in the 110 EUS-HGS cases when the median length of SEMs in the gastric lumen was 54 mm (IQR, 46–60 mm). Consequently, it was recommended that SEM length should be at least 6 cm longer than the length of the parenchyma to ensure the intragastric portion of SEMs is longer than 5 cm [12]. The second is the intra-scope channel stent release technique, which reduces the distance between the stomach wall and liver by deploying the SEMs within the echoendoscope while pressing the stomach wall against the liver with the scope [26]. However, Ochiai et al. [27] reported a slight reduction in the distance between the stomach and liver after the procedure, which subsequently returned to nearly its original position, underscoring the significance of puncture position. Finally, improvements have been made directly to SEMs. While previous reports mentioned the addition of clips or PSs to anchor the SEMs and prevent migration [28,29], recently, several SEMs with anchors that prevent migration have become available and the risk has been greatly reduced [30,31]. Notably, the distance between the stomach and liver post-procedure varied significantly based on SEM type. Cases involving laser-cut type SEMs consistently exhibited distances not exceeding 2 cm. This characteristic might be attributed to the slightly rougher outer surface of the laser-cut SEMs, serving as a natural anchor. However, a potential drawback is difficulty in removing laser-cut SEMs in case of obstruction. Although the SEMs used in our study was of the end-bear partially covered type, Harai et al. [32] reported a 100% technical success rate in 29 cases where reintervention was conducted due to fully-covered laser-cut type SEMs occlusion. In addition, a statistically significant factor in the separation of the stomach wall and liver after the procedure was a bile duct diameter <4 mm. In interpreting the results, it should be noted that the bile duct diameter cannot be used as an absolute indicator because it varies depending on the puncture location (peripheral or central) in the same case. However, because there was no difference in intrahepatic puncture distance in the present study, it is considered that the peripheral bile ducts were punctured at relatively the same level. A possible reason for the shorter post-procedure distance between the stomach and liver in cases with smaller bile ducts (<4 mm) is the difference in liver volume change due to decompression. It is possible that the shift in position caused by improved hepatomegaly was greater in cases in which the bile



► Fig. 2 Trend in procedural time.

ducts were peripherally distended than in cases in which the bile ducts were thinner.

There are several limitations to this study. One is that the incidence of AEs may be underestimated because pain and fever are masked by the antipyretic analgesics already administered. Another is endoscopist learning curve. In a previously reported review comprising 72 cases, the median procedure time was 59 minutes, achieved after the 32nd procedure. It has been documented that procedure time tends to further decrease with the accumulation of cases, falling below 50 minutes after the 50th procedure and possibly stabilizing after exceeding 100 cases [33]. None of the endoscopists in this study had prior experience with more than 100 EUS-HGS cases. However, the technical success rate remained at 100%, and the learning curve did not exert a significant impact on the outcomes, as indicated by the temporal transition in procedure duration and the mean and median values (► Fig. 2). It is also undeniable that the delay in commercial availability of laser-cut SEMs may have contributed to this difference. Furthermore, although the present report had a larger number of cases than the previous report, it was still insufficient to perform a multivariate analysis. Therefore, in addition to the *P* values in the univariate analysis, ORs were also included.

Conclusions

In conclusion, EUS-HGS using SEMs demonstrated high technical and clinical success rates. Cases with laser-cut type SEMs placed tended to have a significantly shorter distance between the stomach and liver on the day after the procedure. Furthermore, the absence of biliary peritonitis in cases without tract dilation suggests that laser-cut type SEMs, which have a thinner delivery system than the braided-type SEMs, may be a better choice for preventing early AEs.

Conflict of Interest

The authors declare that they have no conflict of interest.

References

- [1] Giovannini M, Moutardier V, Pesenti C et al. Endoscopic ultrasound-guided bilioduodenal anastomosis: a new technique for biliary drainage. *Endoscopy* 2001; 33: 898–900 doi:10.1055/s-2001-17324
- [2] Bang JY, Navaneethan U, Hasan M et al. Stent placement by EUS or ERCP for primary biliary decompression in pancreatic cancer: a randomized trial (with videos). *Gastrointest Endosc* 2018; 88: 9–17 doi:10.1016/j.gie.2018.03.012
- [3] Paik WH, Lee TH, Park DH et al. EUS-guided biliary drainage versus ERCP for the primary palliation of malignant biliary obstruction: a multicenter randomized clinical trial. *Am J Gastroenterol* 2018; 113: 987–997 doi:10.1038/s41395-018-0122-8
- [4] Minaga K, Takenaka M, Kitano M et al. Rescue EUS-guided intrahepatic biliary drainage for malignant hilar biliary stricture after failed transpapillary re-intervention. *Surg Endosc* 2017; 31: 4764–4772 doi:10.1007/s00464-017-5553-6
- [5] Kongkam P, Orprayoon T, Boonmee C et al. ERCP plus endoscopic ultrasound-guided biliary drainage versus percutaneous transhepatic biliary drainage for malignant hilar biliary obstruction: a multicenter observational open-label study. *Endoscopy* 2021; 53: 55–62 doi:10.1055/a-1195-8197
- [6] Vanella G, Bronswijk M, Maleux G et al. EUS-guided intrahepatic biliary drainage: a large retrospective series and subgroup comparison between percutaneous drainage in hilar stenoses or postsurgical anatomy. *Endosc Int Open* 2020; 8: E1782–E1794 doi:10.1055/a-1264-7511
- [7] Poincloux L, Rouquette O, Buc E et al. Endoscopic ultrasound-guided biliary drainage after failed ERCP: cumulative experience of 101 procedures at a single center. *Endoscopy* 2015; 47: 794–801 doi:10.1055/s-0034-1391988
- [8] van der Merwe SW, van Wanrooij RLJ, Bronswijk M et al. Therapeutic endoscopic ultrasound: European Society of Gastrointestinal Endoscopy (ESGE) Guideline. *Endoscopy* 2022; 54: 185–205 doi:10.1055/a-1717-1391
- [9] Tyberg A, Napoleon B, Robles-Medranda C et al. Hepaticogastrostomy versus choledochoduodenostomy: An international multicenter study on their long-term patency. *Endosc Ultrasound* 2022; 11: 38–43
- [10] Ohno A, Fujimori N, Kaku T et al. Feasibility and efficacy of endoscopic ultrasound-guided hepaticogastrostomy without dilation: a propensity score matching analysis. *Dig Dis Sci* 2022; doi:10.1007/s10620-022-07555-z
- [11] Yamamoto Y, Ogura T, Nishioka N et al. Risk factors for adverse events associated with bile leak during EUS-guided hepaticogastrostomy. *Endosc Ultrasound* 2020; 9: 110–115
- [12] Nakai Y, Sato T, Hakuta R et al. Long-term outcomes of a long, partially covered metal stent for EUS-guided hepaticogastrostomy in patients with malignant biliary obstruction (with video). *Gastrointest Endosc* 2020; 92: 623–631.e621
- [13] Oh D, Park DH, Song TJ et al. Optimal biliary access point and learning curve for endoscopic ultrasound-guided hepaticogastrostomy with transmural stenting. *Therap Adv Gastroenterol* 2017; 10: 42–53
- [14] Fujimoto K, Fujishiro M, Kato M et al. Guidelines for gastroenterological endoscopy in patients undergoing antithrombotic treatment. *Dig Endosc* 2014; 26: 1–14 doi:10.1111/den.12183
- [15] Horsted F, West J, Grainge MJ. Risk of venous thromboembolism in patients with cancer: a systematic review and meta-analysis. *PLoS Med* 2012; 9: e1001275
- [16] Varki A. Trousseau's syndrome: multiple definitions and multiple mechanisms. *Blood* 2007; 110: 1723–1729 doi:10.1182/blood-2006-10-053736
- [17] Takada T, Takikawa H, Sawada N et al. Cholangio-venous reflux of biliary contents through paracellular pathways between hepatocytes in patients with acute cholangitis. *J Hepatobiliary Pancreat Sci* 2021; 28: 508–514
- [18] Ishiwatari H, Satoh T, Sato J et al. Bile aspiration during EUS-guided hepaticogastrostomy is associated with lower risk of postprocedural adverse events: a retrospective single-center study. *Surg Endosc* 2021; 35: 6836–6845
- [19] Samanta J, Sundaram S, Dhar J et al. EUS-guided biliary drainage in patients with moderate-severe cholangitis is safe and effective: a multi-center experience. *Surg Endosc* 2022; doi:10.1007/s00464-022-09495-1
- [20] Ogura T, Ueno S, Okuda A et al. Technical feasibility and safety of one-step deployment of EUS-guided hepaticogastrostomy using an 8-mm diameter metal stent with a fine-gauge stent delivery system (with video). *Endosc Ultrasound* 2021; 10: 355–360
- [21] Park DH, Lee TH, Paik WH et al. Feasibility and safety of a novel dedicated device for one-step EUS-guided biliary drainage: A randomized trial. *J Gastroenterol Hepatol* 2015; 30: 1461–1466 doi:10.1111/jgh.13027
- [22] Kawakubo K, Isayama H, Kato H et al. Multicenter retrospective study of endoscopic ultrasound-guided biliary drainage for malignant biliary obstruction in Japan. *J Hepatobiliary Pancreat Sci* 2014; 21: 328–334 doi:10.1002/jhbp.27
- [23] Martins FP, Rossini LG, Ferrari AP. Migration of a covered metallic stent following endoscopic ultrasound-guided hepaticogastrostomy: fatal complication. *Endoscopy* 2010; 42: E126–E127 doi:10.1055/s-0029-1243911
- [24] Minaga K, Kitano M, Yamashita Y et al. Stent migration into the abdominal cavity after EUS-guided hepaticogastrostomy. *Gastrointest Endosc* 2017; 85: 263–264
- [25] Nakai Y, Isayama H, Yamamoto N et al. Safety and effectiveness of a long, partially covered metal stent for endoscopic ultrasound-guided hepaticogastrostomy in patients with malignant biliary obstruction. *Endoscopy* 2016; 48: 1125–1128
- [26] Miyano A, Ogura T, Yamamoto K et al. Clinical impact of the intrascope channel stent release technique in preventing stent migration during EUS-guided hepaticogastrostomy. *J Gastrointest Surg* 2018; 22: 1312–1318
- [27] Ochiai K, Fujisawa T, Ishii S et al. Risk factors for stent migration into the abdominal cavity after endoscopic ultrasound-guided hepaticogastrostomy. *J Clin Med* 2021; 10: doi:10.3390/jcm10143111
- [28] Fujisawa T, Isayama H, Ishii S. “ClipFlap” anchoring method for endoscopic ultrasonography-guided hepaticogastrostomy with a covered self-expandable metallic stent. *Dig Endosc* 2020; 32: 628 doi:10.1111/den.13621
- [29] Shima Y, Isayama H, Ito Y et al. Crisscross anchor-stents to prevent metal stent migration during endoscopic ultrasound-guided hepaticogastrostomy. *Endoscopy* 2014; 46: E563
- [30] Yamashita Y, Itonaga M, Gon C et al. Usefulness of a newly designed laser-cut metal stent with an anchoring hook and thin delivery system for EUS-guided hepaticogastrostomy in experimental settings (with video). *Gastrointest Endosc* 2021; 94: 999–1008.e1001
- [31] Cho DH, Lee SS, Oh D et al. Long-term outcomes of a newly developed hybrid metal stent for EUS-guided biliary drainage (with videos). *Gastrointest Endosc* 2017; 85: 1067–1075
- [32] Harai S, Hijioka S, Nagashio Y et al. Usefulness of the laser-cut, fully covered, self-expandable metallic stent for endoscopic ultrasound-guided hepaticogastrostomy. *J Hepatobiliary Pancreat Sci* 2022; 29: 1035–1043 doi:10.1002/jhbp.1165
- [33] Tyberg A, Mishra A, Cheung M et al. Learning curve for EUS-guided biliary drainage: What have we learned? *Endosc Ultrasound* 2020; 9: 392–396