Article published online: 2024-02-28

Acute Necrotizing Pancreatitis Complicated With Sinistral Portal Hypertension And Mechanical Obstruction Of The Colon: A Case Report

Akute nekrotisierende Pankreatitis mit linksseitiger portaler Hypertonie und mechanischer Obstruktion des Dickdarms: Ein Fallbericht

Authors
Guijie Zhao, Shuaiyong Wen, Yu Zhang, Kun Zhang, Yunfeng Cui

Affiliations
Department of Hepatobiliary and Pancreatic Surgery, Department of Surgery, Tianjin Nankai Hospital, Nankai Clinical School of Medicine, Tianjin Medical University, Tianjin, China

Keywords
acute necrotizing pancreatitis, sinistral portal hypertension, splenomegaly, colonic obstruction

Schlüsselwörter
akute nekrotisierende Pankreatitis, sinistrale portale Hypertension, Splenomegalie, Kolonobstruktion

received 5.11.2023

Bibliography
Z Gastroenterol
DOI 10.1055/a-2250-6502
ISSN 0044-2771
© 2024. The Author(s).
This is an open access article published by Thieme under the terms of the Creative Commons Attribution-NonDerivative-NonCommercial-License, permitting copying and reproduction so long as the original work is given appropriate credit. Contents may not be used for commercial purposes, or adapted, remixed, transformed or built upon. (https://creativecommons.org/licenses/by-nc-nd/4.0/).
Georg Thieme Verlag KG, Rüdigerstraße 14, 70469 Stuttgart, Germany

Correspondence
Dr. Yunfeng Cui
Department of Hepatobiliary and Pancreatic Surgery, Department of Surgery, Tianjin Nankai Hospital, Nankai Clinical School of Medicine, Tianjin Medical University, Tianjin, China
nkyycyf@163.com

ABSTRACT

Acute necrotizing pancreatitis (ANP) is often associated with acute necrotic collection (ANC) or walled-off necrosis (WON). Due to the close anatomical connection between the pancreas, the spleen, and the transverse colon, necrotizing pancreatitis is often combined with spleen or colon involvement. Gastrointestinal dysfunction usually caused by pancreatitis leads to paralytic intestinal obstruction. However, pancreatitis combined with mechanical colonic obstruction is extremely rare. It can easily be misdiagnosed as malignant intestinal obstruction, and diagnosing the cause of intestinal obstruction becomes more critical when accompanied by Sinistral portal hypertension (SPH). Surgical resection is the primary method for the previous occurrence of colonic complications. In this case report, upon admission, a 37-year-old patient was diagnosed with acute necrotizing pancreatitis with sinistral portal hypertension. On the 6th day after admission, the patient developed a sudden colonic obstruction. After identifying the cause, the patient underwent a transanal decompression tube and minimally invasive necrosectomy, avoiding colon resection. In acute necrotizing pancreatitis combined with colonic mechanical obstruction, it is essential to clarify the etiology, and focus treatment on clearing the peripancreatic necrotic tissue, non-surgical treatment to deal with colonic obstruction is feasible, and the principle of individualized treatment should be used throughout the disease.

ZUSAMMENFASSUNG

Die akute nekrotisierende Pankreatitis geht häufig mit einer akuten nekrotischen Ansammlung oder einer Walled-off-Nekrose einher. Aufgrund der engen anatomischen Verbindung zwischen der Bauchspeicheldrüse, der Milz und dem Colon transversum ist die nekrotisierende Pankreatitis häufig mit einer Beteiligung der Milz oder des Colons verbunden. Die durch die Pankreatitis verursachte gastrointestinale Funktionsstörung führt in der Regel zu einer paralytischen Darmobstruktion. Eine Pankreatitis in Kombination mit einer mechanischen Kolonobstruktion ist jedoch äußerst selten. Sie kann leicht als bösartige Darmobstruktion fehldiagnostiziert werden, und die Diagnose der Ursache der Darmobstruktion wird noch kritischer, wenn sie von einer linksseitigen portalen Hypertonie (SPH) begleitet wird. Die chirurgische Resektion ist die primäre Methode für das vorherige Auftreten von

Kolonkomplikationen. In diesem Fallbericht wurde bei der Aufnahme eines 37-jährigen Patienten eine akute nekrotisierende Pankreatitis mit linksseitiger portaler Hypertonie diagnostiziert. Am 6. Tag nach der Aufnahme entwickelte der Patient eine plötzliche Kolonobstruktion. Nach Abklärung der Ursache wurde der Patient einer transanalen Dekompressionssonde und einer minimalinvasiven Nekrosektomie unterzogen, wobei eine Kolonresektion vermieden wurde. Bei einer akuten nekrotisierenden Pankreatitis in Kombination mit einer mechanischen Kolonobstruktion ist es wichtig, die Ätiologie zu klären und die Behandlung auf die Beseitigung des peripankreatischen nekrotischen Gewebes auszurichten; eine nicht-chirurgische Behandlung der Kolonobstruktion ist möglich, und das Prinzip der individualisierten Behandlung sollte während der gesamten Erkrankung angewendet werden.

Introduction

Acute necrotizing pancreatitis (ANP) can cause various regional complications due to necrosis and exudation of the pancreatic parenchyma and peripancreatic tissue. The close anatomical connection between the pancreas, spleen, and transverse colon often results in combined spleen or colon involvement in ANP cases. Sinistral portal hypertension (SPH) refers to regional portal hypertension caused by compression and distortion of the splenic vein, inflammatory wall thickening or luminal narrowing and blockage, venous thrombosis, and impaired blood return. SPH accounts for less than 5 % of all patients with portal hypertension [1]. Among the causes of SPH, pancreatitis is the most common, accounting for about 60 % of all reasons. The incidence of colonic complications in acute pancreatitis is approximately 11 %, including paralytic intestinal obstruction, segmental necrosis, and colonic fistula [2]. However, mechanical obstruction of the colon caused by pancreatitis is much more rare. Herein, we report a patient with ANP combined with SPH who had a sudden acute mechanical obstruction of the colon during treatment. We also analyzed the relationship between pancreatitis and colon obstruction and SPH, as well as the choice of treatment measures.

Case presentation

The patient, a 37-year-old male, was admitted to our hospital with ”epigastric pain for more than three months and fever for 20 days”. The patient was diagnosed with “acute pancreatitis” at a local hospital three months prior and received anti-inflammatory treatment and abdominocentesis. Twenty days before admission, the patient developed intermittent abdominal pain with a high fever after the drainage tube of the abdominal puncture was removed and transferred to our hospital. The patient was in good health and had no food or drug allergies history. Abdomen CT plain scan on admission (▶ **Fig. 1A–C**) showed ANP with peripheral infection, gas accumulation, and abdominal effusion. The spleen was enlarged and less uniform in density. The splenic flexural wall of the colon was thickened. After admission, patients were treated with fasting, gastrointestinal decompression, active infection control, nutrition support, and acid inhibitor and ulinastatin.

On the 6th day of admission, the patient had sudden onset of full abdominal distension and pain without defecation. Enhanced CT of the whole abdomen showed (▶ **Fig. 1D–G**) an enlarged pancreas with uneven density, increased density in the surrounding fat space, a patchy high-density shadow, a gas density shadow with the tail of the pancreas being prominent, multiple tortuous vascular shadows in the splenic portal area, and a thickened wall in the splenic region of the transverse colon with incomplete obstruction of the proximal colon, not excluding occupying lesions. After a multidisciplinary discussion, it was considered that the patient had developed mechanical colonic obstruction. Subsequently, the patient underwent transanal decompression tube placement via colonoscopy to relieve the obstructive symptoms. Colonoscopy showed significant mucosal edema in the colonic splanchnic lumen resulting in luminal stenosis (▶ **Fig. 1H–I**), and the tube was fixed at the proximal end of the obstructed intestine through the stenotic segment, draining a large amount of feces. After 10 days, the patient was drained by a CT-guided percutaneous puncture, and a drainage tube was placed in the left pararenal anterior space through the left abdomen (▶ **Fig. 1K**), and the drainage fluid was purulent. After 20 days, minimally invasive removal of pancreatic necrotic tissue was performed. After the operation, the patient was given continuous saline flushing through the drainage tube and continued symptomatic treatment. The patient was discharged after two months with improvement of symptoms.

Discussion

The pathogenesis of SPH by ANP is that infected necrosis of the pancreas causes damage to the intima of the splenic vein adjacent to the pancreas and vasospasm, leading to luminal narrowing and hemodynamic disturbances, which in turn cause thrombosis of the splenic vein [3]. Generally speaking, the main clinical manifestations of SPH are the formation of gastroesophageal varices, ascites, and splenomegaly. In terms of treatment, most scholars believe that in patients with simple splenomegaly not combined with gastrointestinal bleeding, the risk of splenectomy is higher, even higher than the risk of gastrointestinal bleeding due to SPH, so prophylactic splenectomy is not recommended, and active management of the primary disease and regular follow up is required [4]. In this case, the patient only presented with spleen enlargement and had a good prognosis after active treatment of the primary disease.

Mechanical obstruction of the colon caused by pancreatitis is rare. We considered two possible reasons for the patient’s colonic obstruction in this case. Firstly, the enlargement of the spleen due to pancreatitis may compress the wall of the colon, as T. Sommer reported in a case of colonic obstruction due to progressive sple-

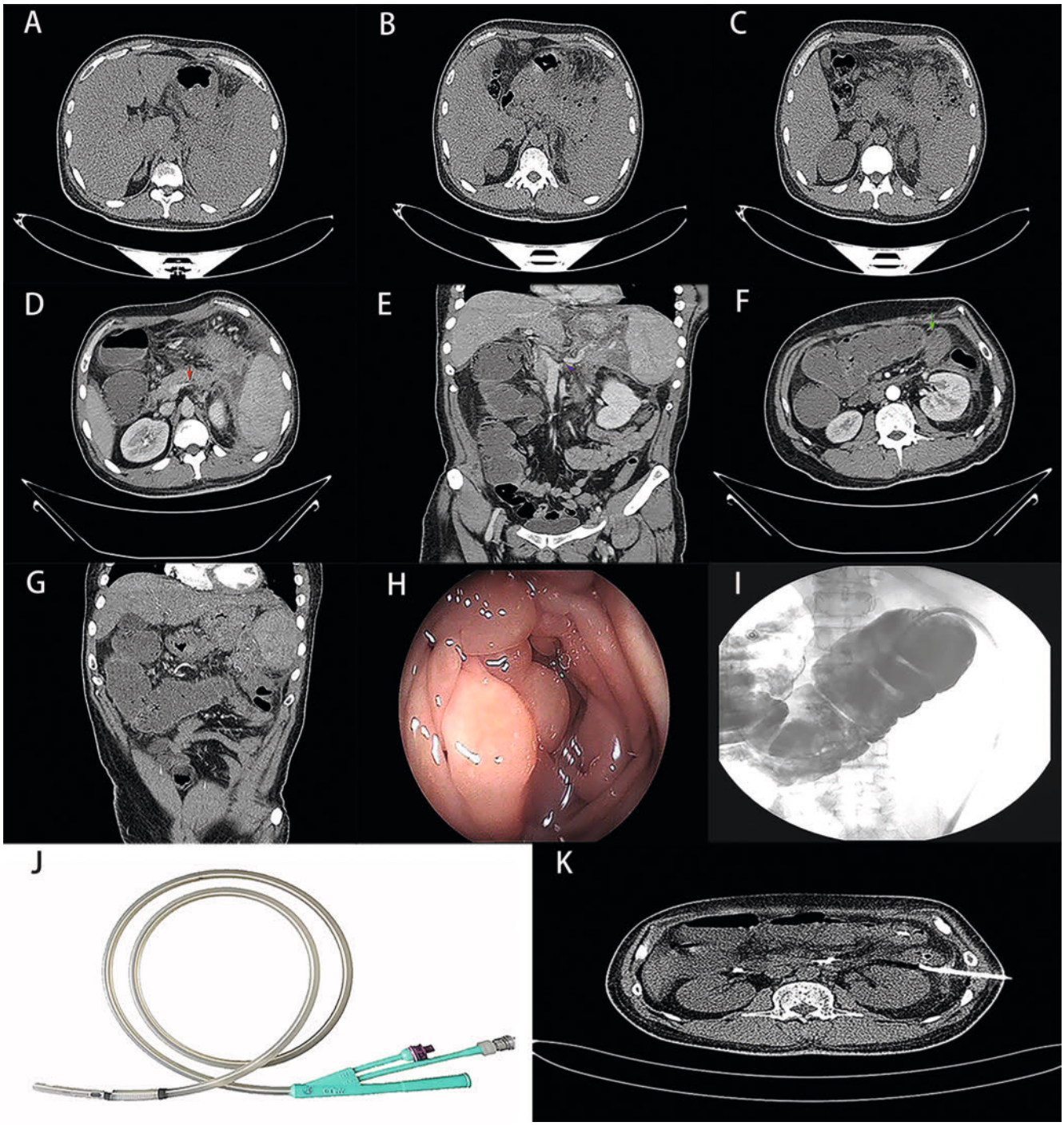

▶ **Fig. 1** The clinical data of the case. (**A**)–(**C**) CT scan of the whole abdomen on admission. The spleen is obviously enlarged.Pancreatic enlargement with an accumulation of necrotic material and gas density shadow visible in the tail of the pancreas and splenic hilum area, considering infection. (**D**) and (**E**) Enhanced CT of the whole abdomen shows splenic vein stenosis, locally indistinct. Coronal view: stenosis of splenic vein shown by the arrow. (**F**) and (**G**) Intestinal wall thickening in the splenic region of the transverse colon with proximal colonic obstruction. (**H**) and (**I**) Colonoscopy showed that intestinal mucosa edema caused by splenic curvature of the colon was obvious. (**J**) the transanal decompression tube consists of a lateral suction port and a balloon at the front and a balloon filling port, a recharge port and a drainage port from top to bottom at the rear. (**K**) Percutaneous puncture and drainage were performed under CT, and the drainage tube was placed in the left pararenal anterior space, and the shadow of the transanal decompression tube in the descending colon was visible.

nomegaly in a patient with hematological disease [5]. Secondly, a large amount of peripancreatic necrotic material in patients can form external pressure on the colon or irritate the colon wall and peri-colonic fatty tissue leading to peri-colonies and causing colonic stricture.

Most of the previously reported cases of colonic obstruction due to pancreatitis were treated with colonic surgery, for example, M. Pascual et al. [6] performed subtotal colectomy for a preoperative misdiagnosis of colonic obstruction secondary to pancreatitis as a splenic flexure tumor of the colon. Mohiuddin et al. [7] performed left hemicolectomy and splenectomy in patients presenting with colonic splenic flexure obstruction after three months of conservative treatment for severe pancreatitis. In a recent report, colonic stents were used to treat colonic strictures secondary to acute pancreatitis [8]. In Eastern countries such as Japan and China, a transanal decompression tube is often used as an alternative to emergency surgery for malignant large bowel obstruction [9]. To date, no cases of transanal decompression tubes being used for colonic obstruction due to pancreatitis have been seen.

In this case report, we emphasize that the primary focus in addressing adjacent organ complications in patients with ANP involves the drainage and elimination of peripancreatic necrotic tissue. For patients experiencing ANP along with a reversible mechanical obstruction of the colon, utilizing a transanal decompression catheter can be a preferable treatment option, potentially averting the need for additional surgical intervention.

Contributors' Statement

Y.F.C. and G.J.Z. conceived and designed the report. S.Y.W. and Y.Z. and K.Z. collected the data. G.J.Z. wrote the manuscript. Y.F.C. revised and edited the manuscript. All authors read and approved the final version for submission.

Funding Information

the Key Program of the Natural Science Foundation of Tianjin (21JCZDJC00550) | the Tianjin 131 Talents Project (201938) | Tianjin Nankai Hospital 2022 Annual Key Special Project (NKYY-IIT-2022-009-2) | Tianjin Science and Technology Project of Traditional Chinese Medicine (2022005) | the Scientifc Research Fund of Tianjin Municipal Administration of Traditional Chinese Medicine (2021006)

Acknowledgement

We thank the patient and participants from our department for their cooperation.

Conflict of Interest

The authors declare that they have no conflict of interest.

References

[1] Köklü S, Çoban Ş, Yüksel O et al. Left-Sided Portal Hypertension. Dig Dis Sci 2007; 52: 1141–1149. doi:10.1007/s10620-006-9307-x

[2] Maatman TK, Nicolas ME, Roch AM et al. Colon Involvement in Necrotizing Pancreatitis: Incidence, Risk Factors, and Outcomes. Annals of Surgery 2022; 275: 568–575. doi:10.1097/SLA.0000000000004149

[3] Kokabi N, Lee E, Echevarria C et al. Sinistral Portal Hypertension: Presentation, Radiological Findings, and Treatment Options – A Case Report. Radiology Case 2010; 4: 14–20. doi:10.3941/jrcr.v4i10.512

[4] Li Z, Li B, Wu Y et al. Acute pancreatitis associated left-sided portal hypertension with severe gastrointestinal bleeding treated by transcatheter splenic artery embolization: a case report and literature review. J Zhejiang Univ Sci B 2013; 14: 549–554

[5] Sommer T. Colonic Obstruction Caused by Adhesive Splenomegaly: Report of a Case. Diseases of the Colon & Rectum 2004; 47: 1738–1739. doi:10.1007/s10350-004-0638-4

[6] Pascual M, Pera M, Martínez I et al. Oclusión intestinal secundaria a pancreatitis que mimetiza una neoplasia estenosante del ángulo esplénico del colon. Gastroenterología y Hepatología 2005; 28: 326–328

[7] Mohiuddin S. Stenosing Lesions of the Colon Secondary to Pancreatitis. Arch Surg 1971; 102: 229. doi:10.1001/archsurg.1971.01350030067022

[8] Kimura J, Lefor AK, Fukai S et al. Use of a stent to treat colonic stenosis secondary to acute pancreatitis: A case report. Int J Surg Case Rep 2019; 61: 26–29. doi:10.1016/j.ijscr.2019.06.065

[9] Matsuda A, Yamada T, Matsumoto S et al. Short-term outcomes of a self-expandable metallic stent as a bridge to surgery vs. a transanal decompression tube for malignant large-bowel obstruction: a meta-analysis. Surg Today 2019; 49: 728–737. doi:10.1007/s00595-019-01784-y