




# Group B Streptococcus Brain Abscess in a Neonate with Bilateral Otorrhea

Emily E. Spencer, BS<sup>1</sup> Sarah Van Nostrand, DO<sup>2</sup> Shreyas Arya, MD<sup>2</sup> 

<sup>1</sup>Department of Pediatrics, Wright State University Boonshoft School of Medicine, Fairborn, Ohio

<sup>2</sup>Department of Neonatal-Perinatal Medicine, Wright State University Boonshoft School of Medicine, Dayton Children's Hospital and Pediatric Neonatology of Ohio, Dayton, Ohio

**Address for correspondence** Shreyas Arya, MD, Department of Neonatal-Perinatal Medicine, Wright State University Boonshoft School of Medicine, Dayton Children's Hospital and Pediatric Neonatology of Ohio, 1 Childrens Plaza, Dayton, OH-45404 (e-mail: shreyas703@gmail.com).

AJP Rep 2024;14:e106–e110.

## Abstract

### Keywords

- ▶ group B streptococcus
- ▶ neonate
- ▶ brain abscess
- ▶ meningitis
- ▶ otorrhea

**Introduction** Group B streptococcus (GBS) is the leading cause of bacterial sepsis and meningitis in neonates worldwide, but brain abscess secondary to GBS is extremely rare. While temporal brain abscesses have been described as a sequelae of otogenic infections in children and adults, such a presentation has not been described in neonates.

**Case Description** An 8-day-old female infant presented with a fever and irritability along with bilateral purulent otorrhea. Maternal GBS screening was negative, but the delivery was complicated by chorioamnionitis. Workup revealed neutrophilic pleocytosis in the cerebrospinal fluid and culture of the ear drainage was positive for GBS. Magnetic resonance imaging showed a circular lesion with rim enhancement within the left temporal lobe concerning for an abscess. The infant was treated with 14 days of intravenous vancomycin, cefepime, and metronidazole followed by 10 weeks of intravenous ampicillin. The hospital course was complicated by seizures and obstructive hydrocephalus requiring multiple neurosurgical interventions.

**Conclusion** Brain abscess can occur as a sequela of GBS meningitis in neonates, but they are rare. Otogenic infections require prompt evaluation and treatment as they can progress to serious central nervous infections in neonates.

Bacterial meningitis has an estimated incidence of 0.1 to 0.4 per 1,000 live births.<sup>1</sup> It is a serious condition in neonates having a mortality rate between 8.5 and 15% with up to 25% of survivors suffering mild to moderate neurological sequelae and 19% with severe long-term neurological sequelae.<sup>2–4</sup> *Streptococcus agalactiae* or group B streptococcus (GBS) is the leading cause of neonatal sepsis and meningitis worldwide.

GBS is a Gram-positive commensal bacteria that is known to colonize the gastrointestinal and genitourinary tracts of

15 to 30% of women, which puts neonates at risk for vertical transmission during the intrapartum period.<sup>5</sup> Infection due to GBS can be classified as early-onset (birth to 6 days of life) which is transmitted vertically and late-onset (7 to 89 days of life) which is often acquired by horizontal transmission from colonized mothers or household contacts.<sup>6</sup> In the past few decades, there has been a progressive decline in the incidence of bacterial meningitis owing to GBS screening and treatment guidelines for pregnant women and timely

received

January 7, 2024

accepted after revision

February 19, 2024

accepted manuscript online

February 26, 2024

DOI <https://doi.org/10.1055/a-2275-9482>.

ISSN 2157-6998.

© 2024. The Author(s).

This is an open access article published by Thieme under the terms of the Creative Commons Attribution-NonDerivative-NonCommercial-License, permitting copying and reproduction so long as the original work is given appropriate credit. Contents may not be used for commercial purposes, or adapted, remixed, transformed or built upon. (<https://creativecommons.org/licenses/by-nc-nd/4.0/>)

Thieme Medical Publishers, Inc., 333 Seventh Avenue, 18th Floor, New York, NY 10001, USA

evaluation and treatment of infants with maternal risk factors for infection.<sup>7</sup>

Brain abscess can complicate up to 10% of cases of neonatal meningitis<sup>8</sup> and is significantly more common in Gram-negative bacterial meningitis,<sup>9</sup> but brain abscess due to GBS infection are extremely rare. We describe the case of a neonate who presented with the unusual symptom of bilateral otorrhea since birth and was subsequently found to have a brain abscess caused by GBS, which resulted in a complicated neurological course.

## Case Description

An 8-day-old female infant presented to the emergency room (ER) with a fever of 101.2F at home and bilateral otorrhea. On physical examination the infant was noted to be alert but irritable and thick purulent greenish-yellow discharge was noted from both ears. Vital signs were normal except for a temperature of 100 F. At home, the infant was exclusively breast fed with good urine and stool output and she was noted to be only 3% below birth weight. Due to the infant's age and presentation, a full septic workup (including blood, urine, and cerebrospinal fluid [CSF] culture and herpes simplex virus [HSV] studies) was done. Additionally, a bacterial culture of the ear drainage was also obtained. The infant was started on ampicillin, gentamicin, and acyclovir and admitted to the neonatal intensive care unit (NICU) for further evaluation and treatment.

The infant was born at 39 weeks' gestation via spontaneous vaginal delivery to a 21-year-old gravida 2 para 2 mother. Rupture of membranes was 7 hours prior to delivery and all maternal serologies including her testing for GBS were negative. Pregnancy was complicated by maternal anxiety and depression (for which she was on sertraline), pregnancy-induced hypertension, and intrauterine growth restriction. At delivery, amniotic fluid was noted to be meconium stained but the infant was not in any distress and Apgar scores were 8 and 9 at 1 and 5 minutes, respectively. The birth weight was 2,705 g. Mother was noted to have a fever of 101 F at delivery with evidence of chorioamnionitis and started on antibiotics. Due to maternal chorioamnionitis, infant was admitted to the NICU where a screening complete blood cell count showed a white blood cell (WBC) count of 18,000/ $\mu$ L with 7% banded and 62% segmented neutrophils. A blood culture was also obtained from the umbilical cord which was eventually negative. The infant otherwise had normal vital signs and was feeding well during the birth hospitalization, so antibiotics were not started per recommendations from the neonatal early-onset sepsis calculator<sup>10</sup> and she was discharged home at 48 hours of life. However, the mother reported that she noticed bilateral ear drainage since shortly after birth and the infant failed her hearing screen bilaterally.

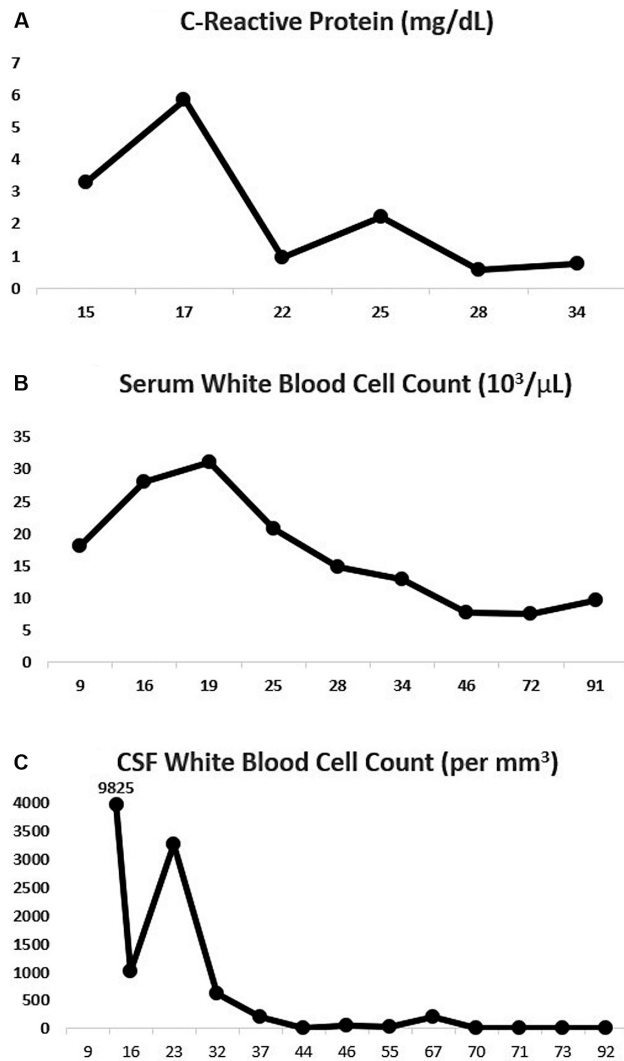
Septic workup obtained in the ER was significant for a grossly abnormal CSF analysis with low glucose of 20 mg/dL (reference range 40–70 mg/dL), elevated protein of 198 (reference range 15–45 mg/dL), WBC count of 9,825/ $\text{mm}^3$

(reference range 0–5/ $\text{mm}^3$ ) with 85% neutrophils, and red blood cell count of 2,525/ $\text{mm}^3$  (reference range 0/ $\text{mm}^3$ ) concerning for bacterial meningitis, so antibiotics were switched to vancomycin and cefepime at meningitic dosing and a pediatric infectious disease specialist was consulted. Interestingly, bacterial culture of the ear drainage and a screening nasopharyngeal culture on admission to the NICU were both positive for GBS. However, blood, urine, and CSF bacterial cultures and HSV polymerase chain reaction studies remained negative.

Soon after admission, the infant was noted to have multiple apneic and bradycardic events associated with gaze abnormalities (downwards and sideways gaze), concerning for seizures, so the infant was intubated and placed on mechanical ventilation and loaded with phenobarbital. An electroencephalogram (EEG) was obtained which confirmed multiple seizures originating from the left temporo-occipital region. A screening bedside head ultrasound was normal but brain magnetic resonance imaging (MRI) with and without contrast showed a circular lesion demonstrating a partially enhancing rim and adjacent edema within the left posteroinferior temporal lobe measuring approximately 25 mm in diameter, concerning for an early abscess. At this point, the neurosurgery team was consulted who recommended broadening antibiotic coverage by adding metronidazole for anaerobic coverage. After initiation of phenobarbital the seizures abated so EEG was discontinued, and the infant was extubated and slowly weaned off all respiratory support, 4 days after admission. To monitor response to antibiotic treatment, serial C-reactive protein levels and CSF analyses were also obtained (**Fig. 1**). CSF bacterial cultures remained negative throughout the course of treatment.

A repeat brain MRI 1 week after admission (day of life 15) showed that the left temporal lobe abscess had increased in size (30.1 mm  $\times$  20.3 mm) and there was purulent material layering within the lateral ventricles (left greater than right) with increased size of the ventricular system (**Fig. 2A**), so decision was made to drain the abscess under ultrasound visualization via a left temporal burr hole. A right frontal external ventricular drain was also inserted via a right frontal burr hole (**Fig. 2B**).

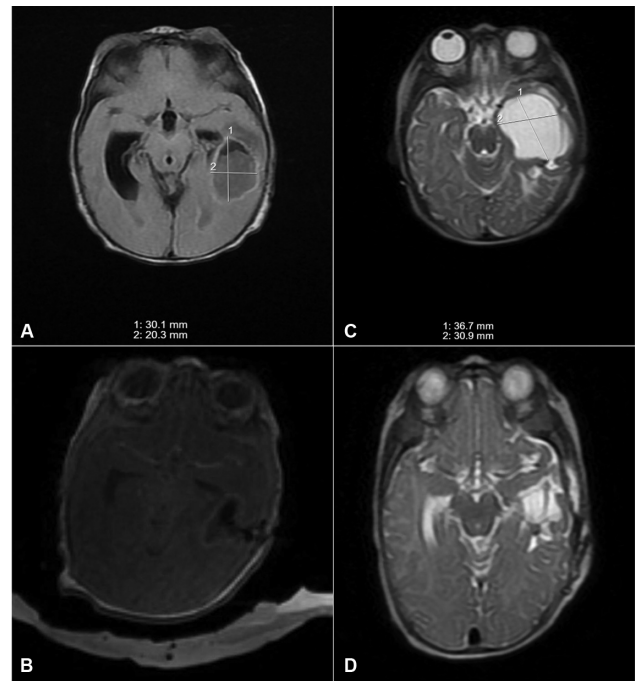
Over the next few weeks, the abscess cavity remained decompressed, but the temporal horn of the left lateral ventricle progressively enlarged, measuring about 36.7 mm  $\times$  30.9 mm on day of life 69 (**Fig. 2C**), so decision was made to insert a left temporal horn ventricular access device (VAD) for obstructive hydrocephalus. With multiple and frequent taps of the VAD there was some initial improvement in the ventricular size but eventually the temporal horn of the left lateral ventricle continued to enlarge requiring placement of a left frontal ventriculoperitoneal (VP) shunt. The VP shunt needed revision with placement of a catheter into the left temporal horn cyst, which eventually led to reduction in size on day of life 104 (**Fig. 2D**). In total, the infant received 14 days of intravenous vancomycin, cefepime, and metronidazole and 10 weeks of intravenous ampicillin monotherapy until discharge.



**Fig. 1** Line graphs depicting trends of (A) C-reactive protein (mg/dL), (B) serum white blood cell count ( $10^3/\mu\text{L}$ ), (C) cerebrospinal fluid (CSF) white blood cell count (per  $\text{mm}^3$ ) on the y-axis and infant age in days of life on the x-axis.

## Discussion

Guidelines for the prevention of perinatal transmission of GBS using intrapartum antibiotic prophylaxis (IAP) were first published in 1996 by the Center for Disease Control and Prevention in consensus with the American Academy of Pediatrics and American College of Obstetrics and Gynecology.<sup>6</sup> Since then these recommendations have undergone several iterations and have evolved from an earlier risk factor-based approach to now universal screening for GBS in pregnant women at 36 to 37 weeks' gestation.<sup>11–13</sup> The implementation of the universal screening program and the use of IAP has resulted in an almost eightfold reduction in early-onset GBS sepsis from 1.8 cases per 1,000 live births (1990) to 0.23 cases per 1,000 live births (2015).<sup>14</sup> Although a positive prenatal GBS culture increases the likelihood of early-onset GBS infection in neonates, in the current era of universal screening more than 60% cases of early-onset



**Fig. 2** Serial brain magnetic resonance imaging showing: (A) Left temporal lobe abscess (30.1 mm  $\times$  20.3 mm) and bilateral ventriculomegaly on day of life 15. (B) Decompression of the left temporal lobe abscess via a left temporal burr hole and decreased ventricular size following external ventricular drain placement via a right frontal burr hole on day of life 16. (C) Increased size of the trapped temporal horn of left lateral ventricle (36.7 mm  $\times$  30.9 mm) on day of life 69. (D) Decrease in size of the temporal horn of left lateral ventricle following placement of left frontal ventriculoperitoneal shunt and revision with placement of a catheter into the left temporal horn cyst on day of life 104.

disease occur in infants of mothers with a negative prenatal GBS screen.<sup>15</sup>

However, despite the overwhelming success of the screening program, IAP has had no effect on the incidence of late-onset sepsis.<sup>14</sup> This is because maternal prenatal GBS testing does not always accurately predict the mother's GBS status during the postpartum period and horizontal transmission from colonized mothers is thought to be the major mechanism implicated in late-onset GBS disease.<sup>16</sup> In a prospective cohort study by Berardi et al, rectovaginal GBS colonization was found in 64% of mothers at the time of late-onset GBS infection diagnosis in infants and an additional 6% of mothers had GBS mastitis.<sup>17</sup>

In the case we present, the mother's GBS screening was negative but the intrapartum period was complicated by chorioamnionitis which increases the risk for neonatal infection.<sup>18</sup> The infant in our case most likely acquired a focal infection (otitis) by vertical transmission, as evidenced by the ear discharge reported shortly after birth, but the overall well appearing status at the time of discharge. This infection then progressed to GBS meningitis and brain abscess in the days that followed, prior to presentation to the ER on the 8th day of life. GBS meningitis is seen in only a minority of early-onset disease but can complicate up to 25 to 30% of late-onset disease.<sup>14</sup> It presents with nonspecific symptoms of temperature instability (fever or hypothermia), irritability or

lethargy, respiratory distress or apnea, poor feeding, and seizures.<sup>19,20</sup> Additional complications include the development of hydrocephalus, subdural effusion, cerebral venous thrombosis, cerebral infarcts, and brain abscess.<sup>21</sup>

Brain abscesses are significantly more common with Gram-negative bacteria like *Citrobacter*, *Serratia*, *Proteus*, and *Escherichia coli*<sup>9</sup> but brain abscess secondary to GBS are extremely rare. In a case reported in 2016, Giannattasio et al described a 6-week-old presenting with irritability, poor feeding, and fever who was found to have GBS meningitis and brain abscess. The infant showed complete resolution of abscess with a 4-week course of meropenem and ampicillin, without any neurosurgical interventions and had normal neurodevelopmental outcomes. However, the size of abscess in their case was significantly smaller at 9 × 6 mm compared to the 25-mm diameter abscess seen in our case.<sup>22</sup> In 2009, Pasternak et al reported the case of an 8-week-old who presented with irritability, projectile vomiting, rapidly increasing head size, and left abducens nerve palsy. MRI showed a large complex cystic lesion in the left temporo-occipital lobe with mass effect and signs of obstructive hydrocephalus. Similar to our case, their patient required neurosurgical drainage and prolonged duration of intravenous ampicillin followed by intravenous ceftriaxone for a total of 16 weeks until complete resolution of abscess.<sup>23</sup> While brain abscesses in the temporal region have been described following otogenic infections (like chronic otitis media) in children and adults,<sup>24</sup> such a presentation has not been described in neonates. It is important to note that, majority of GBS implicated in neonatal disease is susceptible to beta-lactam antibiotics and reports of penicillin-binding protein mutations leading to resistance are extremely rare.<sup>25</sup> Thus, due to its narrow spectrum penicillin is considered first-line therapy for all GBS infections though ampicillin is considered an acceptable alternative<sup>6</sup> and both drugs have excellent central nervous system (CNS) penetration.<sup>26</sup>

The imaging modality of choice for diagnosing a brain abscess is a contrast-enhanced MRI which typically shows a circumscribed area of hypoattenuation with surrounding contrast enhancing rim.<sup>27</sup> Antibiotic therapy alone may be adequate for smaller solitary abscesses (less than 2 cm in diameter), but surgical drainage is often required for larger lesions. Ultrasound is of value in delineating and accessing the abscess for drainage.<sup>27</sup> In a case series of 54 children, majority only needed one aspiration<sup>28</sup>; however, those with an increase in size despite drainage and adequate antibiotic therapy required additional procedures like craniotomy for evacuation of pus and debridement of surrounding brain parenchyma and placement of ventricular drainage devices for obstructive hydrocephalus. No prospective studies have been performed to determine the adequate length of antibiotic therapy for brain abscesses, but experts recommend at least 4 to 6 weeks of treatment with serial imaging to ensure resolution of abscess. Longer antibiotic durations may be needed for tubercular brain abscess or in cases that are slow to resolve.<sup>27</sup> Brain abscess in neonates have a grave prognosis with a case series of 30 neonates describing 4 deaths and an

intelligence quotient below 80 at 2 years of age in 76% of the survivors<sup>21</sup>.

## Conclusion

While exceedingly rare, brain abscess can occur as a sequela of GBS meningitis in neonates. Otogenic infections require prompt evaluation and treatment in neonates because of their risk of progression to serious CNS infections like meningitis and brain abscess. These infections require prolonged antibiotic courses and at times advanced neurosurgical interventions for treatment and are associated with an unfavorable prognosis and adverse neurodevelopmental outcomes in neonates.

## Conflict of Interest

None declared.

## References

- 1 Stevens JP, Eames M, Kent A, Halket S, Holt D, Harvey D. Long term outcome of neonatal meningitis. *Arch Dis Child Fetal Neonatal Ed* 2003;88(03):F179–F184
- 2 Libster R, Edwards KM, Levent F, et al. Long-term outcomes of group B streptococcal meningitis. *Pediatrics* 2012;130(01):e8–e15
- 3 Gaschignard J, Levy C, Romain O, et al. Neonatal bacterial meningitis: 444 cases in 7 years. *Pediatr Infect Dis J* 2011;30(03):212–217
- 4 Heath PT, Nik Yusoff NK, Baker CJ. Neonatal meningitis. *Arch Dis Child Fetal Neonatal Ed* 2003;88(03):F173–F178
- 5 Mosayebi Z, Mohammadi M, Mohammadi M, Jafari A, Movahedian AH. Early-onset meningitis with group b streptococcus: the case of a female neonate with brain abscess in Iran. *J Compr Pediatr* 2017;8(04):e12899
- 6 Puopolo KM, Lynfield R, Cummings JJ Committee on Fetus and Newborn Committee on Infectious Diseases. Management of infants at risk for group B streptococcal disease. *Pediatrics* 2019;144(02):e20191881
- 7 Verani JR, McGee L, Schrag SJ Division of Bacterial Diseases, National Center for Immunization and Respiratory Diseases, Centers for Disease Control and Prevention (CDC) Prevention of perinatal group B streptococcal disease—revised guidelines from CDC, 2010. *MMWR Recomm Rep* 2010;59(RR-10):1–36
- 8 Ouchenir L, Renaud C, Khan S, et al. The epidemiology, management, and outcomes of bacterial meningitis in infants. *Pediatrics* 2017;140(01):e20170476
- 9 Unhanand M, Mustafa MM, McCracken GH Jr, Nelson JD. Gram-negative enteric bacillary meningitis: a twenty-one-year experience. *J Pediatr* 1993;122(01):15–21
- 10 Kuzniewicz MW, Puopolo KM, Fischer A, et al. A quantitative, risk-based approach to the management of neonatal early-onset sepsis. *JAMA Pediatr* 2017;171(04):365–371
- 11 Rocchetti TT, Marconi C, Rall VLM, Borges VTM, Corrente JE, da Silva MG. Group B streptococci colonization in pregnant women: risk factors and evaluation of the vaginal flora. *Arch Gynecol Obstet* 2011;283(04):717–721
- 12 Baltimore RS. Consequences of prophylaxis for group B streptococcal infections of the neonate. *Semin Perinatol* 2007;31(01):33–38
- 13 Prevention of Group B Streptococcal Early-Onset Disease in Newborns. Accessed December 9, 2023 at: <https://www.acog.org/clinical/clinical-guidance/committee-opinion/articles/2020/02/prevention-of-group-b-streptococcal-early-onset-disease-in-newborns>

- 14 Nanduri SA, Petit S, Smelser C, et al. Epidemiology of invasive early-onset and late-onset group B streptococcal disease in the United States, 2006 to 2015: multistate laboratory and population-based surveillance. *JAMA Pediatr* 2019;173(03):224–233
- 15 Van Dyke MK, Phares CR, Lynfield R, et al. Evaluation of universal antenatal screening for group B streptococcus. *N Engl J Med* 2009;360(25):2626–2636
- 16 Berardi A, Trevisani V, Di Caprio A, et al. Understanding factors in group B streptococcus late-onset disease. *Infect Drug Resist* 2021;14:3207–3218
- 17 Berardi A, Rossi C, Lugli L, et al; GBS Prevention Working Group, Emilia-Romagna. Group B streptococcus late-onset disease: 2003–2010. *Pediatrics* 2013;131(02):e361–e368
- 18 Ren J, Qiang Z, Li YY, Zhang JN. Biomarkers for a histological chorioamnionitis diagnosis in pregnant women with or without group B streptococcus infection: a case-control study. *BMC Pregnancy Childbirth* 2021;21(01):250
- 19 Ku LC, Boggess KA, Cohen-Wolkowicz M. Bacterial meningitis in infants. *Clin Perinatol* 2015;42(01):29–45, vii–viii
- 20 Hristeva L, Booy R, Bowler I, Wilkinson AR. Prospective surveillance of neonatal meningitis. *Arch Dis Child* 1993;69(1 Spec No):14–18
- 21 Renier D, Flandin C, Hirsch E, Hirsch JF. Brain abscesses in neonates. A study of 30 cases. *J Neurosurg* 1988;69(06):877–882
- 22 Giannattasio A, Raimondi F, D'Amico A, Lama S, Spagnuolo MI. Late-onset brain abscess due to group B Streptococcus. *Case Rep Perinat Med* 2016;5(02):165–167
- 23 Pasternak JD, Fulford M, Gunnarsson T, Provias J, Singh SK. An unexpected intracranial pressure crisis: infant brain abscess of unusual aetiology. *Childs Nerv Syst* 2009;25(03):377–381
- 24 Duarte MJ, Kozin ED, Barshak MB, et al. Otogenic brain abscesses: a systematic review. *Laryngoscope Investig Otolaryngol* 2018;3(03):198–208
- 25 Metcalf BJ, Chochua S, Gertz RE Jr, et al; Active Bacterial Core surveillance team. Short-read whole genome sequencing for determination of antimicrobial resistance mechanisms and capsular serotypes of current invasive Streptococcus agalactiae recovered in the USA. *Clin Microbiol Infect* 2017;23(08):574.e7–574.e14
- 26 Nau R, Sörgel F, Eiffert H. Penetration of drugs through the blood-cerebrospinal fluid/blood-brain barrier for treatment of central nervous system infections. *Clin Microbiol Rev* 2010;23(04):858–883
- 27 Sheehan JP, Jane JA, Ray DK, Goodkin HP. Brain abscess in children. *Neurosurg Focus* 2008;24(06):E6
- 28 Goodkin HP, Harper MB, Pomeroy SL. Intracerebral abscess in children: historical trends at Children's Hospital Boston. *Pediatrics* 2004;113(06):1765–1770