

Firsttrimester Diagnosis and Therapy @ 11–13⁺⁶ Weeks of Gestation – Part 1

Guideline of the DEGUM, ÖGUM, SGUMGG, DGGG, ÖGG, Gynecologie Suisse, DGPM, DGPGM, BVF, ACHSE (AWMF S2e LL 085-002 1.1.2024)
(<https://register.awmf.org/de/leitlinien/detail/085-002>)

Ersttrimester Diagnostik und Therapie @ 11–13⁺⁶ Schwangerschaftswochen – Teil 1

Leitlinie der DEGUM, ÖGUM, SGUMGG, DGGG, ÖGG, Gynecologie Suisse, DGPM, DGPGM, BVF, ACHSE (AWMF S2e LL 085-002 1.1.2024)
(<https://register.awmf.org/de/leitlinien/detail/085-002>)

Authors

Constantin von Kaisenberg¹, Peter Kozlowski², Karl-Oliver Kagan³, Markus Hoopmann³, Kai-Sven Heling⁴, Rabih Chaoui⁴, Philipp Klaritsch⁵, Barbara Pertl⁶, Tilo Burkhardt⁷, Sevgi Tercanli⁸, Jochen Frenzel⁹, Christine Mundlos¹⁰

Affiliations

- 1 Department of Obstetrics and Gynecology, Hannover Medical School, Hannover, Germany
- 2 Praenatal-Medicine and Genetics Düsseldorf, MVZ Amedes für Pränatal-Medizin und Genetik GmbH, Düsseldorf, Germany
- 3 Department of Obstetrics and Gynecology, University Hospital Tübingen, Tübingen, Germany
- 4 Praxis, Prenatal Diagnosis and Human Genetics, Berlin, Germany
- 5 Department of Obstetrics and Gynecology, Medical University Graz, Graz, Austria
- 6 Privatlinik Graz Ragnitz, Pränatalzentrum Graz Ragnitz, Graz, Austria
- 7 Department of Obstetrics, University Hospital Zurich, Zurich, Switzerland
- 8 Praxis, Ultraschall Freie Strasse, Basel, Switzerland
- 9 Praxis, Saarbrücken, Germany
- 10 ACHSE Wissensnetzwerk, ACHSE, Berlin, Germany

Keywords

first trimester screening, nuchal translucency, chromosomal disorders, malformation, preeclampsia

Schlüsselwörter

Ersttrimester-Screening, Nackentransparenz, Chromosomenstörungen, Fehlbildungen, Präeklampsie

received 17.2.2024

accepted 1.3.2024

published online 2024

Bibliography

Ultraschall in Med

DOI 10.1055/a-2280-4756

ISSN 0172-4614

© 2024, Thieme. All rights reserved.

Georg Thieme Verlag KG, Rüdigerstraße 14, 70469 Stuttgart, Germany

Correspondence

Prof. Dr. Constantin von Kaisenberg
Hannover Medical School, Department of Obstetrics and Gynecology, Carl-Neuberg-Straße 1, 30625 Hannover, Germany
vonkaisenberg.constantin@mh-hannover.de

ABSTRACT

This extensive AWMF 085-002 S2e-guideline “First Trimester Diagnosis and Therapy @ 11–13⁺⁶ Weeks of Gestation” has systematically analyzed high-quality studies and publications and the existing evidence (evidence tables) and produced recommendations (level of recommendation, level of evidence, strength of consensus).

This guideline deals with the following topics in the context of the 11–13⁺⁶ weeks scan: the legal basis, screening for anatomical malformations, screening for chromosomal defects, quality assessment and audit, screening for preeclampsia and FGR, screening for preterm birth, screening for abnormally invasive placenta (AIP) and placenta accreta spectrum (PAS), screening for velamentous cord insertion and vasa praevia, screening for diabetes mellitus and LGA.

Screening for complications of pregnancy can best be carried out @ 11–13⁺⁶ weeks of gestation. The issues of how to identify malformations, chromosomal abnormalities and certain disorders of placentation (high blood pressure and protein-

uria, intrauterine growth retardation) have been solved. The problem of how to identify placenta percreta and vasa previa has been partially solved. What is still unsolved is how to identify disorders of glucose metabolism and preterm birth.

In the first trimester, solutions to some of these problems are available: parents can be given extensive counselling and the risk that a pregnancy complication will manifest at a later stage can be delayed and reduced. This means that screening is critically important as it helps in decision-making about the best way to manage pregnancy complications (prevention and intervals between follow-up examinations).

If no treatment is available and if a termination of pregnancy is considered, the intervention can be carried out with far lower complications compared to the second trimester of pregnancy. In most cases, further examinations are not required and the parents can be reassured. A repeat examination at around week 20 of gestation to complete the screening for malformations is recommended.

Note: The guideline will be published simultaneously in the official journals of both professional societies (i.e. *Ultraschall in der Medizin/European Journal of Ultrasound* for the DEGUM and *Geburtshilfe und Frauenheilkunde* for the DGGG).

ZUSAMMENFASSUNG

In dieser umfassenden AWMF 085-002 S2e-Leitlinie „Ersttrimester Diagnostik und Therapie @ 11–13⁺⁶ Schwangerschaftswochen“ werden die qualitativ hochwertigen Studien und Publikationen bzw. die vorliegende Evidenz (Evidence Tables) systematisch analysiert und Empfehlungen formuliert (Empfehlungsgrad, Evidenzgrad, Konsensstärke).

Die LL behandelt zum Zeitpunkt 11–13⁺⁶ Schwangerschaftswochen folgende Themen: rechtliche Grundlagen, Screening

für Fehlbildungen, Screening für Chromosomenstörungen, Qualitätssicherung und Audit, Screening für Präeklampsie und FGR, Screening für Frühgeburt, Screening für Abnormal Invasive Placenta (AIP) und Placenta Accreta Spectrum (PAS), Screening für Insertio velamentosa und Vasa praevia, Screening für Diabetes mellitus und LGA. Der Zeitpunkt 11–13⁺⁶ Schwangerschaftswochen ermöglicht die Suche nach Schwangerschaftsproblemen. Gelöst ist die Suche nach Fehlbildungen, Chromosomenstörungen und Plazentaproblemen (hoher Blutdruck und Eiweißausscheidung, intrauterine Wachstumsretardierung). Zum Teil gelöst ist die Suche nach Placenta percreta und Vasa praevia. Ungelöst ist die Suche nach Glukosestoffwechselstörungen und Frühgeburt.

Für einen Teil der Probleme existieren im ersten Trimenon Lösungsansätze, die Eltern können intensiv beraten werden; die Wahrscheinlichkeit, dass sich ein Schwangerschaftsproblem später manifestiert, kann hinausgezögert und gesenkt werden. Dies macht die Untersuchung für die Entscheidungsfindung bezüglich des besten Managements (Intervalle der Follow-up-Untersuchungen und Prävention) unverzichtbar. Besteht keine Therapie bzw. wird ein Schwangerschaftsabbruch erwogen, kann dieser mit viel niedrigeren Komplikationsraten als im zweiten Trimenon angeboten werden. In den meisten Fällen sind weiterführende Untersuchungen nicht erforderlich und die Eltern können beruhigt werden. Eine erneute Untersuchung um 20 Schwangerschaftswochen zur Vervollständigung der Fehlbildungsdiagnostik wird empfohlen.

Hinweis: Die Leitlinie wird gleichzeitig in den offiziellen Zeitschriften beider Fachgesellschaften (d.h. *Ultraschall in der Medizin/European Journal of Ultrasound* für die DEGUM und *Geburtshilfe und Frauenheilkunde* für die DGGG) veröffentlicht.

1 Intention and Scope

1.1 Purpose and objectives

The pace of change in sonographic, biochemical and molecular screening methods @ 11–13⁺⁶ weeks of gestation (GW) has made it necessary to present suggestions for a structured and quality-assessed approach in order to offer patients the best possible advice, diagnosis, screening and prevention.

Purpose: to provide clear information which is easy to understand about the methods currently available in screening for

- malformations,
- chromosomal abnormalities,
- disorders of placentation (preeclampsia, growth restriction, fetal death, miscarriage),
- preterm birth,
- abnormally invasive placenta (AIP)/placenta accreta spectrum disorder (PAS),
- velamentous cord insertion, vasa praevia,
- diabetes mellitus and macrosomia;

to outline the capabilities of the individual sonographic, biochemical and molecular methods; to describe the currently recommended standard approach as well optional approaches. The purpose is also to provide information about how later manifestations of high risks identified in the first trimester of pregnancy can be reduced by taking preventive measures as well as providing information on how an individually tailored management of pregnancy would look like.

2 Introduction

2.1 Screening and diagnosis @ 11–13⁺⁶ weeks of gestation

The aim of screening in the first trimester of pregnancy @ 11⁺⁰–13⁺⁶ weeks of gestation is to identify risk factors which require a further diagnostic workup and/or an intervention at an early stage in pregnancy in a self-selected population.

This screening should be understood as an offer to provide examinations without cause undertaken voluntarily (opportunistically).

Screening includes taking the medical history of the mother and fetus, carrying out ultrasound scans, and reviewing the biochemical, biophysical and genetic factors of mother and fetus.

The concept presented here is evidence-based and is not part of the Maternity Guideline.

First-trimester screening is quality assured.

This guideline aims to provide the persons providing care with a systematic overview of the current screening options @ 11–13⁺⁶ weeks of gestation.

When?

11⁺⁰–13⁺⁶ weeks of gestation (CRL 45–84 mm)

Who?

Specialists in Obstetrics and Gynecology who meet the standards described in this guideline (screening must be carried out by a physician).

Ultrasound equipment

Minimum **technical requirements for ultrasound equipment** must comply with:

- **real-time grey-scale** ultrasound (**2D, B-mode imaging**),
 - **color Doppler** (power Doppler), **pulsed Doppler**
 - **M-mode**
 - **transabdominal ultrasound probes** (electronic and/or mechanical curved array or linear, wideband, frequency range 3.0–7.5 MHz), if necessary.
 - **transvaginal ultrasound probes** (electronic and/or mechanical, wideband, high frequency (4.0–10.0 MHz)
 - adjustable **acoustic power** output control, standard parameters (**TIs, Tlb, MI**)
 - **freeze-frame** and **online zoom capability**
 - video **cineloop** capability
 - electronic calipers (minimum discrimination **0.1 mm**)
 - storage and print options for images
 - regular technical inspections (refer to ultrasound agreement)
- (EC, strong consensus 10/10)

Documentation

The information provided to the patient along with the patient's written consent to the examination must be documented.

Safety of ultrasound

Based on the ALARA principle (as low as reasonably achievable)

Approach when the examination cannot be carried out in accordance with the standards of this guideline

If the examination cannot be carried out in accordance with the standards of this guideline:

the patient *must* be referred to an institution where screening can be carried out in accordance with this guideline,

the patient *must* be informed in detail about what is included in first-trimester screening:

- **counselling before** and **after** examinations
- screening for **malformations**

- screening for **preeclampsia and growth restriction**,
- screening for chromosomal disorders
- screening for further **disorders of pregnancy** (if indicated) and what the **potential results** and **consequences** of first-trimester screening can be.

Counselling *must* ensure that **first-trimester screening is offered to every patient in accordance with the standards in this guideline**.

If one of the risks is found to be elevated following first-trimester screening or NIPT, the pregnant woman *must* be quickly transferred to an institution which can carry out further investigations to avoid unnecessary distress.

(EC, strong consensus 11/11)

2.2 Multiple pregnancies

The AWMF 015–087 S2e-guideline on the monitoring and care of twin pregnancies (1.5.2020) [5] describes the care of twin pregnancies (chapter 3 and following).

3 Legal Basis

3.1 Information and counselling

The requirement that screening is carried out by medical specialists means that if a service cannot be provided in accordance with state-of-the-art science and technology, patients will be referred to an institution which is able to provide a state-of-the-art service. Not doing so amounts to falling below the required standard and would mean that the facility providing substandard services can be held liable.

Germany

Genetic Diagnosis Act (GenDG), Maternity Guidelines, Patient Rights Act (PRG), Act on Assistance to Avoid and Cope with Conflicts in Pregnancy (SchKG), German Civil Code (BGB).

Austria

Mother-Child Booklet, Genetic Engineering Act (GTG)

Switzerland

Federal Law on Genetic Testing in Humans (GUMG), Swiss Health Care Benefits Ordinance (KLV)

Letter by Experts No. 52: Prenatal non-invasive risk estimation of fetal aneuploidies

Letter by Experts No. 80: First trimester screening for preeclampsia

Recommendations on ultrasound examinations in pregnancy

3.2 Termination of Pregnancy

Germany: **Strafgesetzbuch** [= German Criminal Code] (**StGB § 218**)

Austria: **Strafgesetzbuch** [= Austrian Criminal Code] [**§ 97 (1) Abs. 1** and **Abs. 2–3**]

Switzerland: **Strafgesetzbuch** [= Swiss Criminal Code] (**§ 119, Abs. 1** and **Abs. 2**)

Laws and guidelines on first-trimester screening in Germany, Austria and Switzerland.

First-trimester screening must be carried out in accordance with the following laws and codes of practice:

Germany

- Maternity Guidelines [9]
- Guidelines on prenatal risk evaluation/examinations [7,8]
- Genetic Diagnosis Act (**GenDG**) [6]
- Patient Rights Act (**PRG**) § 630 BGB [10]
- Act on Assistance to Avoid and Cope with Conflicts in Pregnancy (**SchKG**) [11]
- German Criminal Code (**StGB** § 218a Absatz 2) [15]

Austria

- Mother-Child-Booklet Regulation (**BGBl** II Nr. 470/2001) [18]
- Genetic Engineering Act (**GTG**) [12]
- Austrian Criminal Code (**StGB** § 97) [16]

Switzerland

- Federal Law on Genetic Testing in Humans (**GUMG**) [13]
- Swiss Criminal Code (**StGB** § 119) [17]
- Swiss Health Care Benefits Ordinance (**KLV**) [19]

(Strong consensus 10/10)

4 Screening for Malformations @ 11–13⁺⁶ Weeks of Gestation (Biometry and Anatomy)

Certain malformations can always be detected in the first trimester of pregnancy, some malformations may be detected in part, and some cannot yet be diagnosed in the first trimester (*direct screening*) (► **Table 1, 2**).

4.1 Fetal biometry

The reference curves (formulas) of one of the five authors listed below *must* be used to **determine gestational age** between 11–13⁺⁶ GW based on **crown-rump length (CRL)**: Robinson et al., 1975, McLennan et al., 2008, Sahota et al., 2009, Verburg et al., 2008, or Papageorghiou et al., 2014.

Measurement of the **CRL** *must always* be used to **determine gestational age** except for IVF pregnancies.

The **date of conception** *must* be used to determine the gestational age of IVF pregnancies.

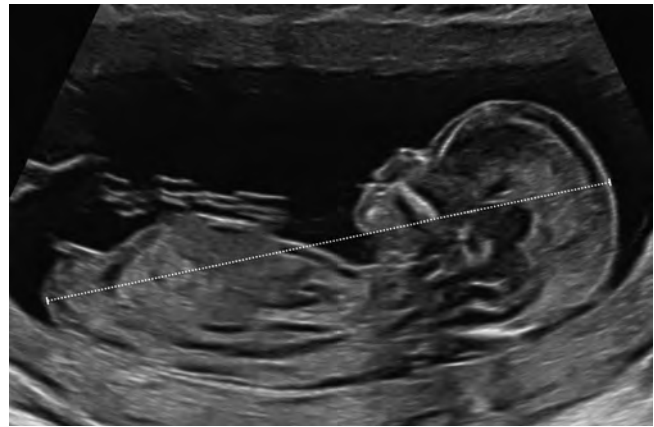(Level of recommendation A, level of evidence 1a, strong recommendation 10/10)

The following *must* be measured between 11–13⁺⁶ GW: **CRL, NT, BPD**

The following *should* be additionally measured between 11–13⁺⁶ GW (optional): **FHR, HC, AC, FL, NB, TR, DV, IT, UA, Cx**

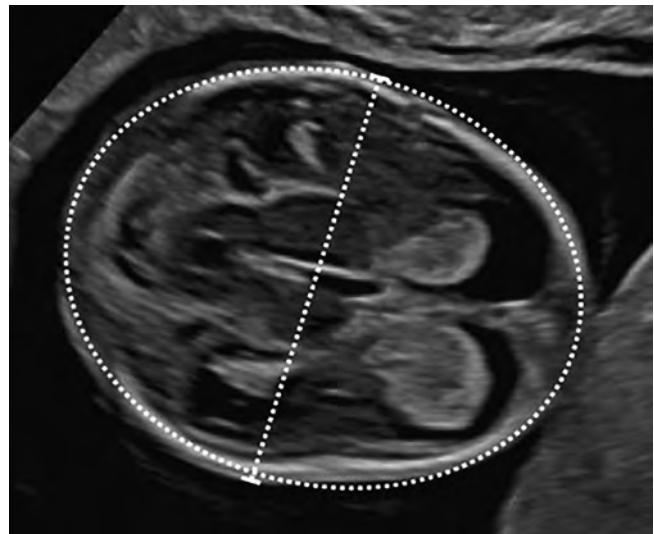
(Level of recommendation EC, level of evidence 5, strong recommendation 11/11)

Crown-rump length (CRL) (► **Fig. 1**)



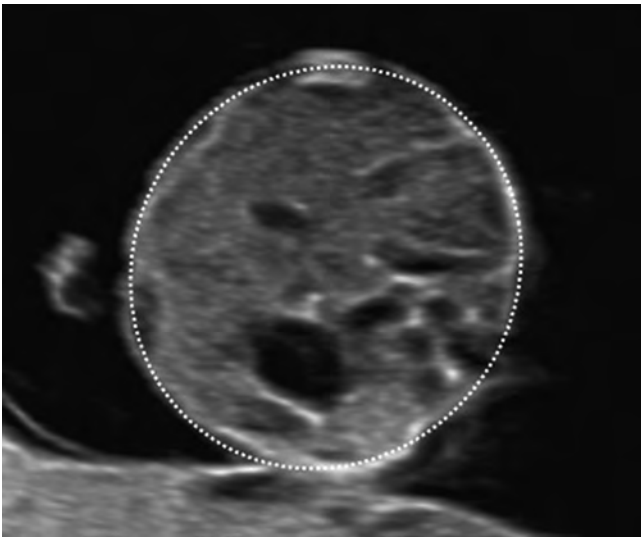
► **Fig. 1** Crown-rump length (CRL), 12⁺³ week of gestation. [rerif]

Biparietal diameter (BPD) and head circumference (HC) (► **Fig. 2**)



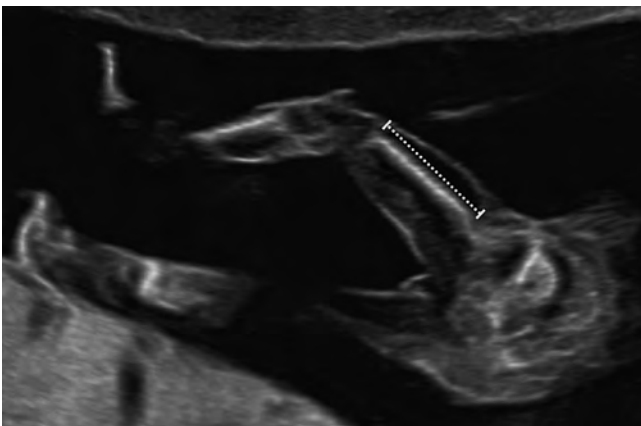
► **Fig. 2** Biparietal diameter (BPD) and head circumference (HC), 12⁺³ week of gestation. [rerif]

Abdominal circumference (AC) ▶ Fig. 3



▶ Fig. 3 Abdominal circumference (AC), 12⁺³ week of gestation. [ref]

Femur length (FL) ▶ Fig. 4

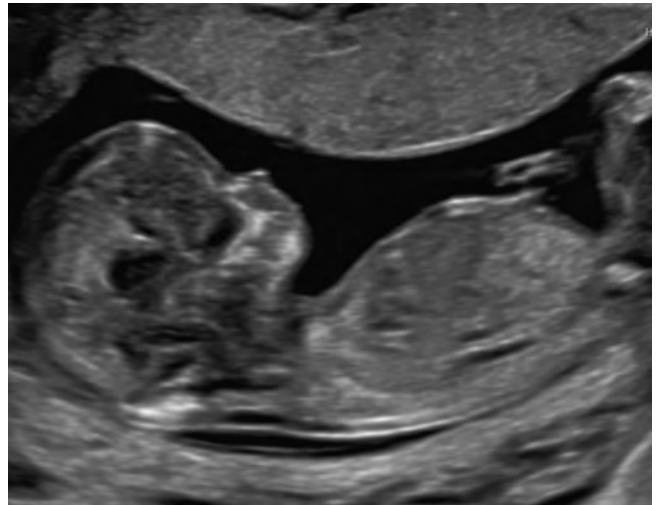


▶ Fig. 4 Femur length (FL), 12⁺³ week of gestation. [ref]

4.2 Fetal anatomy

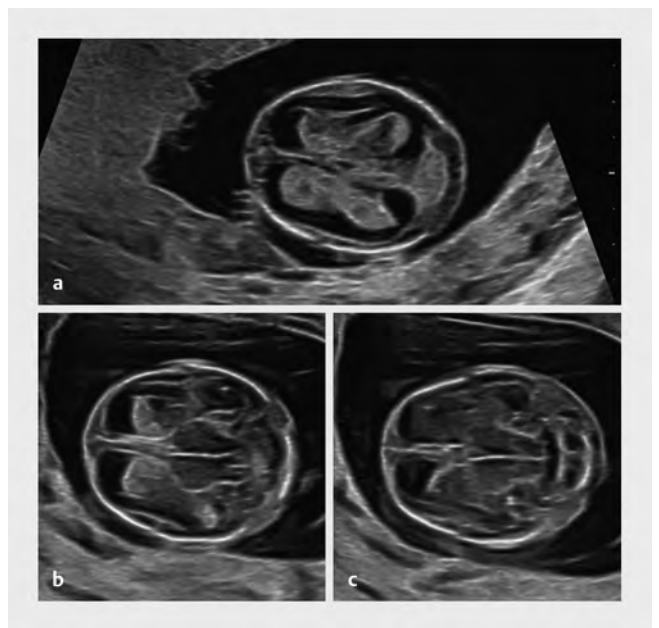
Review of the fetus and placenta

Amniotic fluid and amnion ▶ Fig. 5



▶ Fig. 5 Review of the fetus and placenta, 12⁺³ week of gestation. [ref]

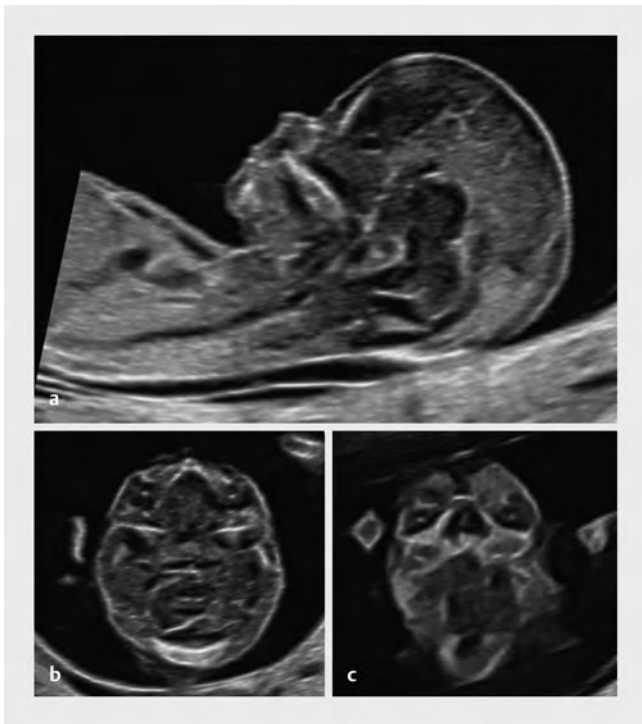
Head and brain ▶ Fig. 6



▶ Fig. 6 Head and brain, axial plane, 12⁺³ week of gestation. [ref]

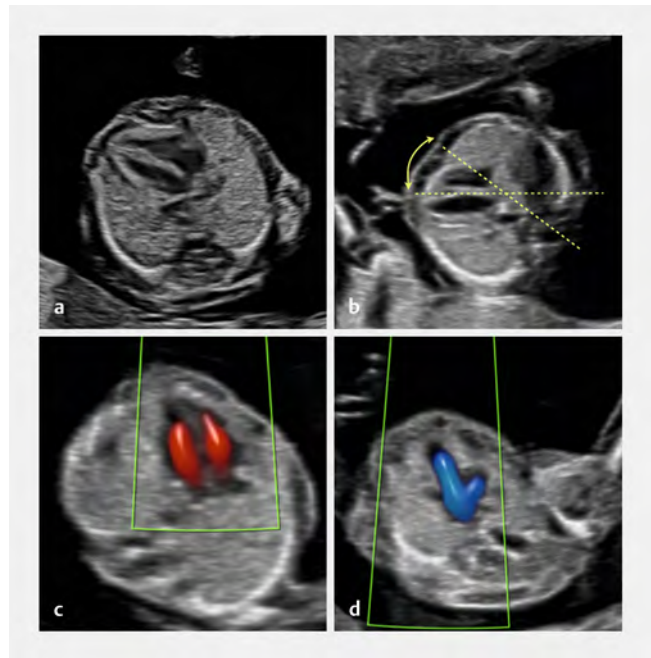
Face

Neck ▶ Fig. 7)



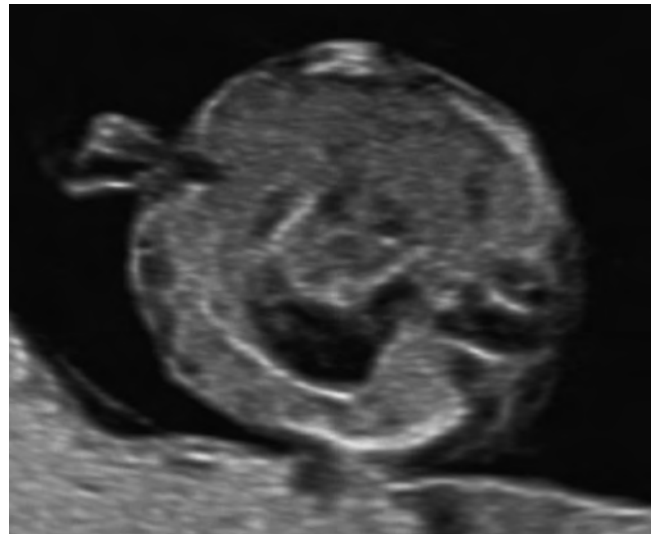
▶ Fig. 7 Face, sagittal, axial and frontal planes, 12⁺³ week of gestation. [rerif]

Thorax and heart ▶ Fig. 8)



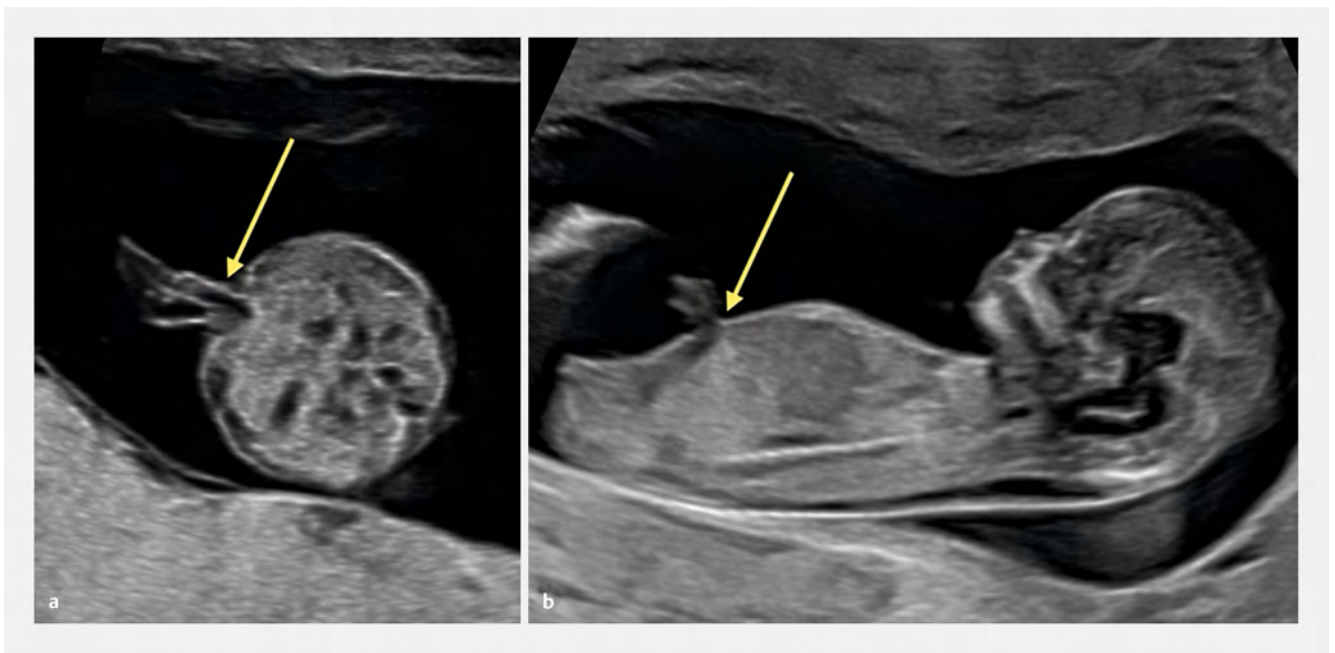
▶ Fig. 8 Heart and thorax, axial plane, 12⁺³ week of gestation. [rerif]

Gastrointestinal tract ▶ Fig. 9)



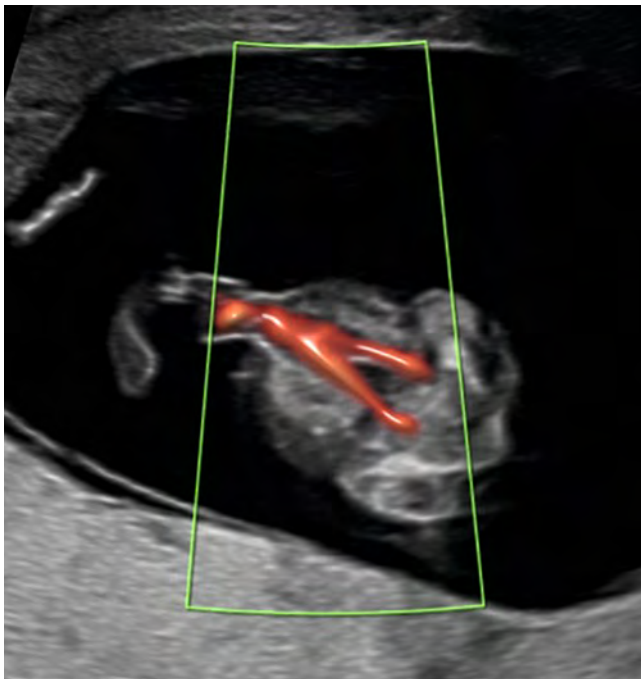▶ Fig. 9 Gastrointestinal tract, 12⁺³ week of gestation. [rerif]

Abdominal wall (► Fig. 10)



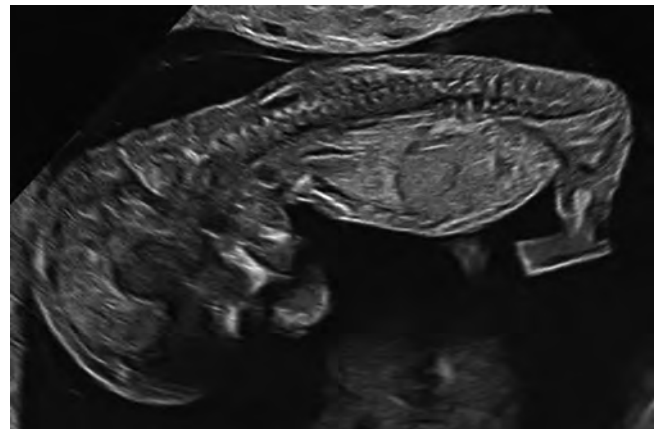
► Fig. 10 Abdominal wall, 12⁺³ week of gestation. [rerif]

Umbilical cord (► Fig. 11)



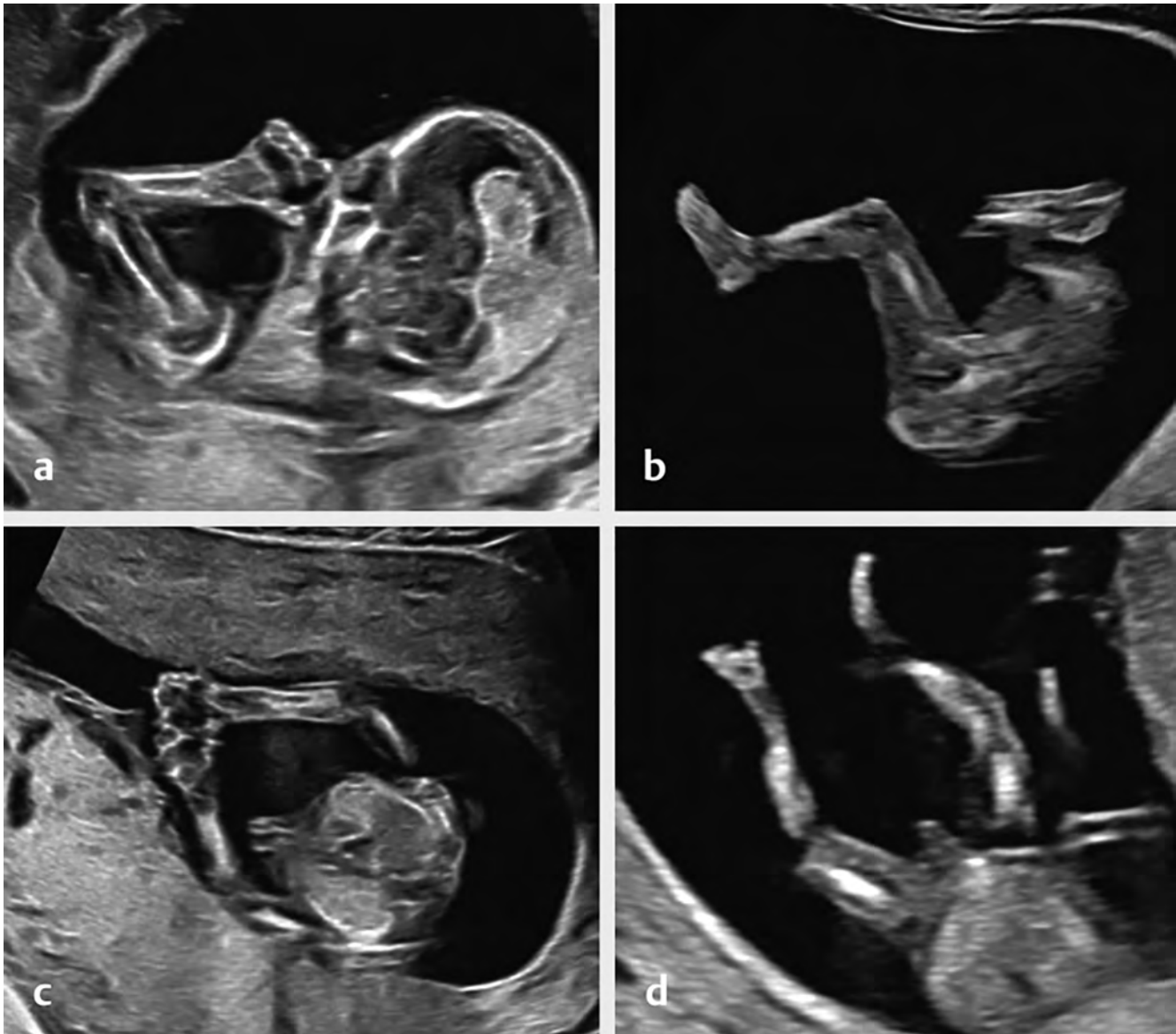
► Fig. 11 Umbilical cord, 12⁺³ week of gestation. [rerif]

Spine (► Fig. 12)



► Fig. 12 Spine, 12⁺³ week of gestation. [rerif]

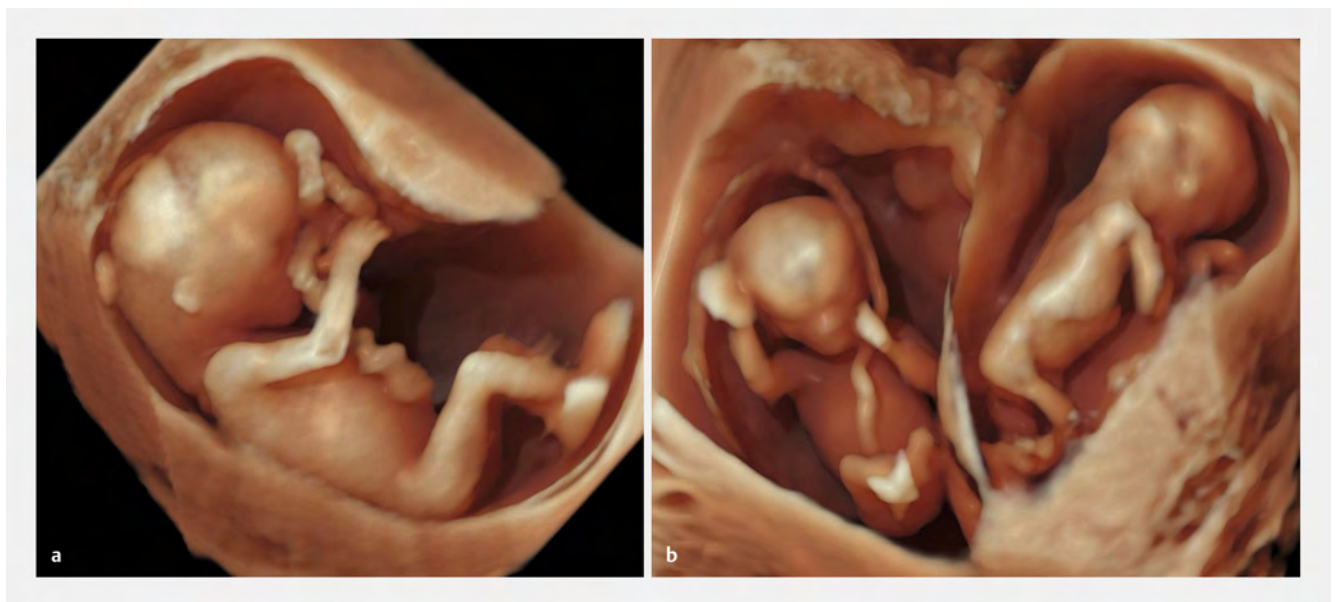
Extremities (► Fig. 13)



► Fig. 13 Extremities, 12⁺³ week of gestation. [rerif]

Genitals

Role of three-dimensional (3D) and 4D ultrasound (► Fig. 14)



► Fig. 14 3D ultrasound, 12⁺³ week of gestation, singleton pregnancy (a) and DC twins (b). [rerif]

	The following visualizations <i>must</i> be done at 11–13 ⁺⁶ GW as part of early structured screening for malformations (obligatory):	The following visualizations <i>should</i> be additionally carried out at 11–13 ⁺⁶ GW as part of early structured screening for malformations (optional):
Skull and brain	cranial vault, cerebral falx, choroid plexus	intracranial translucency (IT), brainstem
Face	profile	eyes, jaw, lips
Neck	nuchal translucency (NT) ¹	nasal bone (NB) ¹
Spine		outline
Heart and thorax	position, outline, four-chamber view, lungs	outflow tracts (color), three vessel trachea view, tricuspid valve flow (TR) ¹
Abdomen	stomach, abdominal wall	diaphragm, ductus venosus flow (DV) ¹ , umbilical cord arteries on either side of the bladder
Extremities	arms and legs	hands and feet (femur, tibia, fibula, humerus, radius, ulna)
Urogenital tract	bladder	kidneys
Placenta	chorionicity, amnionicity (multiple pregnancy), structure	position, insertion of umbilical cord, uterine arteries ¹

(Level of recommendation EC, strong consensus 10/10)

¹ After the patient has been informed and given her consent (GenDG)/ certification by the Fetal Medicine Foundation: NT, NB, TR, DV, uterine arteries, cervix.

NB: nasal bone, TR: tricuspid valve flow (insufficiency), DV: ductus venosus flow (reversed A-wave), IT: intracranial translucency

4.3 Detection rates of non-chromosomal malformations

Screening for fetal malformations in an unselected population differentiates between malformations which are **always detectable**, those that are **potentially detectable**, and those which are **not yet detectable** using the available diagnostic methods in the first trimester of pregnancy.

(Level of evidence 1a, strong consensus 7/7) (► Table 1, 2)

The detection rate for non-chromosomal structural anomalies also depends on the **prevalence** of severe malformations in the investigated cohort.

It is 32 % in low-risk and 60 % in high-risk cohorts.
(Level of evidence 1a, strong consensus 10/10)

► **Table 1** Detection rates for malformations that are always/potentially/not detectable @ 11–13⁺ weeks of gestation in 488 chromosomally normal fetuses [43].

Always detectable	DR (%)	Potentially detectable	DR (%)	Not detectable	DR (%)
anencephaly	100	missing hand/foot	77	agenesis of the corpus callosum	0
alobar holoprosencephaly	100	diaphragmatic hernia	50	hypoplasia of the cerebellar vermis	0
omphalocele	100	skeletal dysplasias	50	echogenic lung lesions	0
gastroschisis	100	polydactyly	60	intestinal obstruction	0
megacystis	100	severe heart defects	34	renal malformations	0
body stalk anomaly	100	facial cleft	5	clubfeet	0
generalized hydrops	100	open spina bifida	14		

► **Table 2** Detection rates in a recent study of anomalies that are always detectable (left column) or detectable in more than 50 % of cases (middle column) compared to anomalies which are rarely detectable (right column) in 1720 (1.7 %) fetuses with normal chromosomes [44].

Always detectable	DR (%)	Often detectable	DR (%)	Rarely detectable	DR (%)
anencephaly	100	open spina bifida	>50	cerebral ventriculomegaly	<10
alobar holoprosencephaly	100	HLHS	>50	agenesis of the corpus callosum	<10
encephalocele	100	AV channel	>50	cleft lip (isolated)	<10
tricuspid/pulmonary atresia	100	complex cardiac defects	>50	lung malformations	<10
pentalogy of Cantrell	100	left isomerism	>50	VSDs	<10
ectopia cordis	100	urogenital obstruction	>50	abdominal cysts	<10
omphalocele	100	limb deficiencies	>50	renal agenesis (unilateral)	<10
gastroschisis	100	FADS	>50	multicystic dysplastic kidney	<10
body stalk anomaly	100	lethal skeletal dysplasias	>50	hydronephrosis	<10
				duplex kidney	<10
				hypospadias	<10
				clubfeet	<10

4.4 Detection rates: structured vs. non-structured vs. no screening protocol

If a structured diagnostic screening is carried out at an early stage in pregnancy, it *should* follow a previously **defined protocol**.

(Level of recommendation B, level of evidence 1a, strong consensus 10/10) (► **Table 3–5**)

The **protocol** for early structured screening for malformations *should* include at the very least:

biometry, head, brain, face, nuchal translucency, spine, extremities, thorax, heart, abdomen, placenta with umbilical cord and amniotic fluid

► **Table 3** Detection rates of malformations/severe malformations depending on whether the population is low risk unselected or high risk [42].

Subgroup	Population	Anomalies (n/100 fetuses)	Sensitivity (%)	Diagnosis in 11–13 ⁺ GW (%)
1	Severe malformations/ <i>low risk</i> unselected	1.01 (0.95–1.07)	46.10 (36.88–55.46)	53.47 (43.42–63.37)
2	All malformations/ <i>low risk</i> unselected	1.81 (1.72–1.90)	32.35 (22.45–43.12)	41.10 (32.13–50.38)
3	All malformations/ <i>high risk</i>	6.55 (5.66–7.52)	61.18 (37.71–82.19)	66.29 (43.47–85.69)

(Numbers in brackets show 95 % CI.)

► **Table 4** Minimum requirements for the first-trimester ultrasound scan @ 11⁺⁰–13⁺⁶ weeks of gestation according to ISUOG [2] (► **Fig. 1–13** and Fig. 1 in Part 2 of the guideline).

Region	Minimum requirements for first-trimester ultrasound scans
General aspect	Singleton/multiple pregnancy
Head and brain	<ul style="list-style-type: none"> axial plane of the head calcifications of the skull shape of the skull (no bony defects) cerebral falx separates two hemispheres choroid plexuses almost fill the lateral ventricles (butterfly sign)
Neck	Mid-sagittal plane of the head and neck (profile) <ul style="list-style-type: none"> nuchal translucency <95th percentile
Heart	Axial plane of the heart, four-chamber view <ul style="list-style-type: none"> heart located in thoracic cavity, beats rhythmically
Abdomen	Axial plane <ul style="list-style-type: none"> stomach can be visualized abdominal wall is closed axial or sagittal planes bladder not dilated
Extremities	Four extremities with visualization of three segments per section
Placenta	Appearance normal with no cystic structures
Biometry	Sagittal view: crown-rump length and nuchal translucency Axial view: BPD

(Level of recommendation A, level of evidence 1a, strong consensus 10/10)

The following malformations can be almost always detected @ 11–13⁺⁶ weeks of gestation and *should* therefore be diagnosed:

- acrania/exencephaly/encephalocele (large)
- alobar holoprosencephaly
- omphalocele/exomphalos
- gastroschisis
- body stalk anomaly/ectopia cordis
- megacystis

(Level of recommendation A, level of evidence 2b, strong consensus 10/10)

4.5 Indirect vs. direct screening for malformations

Open spina bifida can be detected @ 11–13⁺⁶ weeks of gestation in up to 79% of cases using indirect parameters such as intracranial translucency.

A targeted examination, e. g., if there is a prior history of spina bifida, *should* include the following sonographic parameters:

- direct imaging of the spine (frontal, sagittal view)
- sagittal view: intracranial translucency, brain stem, cisterna magna
- axial view: cerebral peduncles, aqueduct of Sylvius

(Level of recommendation B, level of evidence 1a, strong consensus 10/10) (► **Fig. 15**)

► **Table 5** Anatomical structures which can be potentially investigated with structured fetal ultrasound scans @ 11⁺⁰–13⁺⁶ weeks of gestation according to ISUOG [2] (► **Fig. 1–13** and Fig. 1 in Part 2 of the guideline).

Region	Structures which can be visualized in sagittal, axial or coronal planes as required during the detailed anatomical examination
Head & brain	<ul style="list-style-type: none"> skull is intact shape of the head is normal cerebral falx is present choroid plexuses almost fill the lateral ventricles (butterfly sign) thalamus brainstem cerebral peduncles and aqueduct of Sylvius intracranial translucency (fourth ventricle) cisterna magna
Face & neck	<ul style="list-style-type: none"> forehead orbits nasal bone maxilla retronasal triangle upper lip lower jaw nuchal translucency
Thorax	<ul style="list-style-type: none"> shape of the thoracic wall lung fields diaphragm, continuity
Heart	<ul style="list-style-type: none"> cardiac activity present, regular rhythm position: intrathoracic, left deviation of cardiac axis (30–60°) size: 1/3 of the surface of the chest four-chamber view, two ventricles, B-mode images and color Doppler LVOT on B-mode imaging or color Doppler three vessel trachea view, B-mode imaging or color Doppler no TR antegrade flow in the ductus venosus, positive A-wave on pulsed Doppler
Abdomen	<ul style="list-style-type: none"> stomach in normal position in the upper left abdomen bladder: normal filling, located in the pelvis (longitudinal diameter <7 mm) abdominal wall: intact with insertion of umbilical cord two umbilical arteries flanking the bladder kidney: present on both sides
Spine	<ul style="list-style-type: none"> normal shape and continuity
Extremities	<ul style="list-style-type: none"> upper extremities with three segments, freely moveable lower extremities with three segments, freely moveable
Placenta	<ul style="list-style-type: none"> size and texture normal, no cystic appearance location in relation to the cervix and to any previous C-section scarring umbilical cord insertion in the placenta
Amniotic fluid & amnion	<ul style="list-style-type: none"> normal volume of amniotic fluid amnion and chorion, physiological separation

Cleft lip and palate (CLP) is detectable @ 11–13⁺⁶ weeks of gestation in 65 % or 96 % of cases through observation of a maxillary gap (isolated CLP vs. additional malformations).

The targeted examination, e. g., if there is a prior history cleft lip and palate, *should* include the following sonographic parameters:

- mid-sagittal plane showing the maxilla and maxillary gap
- frontal and oblique plane with visualization of the retronasal triangle
- axial view of the maxilla

(Level of recommendation B, level of evidence 2b, strong consensus 10/10) (► Fig. 16)

Sonographic markers such as nuchal translucency and flow through the tricuspid valve and the ductus venosus *should* be used to carry out **indirect screening** for fetal **cardiac defects** and *should* be combined with a four-chamber view.

(Level of recommendation B, level of evidence 4, strong consensus 10/10)

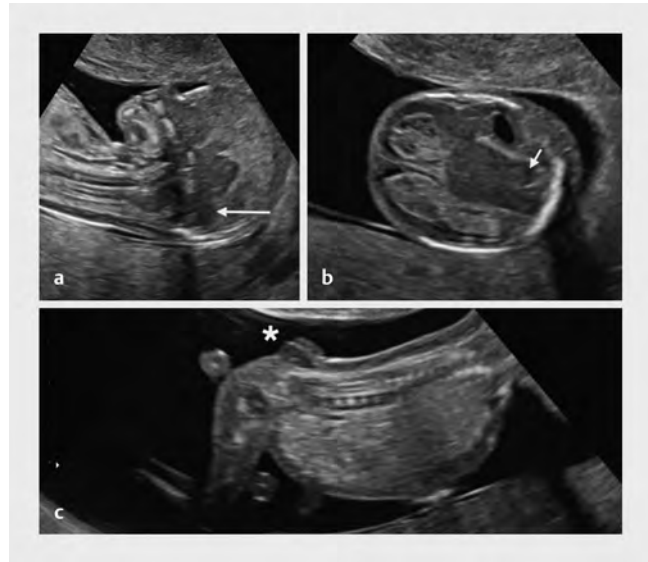
4.6 Indirect vs. direct screening for cardiac defects

Findings of increased NT, reverse flow through the tricuspid valve and/or in the ductus venosus or an abnormal four-chamber view *should* lead to **targeted fetal echocardiography** carried out by a specialist.

(Level of recommendation A, level of evidence 1+, strong consensus 10/10)

Fetal echocardiography in 11–13⁺⁶ GW *should* consist of an examination of the heart using standard scanning planes and color Doppler.

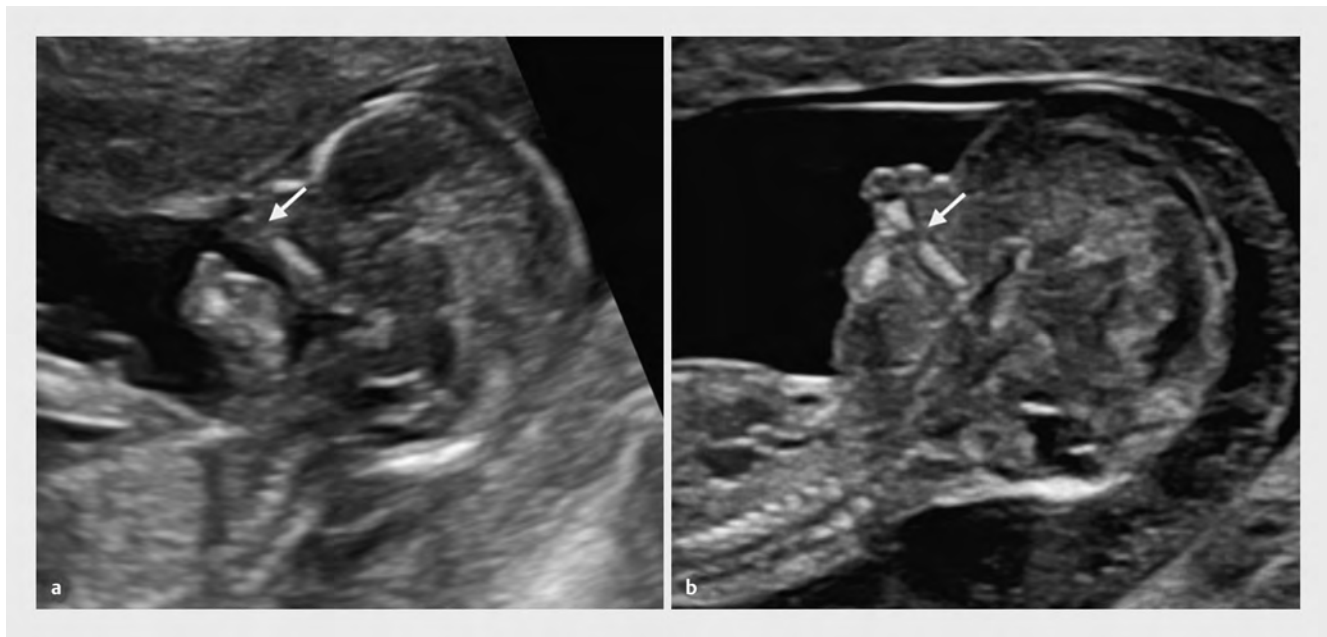
(Level of recommendation B, level of evidence 1+, strong consensus 10/10)



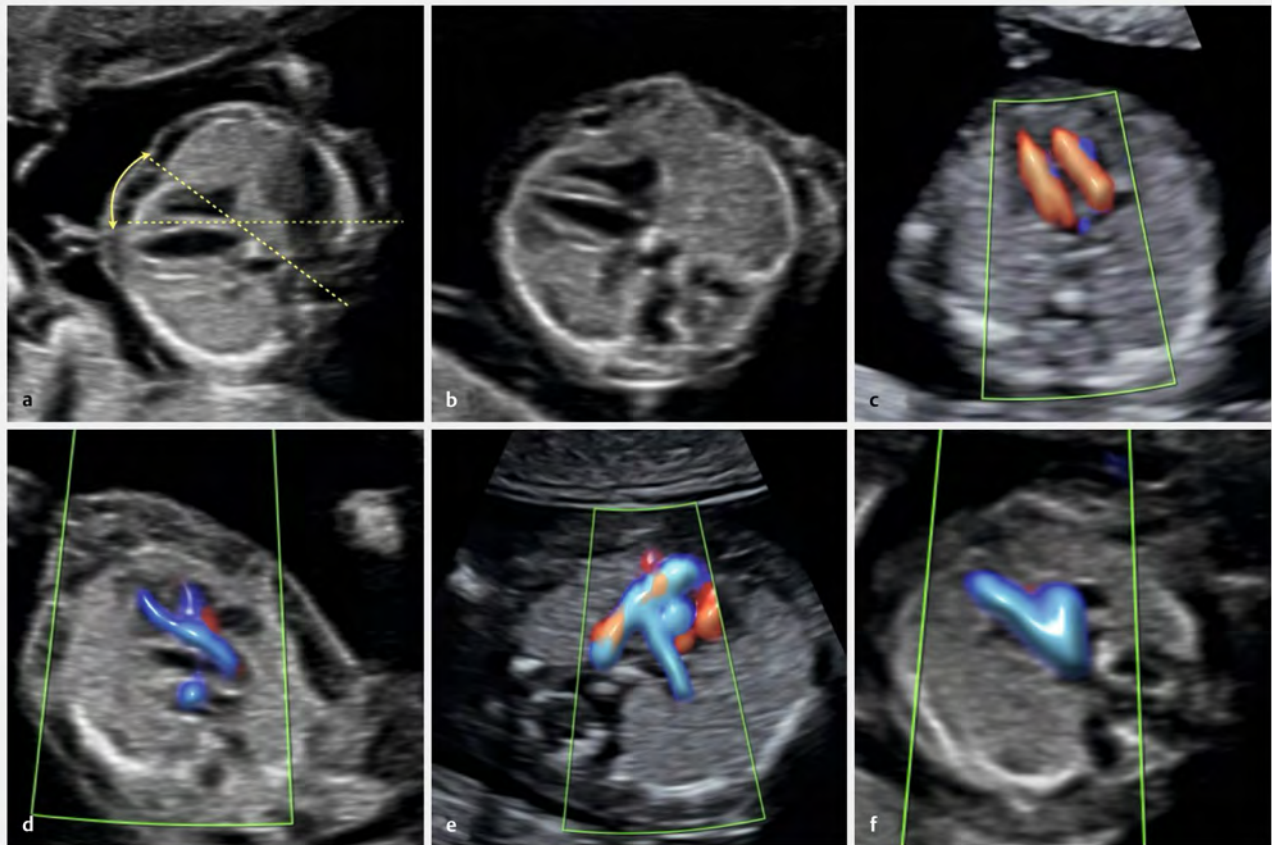
► Fig. 15 Lack of intracranial translucency in spina bifida at 12⁺³ GW (a), sagittal view of the spine with abnormal posterior fossa (long arrow) (a) and axial view showing the crash sign (short arrow) (b) and a direct view of caudal spina bifida (star) (c). (Compare with normal findings shown in ► Fig. 1, 6, 7, 12 and Fig. 1 in Part 2 of the guideline). [rerif]

Fetal echocardiography in 11–13⁺⁶ GW *should* include the following scanning planes using B-mode imaging and color Doppler:

- cardiac position
- cardiac axis
- four-chamber view
- right ventricular outflow tract
- left ventricular outflow tract



► Fig. 16 Cleft lip and palate at 12⁺³ GW with a gap in the upper jaw (arrow) known as the maxillary gap (a, b). Compare with normal findings shown in ► Fig. 1, 7 and Fig. 1 in Part 2 of the guideline. [rerif]



► **Fig. 17** Fetal echocardiography, standard planes, 12⁺³ GW: cardiac axis (a), four-chamber view (b), inflow through the atrioventricular valves (c), left ventricular (d) and right ventricular (e) outflow tract, three vessel trachea view (f) with aortic and ductal arches. [rerif]

- three vessel trachea view with aortic and ductal arches
 - search for ARSA (optional)
- (Level of recommendation A, level of evidence 1a, strong consensus 10/10) (► **Fig. 17**)

4.7 Diagnostic screening for malformations in the second trimester after early ultrasound scan for malformations in the first trimester of pregnancy

Diagnostic screening for malformations at 11–13⁺⁶ GW *must* be followed by organ screening in the second trimester of pregnancy @ 18–23 weeks of gestation.

(Level of recommendation A, level of evidence 1b, strong consensus 10/10)

4.8 Importance of ultrasound scans to detect malformations @ 11–13⁺⁶ weeks of gestation vs. in 18–23 weeks of gestation: benefit for the parents

4.9 Psychological aspects of first-trimester screening

Prior to carrying out first trimester screening, the pregnant woman *should* be informed about possible psychological and emotional consequences of **abnormal findings**.

(Level of recommendation B, level of evidence 1a, strong consensus 10/10)

Note

The guideline will be published simultaneously in the official journals of both professional societies (i. e., Geburtshilfe und Frauenheilkunde for the DGGG and Ultraschall in der Medizin/ European Journal of Ultrasound for the DEGUM).

Conflict of Interest

See also the long version of the guideline: <https://register.awmf.org/de/leitlinien/detail/085-002>

References

See also the long version of the guideline: <https://register.awmf.org/de/leitlinien/detail/085-002>