

Efficacy and safety of the water pressure method for endoscopic submucosal dissection in superficial pharyngeal cancer



Authors

Noriko Matsuura¹, Motohiko Kato², Kentaro Iwata^{1,3}, Kurato Miyazaki^{1,3}, Teppei Masunaga¹, Yoko Kubosawa^{1,3}, Mari Mizutani^{1,3}, Yukie Hayashi³, Motoki Sasaki¹, Tomohisa Sujino², Kaoru Takabayashi², Teppei Akimoto¹, Yusaku Takatori¹, Atsushi Nakayama¹, Mariko Sekimizu⁴, Hiroyuki Ozawa⁴, Naohisa Yahagi¹

Institutions

- 1 Division of Research and Development for Minimally Invasive Treatment, Cancer Center, Keio University School of Medicine, Shinjuku-ku, Japan
- 2 Center for Diagnostic and Therapeutic Endoscopy, Keio University School of Medicine, Shinjuku-ku, Japan
- 3 Division of Gastroenterology and Hepatology, Department of Internal Medicine, Keio University School of Medicine, Shinjuku-ku, Japan
- 4 Department of Otolaryngology, Head and Neck Surgery, Keio University School of Medicine, Shinjuku-ku, Japan

Keywords

Diagnosis and imaging (inc chromoendoscopy, NBI, iSCAN, FICE, CLE), Endoscopy Upper GI Tract, Endoscopic resection (ESD, EMRc, ...), Pharyngeal cancer

received 13.8.2023

accepted after revision 4.3.2024

accepted manuscript online 11.3.2024

Bibliography

Endosc Int Open 2024; 12: E621–E628

DOI 10.1055/a-2284-9184

ISSN 2364-3722

© 2024. The Author(s).

The Author(s). This is an open access article published by Thieme under the terms of the Creative Commons Attribution License, permitting unrestricted use, distribution, and reproduction so long as the original work is properly cited. (<https://creativecommons.org/licenses/by/4.0/>)

Georg Thieme Verlag KG, Rüdigerstraße 14,
70469 Stuttgart, Germany

Corresponding author

Noriko Matsuura, MD, Division of Research and Development for Minimally Invasive Treatment, Cancer Center, Keio University School of Medicine, 35 Shinanomachi, Shinjuku-ku, Tokyo, 160-8582, Japan
matsuura-no@keio.jp

ABSTRACT

Background and study aims Superficial pharyngeal cancers can be cured with transoral surgery (TOS), which preserves organ function and quality of life. Pharyngeal endoscopic submucosal dissection (ESD) is challenging to perform because of limited maneuverability and complex anatomical features. The water pressure method (WPM) is useful for natural traction techniques during ESD and is potentially useful for pharyngeal ESD. This study aimed to investigate the short-term outcomes of WPM-ESD for pharyngeal lesions.

Patients and methods Therapeutic outcomes of patients who underwent WPM-ESD for pharyngeal lesions at Keio University between May 2019 and February 2022 were retrospectively analyzed.

Results Twenty-one pharyngeal lesions treated with WPM-ESD were analyzed. Three lesions were located in the oropharynx and 18 in the hypopharynx. All ESD procedures were performed under general anesthesia. The endoscopic en bloc resection rate was 100%. The median procedure time was 15 minutes (range 4–45 minutes). All patients were successfully extubated on the day of ESD. No serious adverse events (AEs) related to WPM-ESDs were observed. None of the patients required nasogastric intubation, percutaneous endoscopic gastrostomy, or tracheotomy. The median fasting time and hospital stay were 2 days (range 2–5 days) and 6 days (range 6–10 days), respectively. All the histological results indicated squamous cell carcinoma. The complete histologic resection rate was 76.2%.

Conclusions WPM-ESD achieved a high en bloc resection rate and short procedure time without serious AEs. Thus, it may be a useful treatment for pharyngeal lesions.

Introduction

Pharyngeal cancer occurs in approximately 136,000 individuals annually, worldwide, and incidence is increasing in developed countries [1,2]. The disease is often detected at an advanced stage because endoscopic observation is challenging owing to patient reflexes and poor prognosis [3,4].

Recent developments in narrowband imaging (NBI) [5] and the establishment of a precise pharyngeal observation method [6] have enabled increased early-stage detection of superficial pharyngeal cancers. Early-stage pharyngeal cancers can be cured via transoral surgery (TOS), which preserves organ function and quality of life of the patient, and is an effective minimally invasive treatment [7,8,9,10,11,12,13]. TOS includes transoral video-assisted surgery, endoscopic laryngopharyngeal surgery, and endoscopic resection. The primary clinical advantage of TOS is that it protects patients who are candidates for organ- and function-sparing procedures from the potentially adverse events (AEs) of radical surgery or chemoradiation. En bloc resection rates using endoscopic submucosal dissection (ESD) for pharyngeal cancer are high (77.4%–100%) in TOS [7,8,11,12,13]. The fasting period for ESD is typically 2 days. Endoscopic resection is considered less invasive among TOS.

Although ESD is associated with a higher complete resection rate (en bloc with negative histological resection margins) than endoscopic mucosal resection (EMR) and is a potentially therapeutic option, pharyngeal ESD is technically difficult because maneuverability in the pharynx is limited. In addition, approaching the lesion is difficult and visibility of the subepithelial layer during dissection is poor owing to the complex anatomical features of the pharynx.

Since Binmoeller et al. demonstrated the safety and efficacy of underwater EMR, the fluid immersion technique has been applied to ESD throughout the gastrointestinal tract [14,15]. Recently, ESD using the water pressure method (WPM-ESD) has been effective for gastrointestinal ESD as a natural traction method that reduces AEs and shortens procedure time [16,17,18,19,20]. The buoyant force of water immersion and the pumping pressure of the water jet aid in penetrating the submucosal layer without the need for mechanical traction. It is believed that these advantages of the WPM are applicable to pharyngeal lesions. However, the effectiveness of WPM-ESD for pharyngeal lesions has only been documented in a single case report [21]. Therefore, this study aimed to investigate the therapeutic outcomes and safety of WPM-ESD for treatment of pharyngeal lesions.

Patients and methods

Study participants

This retrospective observational study was conducted at the endoscopy unit of a Japanese referral university hospital using a database. Patients who underwent pharyngeal WPM-ESD between May 2018 and February 2021 were retrospectively analyzed. During this period, pharyngeal ESD was performed on 27 lesions. Of these lesions, WPM-ESD was performed on 21 lesions; the use of WPM was determined by videos at the time of

treatment. In pharyngeal ESD, the indication for WPM-ESD was not defined by tumor site or diameter. WPM-ESD in pharyngeal ESD was not reported at the time of its introduction, and it was performed at the decision of the endoscopist, if deemed feasible. This study was conducted in accordance with the tenets of the 2008 Declaration of Helsinki. The study protocol was approved by the Institutional Review Board of the host hospital (20180163 and 20190139).

Indication for ESD

Pharyngeal ESD is recommended for lesions that are suspected to be pharyngeal cancer based on endoscopic observations and histological findings. Diagnostic endoscopy using was used to identify indications for ESD (GIF-H260Z, 290Z, or 1200EZ; Olympus Medical Systems Co., Tokyo, Japan, or EG-L600ZW7; FUJIFILM, Tokyo, Japan). If the lesion exhibited a well-demarcated brownish area and irregular microvascular patterns on NBI, it was diagnosed as endoscopically suspected “superficial cancer.” The details of these findings have been previously reported [22,23]. The horizontal extent of the lesions was assessed using the Valsalva method as required [24]. The feasibility of pharyngeal ESD was determined through discussion between the otolaryngologists and gastroenterologists.

ESD procedures

The ESD procedure was initiated with the patient under general anesthesia, and a laryngoscope was inserted into the supraglottis by an otolaryngologist. A laryngoscope was used to expand the working space as described previously [13]. ESD procedures were performed using an endoscope with a waterjet function (GIF-H290T or GIF-Q260J; Olympus Medical Systems, Co., Ltd.). A 1.5-mm Dual Knife J (KD-655Q; Olympus Medical Systems) was used. A small-caliber-tip transparent hood (ST Hood or ST Hood short-type; DH-28CR, DH-28GR, or DH-33GR; FUJIFILM) was used to facilitate entry of the endoscopic devices into the submucosal layer. Magnifying endoscopy or a 0.75% iodine solution was used to delineate the tumor margin and marking dots were circumferentially placed outside the margin using the Dual Knife J. Sodium thiosulfate solution (STS) was used to neutralize the iodine before ESD. For the submucosal injection, a 10% glycerine (Glycerol; Chugai Pharmaceutical Co., Ltd., Tokyo, Japan) or hyaluronic acid solution (MucoUp; Boston Scientific Japan, Tokyo, Japan) with a small amount of indigo carmine was used. A standard high-frequency generator (VIO3; ERBE Elektromedizin, Tübingen, Germany) and carbon dioxide insufflator (UCR; Olympus Medical Systems) were used. Four modes of electrosurgical current were applied: “dry cut” (effect 2.2) or “endo cut” (effect 1.2) for mucosal incision and “swift coagulation” (effect 3.5) for submucosal dissection, “spray coagulation” (effect 1.2) for haemostasis using the tip of the knife, and “soft coagulation” (effect 3.0) for haemostasis using hemostatic forceps (Coagrasper, Olympus Medical Systems) (► **Table 1**). All procedures were performed by three experienced endoscopists who had performed >250 ESDs. Dexamethasone was intravenously injected immediately after removing the intubation tube to prevent laryngeal edema, as appropriate in consultation with the otolaryngologist. Dexamethasone was not used

► **Table 1** Settings for the water pressure method after endoscopic submucosal dissection (WPM-ESD).

Mucosal incision	Dry cut (effect 2.2) End cut I (effect 1.0, duration 2.0, interval 2.0)
Submucosal dissection	Swift coagulation (effect 3.5)
Hemostasis using a knife tip	Spray coagulation (effect 1.2)
Pre-coagulation	Forced coagulation (effect 0.3)
Hemostasis using haemostatic forceps	Soft coagulation (effect 3.0)

routinely. No difference in the use of dexamethasone or other perioperative management was observed between WPM-ESD and conventional ESD.

The day after ESD, blood tests and chest radiography were performed to monitor any potential complications related to the procedure. Thereafter, the patient was allowed to start drinking water. Diet began 2 days after ESD. If the patient had sore throat or pain during swallowing, nonsteroidal anti-inflammatory drugs (NSAIDs) were administered as appropriate. The patient was discharged 4 days after ESD without any major AEs. Follow-up was conducted at our hospital within 1 month post-ESD for assessment of postoperative complications and histological assessments.

WPM

We have used WPM for duodenal ESD since June 2017. Subsequently, our pharyngeal ESD procedure shifted from conventional ESD to WPM-ESD since its introduction in May 2019. In WPM-ESD, the pharyngeal lumen is filled with saline solution. First, a circumferential incision was made. Thereafter, the space below the mucosal flap was opened using a water stream from the waterjet function of the endoscope (► **Fig. 1**). The pumping pressure of the water jet improves the lateral edge visualization of the dissection layer in the dissection plane. We infused the saline solution using an endoscopic flushing pump (OFFP; Olympus Europe, Hamburg, Germany; ► **Video 1**). In pharyngeal ESD, arterial bleeding is rare and its incidence differs from the other organ ESD. In addition, pre-coagulation with forced coagulation mode is effective in inhibiting bleeding. If venous oozing occurs, identifying the bleeding point is easier in underwater situations, because the bleeding point in saline solution can be easily recognized.

Histological assessment after ESD and ESD-related adverse events

The resected specimens were extended on a board with pins and fixed in 10% formalin for 24 hours. The preserved specimens were cut into consecutive 2-mm sections and examined by pathologists. The lesions were histologically classified as carcinoma in situ or subepithelial invasion. In cases of subepithelial invasion, tumor thickness was measured (the distance between the surface layer and the deepest point). Tumor size, invasion depth, lymphatic and vascular involvement, and tumor involve-

ment in the lateral and vertical margins were assessed according to the Japanese guidelines for head and neck cancer [25]. R0 resection was defined as en bloc resection with negative horizontal and vertical margins. Furthermore, the horizontal margin (HM) was also investigated: HM0 was defined as no tumor exposed on any horizontal margin, HM1 as a tumor present on any vertical margin, and HMX as the inability to assess the existence of a residual tumor on the horizontal margin. The frequency of AEs, such as postoperative bleeding, perforation, laryngeal edema requiring prophylactic or emergency temporary tracheotomy, subcutaneous emphysema, aspiration pneumonia, fistula formation, abscess formation, and stricture formation, were evaluated.

Measured outcomes

This study aimed to investigate short-term outcomes of pharyngeal WPM-ESD. They included en bloc resection, en bloc with R0 resection, procedure time, and complications. The primary outcome of this study was the endoscopic en bloc resection rate. The secondary outcomes of this study were: 1) ESD procedure time, which is defined as duration starting from initial dissection to completion of resection; 2) pathological results, including R0 resection; 3) fasting period; 4) hospital duration; and 5) AEs. All continuous and categorical variables are presented as median (range) and frequencies (percentages), respectively.

Results

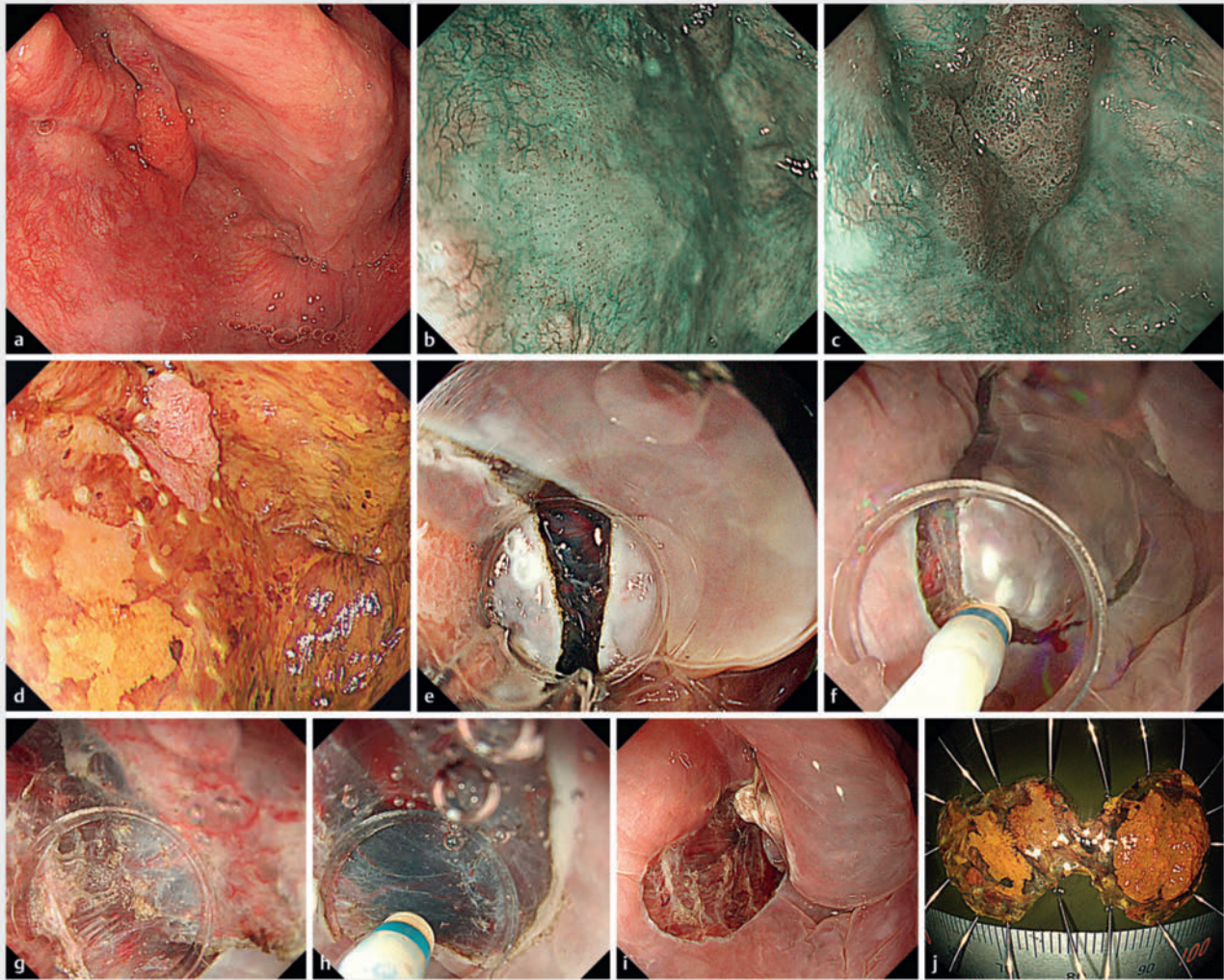
Baseline characteristics

During the study period, 21 patients underwent pharyngeal ESD using the WPM. Baseline characteristics of the patients and their lesions are listed in ► **Table 2**. The median age of patients was 67 years (range, 58–84). The patients comprised eight men (80%) and two women (20%). Fourteen percent of the lesions were located in the oropharynx and 86% in the hypopharynx. The most common macroscopic type was flat lesions (81%). The median endoscopic tumor diameter was 10 mm (range, 5–30 mm).

Therapeutic outcomes

► **Table 3** lists treatment-related outcomes. The endoscopic en bloc resection rate was 100%. The median procedure time was 15 minutes (range, 4–45 minutes). The median fasting period was 2 days (range, 2–5 days). The median hospital duration was 6 days (range, 6–10 days).

No cases involved use of a traction device, including the clip and thread technique. All patients were successfully extubated on the day of ESD and none required tracheotomy. One case of subcutaneous emphysema was observed in the hypopharyngeal lesion. No patients required nasogastric tube feeding or percutaneous endoscopic gastrostomy. No cases of laryngeal edema requiring temporary tracheotomy were observed. No cases of postoperative bleeding or aspiration pneumonia were observed. None of the remaining patients had any AEs other than sore throat or pain during swallowing, which were managed with NSAIDs for several days. All patients had preserved



► **Fig. 1** Endoscopic images of the water pressure method (WPM) method. **a** Pharyngeal observation in general anesthesia. **b** Type 0-IIa flat lesion located on the posterior wall of the hypopharynx. **c** Type 0-I lesion located on the left pyriform sinus. **d** A marking dot is placed outside of the lesion. **e** Incision was made from the anal side. **f** A whole circumferential incision was placed. **g** Dissection of the subepithelial layer using the water pressure method for the posterior wall of the hypopharynx. **h** Dissection of subepithelial layer with water pressure method for left pyriform sinus. **i** Two lesions were removed en bloc. **j** The pathological diagnosis was squamous cell carcinoma pT1s for the posterior wall lesion of the hypopharynx, and pT1 tumor thickness was 1300µm for the left pyriform sinus lesion.

larynx, swallowing, speech, and airway functions. One case of prolonged fasting resulting from subcutaneous emphysema and another of nasal pain, potentially caused by irrigation of the nasal cavity with iodine-containing water, were noted. All patients were treated conservatively. No treatment-related death occurred during the study period.

Histological results

► **Table 4** lists the histological results. All lesions were squamous cell carcinoma (SCC). The T categories were Tis (six lesions, 29%), T1 (12 lesions, 57%), and T2 (three lesions, 14%). Fifteen lesions were subepithelial SCC. The median tumor thickness for subepithelial lesions was 200 µm (range, 100–1300 µm). The pathologically R0 resection rate was 76.2% (16 lesions). Of the five patients with lesions undergoing follow-up


with HMX or HM1, four underwent follow-up endoscopy. No recurrence was observed (median surveillance period, 461 days [range, 330–1147 days]).

Discussion

This study focused on technical aspects of WPM-ESD for superficial pharyngeal cancer and demonstrated its short-term outcomes. In this study, all lesions were successfully en bloc resected and the median procedure time was 15 minutes, which was shorter than that reported in previous studies of conventional pharyngeal ESD. The median hospital stay was 6 days without serious AEs, including laryngeal edema.

Although ESD is a good treatment option, it is technically challenging owing to the anatomical features of the pharynx.

VIDEO



► **Video 1** Procedures in this trial. A transparent hood was placed and the submucosal injection administered. Thereafter, a whole circumferential incision was made, followed by dissection of the subepithelial layer to penetrate below the lesion with the water pressure method. The procedure time was 25 minutes.

The technical difficulty of pharyngeal ESD is strongly affected by the accessibility of the target lesion, availability of adequate maneuverable space, and mutual interference between the endoscope, laryngoscope, and intubation tube. Performing ESD on lesions located in the pyriform sinus poses technical challenges, owing to the narrow and intricate space that makes accessing the lesion difficult. ESD of lesions located on the posterior walls of the oropharynx and hypopharynx is challenging because of the shallow subepithelial layers. The median procedure time for pharyngeal ESD is 50 to 124.9 minutes [11, 12, 13]. To overcome this technical difficulty, several mechanical traction techniques, including the use of laryngeal forceps, clip and thread technique, ring-shaped thread traction, and the grasping forceps method, have been reported [26, 27, 28]. However, occasionally, the direction of traction cannot be controlled, and the forceps interfere with the endoscope. Effective traction is not always achieved.

To overcome these difficulties, WPM-ESD is considered effective for pharyngeal ESD. WPM-ESD is performed in underwater conditions; hence, capitalizing on its features (floating and magnified effects) is advantageous. The “floating” effect, which works opposite to the direction of gravity, can elevate the lesion during underwater submucosal dissection. Endoscopists usually position the patient such that the lesion is in the direction of gravity. Under underwater conditions, the lesion is submerged, and endoscopists do not need to consider the issue of gravity. This is particularly useful for post-cricoid lesions. Lesions in the post-cricoid region, which are often anatomically limited vertically, can be easily dissected using the floating effect. In addition, the magnification effect precisely aids visualization of the dissecting point. The underwater image is magnified approximately 1.33 times owing to the refractive index of water, and the optical zoom effect enables a more precise procedure [29], even if hemorrhaging occurs. The bleeding site is well visualized underwater [30]. Consequently, endoscopists can dissect the subepithelial layer more precisely.

► **Table 2** Baseline characteristics of patients and lesions.

Total number of patients/lesions	10/21
Male, n (%)	8 (80)
Age, y, median (range)	67 (58–84)
History of esophageal cancer, n (%)	
▪ Endoscopic treatment	6 (60)
▪ Surgery	1 (10)
History of head and neck cancer, n (%)	
Endoscopic treatment	1 (10)
CRT	2 (20)
Location, n (%)	
▪ Oropharynx	
▪ posterior wall	3 (14)
▪ Hypopharynx	
▪ Pyriform sinus	9 (43)
▪ Posterior wall	7 (33)
▪ Post-cricoid	1 (5)
▪ Side wall	1 (5)
Macroscopic type, n (%)	
▪ Protruded	4 (19)
▪ Flat	17 (81)
Tumor size (mm), median, (range)	10 (5–30)
CRT, chemoradiotherapy.	

In addition, the pumping pressure of the water jet facilitates ESD. The advantages of the WPM-ESD are as follows: 1) simple and easy, without special equipment or devices; 2) ability to create the mucosal flap within a confined space (natural traction); 3) ease of locating the edge of the lesion; and 4) ability to effectively address fibrotic lesions near scars or those located on the posterior wall. The strengths of this study are as follows. First, the WPM-ESD technique is versatile and can be applied at any point during the procedure. To use it, you simply need to activate the foot pedals connected to the endoscope pump and initiate the water irrigation. Although several mechanical traction techniques have been reported, most of them require special devices or equipment. Second, WPM-ESD enables the surgeon to move below the mucosal flap. In the early stages of dissection, the mucosal flap is relatively small; therefore, encountering the subepithelial space is difficult, in addition to the complex anatomical features of the pharynx. Using the ST hood instead of the conventional transparent hood allows better visualization for penetrating the subepithelial layer and better traction. Third, water irrigation makes it easier to locate the edge of the lesion. WPM-ESD allows safe dissection of the lateral edge from the outside to the inside of the lesion (pull-off method), which is typically impossible with a

► **Table 3** Treatment-related outcomes.*

Lesions according to operator experience Experts n (%)	21 (100)
Procedure time, median (range) minutes	15 (4–45)
En bloc resection, n (%)	21 (100)
Fasting period, median (range) (day)	2 (2–5)
Hospital stay, median (range) (day)	6 (6–10)
Delayed bleeding, n	0
Extubation on day of ESD, n (%)	10 (100)
Tracheotomy, temporary, n	0
Aspiration pneumonia, n	0
Subcutaneous emphysema, n (%)	1 (10)
Nasogastric tube feeding, n	0
*Experts: Endoscopists who had performed >250 ESDs. ESD, endoscopic submucosal dissection.	

tipped or Dual Knife. This pull-off method is beneficial for pharyngeal ESD because of the limited working space and difficulty in approaching the lesion owing to its complex anatomical features. Fourth, using a water stream allows easier visualization of the dissection line, especially for lesions with severe fibrosis near a previous ESD scar or in the oropharyngeal posterior wall, where the subepithelial layer is shallow. Subepithelial, muscularis, and fibrotic tissues can be distinguished based on the degree of tissue vibration when an active water stream is applied. Owing to the advantages of WPM, no cases of post-operative laryngeal edema or aspiration pneumonia were found, as the treatment could be efficiently completed in a short duration.

In WPM-ESDs, a saline solution is preferable for the following reasons: First, a saline solution exhibits increased buoyancy compared with water due to its higher specific gravity. Second, the risk of electrolyte imbalance is lower when using saline solutions than when using water alone. Third, the presence of electrolytes in saline solutions provides superior electrical conductivity under fluid immersion conditions and facilitates clean tissue cutting [31].

One disadvantage of WPM-ESD is that bleeding can lead to cloudiness in the water, causing impaired visibility. Arterial bleeding is rare in pharyngeal ESD compared with that in gastric or duodenal ESD. If vessels are visible during ESD, detailed cauterization and resection with preforced coagulation can prevent intraoperative bleeding. If intraoperative bleeding causes cloudy water and poor vision, water in the pharyngeal space must be appropriately aspirated. Another disadvantage of WPM-ESD for pharyngeal lesions is the risk of aspiration pneumonia. In our retrospective trial, aspiration pneumonia was not observed in any patient. This may be because the cuff on the intubation tube prevented water from flowing into the trachea. There is also a risk of iodine reflux into the nasal cavity due to water irrigation in the pharyngeal space. In this study,

► **Table 4** Histological result.

Pathological findings, n (%)	21 (100)
Squamous cell carcinoma	
Invasion depth, n (%)	
▪ Intraepithelial/subepithelial	6 (28.6)/15 (71.4)
Tumor thickness for subepithelial lesions, median (range) (µm)	150 (100–800)
T category, n (%)	
▪ Tis/T1/T2	6 (28.6)/12 (57.1)/3 (14.3)
Lymphatic invasion	0
Venous invasion	0
Margin status, n (%)	
▪ Horizontal margin negative (HM1)	16 (76.2)
▪ Horizontal margin unclear (HMX)	2 (9.5)
▪ Horizontal margin positive (HM0)	3 (14.3)
▪ Vertical margin negative (VM0)	21 (100)
▪ Vertical margin positive (VM1)	0 (0)
R0 resection, n (%)	16 (76.2)
HM0, pathological horizontal margin negative; HMX, pathological horizontal margin unclear; HM1, pathological horizontal margin positive; VM0, pathological vertical margin negative; VM1, pathological vertical margin positive.	

one case of post-ESD nasal pain, possibly caused by iodine, was observed. To overcome this, STS was sprayed to neutralize the iodine before initiating ESD. This process may inhibit the iodine content of the irrigating water.

If the lesion is resected with a negative margin, no additional treatments are generally performed and the patient is in the surveillance period for oropharyngeal and hypopharyngeal lesions. In head and neck lesions, no correlation was established between the histological features and lymph node metastasis. The “resect and watch” strategy, which involves local resection and observation until local lesion recurrence, seems feasible for functional or organ preservation [32]. Before the ESD procedure, all treatment strategies were discussed with the otolaryngologists, and during the ESD procedure, they were executed with collaborative efforts, which are essential for a safe ESD. We first showed that WPM-ESD for pharyngeal lesions achieved a high en bloc resection rate and short procedure time without serious adverse events.

This study had some limitations. First, it was a retrospective trial performed at a single university hospital. We did not compare the short-term therapeutic outcomes with conventional pharyngeal ESD or the mechanical traction method. Therefore, it would be beneficial to perform a prospective study to investigate the efficacy of WPM-ESD. We are currently conducting a prospective trial (UMIN000047207) to investigate the short-term outcomes of pharyngeal ESD. Second, all procedures were performed by experienced endoscopists familiar with ESD of the gastrointestinal tract, such as the esophagus, stom-

ach, and colon. However, after pharyngeal ESD, several post-operative AEs, including laryngeal edema and subcutaneous emphysema, can be critical, and this procedure is better performed by endoscopists who specialized in the pharyngeal field. Third, the amount of water irrigated during the WPM-ESD was not measured. We intend to investigate these issues in a prospective trial.

Conclusions

WPM-ESD for pharyngeal lesions achieved a high en bloc resection rate and short procedure time without serious AEs. Thus, it may be a useful treatment method for the natural traction of pharyngeal lesions.

Acknowledgement

We would like to thank Editage for English language editing.

Conflict of Interest

The authors declare that they have no conflict of interest.

References

- [1] Siegel R, Naishadham D, Jemal A. Cancer statistics, 2013. *CA Cancer J Clin* 2013; 63: 11–30 doi:10.3322/caac.21166
- [2] Chaturvedi AK, Anderson WF, Lortet-Tieulent J et al. Worldwide trends in incidence rates for oral cavity and oropharyngeal cancers. *J Clin Oncol* 2013; 31: 4550–4559 doi:10.1200/JCO.2013.50.3870
- [3] Global Burden of Disease Cancer Collaboration. Fitzmaurice C, Allen C et al. Global, regional, and national cancer incidence, mortality, years of life lost, years lived with disability, and disability-adjusted life-years for 32 Cancer groups, 1990 to 2015: A systematic analysis for the global burden of disease study. *JAMA Oncol* 2017; 3: 524–548
- [4] National Cancer Center, Tokyo. Vital statistics. https://ganjoho.jp/reg_stat/statistics/index.html
- [5] Muto M, Minashi K, Yano T et al. Early detection of superficial squamous cell carcinoma in the head and neck region and esophagus by narrow band imaging: a multicenter randomised controlled trial. *J Clin Oncol* 2010; 28: 1566–1572
- [6] Yamasaki Y, Ishihara R, Hanaoka N et al. Pethidine hydrochloride is a better sedation method for pharyngeal observation by transoral endoscopy compared with no sedation and midazolam. *Dig Endosc* 2017; 29: 39–48
- [7] Muto M, Satake H, Yano T et al. Long-term outcome of transoral organ-preserving pharyngeal endoscopic resection for superficial pharyngeal cancer. *Gastrointest Endosc* 2011; 74: 477–484 doi:10.1016/j.gie.2011.04.027
- [8] Satake H, Yano T, Muto M et al. Clinical outcome after endoscopic resection for superficial pharyngeal squamous cell carcinoma invading the subepithelial layer. *Endoscopy* 2015; 47: 11–18 doi:10.1055/s-0034-1378107
- [9] Shiotani A, Tomifuji M, Araki K et al. Videolaryngoscopic transoral en bloc resection of supraglottic and hypopharyngeal cancers using laparoscopic surgical instruments. *Ann Otol Rhinol Laryngol* 2010; 119: 225–232 doi:10.1177/000348941011900403
- [10] Watanabe A, Taniguchi M, Kimura Y et al. Synopsis of transoral endoscopic laryngopharyngeal surgery for superficial pharyngeal cancers. *Head Neck* 2017; 39: 1779–1787 doi:10.1002/hed.24839
- [11] Okada K, Tsuchida T, Ishiyama A et al. Endoscopic mucosal resection and endoscopic submucosal dissection for en bloc resection of superficial pharyngeal carcinoma. *Endoscopy* 2012; 44: 556–564
- [12] Katada C, Muto M, Fujii S et al. Transoral surgery for superficial head and neck cancer: national Multi-Center Survey in Japan. *Cancer Med* 2021; 10: 3848–3861 doi:10.1002/cam4.3927
- [13] Iizuka T, Kikuchi D, Suzuki Y et al. Clinical relevance of endoscopic treatment for superficial pharyngeal cancer: feasibility of techniques corresponding to each location and long-term outcomes. *Gastrointest Endosc* 2021; 93: 818–827
- [14] Binmoeller KF, Weilert F, Shah J et al. "Underwater" EMR without submucosal injection for large sessile colorectal polyps (with video). *Gastrointest Endosc* 2012; 75: 1086–1091
- [15] Binmoeller KF, Shah JN, Bhat YM et al. "Underwater" EMR of sporadic laterally spreading nonampullary duodenal adenomas (with video). *Gastrointest Endosc* 2013; 78: 496–502
- [16] Yahagi N, Nishizawa T, Sasaki M et al. Water pressure method for duodenal endoscopic submucosal dissection. *Endoscopy* 2017; 49: E227–E228 doi:10.1055/s-0043-113556
- [17] Yoshii S, Hayashi Y, Matsui T et al. "Underwater" endoscopic submucosal dissection: a novel technique for complete resection of a rectal neuroendocrine tumor. *Endoscopy* 2016; 48: (Suppl. 01): E67–E68 doi:10.1055/s-0042-101855
- [18] Ozeki Y, Hirasawa K, Ikeda R et al. Safety and efficacy of water pressure endoscopic submucosal dissection for colorectal tumors with submucosal fibrosis (with video). *Gastrointest Endosc* 2021; 94: 607–617.e2
- [19] Kato M, Takatori Y, Sasaki M et al. Water pressure method for duodenal endoscopic submucosal dissection (with video). *Gastrointest Endosc* 2021; 93: 942–949
- [20] Masunaga T, Kato M, Sasaki M et al. Colorectal endoscopic submucosal dissection using the water pressure method for diverticulum-associated lesions: A case series study (with video). *Endosc Int Open* 2023; 11: E305–E314
- [21] Miyazaki K, Kato M, Takatori Y et al. A successful case of endoscopic submucosal dissection using the water pressure method for hypopharyngeal carcinoma with severe fibrosis. *Endoscopy* 2023; 55: E721–E722
- [22] Muto M, Katada C, Sano Y et al. Narrow band imaging: a new diagnostic approach to visualize angiogenesis in superficial neoplasia. *Clin Gastroenterol Hepatol* 2005; 3: (Suppl. 01): S16–20 doi:10.1016/s1542-3565(05)00262-4
- [23] Muto M, Nakane M, Katada C et al. Squamous cell carcinoma in situ at oropharyngeal and hypopharyngeal mucosal sites. *Cancer* 2004; 101: 1375–1381 doi:10.1002/cncr.20482
- [24] Hamada K, Ishihara R, Yamasaki Y et al. Transoral endoscopic examination of head and neck region. *Dig. Endosc* 2018; 30: 516–521 doi:10.1111/den.13071
- [25] Nibu KI, Hayashi R, Asakage T et al. Japanese clinical practice guideline for head and neck cancer. *Auris Nasus Larynx* 2017; 44: 375–380 doi:10.1016/j.anl.2017.02.004
- [26] Yoshio T, Tsuchida T, Ishiyama A et al. Efficacy of double-scope endoscopic submucosal dissection and long-term outcomes of endoscopic resection for superficial pharyngeal cancer. *Dig Endosc* 2017; 29: 152–159 doi:10.1111/den.12712
- [27] Minami H, Tabuchi M, Matsushima K et al. Endoscopic submucosal dissection of the pharyngeal region using anchored hemoclip with surgical thread: a novel method. *Endosc Int Open* 2016; 4: E828–E831
- [28] Matsuno K, Miyamoto H, Shono T et al. Efficacy of a new traction method using ring-shaped thread for endoscopic submucosal dissec-

- tion in the pharynx. *Esophagus* 2023; 20: 256–263 doi:10.1007/s10388-022-00971-0
- [29] Cammarota G, Cesaro P, Cazzato A et al. The water immersion technique is easy to learn for routine use during EGD for duodenal villous evaluation: a single-center 2-year experience. *J Clin Gastroenterol* 2009; 43: 244–248
- [30] Frossard JL, Gervaz P, Huber O. Water-immersion sigmoidoscopy to treat acute GI bleeding in the perioperative period after surgical colorectal anastomosis. *Gastrointest Endosc* 2010; 71: 167–170 doi:10.1016/j.gie.2009.07.018
- [31] Despott EJ, Murino A. Saline-immersion therapeutic endoscopy (SITE): an evolution of underwater endoscopic lesion resection. *Dig Liver Dis* 2017; 49: 1376 doi:10.1016/j.dld.2017.08.035
- [32] Imai K, Tanaka M, Hasuike N et al. Feasibility of a “resect and watch” strategy with endoscopic resection for superficial pharyngeal cancer. *Gastrointest Endosc* 2013; 78: 22–29