

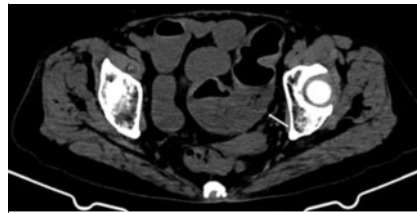
A radiation-free novel approach for intestinal stent placement: the “scope-in-scope” technique

An elderly woman with persistent abdominal pain and bloating was diagnosed with obstructive sigmoid colon cancer on computed tomography (CT) (► **Fig. 1**). Because of a low oxygen saturation value caused by secondary aspiration pneumonia she was admitted to the intensive care unit; therefore transfer to a fluoroscopy-equipped operating room was inappropriate.

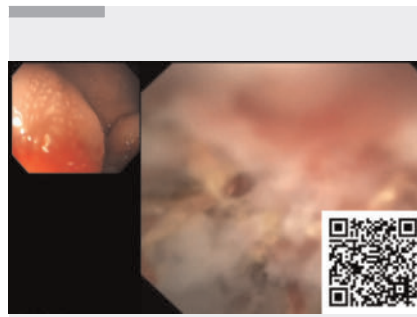
After multidisciplinary discussions, colonic stent placement was decided upon, using the “scope-in-scope” technique that combines digital single-operator cholangioscopy with colonoscopy. The colonoscope was used to approach the sigmoid colon, where an infiltrative mass was causing luminal narrowing (► **Fig. 2**). Then the cholangioscope (9-Fr, EyeMax; Micro-Tech, Nanjing, China) was inserted directly through the colonoscope biopsy channel.

The forward direction of the cholangioscope can be flexibly adjusted using the operating unit (► **Video 1**) and narrow lumens can be navigated under direct visualization. Thus clear observation of the internal structure of the colonic tumor was possible (► **Fig. 3**). The cholangioscope was advanced accompanied by irrigation with saline. Passage beyond the obstructed segment was confirmed when dilated intestinal lumen was seen (► **Fig. 4**).

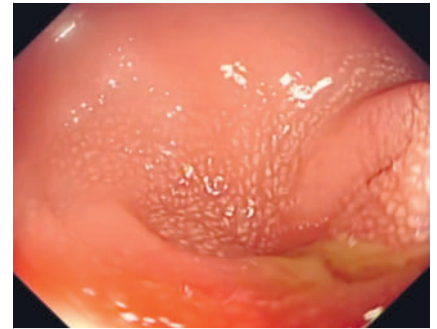A 0.035-inch guidewire was inserted through the forceps channel of the cholangioscope and positioned on the oral side of the tumor. The guidewire was maintained in this position as the cholangioscope was withdrawn, measuring the length of the tumor for stent selection. Guided by the wire and direct visualization, an uncoated metal intestinal stent (25 mm diameter, 9 cm length; Boston Scientific) was gradually deployed. It was possible to introduce the cholangioscope into the lumen of the incompletely expanded stent, to ensure that the stent ex-



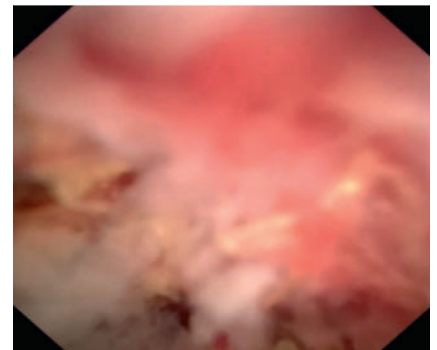
► **Fig. 1** Abdominal computed tomography in an elderly woman, showing a sigmoid colon mass with distension of the distal bowel (arrow).



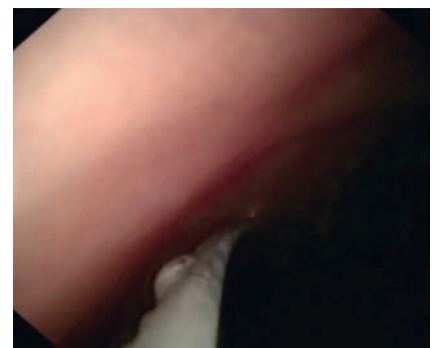
► **Video 1** “Scope-in-scope” technique, combining cholangioscopy and colonoscopy: swift placement of an intestinal stent without fluoroscopic guidance.



► **Fig. 2** Colonoscopy showed an infiltrative mass in the sigmoid colon, accompanied by luminal narrowing.



► **Fig. 3** Cholangioscopy image: ulceration and necrotic areas are observed within the tumor cavity.

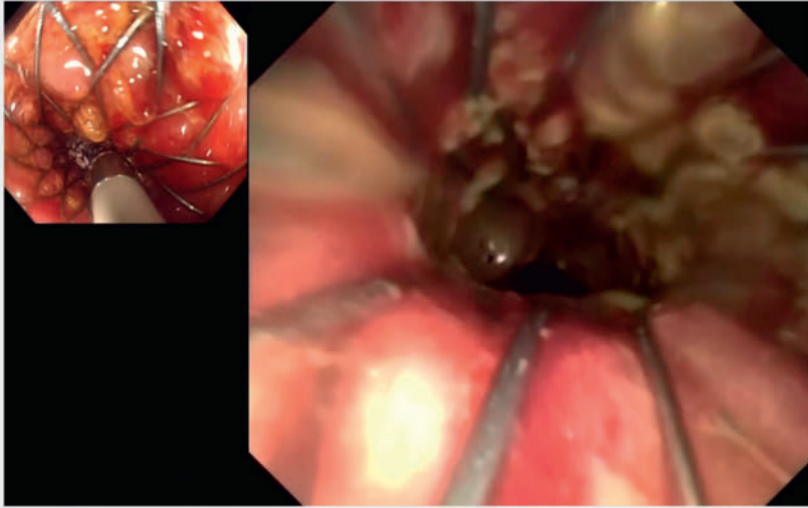


► **Fig. 4** The cholangioscope showed dilated intestinal lumen, indicating passage beyond the obstructed segment.

tended beyond both ends of the narrowed segment (► **Fig. 5**).

Postoperatively, the patient experienced significant relief from abdominal pain and bloating, bowel movements were successfully resumed, and no complications such as bleeding or perforation were encountered.

Traditional procedures for endoscopic stent placement [1] may lead to radiation exposure for both doctors and patients. This new method is particularly beneficial for certain groups, such as pregnant women, children, and patients with fragile constitutions. The “scope-in-scope” method described above, akin to its application in the appendiceal cavity [2], uniquely allows direct observation and



► **Fig. 5** Cholangioscopy image: the cholangioscope can be introduced into the incompletely expanded stent lumen.

treatment for colonic obstructions and may reduce the risk of perforation and bleeding.

It presents a safer and more efficient alternative for stent placement in patients for whom fluoroscopy is undesirable or at institutions lacking fluoroscopic equipment.

Endoscopy_UCTN_Code_TTT_1AQ_2AF

Funding Information

Natural Science Foundation of Fujian Province

<http://dx.doi.org/10.13039/501100003392>
2021J01388

Fujian Medical University
<http://dx.doi.org/10.13039/501100013795>
2022QH1299

Conflict of Interest

The authors declare that they have no conflict of interest.

The authors

Jiaqing Hu^{1,2‡}, Jinhui Zheng^{1‡}, Changshun Yang³, Xiang Gao¹, Xianbin Guo¹, Xiaoling Zheng¹

- 1 Department of Gastrointestinal Endoscopy, Fujian Provincial Hospital, Fuzhou, China
- 2 Fujian Medical University Provincial Clinical Medical College, Fuzhou, China
- 3 Department of Surgical Oncology, Fujian Provincial Hospital, Fuzhou, China

Corresponding author

Xiaoling Zheng, MD

Department of Gastrointestinal Endoscopy, Fujian Provincial Hospital, Fuzhou City, Fujian Province, CN 350001, China
fjzhengxl@163.com

References

- [1] van Hooft JE, van Halsema EE, Vanbiervliet G et al. European Society of Gastrointestinal Endoscopy. Self-expandable metal stents for obstructing colonic and extracolonic cancer: European Society of Gastrointestinal Endoscopy (ESGE) Clinical Guideline. *Endoscopy* 2014; 46: 990–1053. doi:10.1016/j.gie.2014.09.018

- [2] Kong LJ, Liu D, Zhang JY et al. Digital single-operator cholangioscope for endoscopic retrograde appendicitis therapy. *Endoscopy* 2022; 54: 396–400. doi:10.1055/a-1490-0434

Bibliography

Endoscopy 2024; 56: E313–E314

DOI 10.1055/a-2291-9315

ISSN 0013-726X

© 2024. The Author(s).

This is an open access article published by Thieme under the terms of the Creative Commons Attribution License, permitting unrestricted use, distribution, and reproduction so long as the original work is properly cited.

(<https://creativecommons.org/licenses/by/4.0/>)

Georg Thieme Verlag KG, Rüdigerstraße 14, 70469 Stuttgart, Germany



ENDOSCOPY E-VIDEOS

<https://eref.thieme.de/e-videos>



E-Videos is an open access online section of the journal *Endoscopy*, reporting on interesting cases

and new techniques in gastroenterological endoscopy. All papers include a high-quality video and are published with a Creative Commons CC-BY license. *Endoscopy E-Videos* qualify for HINARI discounts and waivers and eligibility is automatically checked during the submission process.

We grant 100% waivers to articles whose corresponding authors are based in Group A countries and 50% waivers to those who are based in Group B countries as classified by Research4Life (see: <https://www.research4life.org/access/eligibility/>).

This section has its own submission website at

<https://mc.manuscriptcentral.com/e-videos>

‡ Contributed equally to the manuscript.