Thieme

Endoscopic intermuscular dissection of early anal cancer

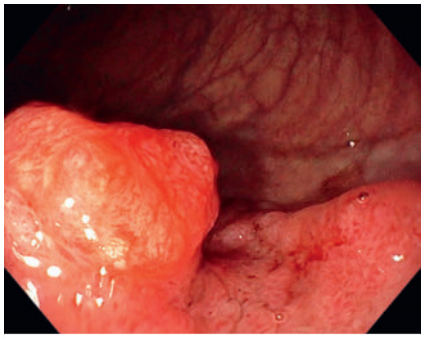

▶ **Fig. 1** White-light imaging of the top of a large anal nodule showing an unusual pit pattern in a 44-year-old woman presenting with rectal blood loss.

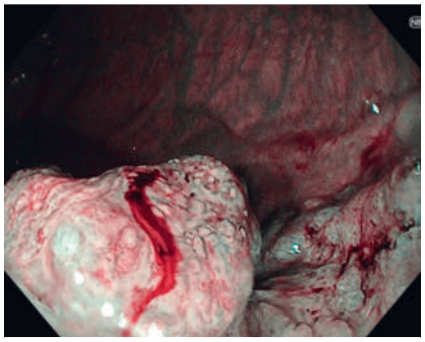

▶ **Fig. 2** Narrow-band imaging of the top of the large nodule showing nonstructured, amorphous pits and nearly avascular and loose microcapillary vessels.

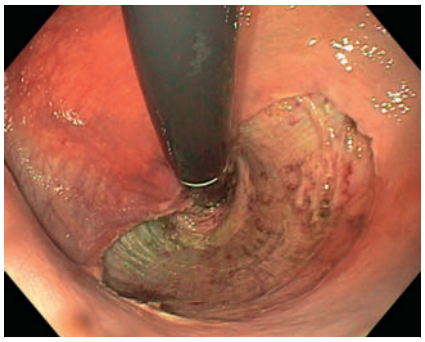

▶ **Fig. 3** Endoscopic view of the resection site after endoscopic intermuscular dissection (EID).

Anal cancer accounts for 0.5 % of all new cancer cases, with an observed annual increase in incidence of up to 2.7 % over the past decade [1]. This increase has closely mirrored the rise in human papillomavirus infections, the most important risk factor for anal cancer. According to international guidelines [2–4], marginal/perianal lesions smaller than 2 cm without lymphatic involvement or metastatic spread can be curatively treated with complete local excision, thereby sparing patients the adverse effects of surgery or chemoradiotherapy. Here, we describe a case of early anal cancer which was successfully treated by endoscopic intermuscular dissection (EID).

A 44-year-old woman presented with rectal blood loss. Colonoscopy revealed a 30-mm laterally spreading polyp with a large nodule and involvement of the dentate line. Endoscopic assessment showed an unusual pit pattern on the top of the large nodule (▶ **Fig. 1**). Virtual chromoendoscopy showed nonstructured, amorphous pits and nearly avascular and loose microcapillary vessels (▶ **Fig. 2**). As deep submucosal invasion was suspected, EID was performed (see step-by-step explanation in ▶ **Video 1**). We used a conventional video endoscope (GIF-TH190; Olympus, Germany) with a small-caliber-tip transparent hood (DH-28GR; Fujifilm, Japan) fitted to the tip of the endoscope. A FlushKnife BT (DK2618JB-15; Fujifilm, Japan) was used for incision and dissection. For electrical cutting and coagulation, a VIO 300 D electrosurgical generator (Erbe Elektromedizin, Germany) was used. EID was carried out using the tunneling method [5]: an intermuscular tunnel was created from the anal canal to the proximal side in the distal rectum, followed by mobilization of the lateral edges. Complete en bloc resection was achieved (▶ **Fig. 3**, ▶ **Fig. 4**; total proce-

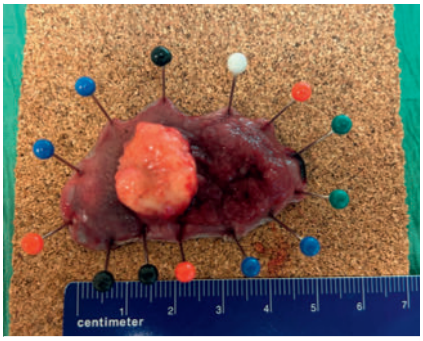

▶ **Fig. 4** Macroscopic view of the resected specimen.

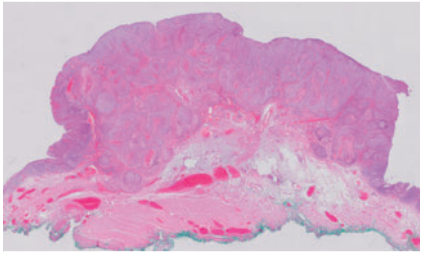

▶ **Fig. 5** Histological analysis of the resected specimen (hematoxylin-eosin stain) showing a T1Sm2 squamous cell carcinoma with free resection margins (> 2 mm).

▶ **Video 1** Endoscopic intermuscular dissection of early anal cancer: step-by-step demonstration of the procedure.

dure time 120 min). Histological analysis showed a T1Sm2 squamous cell carcinoma with free resection margins (> 2 mm) and no signs of lymphovascular invasion or high-grade tumor budding (▶ **Fig. 5**). In conclusion, EID is a feasible and potentially curative treatment option for small, localized early-stage anal cancers.

Endoscopy_UCTN_Code_TTT_1AQ_2AD_3AF

Acknowledgement

We would like to thank our expert gastrointestinal pathologist Stijn Crobach (Department of Pathology, Leiden University Medical Center) for examining and providing histological images of the resected specimen.

Conflict of Interest

The authors declare that they have no conflict of interest.

The authors

Hao Dang[1], Daan A. Verhoeven[1], Kirill Basiliya[1], Jurjen J Boonstra[1]

1 Department of Gastroenterology and Hepatology, Leiden University Medical Center, Leiden, Netherlands

Corresponding author

Hao Dang, PhD
Department of Gastroenterology and Hepatology, Leiden University Medical Center, Postzone C4-P, PO Box 9600, 2300 RC Leiden, The Netherlands
H.Dang@lumc.nl

References

[1] Eng C, Ciombor KK, Cho M et al. Anal cancer: emerging standards in a rare disease. J Clin Oncol 2022; 40: 2774–2788. doi:10.1200/JCO.21.02566

[2] Rao S, Guren MG, Khan K et al. Anal cancer: ESMO clinical practice guidelines for diagnosis, treatment and follow-up. Ann Oncol 2021; 32: 1087–1100. doi:10.1016/j.annonc.2021.06.015

[3] Benson AB, Venook AP, Al-Hawary MM et al. Anal carcinoma, version 2.2023, NCCN clinical practice guidelines in oncology. J Natl Compr Canc Netw 2023; 21: 653–677. doi:10.6004/jnccn.2023.0030

[4] Valadao M, Riechelmann RP, Silva J et al. Brazilian Society of Surgical Oncology: guidelines for the management of anal canal cancer. J Surg Oncol 2023. doi:10.1002/jso.27269

[5] Dang H, Hardwick JCH, Boonstra JJ. Endoscopic intermuscular dissection with intermuscular tunneling for local resection of rectal cancer with deep submucosal invasion. VideoGIE 2022; 7: 273–277. doi:10.1016/j.vgie.2022.02.012

Bibliography

Endoscopy 2024; 56: E472–E473
DOI 10.1055/a-2321-9527
ISSN 0013-726X

Georg Thieme Verlag KG, Rüdigerstraße 14, 70469 Stuttgart, Germany