

# Journal of Reconstructive Microsurgery

## Lymphatic patterns in the superficial circumflex iliac artery perforator flap

Jose L Campos Sánchez, Sinikka Suominen, Gemma Pons, Ali M. Al-Sakkaf, Irene Laura Lusetti, Max Sirota, Francisco Javier Vela, Laura Cristina Pires, Francisco Miguel Sánchez Margallo, Elena Abellán Rubio, Jaume Masia Ayala.

Affiliations below.

DOI: 10.1055/a-2340-9629

Please cite this article as: Campos Sánchez J L, Suominen S, Pons G et al. Lymphatic patterns in the superficial circumflex iliac artery perforator flap. Journal of Reconstructive Microsurgery 2024. doi: 10.1055/a-2340-9629

**Conflict of Interest:** The authors declare that they have no conflict of interest.

**This study was supported by** Junta de Extremadura (<http://dx.doi.org/10.13039/501100014181>), GR21201

**Trial registration:** IIBSPIN202273, EU Clinical Trials Register (<https://www.clinicaltrialsregister.eu>), Multi-center study

### Abstract:

**Background:** Lymphedema is a chronic condition, characterized by fluid buildup and tissue swelling and is caused by impairment of the lymphatic system. The lymph interpositional flap transfer (LIFT) technique, in which lymph flow is restored with a flap that includes subdermal lymphatic channels, is an option for surgical reconstruction. The superficial circumflex iliac artery perforator (SCIP) flap can be used for this purpose. This study aimed to describe and characterize the lymphatic patterns within the vascular territory of the superficial circumflex iliac artery perforator flap.

**Methods:** This cross-sectional multicenter study involved 19 healthy volunteers aged  $\geq 18$  years of both sexes assessing the bilateral SCIP flap zone. Superficial lymphatic patterns were evaluated at 4-, 14-, and 24-minutes after indocyanine green lymphography (ICG) injection. Standardized procedures were implemented for all participants in both hospitals.

**Results:** The linear pattern was predominant bilaterally. The median number of lymphatic vessels and their length increased over time. Most lymphatic vessels in the superficial circumflex iliac artery perforator flap were oriented towards the inguinal lymph node. However, the left SCIP zone lymphatic vessels were directed opposite to the inguinal lymph node.

**Conclusion:** The two sides SCIP zones were not significantly different. The primary direction of the bilateral lymphatic vessels was towards the inguinal lymph node, although only single side lymphatic vessels were in the opposite direction. These findings emphasize the importance of assessing lymphatic axially and coherent lymphatic patterns prior to undertaking the SCIP as an interposition flap, to ensure effective restoration of lymphatic flow.

### Corresponding Author:

DVM, MSc, PhD st Jose L Campos Sánchez, Centro de Cirugía de Mínima Invasión Jesús Usón, Microsurgery, Carretera Nacional 521, km 41,8, 10071 Caceres, Spain, [jlcampos@ccmijesususon.com](mailto:jlcampos@ccmijesususon.com), [revjcs12@gmail.com](mailto:revjcs12@gmail.com)

### Affiliations:

Jose L Campos Sánchez, Centro de Cirugía de Mínima Invasión Jesús Usón, Microsurgery, Caceres, Spain

Gemma Pons, Hospital de la Santa Creu i Sant Pau, Plastic Surgery, Barcelona, Spain

Ali M. Al-Sakkaf, Hospital de la Santa Creu i Sant Pau, Plastic Surgery, Barcelona, Spain

[...]

Jaume Masia Ayala, Hospital de la Santa Creu i Sant Pau, Plastic Surgery, Barcelona, Spain

## Lymphatic patterns in the superficial circumflex iliac artery perforator flap

José Luis Campos, DVM, MSc, PhD<sup>1,\*</sup>, Sinikka Suominen, MD, PhD<sup>2</sup>, Gemma Pons, MD, PhD<sup>3</sup>, Ali M. Al-Sakkaf, MD, MSc, PhD<sup>3,\*</sup>, Irene Laura Lusetti, MD<sup>3</sup>, Max Sirota, MD<sup>3</sup>, Francisco Javier Vela, DVM, PhD<sup>1</sup>, Laura Pires, DVM<sup>1</sup>, Francisco Miguel Sánchez-Margallo, DVM, PhD<sup>1</sup>, Elena Abellán, DVM, PhD<sup>1</sup>, Jaume Masiá, MD, PhD<sup>3</sup>

<sup>1</sup>Department of Microsurgery, Jesús Usón Minimally Invasive Surgery Centre, Cáceres, Spain

<sup>2</sup>Department of Plastic and Reconstructive Surgery, Helsinki University Central Hospital, Helsinki, Finland

<sup>3</sup>Department of Plastic Surgery, Hospital de la Santa Creu i Sant Pau, Barcelona, Spain

\* Corresponding authors:

José Luis Campos

Department of Microsurgery, Jesús Usón Minimally Invasive Surgery Centre, Cáceres, Spain  
Carretera Nacional 521, Km 41.8 10071, 10004 Cáceres, Spain

E-mail address: jlcampos@ccmijesususon.com

**Previous presentations:**

None.

### **Abstract**

**Background:** Lymphedema is a chronic condition, characterized by fluid buildup and tissue swelling and is caused by impairment of the lymphatic system. The lymph interpositional flap transfer (LIFT) technique, in which lymph flow is restored with a flap that includes subdermal lymphatic channels, is an option for surgical reconstruction. The superficial circumflex iliac artery perforator (SCIP) flap can be used for this purpose. This study aimed

to describe and characterize the lymphatic patterns within the vascular territory of the superficial circumflex iliac artery perforator flap.

**Methods:** This cross-sectional multicenter study involved 19 healthy volunteers aged  $\geq 18$  years of both sexes assessing the bilateral SCIP flap zone. Superficial lymphatic patterns were evaluated at 4-, 14-, and 24-minutes after indocyanine green lymphography (ICG) injection. Standardized procedures were implemented for all participants in both hospitals.

**Results:** The linear pattern was predominant bilaterally. The median number of lymphatic vessels and their length increased over time. Most lymphatic vessels in the superficial circumflex iliac artery perforator flap were oriented towards the inguinal lymph node. However, the left SCIP zone lymphatic vessels were directed opposite to the inguinal lymph node.

**Conclusion:** The two sides SCIP zones were not significantly different. The primary direction of the bilateral lymphatic vessels was towards the inguinal lymph node, although only single side lymphatic vessels were in the opposite direction. These findings emphasize the importance of assessing lymphatic axially and coherent lymphatic patterns prior to undertaking the SCIP as an interposition flap, to ensure effective restoration of lymphatic flow.

**Keywords:** Lymph; Lymphedema; Microsurgery; SCIP flap; Lymphatic pattern

## Introduction

The lymphatic system comprises lymphatic organs and vessels which play vital roles in maintaining tissue fluid balance, macromolecule transport, and fat absorption from the intestine, and assists the immune system in ensuring adaptive immune protection and immune surveillance.<sup>1-4</sup> Impaired lymphatic function can lead to lymphedema, a chronic

condition characterized by a weakened immune response, fluid accumulation, tissue swelling, and fibroadipose deposition.<sup>2,5-7</sup>

To date, lymphedema has no definitive cure, but many treatments can improve symptoms and quality of life of patients. These techniques are divided into conservative and surgical approaches.<sup>8</sup> Surgical procedures can be classified into two categories: excisional and physiological. Excisional procedures primarily involve tissue volume reduction and the enhancement of aesthetic outcomes, while physiological procedures focus on restoring or reconstructing the natural lymph fluid drainage system.<sup>9-17</sup>

Currently, in lymphatic reconstructive surgeries, lymphovenous anastomosis (LVA)<sup>18</sup> and vascularized lymph node transfer (VLNT)<sup>19</sup> are the most valuable surgical options. However, both procedures have several drawbacks: LVA requires supermicrosurgical techniques and healthy, actively contractile lymphatic vessels. Vascularized lymph node transfer entails a potential risk of donor-site lymphedema, and functional lymph node transfer is not consistently feasible.<sup>16</sup>

In recent years, a novel concept, known as lymph-interposition-flap transfer (LIFT), has emerged.<sup>17,20</sup> This technique involves the reconstruction of lymphatic pathways by utilizing a flap that includes lymph vessels, but without the need for lymph node transfer or supermicrosurgical lymphatic anastomosis. This underscores its potential in both the treatment and prevention of lymphedema.<sup>17,20-22</sup>

The primary determinant for successful lymph flow restoration is the preservation of lymph axiality and the potential to bridge regions with robust lymphatic transport capacity. In theory, any flap containing deep adipose tissue can be employed for LIFT.<sup>23-25</sup> However, the superficial circumflex iliac artery perforator (SCIP) flap is particularly advantageous as it resides in an area devoid of dominant lymphatic pathways and links to the superficial epigastric lymph nodes. By utilizing this flap, the risk of donor-site lymphedema is

minimized, even in the absence of incorporated lymph nodes.<sup>26-33</sup> The aim of this study was to describe the superficial lymphatic vessel anatomy within the SCIP flap zone by using indocyanine green (ICG) lymphography to facilitate the understanding of lymphatic flow and its application as an interpositional flap.

### **Materials and methods**

After obtaining approval from the institutional review board, this cross-sectional study was conducted between September 2022 and November 2022 at Hospital de la Santa Creu i Sant Pau (Barcelona, Spain) and Helsinki University Hospital H.U.S. (Helsinki, Finland).

This multicenter investigation aimed at evaluating and defining superficial lymphatic patterns within the vascular territory of the SCIP flap in a cohort of 19 healthy volunteers of both sexes. Standardized procedures were implemented for all participants in both hospitals. The study population comprised only individuals aged  $\geq 18$  years. Individuals were excluded for the following reasons: pregnancy, history of previous superficial abdominal or inguinal surgeries, or any signs or symptoms of lymphedema. Before the study commencement, written informed consent was obtained from all participants. Comprehensive demographic information, medical history, and thorough physical examinations were documented. ICG lymphography was employed to evaluate the superficial lymphatic channels and to establish the lymphatic drainage patterns specific to the SCIP area. Despite the inherent limitation of ICG, with a visualization depth restricted to 1.5 mm, it proved adequate for discerning superficial lymphatic vessels in the SCIP area. For each volunteer, a digital video camera equipped with an infrared filter was used to capture and record the ICG contrast (25 mg; Verdyne; Diagnostic Green Limited, Westmeath, Ireland). Throughout the study, adverse reactions, if any, were closely monitored.

Indocyanine green lymphography entails the subcutaneous administration of ICG, a water-soluble cyanine dye, diluted in a vial containing 2.5 mg/mL of contrast mixed with 5 mL of

10% glucose saline solution. A total volume of 1.2 mL of the diluted solution was injected subcutaneously on the right and left sides (0.6 mL on each side) at three distinct points spaced 6 cm apart (0.2 mL per point). The first injection point was at the level of the iliac crest, the second point was 3 cm above, and the third point was 3 cm below the initial injection site. After injection, the transport of the contrast agent was recorded at three-time points using an infrared camera (Fluobeam [Fluoptics, Grenoble, France]<sup>34</sup> and EleVision IR Platform [Medtronic, Minneapolis, MN, USA]<sup>35</sup>): 4 minutes (i.e., the early transient phase), 14 minutes (i.e., the plateau phase), and 24 minutes (i.e., the late plateau phase). Several parameters were assessed to qualitatively evaluate the superficial lymphatic patterns, including assessment of the number of lymphatic vessels, their direction, length, and the presence of a normal linear pattern. Both sides SCIP territories were analyzed.

## **Results**

### **Characteristics of study participants**

Nineteen healthy volunteers were enrolled in this study. However, four volunteers were excluded because of their medical history, thus 15 individuals were included in the final analysis of the data. Among the analyzed volunteers, 12 were women and 3 were men. The body mass index (BMI) of the individuals was 23.6 (range, 20.2–27). The mean age was 40.5 years (range, 30–50 years). No adverse reactions occurred after the administration of the ICG in any of the volunteers, all of whom tolerated the procedure well. The analysis of results was stratified for both SCIP sides, based on the hypothesis of possible distinctions in the lymphatic anatomy between both sides, whether in terms of quantity and/or distribution. Tables 1 and 2 summarize the properties of the Right and left side of the SCIP flap zone.

### **Four minutes: the early transient phase on both SCIP sides (Fig. 1 and Fig. 2)**

In both sides, the vessels of 12 participants displayed a normal linear pattern, whereas the vessels of the remaining three participants did not exhibit this pattern. The median count of

lymphatic vessels observed per individual was one on each side (range, 1). All lymphatic vessels observed in the 15 volunteers exhibited a trajectory towards the inguinal lymph node (ILN) on both sides, except for one of the volunteers, in which the lymphatic vessel on the left side was oriented opposite to the ILN. The mean length of the lymphatic vessels on the right and left side were 2.8 cm and 2.9 cm, respectively.

**Fourteen minutes: the plateau phase in both SCIP sides (Fig. 3 and Fig.4)**

The median count of observed lymphatic vessels per individual on the right side was two vessels (range, 1–2), whereas on the left side only one was observed (range, 1). The directional distribution of the lymphatic vessels was predominantly towards the ILN in all 15 volunteers, whereas one volunteer presented the left side lymphatic vessel oriented in the opposite direction to the ILN. Furthermore, the computed mean length of the lymphatic vessels on the right and left sides were 3.76 cm and 3.9 cm, respectively.

**Twenty-four minutes: the late plateau phase on both SCIP sides (Fig. 5 and Fig.6)**

The median count of observed lymphatic vessels per individual on the right side was three vessels (range, 1–3), and the count on the left side was two vessels (range, 1–2). All lymphatic vessels observed at this stage were oriented toward the ILN in all 15 volunteers, except for one participant in which the left-side lymphatic vessels were oriented in the opposite direction to the ILN. Furthermore, the calculated mean length of the lymphatic vessels on the right and left sides were 5.24 cm and 5.5 cm, respectively.

The results indicated that the predominant lymphatic pattern observed in the SCIP flap involved lymphatic vessels directed towards the ILN (**Fig. 7**). No lymphatic vessels were observed oriented away from the ILN; however, such patterns were noted only in one volunteer on the left side (**Fig. 8**). The number of lymphatic vessels and their length increased with time bilaterally (**Figs. 9 and 10**). Most patients had a predominantly unidirectional and favorable flow pattern within the lymphatic system.

## Discussion

The LIFT technique is a corrective physiological procedure employed in lymphatic surgery, in which lymphatic reconstruction is achieved by utilizing a flap that includes superficial lymph vessels in the cutaneous island.<sup>17,21</sup> Unlike other techniques such as VLNT<sup>19</sup> or supermicrosurgical LVA,<sup>36</sup> LIFT does not involve the transfer of lymph nodes or the performance of intricate lymphatic anastomoses. Any flap containing subcutaneous fat could theoretically be used for LIFT.<sup>17,21</sup> However, the SCIP flap is particularly advantageous as it is situated in an area devoid of major lymphatic pathways. Lymph axiality plays a crucial role in facilitating lymph flow restoration, thereby making it a significant factor to consider in achieving successful outcomes in lymphatic surgery.<sup>25</sup> In the context of VLNT procedures, the primary objective is to establish a novel lymphatic afferent pathway to a specific lymph node. This procedure aims to enhance the lymphatic circulation and to mitigate swelling in the affected region, thereby enhancing the quality of life of the patient. Lymph node transfer is typically performed as a component of vascularized tissue transfer, commonly involving a tissue flap containing arteries, veins, and lymphatic vessels, which is surgically connected to the affected area to provide functional lymphatic flow. The SCIP flap has been effectively utilized for reconstruction across diverse anatomical regions.<sup>37-39</sup> This flap is distinguished by a dual vascular pedicle, typically with one extending vertically through the skin and the other traversing deep within the subcutaneous tissue toward the mid-axillary line. Notably, for optimal inclusion of superficial lymphatic vessels and to minimize dissection while avoiding harm to the deeper lymphatic structures beneath the superficialis fascia, preference should be given to the pedicle ascending vertically into the skin over the one advancing deep toward the axillary line.<sup>40</sup> Understanding the lymphatic pattern and its axiality within the SCIP flap is crucial for the effective design of the contiguous skin island and its successful application and orientation.<sup>21</sup>



The aim of this present cross-sectional study was to evaluate and characterize the lymphatic patterns within the vascular territory of the SCIP flap. Lymphography using ICG was used to visualize the lymphatic channels and to assess the lymphatic drainage patterns specific to the SCIP area.<sup>41-43</sup>

We assessed the bilateral lymphatic patterns of the SCIP zone at 4-, 14-, and 24-minute intervals after ICG lymphography injection. All injections were administered laterally, aligning with the study's protocol, which did not entail accessing the pedicle of the SCIP flap. Instead, the focus was on delineating the superficial lymphatics within the cutaneous island of the SCIP flap.

We found that most lymphatic vessels within the SCIP flap exhibited a trajectory toward the ILN, except in one volunteer the lymphatic vessels on the left side were observed to be directed opposite to the ILN. Furthermore, the number and length of lymphatic vessels observed increased over time, which indicated good uptake and transport of ICG dye through the lymphatic network. This underscores the importance of assessing the lymphatic pattern in the SCIP flap area preoperatively to ensure proper lymphatic flow.

The findings from this study provide valuable insights into the count, directional distribution, length, and flow dynamics of lymphatic vessels within the examined population. These results enhance our understanding of standard anatomy, possible variations and their potential impact on lymphatic transport. Furthermore, these findings have significant implications for further research and clinical applications in diverse physiological and pathological scenarios, thereby enabling a deeper exploration of lymphatic function and its role in various contexts.

This study provides valuable insights into the superficial lymphatic patterns within the SCIP flap, consistent with the findings reported by Suami *et al.*<sup>44</sup> Several studies have previously demonstrated the efficacy of using a simultaneous lymphatic flap in autologous breast reconstruction using the deep inferior epigastric artery perforator flap,<sup>45,46</sup> or the superficial

circumflex iliac artery perforator free flap including lymphatic vessels.<sup>23</sup> However, to date, insufficient information exists in the scientific literature to describe all lymphatic patterns in this area for the analysis before surgery.

This study is limited by the fact that only a small number of participants were involved, which makes reaching a standard anatomical conclusion difficult. In addition, the use of different infrared cameras in both hospitals may have influenced the overall sensitivity of lymphatic vessel detection. Moreover, ICG dye is constrained by its maximum visualization depth of up to 1.5 mm, although it was adequate for detecting superficial lymphatics in the SCIP zone. The lateral injection sites may limit visualization of certain medial lymphatics, but such visualization was beyond the scope of this study. Lastly, it is essential to clarify that the study's objective was not to deliberate on the indications of the LIFT flap, rather the focus of the study was to provide evidence that underscored the significance of the LIFT concept, which is predicated on the orientation and axially of the superficial lymphatic vessels. Notably, the SCIP flap was presented as a representative example of a commonly employed flap for LIFT procedures.

### **Conclusions**

This study delineates the superficial lymphatic pathway patterns within the SCIP flap zone, indicating its suitability for implementing the LIFT principle. These results underscore the significance of lymphatic axially and compatible lymphatic patterns in accomplishing successful lymphatic flow restoration.

### **Ethics statement**

This cross-sectional multicenter study was approved by the Ethical Committees of the Hospital de la Santa Creu i Sant Pau (Barcelona, Spain) and Helsinki University Hospital (Helsinki, Finland) (Code: EC/22/338/7016 (R-EOM)).

### **Acknowledgments**

We would like to express our gratitude to all the volunteers for participating in this study and to all hospital staff of both hospitals who assisted in collecting data and performing ICG imaging. Special thanks are extended to María Pérez for preparing the figures and to the Microsurgery Department of JUMISC for providing constant encouragement.

### **Funding**

This work was partially funded by the Junta de Extremadura (Spain), the European Regional Development Fund (ERDF) (GR21201).

### **Conflict of interest statement**

None declared.

### **References**

1. Schulte-Merker S, Sabine A, Petrova TV. Lymphatic vascular morphogenesis in development, physiology, and disease. *J Cell Biol* 2011;193:607–618.
2. Alitalo, K. The lymphatic vasculature in disease. *Nat Med* 2011;17:1371–1380.
3. Padberg Y, Schulte-Merker S, Van Impel A. The lymphatic vasculature revisited—new developments in the zebrafish. *Methods Cell Biol* 2017;138:221–238.
4. Alderfer L, Wei A, Hanjaya-Putra D. Lymphatic tissue engineering and regeneration. *J Biol Eng* 2018;12:32.
5. Kim KW, Song JH. Emerging roles of lymphatic vasculature in immunity. *Immune Netw* 2017;17:68–76.
6. Bernier-Latmani J, Petrova TV. Intestinal lymphatic vasculature: structure, mechanisms and functions. *Nat Rev Gastroenterol Hepatol* 2017;14:510–26.
7. Ogata F, Fujiu K, Koshima I, Nagai R, Manabe I. Phenotypic modulation of smooth muscle cells in lymphoedema. *Br J Dermatol* 2015;172:1286–1293.

8. Executive Committee of the International Society of Lymphology. The diagnosis and treatment of peripheral lymphedema: 2020 consensus document of the International Society of Lymphology. *Lymphology* 2020;53:3–19.
9. Yamamoto T, Narushima M, Yoshimatsu H, et al. Minimally invasive lymphatic supermicrosurgery (MILS): indocyanine green lymphography-guided simultaneous multisite lymphaticovenular anastomoses via millimeter skin incisions. *Ann Plast Surg* 2014;72:67–70.
10. Chang DW. Lymphaticovenular bypass for lymphedema management in breast cancer patients: a prospective study. *Plast Reconstr Surg* 2010;126:752–758.
11. Raju A, Chang DW. Vascularized lymph node transfer for treatment of lymphedema: a comprehensive literature review. *Ann Surg* 2015;261:1013–1023
12. Yamamoto T, Saito T, Ishiura R, Iida T. Quadruple-component superficial circumflex iliac artery perforator (SCIP) flap: A chimeric SCIP flap for complex ankle reconstruction of an exposed artificial joint after total ankle arthroplasty. *J Plast Reconstr Aesthet Surg* 2016;69:1260–1265.
13. Yamamoto T, Yamamoto N, Kageyama T, et al. Supermicrosurgery for oncologic reconstructions. *Glob Health Med* 2020;2:18–23
14. Yamamoto T, Yamamoto N, Kageyama T, et al. Technical pearls in lymphatic supermicrosurgery. *Glob Health Med* 2020;2:29–32.
15. Vignes S, Blanchard M, Yannoutsos A, Arrault M. Complications of autologous lymph-node transplantation for limb lymphoedema. *Eur J Vasc Endovasc Surg* 2013;45:516–520.
16. Pons G, Masia J, Loschi P, Nardulli ML, Duch J. A case of donor-site lymphoedema after lymph node–superficial circumflex iliac artery perforator flap transfer. *J Plast Reconstr Aesthet Surg* 2014;67:119–123.
17. Yamamoto T, Yamamoto N, Kageyama T, Sakai H, Fuse Y, Tsukuura R. Lymph-interpositional-flap transfer (LIFT) based on lymph-axiality concept: simultaneous soft tissue

and lymphatic reconstruction without lymph node transfer or lymphatic anastomosis. *J Plast Reconstr Aesthet Surg* 2021;74:2604–2612.

18. Scaglioni MF, Fontein DBY, Arvanitakis M, Giovanoli P. Systematic review of lymphovenous anastomosis (LVA) for the treatment of lymphedema. *Microsurgery* 2017;37:947–953.
19. Schaverien MV, Badash I, Patel KM, Selber JC, Cheng MH. Vascularized lymph node transfer for lymphedema. *Semin Plast Surg* 2018;32:28–35.
20. Yan A, Avraham T, Zampell JC, Aschen SZ, Mehrara BJ. Mechanisms of lymphatic regeneration after tissue transfer. *PLoS One* 2011;6:e17201.
21. Gentileschi S, Servillo M, Garganese G, et al. The lymphatic superficial circumflex iliac vessels deep branch perforator flap: a new preventive approach to lower limb lymphedema after groin dissection-preliminary evidence. *Microsurgery* 2017;37:564–573.
22. Caretto AA, Stefanizzi G, Fragomeni SM, et al. Lymphatic function of the lower limb after groin dissection for vulvar cancer and reconstruction with lymphatic SCIP flap. *Cancers (Basel)* 2022;14:1076.
23. Pereira N, Cámara Á, Kufeke M, Roa R. Post-traumatic lymphedema treatment with superficial circumflex iliac artery perforator lymphatic free flap: a case report. *Microsurgery* 2019;39:354–359.
24. Yamamoto T. Onco-reconstructive supermicrosurgery. *Eur J Surg Oncol* 2019;45:1146–1151.
25. Yamamoto T, Iida T, Yoshimatsu H, Fuse Y, Hayashi A, Yamamoto N. Lymph flow restoration after tissue replantation and transfer: importance of lymph axially and possibility of lymph flow reconstruction without lymph node transfer or lymphatic anastomosis. *Plast Reconstr Surg* 2018;142:796–804.

26. Koshima I, Nanba Y, Tsutsui T, et al. Superficial circumflex iliac artery perforator flap for reconstruction of limb defects. *Plast Reconstr Surg* 2004;113:233–240.
27. Hong JP, Choi DH, Suh H, et al. A new plane of elevation: the superficial fascial plane for perforator flap elevation. *J Reconstr Microsurg* 2014;30:491–496.
28. Feng S, Xi W, Zhang Z, et al. A reappraisal of the surgical planning of the superficial circumflex iliac artery perforator flap. *J Plast Reconstr Aesthet Surg* 2017;70:469–477.
29. He Y, Jin S, Tian Z, et al. Superficial circumflex iliac artery perforator flap's imaging, anatomy and clinical applications in oral maxillofacial reconstruction. *J Craniomaxillofac Surg* 2016;44:242–248.
30. Hsu WM, Chao WN, Yang C, et al. Evolution of the free groin flap: the superficial circumflex iliac artery perforator flap. *Plast Reconstr Surg* 2007;119:1491–1498.
31. Kim JH, Kim KN, Yoon CS. Reconstruction of moderate-sized distal limb defects using a superthin superficial circumflex iliac artery perforator flap. *J Reconstr Microsurg* 2015;31:631–635.
32. Myung Y, Yim S, Kim BK. A comparison of axial circumference between superficial circumflex iliac artery perforator flap and other workhorse flaps in dorsal foot reconstruction. *J Plast Surg Hand Surg* 2017;51:381–386.
33. Gandolfi S, Postel F, Auquit-Auckbur I, et al. Vascularization of the superficial circumflex iliac perforator flap (SCIP flap): an anatomical study. *Surg Radiol Anat* 2020;42:473–481.
34. Hirche C, Engel H, Kolios L, et al. An experimental study to evaluate the Fluobeam 800 imaging system for fluorescence-guided lymphatic imaging and sentinel node biopsy. *Surg Innov* 2013;20:516–523.
35. Bigdeli AK, Gazyakan E, Schmidt VJ, et al. Indocyanine green fluorescence for free-flap perfusion imaging revisited: advanced decision making by virtual perfusion reality in visionsense fusion imaging angiography. *Surg Innov* 2016;23:249–260.

36. Onoda S, Satake T, Hamada E. Super-microsurgery technique for lymphaticovenular anastomosis. *J Vasc Surg Venous Lymphat Disord* 2023;11:177–18.
37. Kageyama, T. Effective evaluation of SCIV and SIEV as donor vessels by preoperative ultrasound in planning of thin SCIP flaps. *J Reconstr Microsurg* 2023;39:e1-e2
38. Yoshimatsu H, Karakawa R, Fuse Y, et al. Superficial circumflex iliac artery perforator flap elevation using preoperative high-resolution ultrasonography for vessel mapping and flap design. *J Reconstr Microsurg* 2022;38:217-220.
39. Kim HB, Min JC, Pak CJ, et al. Maximizing the versatility of thin flap from the groin area as a workhorse flap: the selective use of superficial circumflex iliac artery perforator (SCIP) free flap and superficial inferior epigastric artery (SIEA) free flap with precise preoperative planning. *J Reconstr Microsurg* 2023;39:148-155.
40. Gentileschi S, Servillo M, De Bonis F, et al. Radioanatomical study of the pedicle of the superficial circumflex iliac perforator flap. *J Reconstr Microsurg* 2019;35:669-676.
41. Yamamoto T, Yamamoto N, Doi K, et al. Indocyanine green-enhanced lymphography for upper extremity lymphedema: a novel severity staging system using dermal backflow patterns. *Plast Reconstr Surg* 2011;128:941–947.
42. Alander JT, Kaartinen I, Laakso A, et al. A review of indocyanine green fluorescent imaging in surgery. *Int J Biomed Imaging* 2012;2012:1–26.
43. Suami H, Chang DW, Yamada K, Kimata Y. Use of indocyanine green fluorescent lymphography for evaluating dynamic lymphatic status. *Plast Reconstr Surg* 2011;127:74e–76e.
44. Scaglioni MF, Suami H. Lymphatic anatomy of the inguinal region in aid of vascularized lymph node flap harvesting. *J Plast Reconstr Aesthet Surg*. 2015;68:419–427.
45. Yoshimatsu H, Karakawa R, Fuse Y, Yano T. Simultaneous lymphatic superficial circumflex iliac artery perforator flap transfer from the zone 4 region in autologous breast reconstruction

using the deep inferior epigastric artery perforator flap: a proof-of-concept study. *J Clin Med* 2022;11:534.

46. Yoshimatsu H, Visconti G, Karakawa R, Hayashi A. Lymphatic system transfer for lymphedema treatment: transferring the lymph nodes with their lymphatic vessels. *Plast Reconstr Surg Glob Open* 2020;8:e2721.

**Figure 1.** Results of contrast agent transport at 4 minutes in the early transient phase on the right side. ICG lymphography shows the dye inoculation points (red asterisks) and lymphatic vessels (red arrowheads). The images on the left represent the ICG visualization in the color-fused and green overlay modes. ICG, indocyanine green

**Figure 2.** Results of contrast agent transport at 4 minutes in the early transient phase on the left side. ICG lymphography shows the dye inoculation points (red asterisks) and lymphatic vessels (red arrowheads). The images on the left represent ICG visualization in the color-fused and green overlay modes. ICG, indocyanine green

**Figure 3.** Results of contrast agent transport at 14 minutes in the late plateau phase on the right side. ICG lymphography shows dye inoculation points (red asterisks) and lymphatic vessels (red arrowheads). The images on the left represent the ICG visualization in the color-fused and green overlay modes. ICG, indocyanine green

**Figure 4.** Results of contrast agent transport at 14 minutes in the late plateau phase on the left side. ICG lymphography shows the dye inoculation points (red asterisk) and lymphatic vessels (red arrowheads). The images on the left represent the ICG visualization in the color-fused and green overlay modes. ICG, indocyanine green

**Figure 5.** Results of contrast agent transport at 24 minutes in the late plateau phase on the right side. ICG lymphography shows the dye inoculation points (red asterisk) and lymphatic



vessels (red arrow). The images on the left represent the ICG visualization in the color-fused and green overlay modes. ICG, indocyanine green

**Figure 6.** Results of contrast agent transport at 24 minutes in the late plateau phase on the left side. ICG lymphography shows the dye inoculation points (red asterisks) and lymphatic vessels (red arrowheads). The images on the left represent the ICG visualization in the color-fused and green overlay modes. ICG, indocyanine green

**Figure 7.** Lymphatic pattern towards the ILN on the right side. ICG lymphography shows the dye inoculation points (red asterisks) and lymphatic vessels at 14 minutes (red arrowheads). ICG, indocyanine green

**Figure 8.** Lymphatic pattern observed in the opposite direction to the ILN on the left side. ICG lymphography shows the dye inoculation points (red asterisks) and lymphatic vessels at 14 minutes (red arrowheads). ICG, indocyanine green

**Figure 9.** Temporal variation in the mean length of lymphatic vessels on the right and left sides. The figure presents the mean length of the lymphatic vessels on the right and left sides across different time intervals, which reflects the temporal dynamics of these measurements. ICG, indocyanine green

**Figure 10.** Median count of lymphatic vessels per individual on the right and left sides over time. The figure presents the median counts of observed lymphatic vessels per individual on the right and left sides across different time intervals, which illustrates variations in vessel counts over time. ICG, indocyanine green.

**Table 1.** Summary of the results of the SCIP flap zone on the right side

	<b>Linear pattern</b> <b>[no. volunteers</b> <b>(%)]</b>	<b>Median count of</b> <b>lymphatic vessels</b>	<b>Direction</b> <b>(no. volunteers [%])</b>	<b>Mean length</b>

<b>4 min</b>	12 (80%)	1	Toward ILN (100%)	2.8 cm
			Opposite to ILN (0.0%)	
<b>14 min</b>		2	Toward ILN (100%)	3.76 cm
			Opposite to ILN (0.0%)	
<b>24 min</b>		3	Toward ILN (100%)	5.24 cm
			Opposite to ILN (0.0%)	

SCIP, superficial circumflex iliac artery perforator. ILN, inguinal lymph node

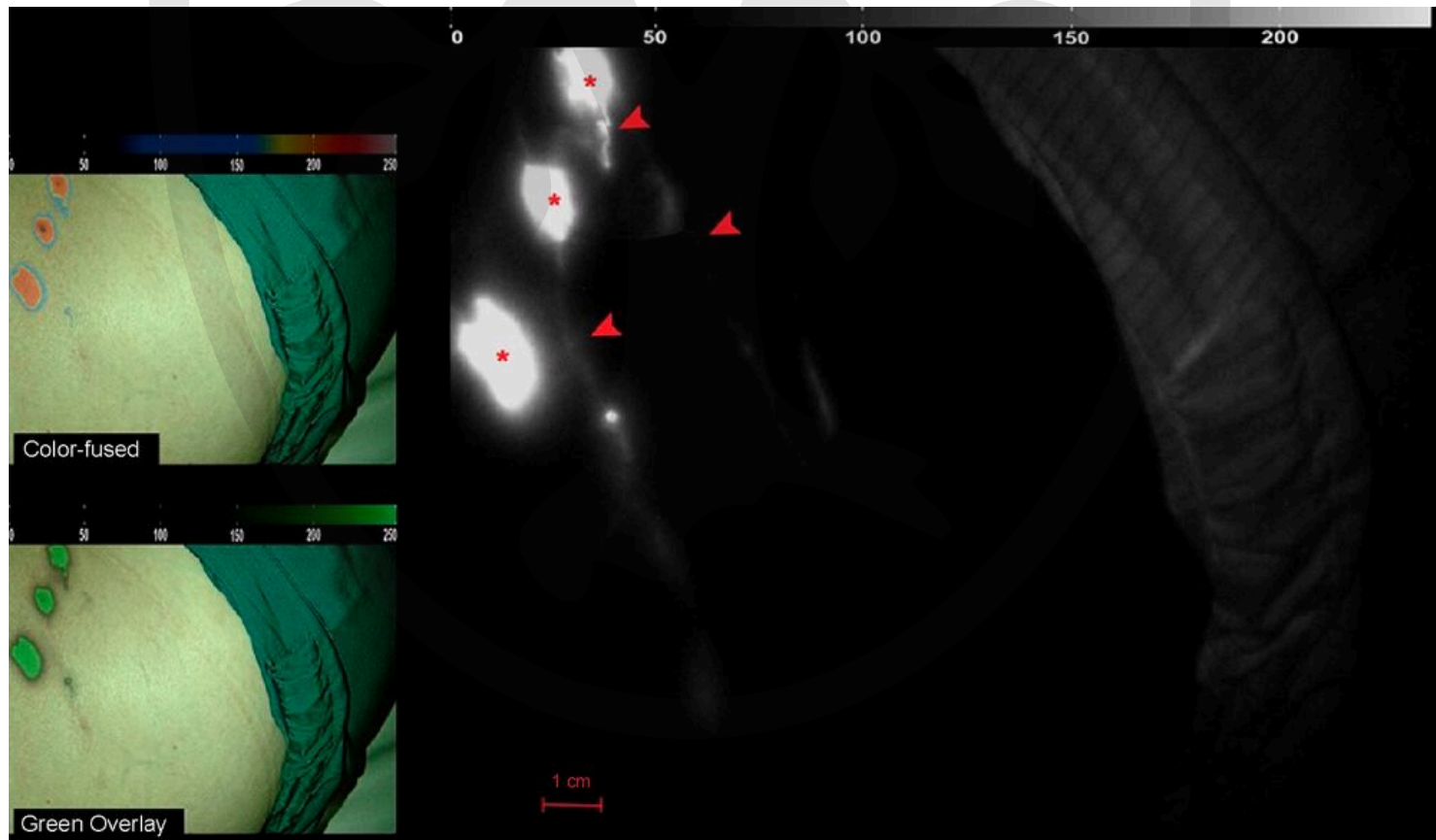
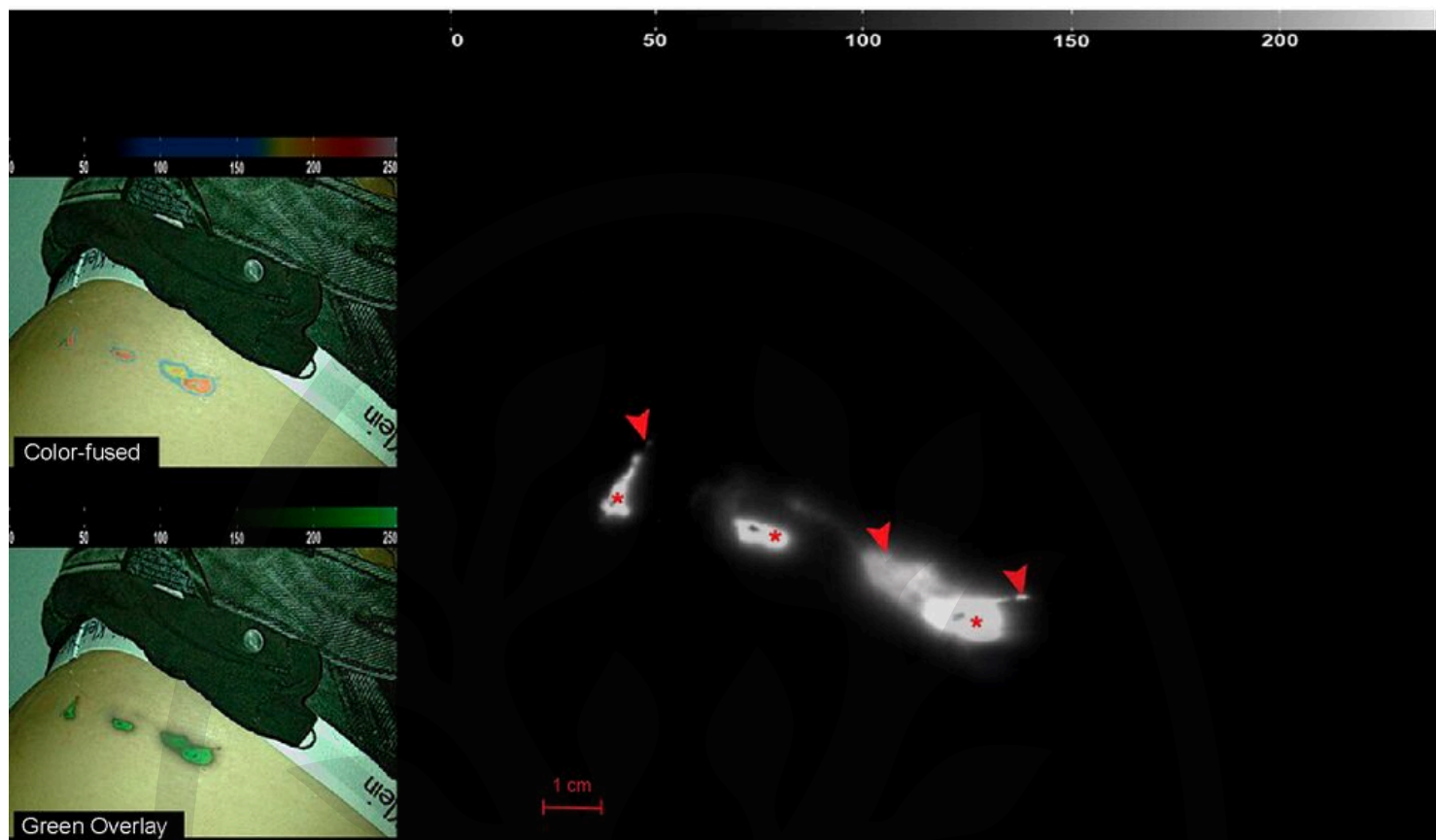
**Table 2.** Summary of the results the SCIP flap zone on the left side

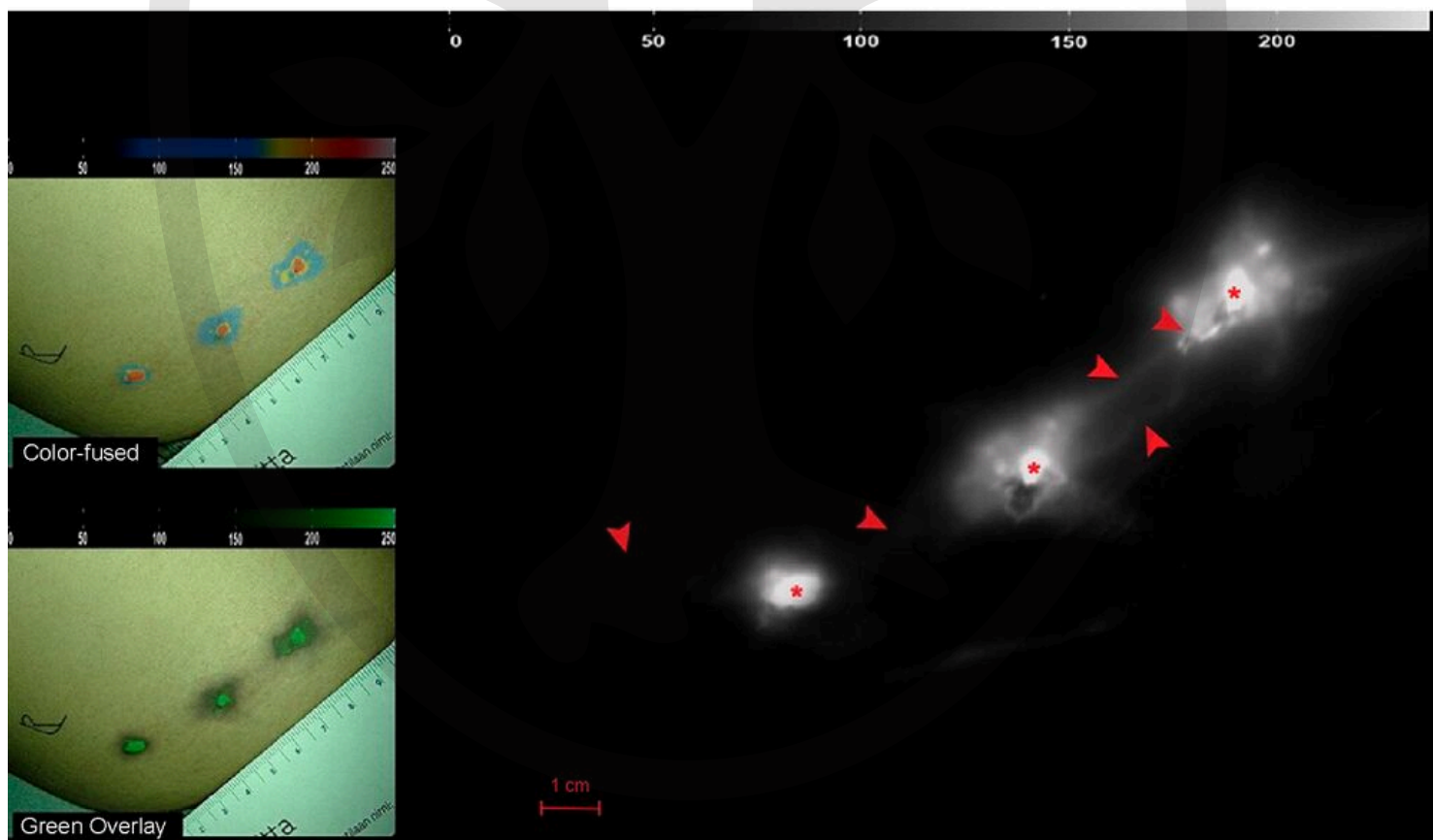

	<b>Linear pattern [no. volunteers (%)]</b>	<b>Median count of lymphatic vessels</b>	<b>Direction (no. volunteers [%])</b>	<b>Mean length</b>
<b>4 min</b>	11 (73.3%)	1	Toward ILN (86.7%)	2.9 cm
			Opposite to ILN (13.3%)	
<b>14 min</b>		1	Toward ILN (86.7%)	3.9 cm
			Opposite to ILN (13.3%)	
<b>24 min</b>		2	Toward ILN (86.7%)	5.5 cm

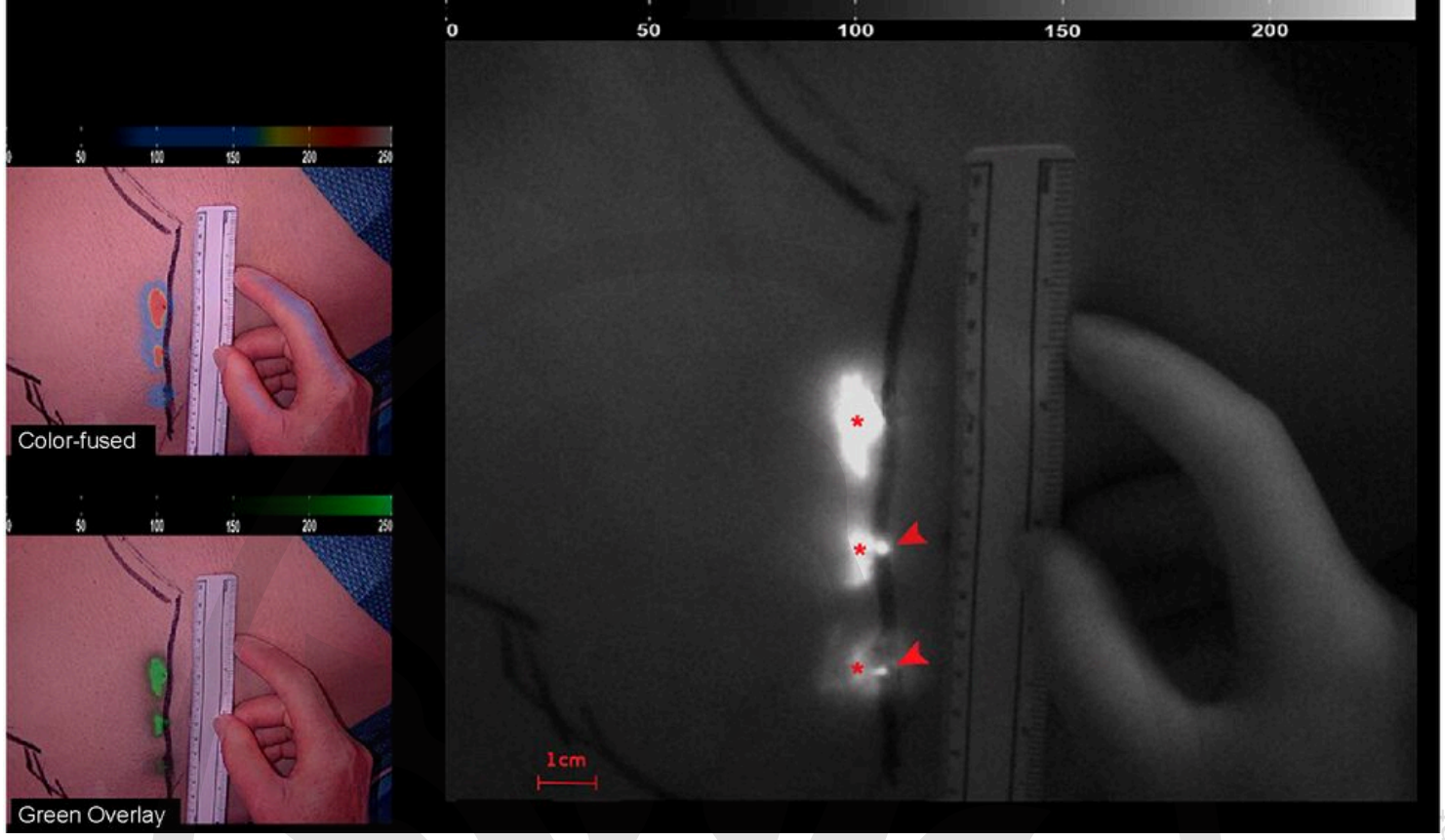
			Opposite to ILN (13.3%)	
--	--	--	-------------------------	--

SCIP, superficial circumflex iliac artery perforator. ILN, inguinal lymph node

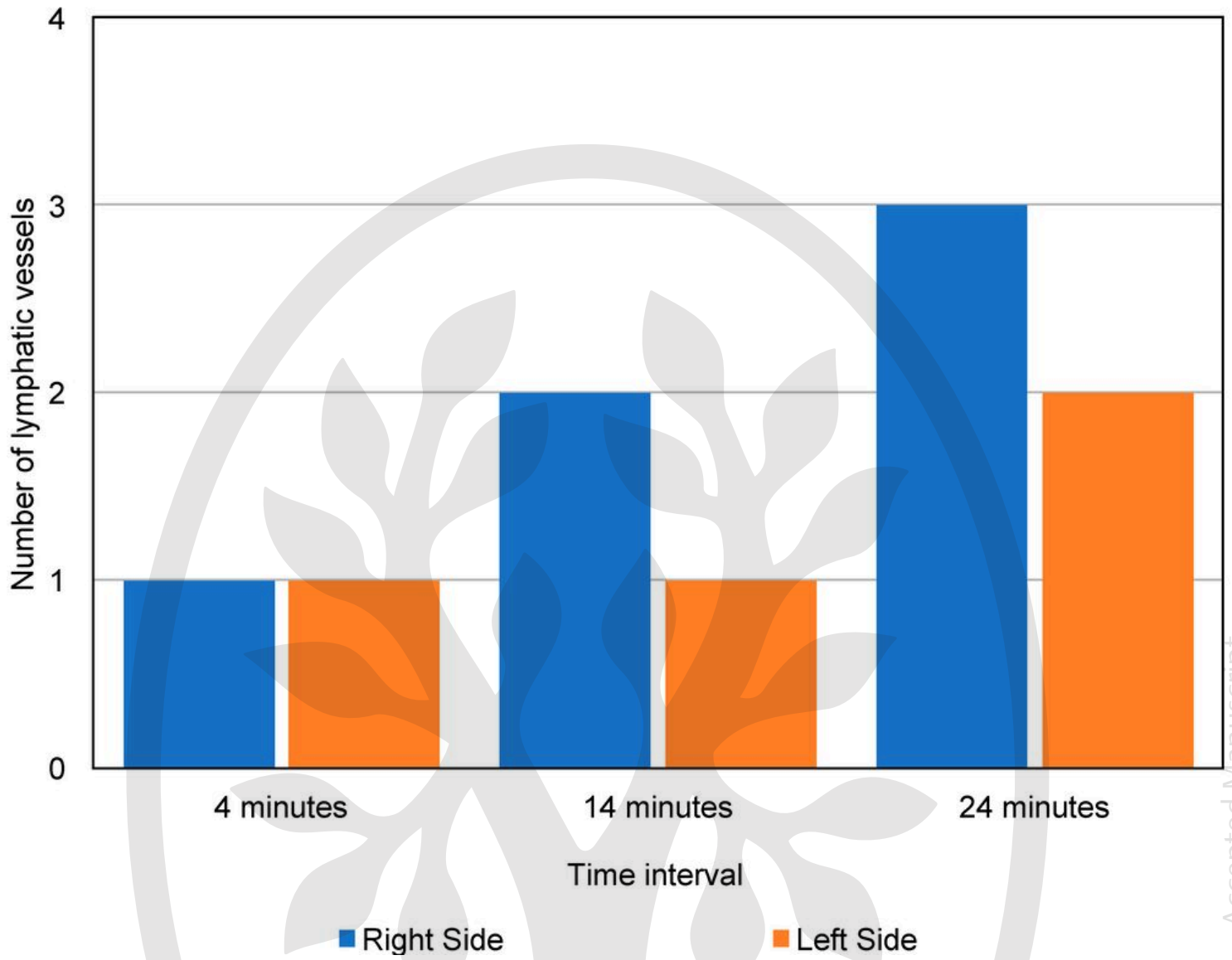


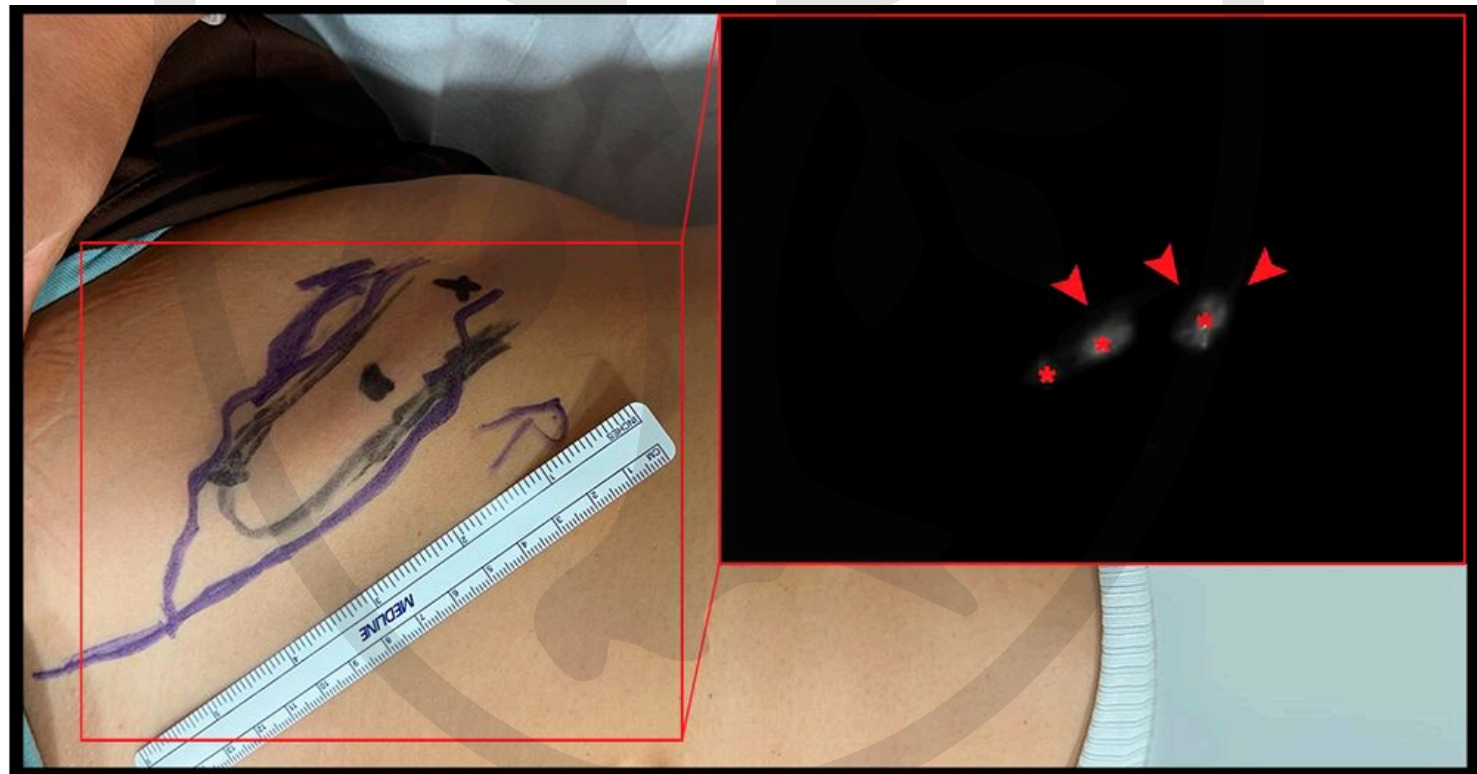




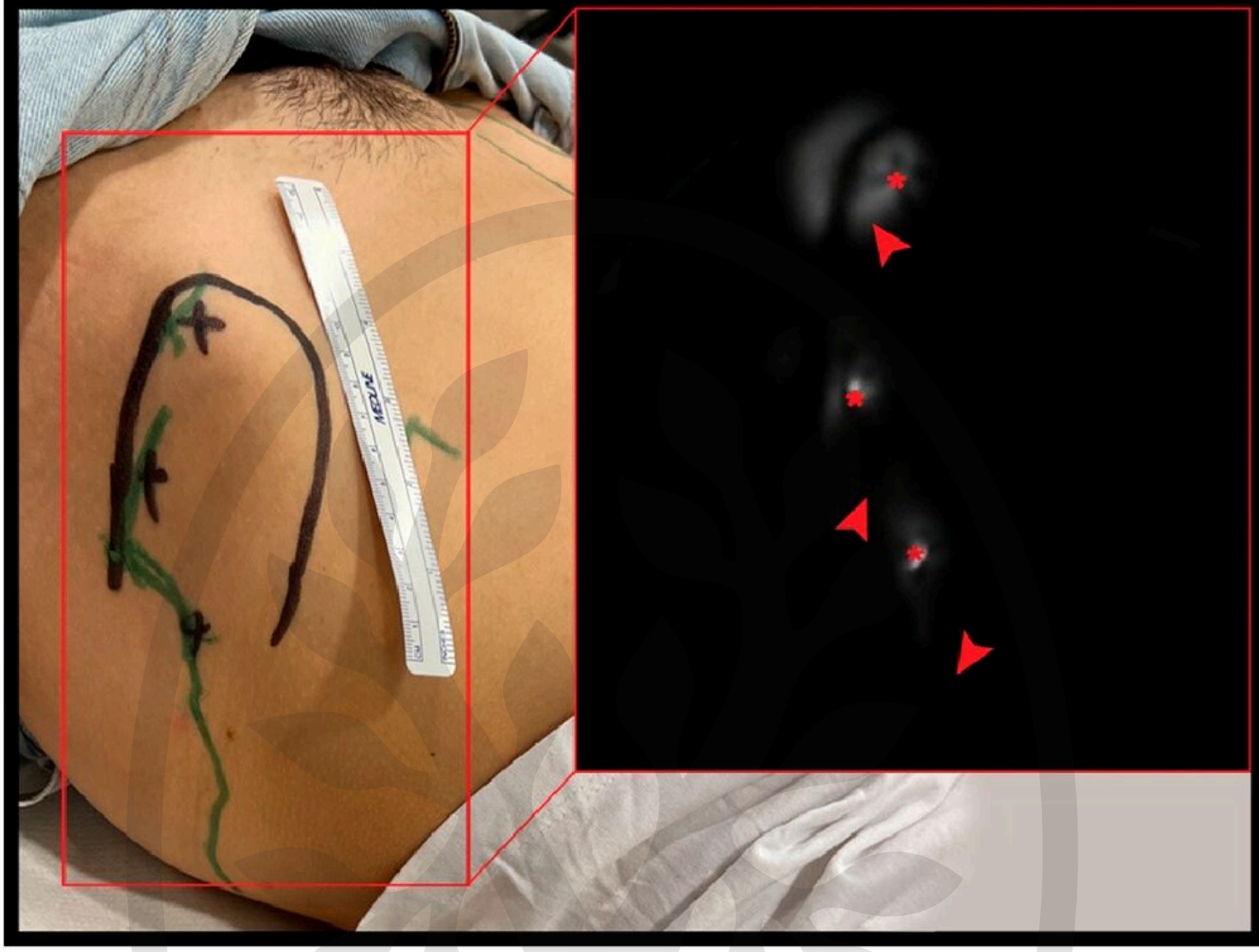

# Median Lymphatic Vessels Per Minute: Right and Left Sides









## Average Length Lymphatic Vessels: Right and Left Sides

