

Gastric variceal obstruction improves the efficacy of endoscopic management of esophageal variceal bleeding in GOV type I



Authors

Xiaoquan Huang^{1,2}, Detong Zou^{†3}, Huishan Wang¹, Wei Chen⁴, Lili Zhang³, Feng Li¹, Lili Ma⁵, Chunqing Zhang⁶, Ying Chen⁴, Shiyao Chen^{1,2,5}

Institutions

- 1 Department of Gastroenterology and Hepatology, Zhongshan Hospital, Fudan University, Shanghai, P.R. China
- 2 Center of Evidence-Based Medicine, Fudan University
- 3 Department of Gastroenterology, Xinghua Renming Hospital, Jiangsu, P.R. China
- 4 Department of Gastroenterology and Hepatology, Minhang Hospital, Fudan University, Shanghai, P.R. China
- 5 Endoscopy Center and Endoscopy Research Institute, Zhongshan Hospital, Fudan University, Shanghai, P.R. China
- 6 Department of Gastroenterology, Shandong Provincial Hospital Affiliated to Shandong First Medical University, Jinan, Shandong, P.R. China

Key words

Endoscopy Upper GI Tract, Portal hypertension and variceal bleeding, Dilatation, injection, stenting, Quality and logistical aspects, Performance and complications

received 2.1.2024

accepted after revision 27.6.2024

Bibliography

Endosc Int Open 2024; 12: E940–E946

DOI 10.1055/a-2360-4490

ISSN 2364-3722

© 2024. The Author(s).

This is an open access article published by Thieme under the terms of the Creative Commons Attribution-NonDerivative-NonCommercial License, permitting copying and reproduction so long as the original work is given appropriate credit. Contents may not be used for commercial purposes, or adapted, remixed, transformed or built upon. (<https://creativecommons.org/licenses/by-nc-nd/4.0/>)

Georg Thieme Verlag KG, Rüdigerstraße 14,
70469 Stuttgart, Germany

Corresponding authors

Ying Chen, Department of Gastroenterology and Hepatology, Minhang Hospital, Fudan University, No.170, XinSong Road, 201199 Shanghai, P.R. China

chenying_1120@fudan.edu.cn

Dr. Shiyao Chen, Department of Gastroenterology and Hepatology, Endoscopy Center and Endoscopy Research Institute, Zhongshan Hospital, Fudan University, 180 Fenglin Road, 200032 Shanghai, P.R. China
chen.shiyao@zs-hospital.sh.cn

ABSTRACT

Background and study aims Limited data exist regarding endoscopic obstruction of type I gastroesophageal (GOV I) in managing bleeding from esophageal varices. In this multicenter retrospective cohort study, we aimed to access the efficacy of blocking gastric varices in management of bleeding from esophageal varices in patients with GOV1.

Patients and methods Cirrhotic patients experiencing bleeding from esophageal varices and having GOV I gastric varices in four centers were screened. All included patients were followed up for 180 days, or until death.

Results A total of 93 cirrhotic patients with GOV I and bleeding esophageal varices were included. Among them, 58 patients underwent endoscopic cyanoacrylate injection (ECI) for gastric varices in addition to treatment for esophageal varices (EV), while the remaining 35 patients received treatment for EV only. Kaplan-Meier analysis demonstrated that the cumulative 180-day rebleeding rate was significantly lower in the ECI plus EV treatment group (7.9%) compared with the EV treatment group (30.7%) ($P=0.0031$). The cumulative incidence of 180-day mortality was 1.9% in the ECI plus EV treatment group and 23.9% in the EV treatment group ($P=0.0010$). Multivariable Cox regression analysis revealed that concomitant ECI treatment was an independent protective factor against 180-day rebleeding and overall mortality.

† These authors contributed equally.

Conclusions In conclusion, obstruction of gastric varices in addition to endoscopic treatment for bleeding from esophageal varices in patients with GOV 1 proved superior

to endoscopic treatment alone for esophageal variceal bleeding.

Introduction

Portal hypertension is a significant outcome of cirrhosis, and its most critical complication is acute gastroesophageal varices (GV) bleeding. It is linked with increased mortality, which remains approximately 20% at 6 weeks despite recent advancements in management [1]. Gastric and esophageal varices are present in up to 20% of portal hypertension patients, with 65% of them experiencing rebleeding within 2 years [2]. GV are categorized based on their location in the stomach and their relationship to esophageal varices (EV), as previously described [3]. They are classified into different types: Type 1 GV (GOV I) emerge as extensions of EV and run along the lesser curve of the stomach; Type 2 GOVs (GOV2) extend beyond the gastroesophageal junction into the fundus of the stomach; and isolated GV (IGV) [3].

Although GOV1 is the most prevalent type of GV, controversies persist regarding its optimal treatment. The Baveno VII consensus has endorsed endoscopic variceal ligation (EVL) as the primary therapy for EV bleeding, while endoscopic cyanoacrylate injection is commonly employed to eliminate GV [4]. The European Society of Gastrointestinal Endoscopy Guideline (ESGE) suggests EVL for treating acute EV hemorrhage, and either endoscopic cyanoacrylate injection (ECI) or EVL for GOV1-specific bleeding [5]. However, some experts propose treating GOV1 similarly to EV because varices along the lesser curvature share a similar natural history [6,7]. Thus, data about endoscopic obstruction of GV in GOV1 patients with EV bleeding are limited. The efficacy of EVL for esophageal varices combined with cyanoacrylate injection for GV in GOV1 appears promising.

In this multicenter retrospective cohort study, we aimed to assess the effectiveness of ECI in addition to managing EV bleeding in GOV1 patients compared with treatment for EV alone.

Patients and methods

Study design and patient population

Cirrhotic patients experiencing EV bleeding, confirmed by endoscopy and receiving endoscopic treatment for rebleeding prevention between February 1, 2017 and July 31, 2021 were screened at four medical centers (Zhongshan Hospital of Fudan University, Shandong Provincial Hospital, Minhang Hospital of Fudan University, and Xinghua Renming Hospital). Active bleeding was defined as admission with melena/hematemesis and a hemoglobin drop of ≥ 2 mg/dL within 24 hours. Patients were included if they were confirmed to have GOV I and excluded if they had active gastric bleeding or were GOV II or only had EV. The protocol was approved by the Medical Ethics Commit-

tee of Zhongshan Hospital, Fudan University (B2022-110), in accordance with the Declaration of Helsinki.

Endoscopic treatment

All patients included in the study underwent endoscopy, confirming active bleeding from EV or presence of an esophageal thrombus. Treatment for EV was defined as receiving only endoscopic interventions for EV, which could include ligation, ECI, or a combination of both. The treatment modalities for EV encompassed EVL and/or endoscopic injection of cyanoacrylate and laurumacrogol. Six multi-band ligators (Cook Endoscopy, Winston-Salem, North Carolina, United States) or Ligatures Endoscopic Loop (Health Microport Medical Device Co., Ltd., Changzhou, China) were utilized. *N*-butyl-cyanoacrylate (COMPONT, Beijing, China) and laurumacrogol (Tianyu, Shanxi, China) were injected directly near the bleeding site in the esophagus. ECI for GV involved use of *N*-butyl-cyanoacrylate employing the sandwich method (laurumacrogol–cyanoacrylate–laurumacrogol) as previously described [8]. Intravascular multi-injection was performed in an attempt to completely obstruct the varices, as previously documented [9]. The endoscopist could choose EV treatment alone or ECI plus EV treatment according to the clinical situation. Typically, after successful control of active bleeding, ECI was performed, followed by management of EV. All endoscopic procedures were conducted by an experienced endoscopist who specialized in treating GV.

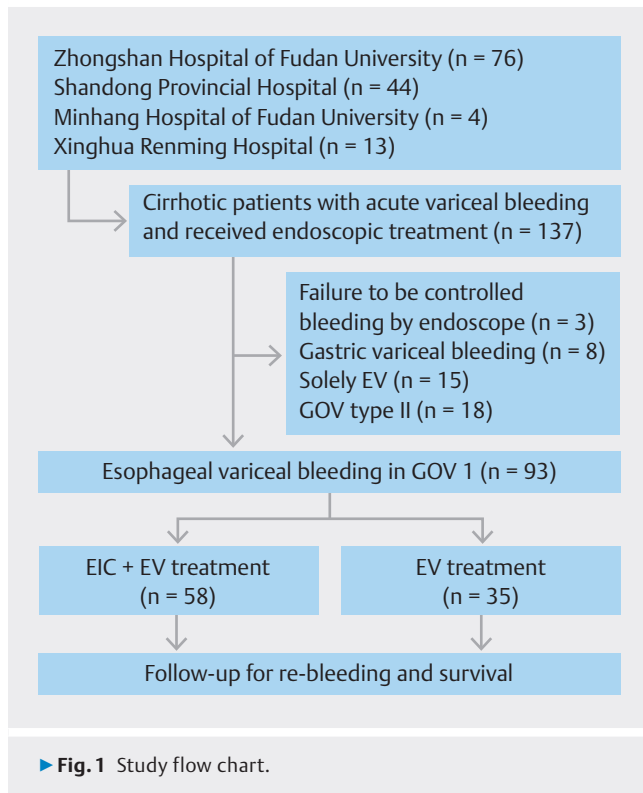
Defining variables and follow-up

Clinical and biochemical parameters obtained on the day of admission served as the baseline characteristics. All included patients underwent computer tomography angiography of the portal venous system upon admission before receiving endoscopic treatment.

All patients had follow-up every 2 to 3 months and received subsequent endoscopic treatment until GV were eradicated. Abdominal ultrasound was performed every 2 to 3 months during follow-up. Rebleeding was defined as any evidence of active bleeding (in the presence of melena/hematemesis and a hemoglobin drop of ≥ 2 mg/dL) after endoscopic treatment of variceal bleeding, as previously defined. All the included patients were followed up for 180 days, until death or liver transplantation.

Statistical analysis

Continuous variables were reported as mean \pm standard deviation for normally distributed values and as median with interquartile range (IQR) for values significantly deviating from the normal distribution. Categorical variables were presented as *n* (proportion) and tested using the chi-squared test. Student's unpaired *t* test evaluated normally distributed continuous vari-



ables while the Mann–Whitney *U* test was used for all other variables between two groups. The Levene’s test validated the equality of variances. Kaplan–Meier analysis and log-rank test visualized and compared rebleeding and overall mortality rates. Univariate Cox proportional hazard regression identified predictors of the 180-day rebleeding rate. Covariates with $P < 0.2$ were included simultaneously in the multivariable Cox proportional hazards regression. Statistical significance was analyzed using a two-tailed test, with $P < 0.05$ considered significant. Data were analyzed using STATA 16.0 (StataCorp Lp, Texas, United States).

Results

A total of 137 cirrhotic patients with acute variceal bleeding were identified from four centers. Among them, three patients failed to achieve gastrointestinal bleeding control with endoscopic treatment, eight had GV bleeding, 15 patients had solely EV, and 18 patients with GOV type II were excluded. Thus, 93 cirrhotic patients with GOV type I and EV bleeding were included in the analyses (► **Fig. 1**).

All included patients received endoscopic treatment to prevent variceal rebleeding. Among them, 58 patients received EIC for GV in addition to treatment for EV (EIC+EV treatment group), while the remaining 35 patients received only treatment for EV (EV treatment group). Both groups had similar baseline characteristics, including etiology of cirrhosis, major laboratory index and Child–Pugh grade (► **Table 1**).

► **Table 1** Baseline characteristics of patients with GOV1 and esophageal variceal bleeding.

	EIC + EV treatment group (n = 58)	EV treatment group (n = 35)	P value
Age	56 (47–63)	61 (53–70)	0.017
Sex (male/female)	39 (67.2%)/19 (32.8%)	21 (60.0%)/14 (40.0%)	0.480
Etiology of cirrhosis			0.208
▪ Hepatitis	34 (58.6%)	14 (56.0%)	
▪ Acholic	2 (3.5%)	4 (11.4%)	
▪ AIH	7 (12.1%)	4 (11.4%)	
▪ Others*	15 (25.9%)	13 (37.1%)	
Tumor†	10 (17.2%)	15 (42.9%)	0.007
Diabetes	12 (20.7%)	6 (17.1%)	0.675
Hypertension	9 (15.5%)	7 (20.0%)	0.579
PVT	18 (31.0%)	10 (28.6%)	0.802
Child grade (A/B/C)	14 (24.1%)/36 (62.1%)/8 (13.8%)	13 (37.1%)/17 (48.6%)/5 (14.3%)	0.373
Child–Pugh score	7.8±1.5	7.5±1.7	0.190
Ascites (absent/mild/moderate to severe)	13 (22.4%)/14 (24.1%)/31 (53.5%)	7 (20.0%)/12 (34.3%)/16 (45.7%)	0.571
Splenectomy	5 (8.6%)	3 (8.6%)	0.993
Hemoglobin (g/L)	76 (63–91)	82.0 (59.0–88.0)	0.902
Platelet (10 ⁹ /L)	66.5 (45–105)	87 (48–120)	0.279
White blood cell (10 ¹² /L)	4.06 (2.45–5.89)	4.34 (3.19–8.28)	0.545
Prothrombin time (s)	14.7 (13.5–16.1)	14.0 (12.9–15.8)	0.186
Albumin (g/L)	31.7 (28.2–36.6)	32.1 (28.8–40.4)	0.552
Creatine (μmol/L)	64.1 (54.1–75.7)	68.5 (59.1–79.0)	0.767

*Other etiologies included schistosomiasis, NASH, and cryptogenic cirrhosis.
†Tumors included hepatic cancer, colorectal cancer and breast cancer.

AIH, autoimmune hepatitis; EIC, endoscopic cyanoacrylate injection; EV, esophageal varices; GOV1, Type 1 gastroesophageal varices; PVT, portal vein thrombosis.

► **Table 2** Details of endoscopic treatment and follow-up.

	ECI + EV treatment (n = 58)	EV treatment (n = 35)	P value
Active bleeding	6 (10.3%)	7 (20.0%)	0.193
Bleeding/thrombus site from incisor teeth (cm)	32.3±3.4	32.0±3.9	0.697
EV treatment			0.120
▪ Sclerotherapy	9 (15.5%)	6 (17.1%)	
▪ EVL	34 (58.6%)	26 (74.3%)	
▪ Sclerotherapy + EVL	15 (25.9%)	3 (8.6%)	
Follow-up endoscopy			
▪ Esophageal scar	17 (44.7%)	11 (42.3%)	0.847
▪ Esophageal ulcer	2 (5.6%)	2 (9.1%)	0.606
▪ Esophageal stricture	0	0	–

ECI, endoscopic cyanoacrylate injection; EV, esophageal varices; EVL, esophageal varices ligation.

Details of endoscopic treatment

A total of 12 patients experienced active EV bleeding during endoscopic treatment. Most of the bleeding sites were located in the lower part of the esophagus. Regarding management of EV bleeding, 34 patients in the ECI + EV treatment group underwent EV banding, 15 received concomitant cyanoacrylate and lauromacrogol injection combined with banding, and nine received cyanoacrylate and lauromacrogol injection alone. In the EV treatment group, 26 patients underwent esophageal banding, three received concomitant cyanoacrylate and lauromacrogol injection combined with banding, and six received cyanoacrylate and lauromacrogol injection alone. Follow-up endoscopy revealed similar rates of esophageal ulceration and scarring between groups, and no strictures were identified (► **Table 2**).

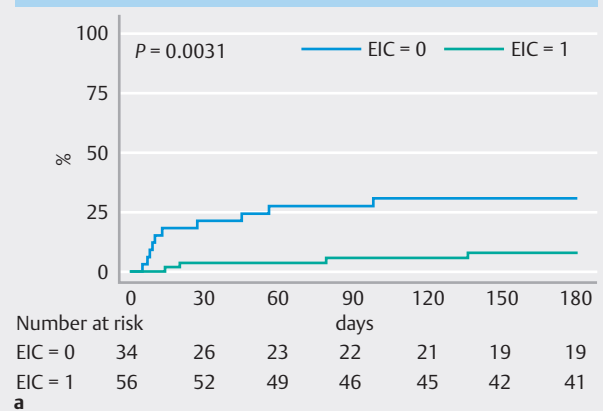
Rebleeding and overall mortality rate

The 180-day rebleeding and mortality rates were significantly higher in the EV treatment group compared with the ECI + EV treatment group. Kaplan-Meier analysis demonstrated that cumulative incidence of rebleeding was significantly lower in the ECI + EV treatment group (7.9%) than in the EV treatment group (30.7%) ($P = 0.0031$) (► **Fig. 2a**). In addition, the cumulative incidence of mortality was 1.9% in the ECI + EV treatment group and 23.9% in the EV treatment group ($P = 0.0010$) (► **Fig. 2b**).

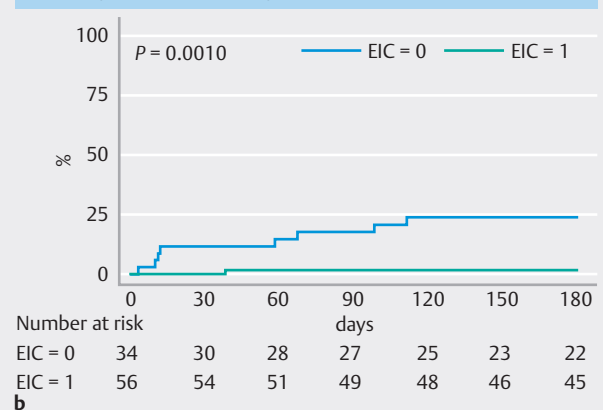
Multivariable Cox regression analysis of rebleeding and overall mortality

Given the differences in baseline characteristics between these two groups, multivariable Cox regression analysis was employed to identify risk factors for rebleeding and overall mortality during the 180 days following endoscopic treatment. The

180-day re-bleeding rate



180-day overall mortality rate



► **Fig. 2** Cumulative Incidence of rebleeding and mortality in the ECI + EV group vs. the EV Group. **a** Cumulative incidence of rebleeding at 180 days. **b** Overall mortality at 180 days. The number of patients at risk at different points in time are presented below the graph.

multivariable Cox regression analysis, considering age, malignant tumor, active bleeding, Child-Pugh score, concomitant ECI treatment, and EV treatment method, indicated that concomitant ECI treatment (hazard ratio [HR] 0.280, 95% confidence interval [CI] 0.083–0.944; $P = 0.040$) was an independent protective factor for 180-day rebleeding. For mortality, the multivariable Cox regression analysis showed that Child-Pugh score (HR 1.820, 95% CI 1.142–2.901; $P = 0.012$) was a risk factor, while concomitant ECI treatment (HR 0.056, 95% CI 0.007–0.479; $P = 0.008$) was an independent protective factor for 180-day overall mortality (► **Table 3**).

Discussion

Recent practice guidelines recommend EV ligation for treating bleeding from EVs, while ECI is recommended for treating bleeding from GOV2 or IGV1 [4]. Treatment of EV in GOV1 follows similar principles as EV, albeit with a risk of rebleeding. The optimal endoscopic treatment for GOV1 remains contro-

► **Table 3** Univariable and multivariable Cox proportional hazards regression analysis of 180-day rebleeding and mortality rates.

180-day rebleeding rate						
Variable	Univariate analysis			Multivariate analysis		
	HR	95% CI	P	HR	95% CI	P
Age	1.048	0.999–1.100	0.055	1.034	0.983–1.088	0.191
Malignant tumor	2.502	0.867–7.215	0.090	1.814	0.613–5.366	0.282
Active bleeding	1.927	0.537–6.909	0.314			
Child-Pugh score	1.1734	0.831–1.655	0.365			
Concomitant GV treatment	0.206	0.064–0.656	0.008	0.280	0.083–0.944	0.040
EV treatment method*	0.691	0.278–1.719	0.427			
180-day overall mortality rate						
Variable	Univariate analysis			Multivariate analysis		
	HR	95% CI	P	HR	95% CI	P
Age	1.012	0.955–1.072	0.689			
Malignant tumor	3.836	1.029–14.301	0.045	1.221	0.283–5.267	0.789
Active bleeding	3.118	0.780–12.470	0.108	1.619	0.370–7.089	0.523
Child-Pugh score	1.715	1.057–2.785	0.029	1.820	1.142–2.901	0.012
Concomitant GV treatment	0.0708	0.009–0.566	0.013	0.056	0.007–0.479	0.008
EV treatment method	0.618	0.199–1.913	0.404			

*EV treatment method included esophageal banding, concomitant cyanoacrylate and lauromacrogol injection and banding, and cyanoacrylate and lauromacrogol injection.
CI, confidence interval; EV, esophageal varices; GV, gastroesophageal varices; HR, hazard ratio.

versial. GOV1 represents an extension of EV and is also a supply vessel for EV. EV ligation is considered the standard treatment, with ECI and lauromacrogol reported in previous studies [10]. A prior study comparing ligation and ECI found that ligation was superior to cyanoacrylate injection in reducing the long-term rebleeding rate in GOV I [11]. In addition, EV obturation in patients with GV bleeding was found to be more effective in those with GOV I [12]. Large-volume band ligators have demonstrated similar efficacy and safety compared with cyanoacrylate injection for eradicating GV [13]. However, previous studies were conducted at single centers with relatively small sample sizes. The efficacy of combining ECI and ligation for GOV1 bleeding remains unclear. We hypothesized that obstruction of GV, the feeders of EV, might significantly reduce the rebleeding rate after endoscopic treatment to prevent EV rebleeding. In this study, we found that in addition to GV obstruction, the rebleeding rate significantly decreased after endoscopic treatment for prevention of EV rebleeding.

In this study, we included cirrhotic patients with GOV1 and acute EV bleeding who underwent endoscopic treatment. Our results indicate that GV obstruction in addition to EV treatment is superior to EV treatment alone in terms of overall rebleeding and mortality rates. The occurrence of esophageal ulceration and scarring was similar between groups, and no esophageal

strictures were observed in these patients. EV ligation, which involves ligating superficial varices to physically block blood flow, primarily acts locally. However, deeper varices may persist due to communicating or collateral veins, potentially leading to disease recurrence [14]. Endoscopic sclerotherapy, including injection of lauromacrogol and cyanoacrylate, involves intravenous injection of cyanoacrylate, which can eliminate paraesophageal varicose veins and communicating veins [15]. Park and colleagues enrolled 91 patients treated with EVL or obturation via cyanoacrylate injection for bleeding from GOV1. They demonstrated that the rebleeding rate was significantly higher ($P = 0.004$) and the rebleeding-free survival rate was significantly lower ($P = 0.001$) in the EV ligation group than in the EV obstruction group [16]. Another comparative study of tissue adhesive therapy versus band ligation for control of active bleeding from EV was conducted [11]. They noted that endoscopic hemostasis was achieved with both EVL in 182 patients (91.9%) and cyanoacrylate injection in 197 patients (97.05%) without significant differences ($P = 0.15$). Rebleeding occurred more frequently in the EV ligation group with 20 patients (10.1%) compared with 14 patients (6.9%) in the cyanoacrylate injection group ($P = 0.01$). Early 6-week mortality was higher among the EV ligation group (20.7%) compared with cyanoacrylate injection (17.2%) with no statistical significance ($P =$

0.3) [17]. A similar conclusion was drawn by Lo and colleagues [18]. We found that cyanoacrylate injection into the GV in GOV1 may help obstruct EV. Therefore, a combination of these two endoscopic treatments may be more effective than either as monotherapy. Because the superiority of combined therapy was indicated in our study, the role of cyanoacrylate injection should not be overlooked, at least in this specific subgroup of patients.

To minimize confounding factors affecting rebleeding and mortality rates in esophageal bleeding among GOV1-specific patients, multivariate analysis was conducted. After balancing the presence of malignant tumor, we observed that concomitant ECI treatment and Child-Pugh score were independent predictors for the 180-day overall mortality rate in these patients. In addition, in the multivariate analysis for rebleeding, concomitant ECI remained an independent predictor. Moreover, the methods of esophageal variceal treatment did not significantly affect rebleeding or overall mortality rates. These results suggest that cyanoacrylate injection into GV, combined with EV treatment, may reduce rebleeding and mortality rates in cirrhotic patients with GOV1 and EV bleeding.

Several limitations of our study should be acknowledged. Because it was retrospective, prospective studies with larger sample sizes and interventions are needed to confirm the effectiveness and safety of ECI for GV in managing esophageal bleeding in GOV1-specific patients. Second, long-term follow-up data are necessary to verify the efficacy of additional GV treatment. Third, the presence of tumors was significantly different between groups and multivariable regression analysis was used to minimize the effect of this confounder. Last, prospective studies are required to evaluate the optimal dosage and injection site for treating GV.

Conclusions

In conclusion, our findings suggest that adding ECI to management of EV bleeding in patients with GOV1 is superior to endoscopic treatment of EV bleeding alone.

Conflict of Interest

The authors declare that they have no conflict of interest.

Funding Information

the Shanghai Committee of Science and Technology 22Y11907400
the Natural Science Foundation of Shanghai 23ZR1410100
the Shanghai Minhang District Natural Science Foundation
2022MHZ028

Contributors' Statement

Shiyao Chen conceived the study. Xiaoquan HUANG and Detong Zou analyzed, interpreted the data, and drafted the manuscript. Huishan Wang, Wei Chen, Lili Zhang, Feng Li, Lili MA, Chunqing Zhang and Ying Chen undertook data collection, data analysis and revised the manuscript. Shiyao Chen and Ying Chen performed the critical revision of the manuscript. All authors were involved in critical revision of the manuscript for important intellectual content.

References

- [1] Ibrahim M, Mostafa I, Devière J. New developments in managing variceal bleeding. *Gastroenterology* 2018; 154: 1964–1969 doi:10.1053/j.gastro.2018.02.023
- [2] Tripathi D, Stanley AJ, Hayes PC et al. U.K. guidelines on the management of variceal haemorrhage in cirrhotic patients. *Gut* 2015; 64: 1680–1704 doi:10.1136/gutjnl-2015-309262
- [3] Sarin SK, Lahoti D, Saxena SP et al. Prevalence, classification and natural history of gastric varices: a long-term follow-up study in 568 portal hypertension patients. *Hepatology* 1992; 16: 1343–1349 doi:10.1002/hep.1840160607
- [4] de Franchis R, Bosch J, Garcia-Tsao G et al. Baveno VII – Renewing consensus in portal hypertension. *J Hepatol* 2022; 76: 959–974 doi:10.1016/j.jhep.2021.12.022
- [5] Gralnek IM, Camus Duboc M, Garcia-Pagan JC et al. Endoscopic diagnosis and management of esophagogastric variceal hemorrhage: European Society of Gastrointestinal Endoscopy (ESGE) Guideline. *Endoscopy* 2022; 54: 1094–1120
- [6] Garcia-Tsao G, Bosch J. Management of varices and variceal hemorrhage in cirrhosis. *N Engl J Med* 2010; 362: 823–832 doi:10.1056/NEJMra0901512
- [7] Kaplan DE, Bosch J, Ripoll C et al. AASLD practice guidance on risk stratification and management of portal hypertension and varices in cirrhosis. *Hepatology* 2024; 79: 1180–2011 doi:10.1097/HEP.0000000000000647
- [8] Zeng XQ, Ma LL, Tseng YJ et al. Endoscopic cyanoacrylate injection with or without laurmacrogol for gastric varices: A randomized pilot study. *J Gastroenterol Hepatol* 2017; 32: 631–638 doi:10.1111/jgh.13496
- [9] Huang X, Ma L, Zeng X et al. Endoscopic approaches to the treatment of variceal hemorrhage in hemodialysis-dependent patients. *Gastroenterol Res Pract* 2016; 2016: 9732039 doi:10.1155/2016/9732039
- [10] Metwally MA, El-Shewi ME, El-Ghaffar MMA et al. Prophylactic cyanoacrylate injection for gastric extension of esophageal varices: a randomized controlled trial. *Clin Exp Hepatol* 2022; 8: 84–91 doi:10.5114/ceh.2022.114271
- [11] Hong HJ, Jun CH, Lee du H et al. Comparison of endoscopic variceal ligation and endoscopic variceal obliteration in patients with GOV1 bleeding. *Chonnam Med J* 2013; 49: 14–19
- [12] Lee HA, Chang JM, Goh HG et al. Prognosis of patients with gastric variceal bleeding after endoscopic variceal obturation according to the type of varices. *Eur J Gastroenterol Hepatol* 2019; 31: 211–217
- [13] Shi D, Liu J. Comparing large-volume band ligators and cyanoacrylate injection for gastric variceal eradication: A prospective study. *Medicine (Baltimore)* 2022; 101: e31939 doi:10.1097/MD.00000000000031939
- [14] Lee EW, Shahrouki P, Alanis L et al. Management options for gastric variceal hemorrhage. *JAMA Surg* 2019; 154: 540–548 doi:10.1001/jamasurg.2019.0407

- [15] Luo X, Xiang T, Wu J et al. Endoscopic cyanoacrylate injection versus balloon-occluded retrograde transvenous obliteration for prevention of gastric variceal bleeding: A randomized controlled trial. *Hepatology* 2021; 74: 2074–2084 doi:10.1002/hep.31718
- [16] Park SJ, Kim YK, Seo YS et al. Cyanoacrylate injection versus band ligation for bleeding from cardiac varices along the lesser curvature of the stomach. *Clin Mol Hepatol* 2016; 22: 487–494
- [17] Naga M, Wahba M, Okasha H et al. Comparative study of tissue adhesive therapy versus band ligation in control of actively bleeding esophageal varices. *Acta Gastroenterol Belg* 2020; 83: 5–10
- [18] Lo GH, Lin CW, Perng DS et al. A retrospective comparative study of histoacryl injection and banding ligation in the treatment of acute type 1 gastric variceal hemorrhage. *Scand J Gastroenterol* 2013; 48: 1198–1204 doi:10.3109/00365521.2013.832792