

Self-assembling peptide improves the efficacy and safety of endoscopic band ligation for colonic diverticular bleeding ▶



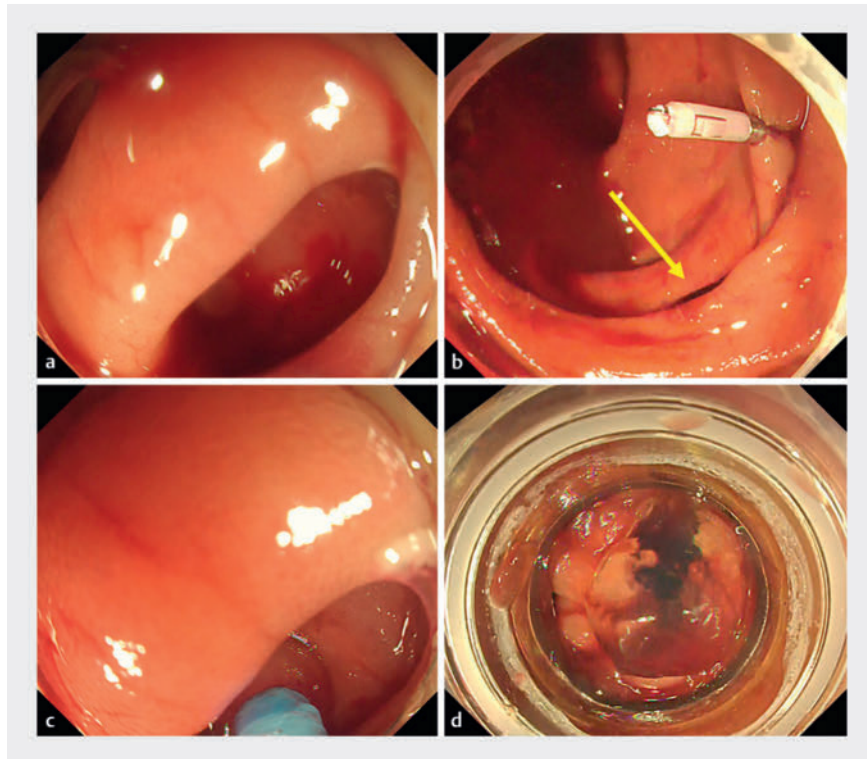
Introduction

Endoscopic band ligation (EBL) for colonic diverticular bleeding (CDB) is useful treatment, offering lower rebleeding rates, reduced need for interventional radiology, and shorter length of hospital stay, compared with clip therapy [1,2]. However, it requires some time to attach an EBL device after the bleeding source has been identified, which can cause problems with prolonged bleeding [1,2,3]. Furthermore, continuous bleeding can cause visibility to be impaired, and make it difficult to identify the bleeding source and potentially worsen the patient's condition.

Self-assembling peptide is indicated for hemostasis of oozing bleeding [4], but a case report exists of self-assembling peptide solution temporarily stopping spurting bleeding [5]. We considered that self-assembling peptide might help solve the problem.

Patient and methods

Our patient was an 80-year-old man who had several episodes of bloody stools. Owing to the progression of anemia and detection of diverticulosis of the ascending colon on computed tomography, he was suspected of having CDB and underwent an emergency colonoscopy. As shown in the video, we found continuous bleeding from a diverticulum in the patient's ascending colon, (▶**Fig. 1a**), which we marked by placing a clip (▶**Fig. 1b**). Subsequently, we used a dispersal tube to fill the diverticulum with 3 mL of self-assembling peptide ▶**Fig. 1c**). After primary hemostasis was obtained, we removed the endoscope, attached an EBL device, and reinserted the endoscope. On reinsertion, we found that hemostasis was maintained and it was easy to find the clip and the diverticulosis filled with self-assembling peptide (▶**Fig. 1d**), and complete hemostasis was obtained with EBL (▶**Video 1**).



▶ **Fig. 1** Images of colonic diverticular bleeding managed with the combination of a clip and self-assembling peptide. **a** Continuous bleeding from a diverticulum located in the ascending colon. **b** A marking clip is placed near the diverticulum (arrow). **c** The diverticulum is filled with 3 mL of self-assembling peptide. **d** The diverticulosis filled with self-assembling peptide.

During and after the treatment, there were no signs of rebleeding and the patient required no other treatment.

Conclusions

Self-assembling peptide can provide primary hemostasis, which makes it easier to identify the diverticulum before proceeding to EBL, and keep patients' conditions stable. In other word, self-assembling peptide improves the efficacy of EBL while causing minimal changes in vital signs and increasing the safety of the procedure.

Conflict of Interest

The authors declare that they have no conflict of interest.

VIDEO

Endoscopy International Open

VidEIO

Thieme

► **Video 1** Self-assembling peptide improves the efficacy and safety of endoscopic band ligation for colonic diverticular bleeding.

Bibliography

Endosc Int Open 2024; : –

DOI 10.1055/a-2387-1845

ISSN 2364-3722

© 2024. The Author(s).

This is an open access article published by Thieme under the terms of the Creative Commons Attribution-NonDerivative-NonCommercial License, permitting copying and reproduction so long as the original work is given appropriate credit.

Contents may not be used for commercial purposes, or adapted, remixed, transformed or built upon. (<https://creativecommons.org/licenses/by-nc-nd/4.0/>)

Georg Thieme Verlag KG, Rüdigerstraße 14, 70469 Stuttgart, Germany



The authors

Yuki Takeuchi^{1,2}, **Koichi Miyahara**², **Daisuke Yamaguchi**³, **Moeko Shirozu**⁴, **Ryuma Morita**⁵, **Kenichiro Nakayama**², **Takahiro Noda**²

- 1 Gastroenterology, Takagi Hospital, Okawa, Japan
- 2 Gastroenterology, Karatsu Red Cross Hospital, Karatsu, Japan
- 3 Endoscopy and Endoscopic Surgery, Saga University Hospital, Saga, Japan
- 4 Gastroenterology, Saga University Hospital, Saga, Japan
- 5 Gastroenterology, Saga Prefecture Medical Center Koseikan, Saga, Japan

Corresponding author

Dr. Yuki Takeuchi

Takagi Hospital, Gastroenterology, Okawa, Japan
snjgw899@yahoo.co.jp

References

- [1] Kobayashi K, Nagata N, Furumoto Y et al. Effectiveness and adverse events of endoscopic clipping versus band ligation for colonic diverticular hemorrhage: a large-scale multicenter cohort study. *Endoscopy* 2022; 54: 1160–1161 doi:10.1055/a-1705-092134820792
- [2] Setoyama T, Ishii N, Fujita Y. Endoscopic band ligation (EBL) is superior to endoscopic clipping for the treatment of colonic diverticular hemorrhage. *Surg Endosc* 2011; 25: 3574–3578 doi:10.1007/s00464-011-1760-821638178
- [3] Ishii N, Setoyama T, Deshpande GA et al. Endoscopic band ligation for colonic diverticular hemorrhage. *Gastrointest Endosc* 2012; 75: 382–387 doi:10.1016/j.gie.2011.07.03021944311
- [4] Fedrica B, Rolf K-N, Kristina F et al. PuraStat in gastrointestinal bleeding: results of a prospective multicentre observational pilot study. *Surg Endosc* 2022; 36: 2954–2961
- [5] Yamaguchi D, Ishida S, Nomura T et al. Endoscopic hemostasis of spurting colonic diverticular bleeding using the combination of self-assembling peptide solution and endoscopic band ligation. *Endoscopy* 2023; 55: E418–E419 doi:10.1055/a-2008-059936758630