

# Contrast-enhanced endoscopic ultrasound for differential diagnosis of autoimmune pancreatitis: a meta-analysis



## Authors

Shanshan Zhu<sup>1</sup>, Xinguang Cao<sup>1</sup>, Ghulam Nabi<sup>2</sup>, Fangbin Zhang<sup>1</sup>, Ping Liu<sup>1</sup>, Jingwen Zhang<sup>1</sup>, Changqing Guo<sup>1</sup>

## Institutions

- 1 Department of Gastroenterology, The First Affiliated Hospital of Zhengzhou University, Zhengzhou, China
- 2 Endocrinology and Physiology, Institute of Nature Conservation PAS, Krakow, Poland

## Key words

Pancreatobiliary (ERCP/PTCD), Pancreatoscopy, Endoscopic ultrasonography

received 10.9.2023

accepted after revision 25.4.2024

## Bibliography

Endosc Int Open 2024; 12: E1134–E1142

DOI 10.1055/a-2409-5519

ISSN 2364-3722

© 2024. The Author(s).

This is an open access article published by Thieme under the terms of the Creative Commons Attribution-NonDerivative-NonCommercial License, permitting copying and reproduction so long as the original work is given appropriate credit. Contents may not be used for commercial purposes, or adapted, remixed, transformed or built upon. (<https://creativecommons.org/licenses/by-nc-nd/4.0/>)

Georg Thieme Verlag KG, Rüdigerstraße 14,  
70469 Stuttgart, Germany

## Corresponding author

Dr. Changqing Guo, The First Affiliated Hospital of Zhengzhou University, Department of Gastroenterology, Zhengzhou, China  
1807872771@qq.com

Supplementary Material is available at  
<https://doi.org/10.1055/a-2409-5519>

## ABSTRACT

**Background and study aims** To assess the diagnostic value of contrast-enhanced endoscopic ultrasound (CE-EUS) for autoimmune pancreatitis and other solid pancreatic masses.

**Patients and methods** A systematic search of PubMed, Embase, and Web of Science was performed from inception to October 2022. We calculated individual and pooled sensitivities and specificities to determine the diagnostic ability of CE-EUS. In addition, we calculated  $I_2$  to test for heterogeneity and explored the source of heterogeneity by meta-regression analysis.

**Results** A total of 472 patients from seven eligible studies were included. The mean sensitivity and specificity of the Bivariate analysis were 0.84 (95% CI 0.71–0.92) and 0.95 (95% CI 0.84–0.99), respectively. The diagnostic advantage ratio was 107.91 (95% confidence interval [CI] 22.22–524.13), and the area under the summary receiver operating characteristics curve was 0.91 (95% CI 0.88–0.93). The overall heterogeneity of the studies is negligible ( $I^2=0$ , 95% CI 0–100). However, notable heterogeneity was observed in the combined specificity ( $P<0.01$ ,  $I^2=74.82$ ) and diagnostic odds ratio ( $P=0.05$ ,  $I^2=51.54$ ). The heterogeneity in these aspects could be elucidated through sensitivity analysis.

**Conclusions** Our analysis showed that CE-EUS is useful in identifying autoimmune pancreatitis. However, further large sample size, multicenter, prospective studies are needed to demonstrate its utility.

## Introduction

Autoimmune pancreatitis (AIP) is a specific type of chronic pancreatitis with nonspecific clinical features such as obstructive jaundice [1]. It is often confused with pancreatic cancer (PC) and may lead to unnecessary surgical treatment. AIP is also often confused with other solid pancreatic masses such as chronic pancreatitis and pancreatic neuroendocrine tumors. Although endoscopic ultrasound (EUS)-guided tissue acquisition can

help distinguish AIP from other solid pancreatic masses, the diagnostic yield is not satisfactory [2].

Contrast-enhanced EUS (CE-EUS) includes contrast-enhanced Doppler EUS (CD-EUS) and enhanced harmonic EUS (CEH-EUS) [3]. Doppler imaging with ultrasound contrast enhances the signal, resulting in a clear image of blood flow [4]. Contrast-enhanced harmonic EUS by IV infusion of ultrasound contrast allows visualization of the vascular system of the abdominal organs [5, 6, 7]. CEH-EUS allows capillary capture and

acquisition of parenchymal perfusion images and, therefore, can be used to differentiate AIP from other solid pancreatic masses [4]. Although a few relevant studies are available worldwide, their sample sizes are relatively small and no definite conclusion is drawn. Therefore, this study systematically evaluated the value of this technique for differential diagnosis of AIP and other solid pancreatic masses through meta-analysis to provide clinicians with more objective and systematic evidence-based medical evidence.

## Patients and methods

### Study design

We conducted a systematic literature search in accordance with the guidelines outlined in the PRISMA statement (Preferred Reporting Items for Systematic Reviews and Meta-Analyses), preferred reporting items for systematic reviews and meta-analyses. Throughout the process of study selection, we strictly adhered to the PRISMA checklist.

### Data sources and search strategies

This meta-analysis was registered on PROSPERO (CRD42022373780). We use the term ("Autoimmune pancreatitis" OR "AIP" OR "pancreatic cancer" OR "pancreatic mass" OR "pancreatic carcinoma" OR "pancreatic tumors ") AND ("contrast-enhanced" OR "echo enhanced" OR "contrast enhancement") AND ("Endosonography" OR "endoscopic ultrasonography" OR "endoscopic ultrasound" OR "EUS") as keywords. Two authors independently and systematically searched PubMed, Embase, and Web of Science between inception and October 2022 relevant English-language literature to assess the ability of contrast-enhanced ultrasound endoscopy to identify AIP.

### Selection criteria

Inclusion criteria: (1) CE-EUS is used for the differential diagnosis of AIP and other solid pancreatic masses, requiring clear criteria for distinction; (2) The search period ends on October 2022; (3) Direct extraction of 2×2 contingency table data from the literature or profile calculation available; (4) All lesions need to be diagnosed pathologically and have a clinical follow-up period of six months or more; (5) The language of the selected literature was English; and (6) There was no duplication of data in the selected literature. Exclusion criteria: (1) reviews, case reports, book reviews, correspondence; (2) data cannot be extracted from the literature in a 2×2 contingency table; (3) duplicate published data; (4) cases included without pathological, EUS-FNA or EUS-FNB confirmation; and (5) The number of cases was less than 20.

Secondary screening of the studies was conducted independently by two researchers and assessed jointly by a third researcher in case of disagreement. We used the Quality Assessment of Diagnostic Accuracy Studies-2 (QUADAS-2) tool to assess the quality of the studies [8]. The selected studies were extracted for the following characteristics: first author, year of publication, study region, study period, study design, the total number of patients, gender distribution, mean age, mass location, diagnostic criteria, type of contrast agent, contrast pat-

tern, imaging pattern, gold standard, and the 2×2 contingency table to differentiate AIP from other solid masses of the pancreas.

### Statistical methods

We tabulated true positives, false negatives, false positives, and true negatives (TP, FN, FP, and TN) for patients with AIP and stratified them according to the study. Sensitivity, specificity, positive likelihood ratio, negative likelihood ratio, diagnostic ratio, and the corresponding confidence interval (CI) were calculated from these figures, while summary receiver operating characteristics (SROC) curves were plotted. To synthesize the data, we used a bivariate mixed-effects regression model developed by Van Houwelingen for the meta-analysis of diagnostic tests [9, 10]. The model retains the two-dimensional nature of the study sensitivity and specificity data [11]. Based on the bivariate model, the sensitivity and specificity of each study were logit-transformed to conform to a normal distribution. Logit-transformed sensitivities, specificities, diagnostic advantage ratios, diagnostic scores, likelihood ratios and their standard errors, 95% CIs, and estimates of study variance were obtained.

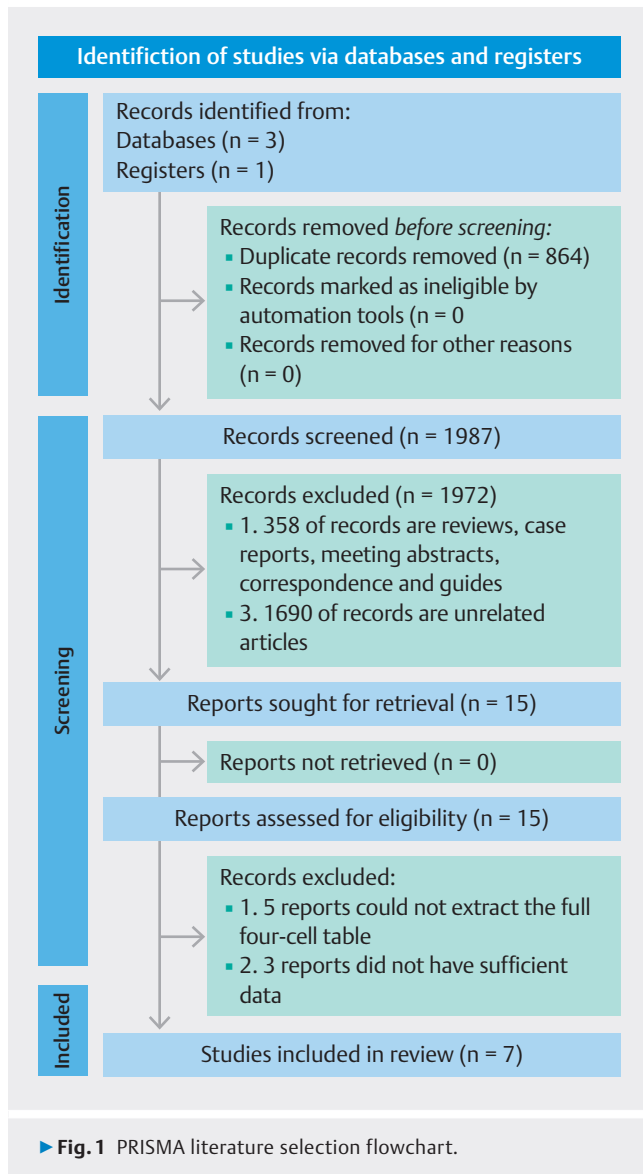
The heterogeneity of the studies was assessed using the Cochran Q test and the  $I^2$  statistic and the results were visually represented through a bivariate boxplot [12]. The  $I^2$  values, ranging from 0% to 100%, indicate the proportion of total variability attributed to heterogeneity. Higher  $I^2$  values suggest increased levels of heterogeneity, categorized into low, moderate, high, and very high levels. In our report, we provided specific  $I^2$  values along with their 95% CIs to reflect the uncertainty surrounding the estimates. If heterogeneity is present in the studies, the sources of heterogeneity will be investigated through subgroup analysis or sensitivity analysis.

We employed the MIDAS module in STATA version 14 for bivariate mixed-effects meta-regression analysis and visualization. Quality assessment was performed using Review Manager 5.4 software.

## Results

### Study selection and quality assessment

We initially included 2,851 articles. After initially removing duplicate studies, reviews, and irrelevant literature by reading the titles and abstracts, we excluded 2836 articles. Eight studies were excluded after a full-text review, leaving seven studies that met the requirements for inclusion in the study. The detailed selection process is shown in ► **Fig. 1** [13] and the key features are listed in ► **Table 1**. Two studies used CD-EUS [14, 15] and five studies used CEH-EUS [16, 17, 18, 19, 20]. Gold diagnostic criteria were based on pathology, histology, or follow-up. According to the QUADAS-2, most studies had a low risk of bias. However, two conference abstracts where the full 2×2 contingency table could be extracted were included. For information not mentioned in the conference proceedings, we selected the "unclear" option (► **Fig. 2**).



## Diagnostic value of CE-EUS

The combined sensitivity was 0.84 (95% CI 0.71–0.92), the combined specificity was 0.95 (95% CI 0.84–0.99) (► **Fig. 3**), and the diagnostic advantage ratio was 107.91 (95% CI 22.22–524.13) (► **Fig. 4**). The area under the subject's working characteristic curve was 0.91 (95% CI 0.88–0.93) (► **Fig. 5**). The positive likelihood ratio was 18.12 (95% CI 4.84–68.30) and the negative likelihood ratio was 0.17 (95% CI 0.09–0.32) (► **Fig. 6**). The Fagan plot showed a post-test probability of 95%, meaning that if the CE-EUS diagnosis was positive, the patient had a 95% probability of having AIP (► **Fig. 7**). The overall  $I^2$  for the bivariate model was 0 (**Fig. S1**), but there was heterogeneity in the combined specificity ( $P < 0.01$ ,  $I^2 = 74.82$ ) and diagnostic advantage ratio ( $P = 0.05$ ,  $I^2 = 51.54$ ). The small number of studies ( $< 10$ ) made it difficult to plot funnel plots and reveal publication bias [21]. However, we minimized publication bias by searching controlled registration databases like PubMed, Em-

base, and Web of Science exhaustively with references to relevant issues.

## Meta-regression and sensitivity analysis

Through an analysis of the included studies, we observed that the heterogeneity in combined specificity and diagnostic odds ratio may arise from the types of diseases used for distinguishing AIP in the studies. Consequently, we stratified the studies into two groups: differentiation between AIP and PC and differentiation between AIP and various solid pancreatic masses. To explore other potential sources of heterogeneity, we conducted a meta-regression analysis, examining patient numbers ( $> 60$  vs  $\leq 60$ ), comparison modes (harmonic vs. Doppler), imaging modes (qualitative vs. quantitative), and the types of diseases for differentiation (PC vs. various). The results indicated that the number of study cases and the diseases differentiated from AIP may be sources of heterogeneity ( $P < 0.05$ ) (► **Fig. 8**). However, recognizing the potential impact on result validity from the analysis method of excluding data to reduce heterogeneity, which could induce selection bias, we opted to exclude studies that differentiated AIP from various solid pancreatic masses. The sensitivity analysis after exclusion yielded results consistent with the primary findings, with a reduction in heterogeneity (► **Table 2**, **Fig. S2**, **Fig. S3**, **Fig. S4**).

## Diagnostic value of CE-EUS in differentiating AIP from PC

Drawing insights from the subgroup analysis results, we extracted data related to the differentiation between AIP and PC from the study conducted by Yamashita et al. Subsequently, we performed a bivariate mixed-effects meta-analysis, incorporating these data with findings from other studies. This approach aimed to explore the efficacy of contrast-enhanced endoscopic ultrasound (CE-EUS) in distinguishing AIP from PC when considering the impact of results not influenced by differentiation of AIP from other benign solid pancreatic masses.

The combined sensitivity was 0.84 (95% CI 0.71–0.92), the combined specificity was 0.94 (95% CI 0.91–0.96) (**Fig. S5**), and the diagnostic advantage ratio was 87.64 (95% CI 22.22–524.13) (**Fig. S6**). The area under the subject's working characteristic curve was 0.95 (95% CI 0.93–0.97) (**Fig. S7**). The positive likelihood ratio was 14.82 (95% CI 9.40–23.38), and the negative likelihood ratio was 0.17 (95% CI 0.09–0.32) (**Fig. S8**). The Fagan plot showed a post-test probability of 94%, meaning that if the CE-EUS diagnosis was positive, the patient had a 94% probability of having AIP (**Fig. S9**). The overall  $I^2$  for the bivariate model was 0 (**Fig. S10**), but there was heterogeneity in the diagnostic advantage ratio ( $P = 0.06$ ,  $I^2 = 50.42$ ).

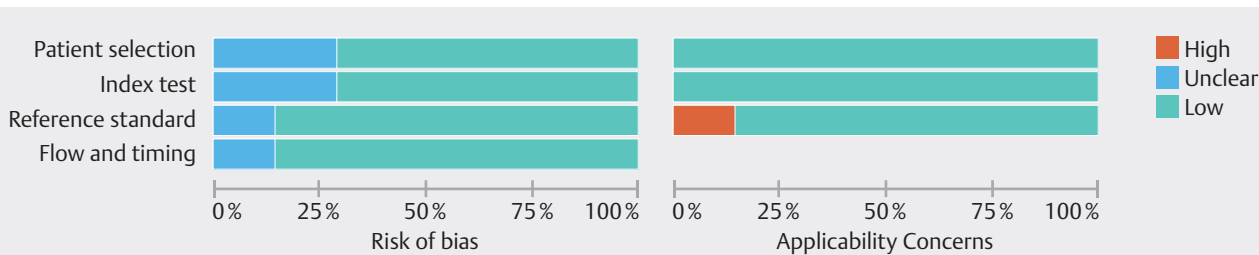
## Discussion

Although AIP with typical presentations such as diffuse pancreatic enlargement is easy to diagnose on computed tomography or magnetic resonance imaging, the differentiation of focal AIP (f-AIP) from other solid pancreatic masses has always been a challenge. However, differential diagnosis of AIP from other solid pancreatic masses, especially PC, is essential. The risk of

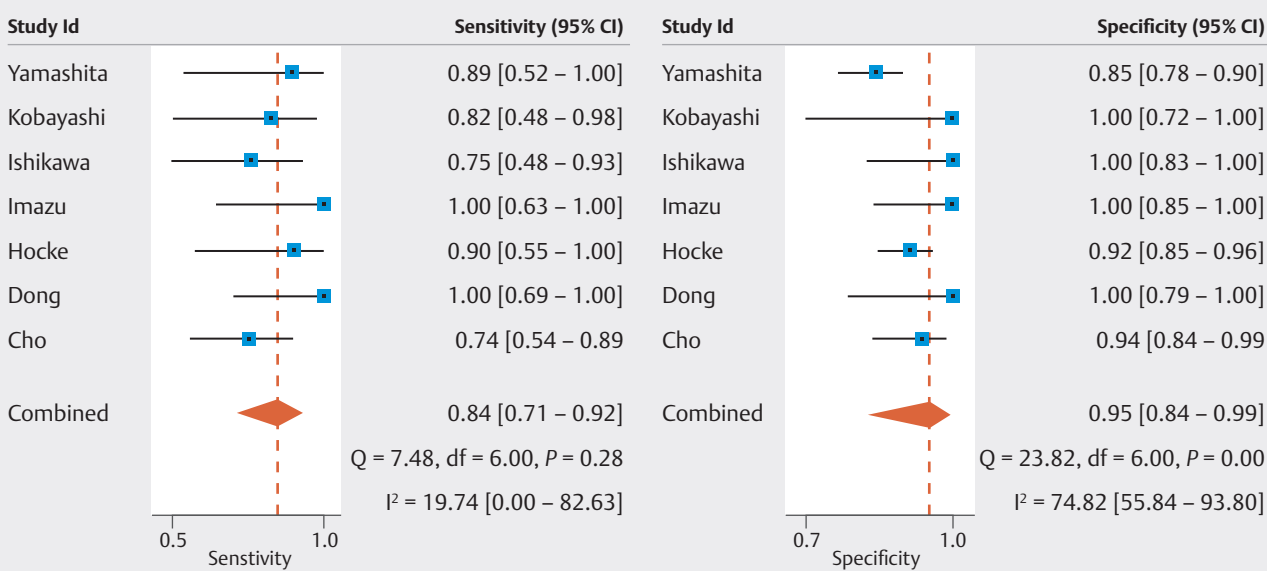
► **Table 1** Characteristics of selected studies.

Author/year/ country	Period/de- sign	TP	FP	FN	TN	No. pa- tients	Sex (M/F)	Age (mean, year)	Location (head/ body-tail)	Diagnostic standard	Contrast agent	Contrast mode	Imaging mode	Gold- standard
Cho 2018 Korea [16]	2014– 2015 Prospect- ive	20	3	7	50	80	46/34	60	40/40	Hyper- to iso- enhancement without irreg- ular internal vessels	Sono- Vue	Har- monic	Qualita- tive	ICDC
Dong 2018 China [17]	NA Retro- spective	10	0	0	16	26	NA	57.5	NA	Hyperen- hancement in the Arterial phase	Sono- Vue	Har- monic	Qualita- tive	Histol- ogy
Hocke 2011 Germany [14]	NA Retro- spective	9	10	1	111	131	127/77	62.1	NA	Net-like hy- pervasculari- zation pattern	Sono- Vue	Bicolor Dop- pler	Qualita- tive	Histol- ogy or cy- tology
Imazu 2012 Japan [18]	2009– 2010 Retro- spective	8	0	0	22	30	22/8	66.9	21/9	Maximum in- tensity gain cut-off = 12.5	Sona- zoid	Har- monic	Quanti- tative	JPS
Ishikawa 2009 Japan [19]	2003– 2008 Retro- spective	12	0	4	20	36	NA	NA	NA	Equal en- hancement ef- fect continued for 5 minutes	Sona- zoid	Har- monic	Quanti- tative	JPS
Kobayashi 2014 Japan [15]	NA	9	0	2	11	22	NA	NA	NA	Dendritic vas- cular pattern in the Eflow color mode	Sona- zoid	Color Dop- pler	Quanti- tative	Serolo- gy
Yamashita 2015 Japan [20]	2009– 2013 Retro- spective	8	21	1	118	147	92/55	69	NA	Isovascular pattern in late-phase im- age	Sona- zoid	Har- monic	Quanti- tative	ICDC

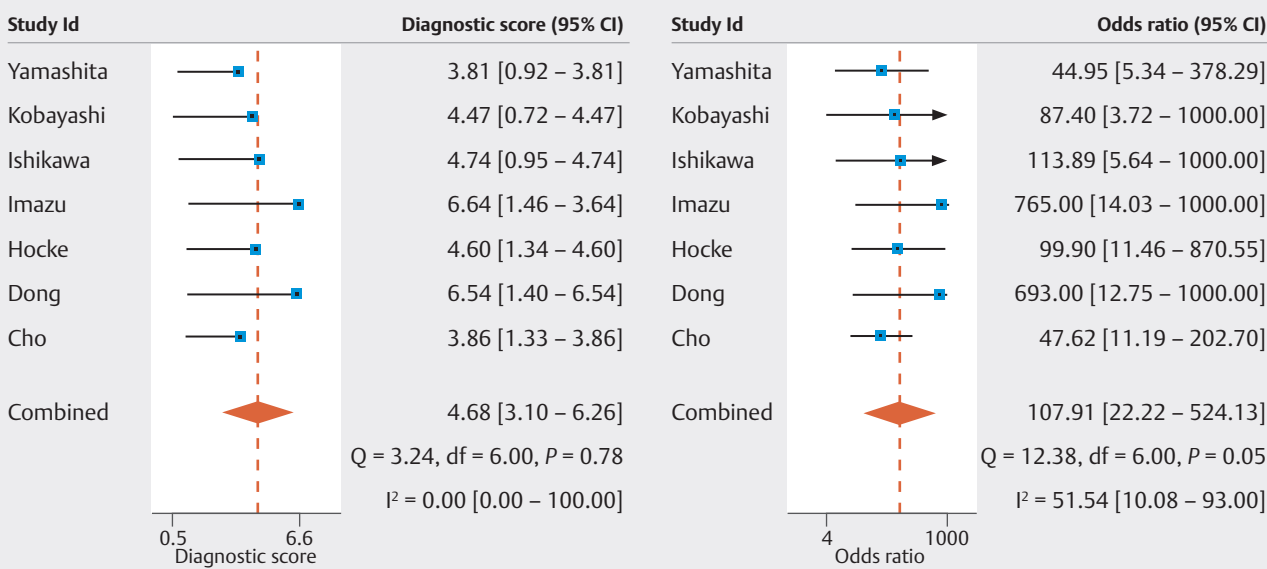
Diagnostic standard: Those meeting the diagnostic criteria are identified as AIP, while those not meeting the criteria are considered as having other diseases.  
TP, true positive; FP, false positive; FN, false negative; TN, true negative; ICDC, International Consensus Diagnostic Criteria; JPS, Japan Pancreas Society.



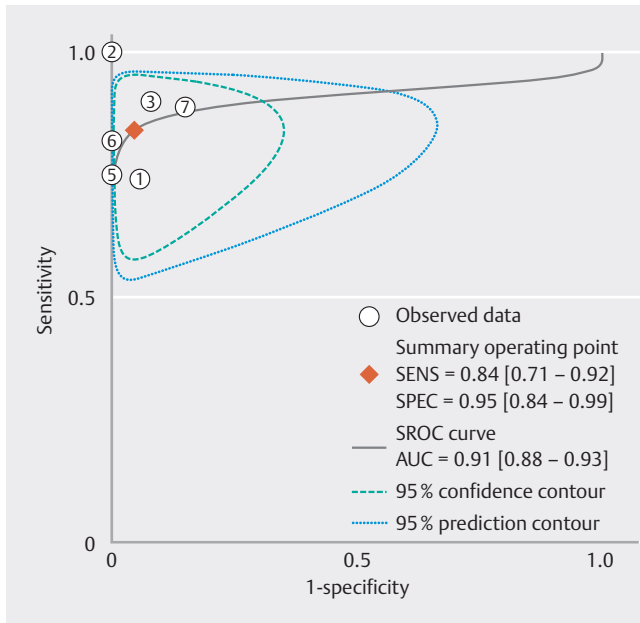
► Fig. 2 Quality assessment of included studies according to Diagnostic Accuracy Study Quality Assessment Criteria-2. Red indicates high risk of bias, yellow indicates unclear risk of bias, and green indicates low risk of bias.



► Fig. 3 Forest plot of pooled sensitivity and specificity for the diagnosis of AIP. It shows sensitivity with low heterogeneity between the combined measurements ( $I^2 = 19.74$ ) and specificity with high heterogeneity between the combined measurements ( $I^2 > 50\%$ ).



► Fig. 4 Forest plot of CE-EUS diagnostic advantage ratio and diagnostic score. Shows diagnostic scores for no heterogeneity ( $I^2 = 0$ ) and diagnostic dominance ratios for high heterogeneity ( $I^2 > 50\%$ ).

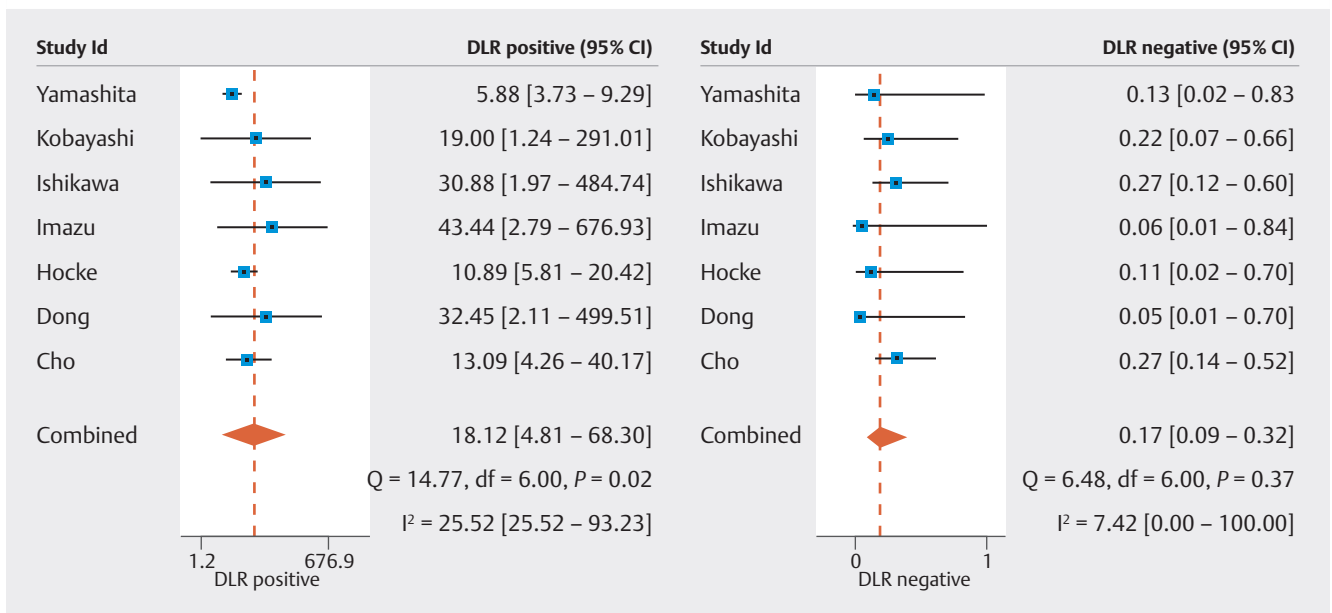


► **Fig. 5** The SROC curve used for the diagnostic accuracy of the CE-EUS. The AUC (area under curve) was 0.91.

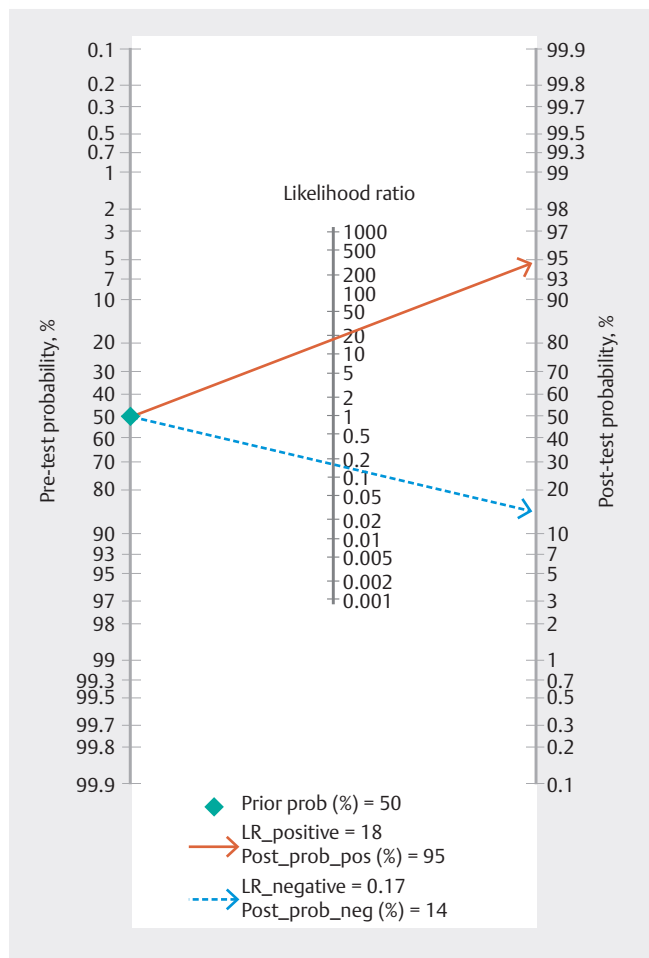
pancreatic surgery is high, yet the proportion of patients with AIP diagnosed as cancer and operated on for the wrong treatment is as high as 3% to 5% [22, 23, 24, 25, 26]. EUS-guided fine-needle aspiration (EUS-FNA) is often used to confirm the diagnosis and exclude PC, but its diagnostic effect on AIP is inadequate [27]. In a previous meta-analysis, the overall diagnostic accuracy of EUS tissue collection (EUS-TA) was 54.7% and EUS-guided needle aspiration biopsy (EUS-FNB) was superior to EUS-FNA (63% and 45.7% respectively), but the diagnostic results were still unsatisfactory [2]. Moreover, EUS-TA is inva-

sive and may have sequelae such as bleeding, mild pancreatitis, and abdominal pain [28]. We searched for alternative ways to differentially diagnose AIP and found CE-EUS to be highly diagnostic and a noninvasive test. Therefore, in this study, we collected clinical evidence on the differential diagnosis of AIP and investigated the usefulness of CE-EUS as an effective tool for differential diagnosis of AIP and to avoid unnecessary treatment of AIP.

CE-EUS is a new EUS technique based on EUS combined with contrast-enhanced techniques to show pancreatic parenchymal perfusion and microvasculature, which is significant for differential diagnosis of digestive diseases [5]. Sonazoid and SonoVue are commonly used as second-generation contrast agents. Sonazoid is well suited as a contrast agent for ultrasound medical imaging and was previously used for radiofrequency ablation of hepatocellular carcinoma [29, 30] and SonoVue is also highly used. Doppler imaging with ultrasound contrast agents can enhance the signal to produce clear blood flow images. eFLOW mode of Aloka- $\alpha$ 10, H-FLOW of Olympus ME2 and F-FLOW of Fujifilm also suppress artifacts and produce clearer blood flow images, making them suitable for contrast-enhanced color Doppler EUS (CC-EUS) [4]. CEH-EUS, performed by intravenous (IV) infusion of ultrasound contrast, allows visualization of the vascular system of abdominal organs [5, 6, 7]. Use of CE-EUS for scanning has more advantages over conventional imaging. Firstly, it helps to avoid interference of abdominal fat with other organs in the abdominal cavity. And the probe is closer to the pancreas, allowing clear visualization of pancreatic masses <2 cm in diameter. In addition, CE-EUS is a relatively noninvasive test that avoids adverse events such as bleeding, infection, mild pancreatitis, and needle tract metastasis of cancerous foci caused by EUS-TA, and is not limited in cases where the patient has coagulation disorders or the mass is deep.

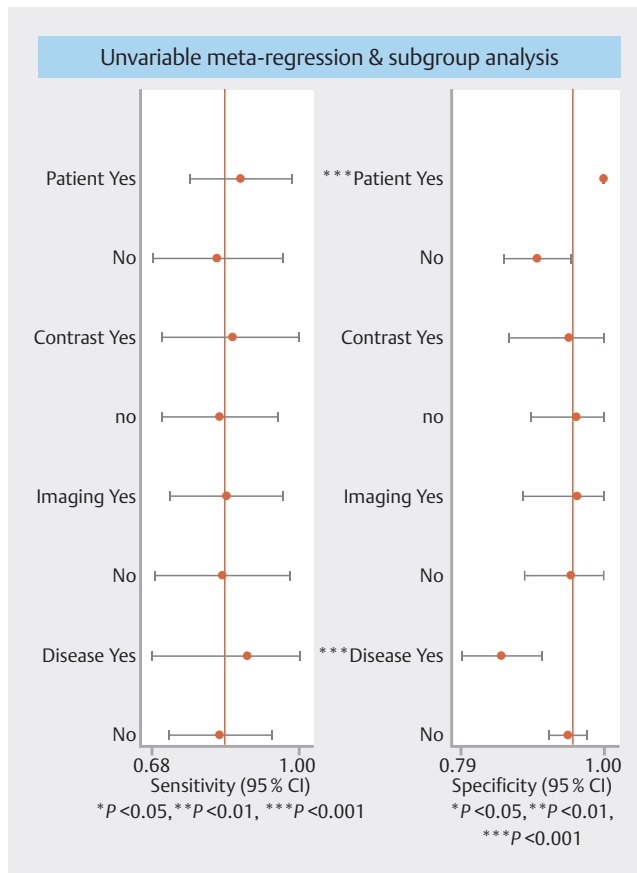


► **Fig. 6** Forest plot of positive and negative likelihood ratios for CE-EUS. Heterogeneity is low in both scenarios (I<sup>2</sup> = 25.52 and I<sup>2</sup> = 7.42).



► Fig. 7 Fagan diagram for diagnosing AIP by CE-EUS.

In different pathological situations, CE-EUS can identify the nature of pancreatic masses based on differences in the density and distribution of microvessels. In dual-screen Doppler-enhanced contrast mode, AIP shows an increased net-like hypervascularization pattern compared to the normal tissue surrounding the pancreas, whereas PC has a reduced blood supply compared to the surrounding tissue [14]. In the Eflow mode of CD-EUS, AIP shows a dendritic vascular pattern, distinguishing it from PC [15]. In the CEH-EUS mode, AIP shows microvascular



► Fig. 8 Meta-regression analysis of potential sources of heterogeneity.

imaging of the tumor in the vascular phase with contrast injection and uniform staining in the perfusion phase, with slower decay in the later phase. In PC, curved tumor vessels are seen in the marginal areas of the tumor during the vascular phase, and only faint and uneven staining is seen in the marginal areas during the reperfusion phase, with a rapid decay in the later stages. In pancreatic endocrine tumors, the lesions stain rapidly and intensely after contrast injection, with EI lasting relatively longer in the vasculature compared to the reperfusion phase. However, the presentation of mass-forming pancreatitis is similar to AIP, which is also a reason for the decreased discrimina-

► Table 2 Subgroup analysis after exclusion of outliers.

Pooled results	Pooled value (95%CI)	P value	I <sup>2</sup> (%)
Sensitivity	0.84 (0.71–0.91)	0.24	26.59
Specificity	0.97 (0.80–1.00)	0.19	33.39
Positive likelihood ratio	25.42 (3.67–176.23)	0.55	0
Negative likelihood ratio	0.17 (0.09–0.32)	0.32	14.10
Diagnostic Odds Ration	150.61 (15.58–1455.62)	0.04	57.32

CI, confidence interval; I<sup>2</sup>, heterogeneity. I<sup>2</sup> >50% is considered to be significant as heterogeneity.

tory ability of CE-EUS. Few studies used CE-EUS to differentially diagnose AIP from other solid tumors of the pancreas, and the quality of the studies is variable. Therefore, this study used meta-analysis to evaluate the use of CE-EUS in pancreatic lesions systematically.

This meta-analysis showed that the combined sensitivity, specificity, positive likelihood ratio, negative likelihood ratio, and diagnostic ratio for the differential diagnosis of AIP and other solid pancreatic masses using CE-EUS were 0.84 (95% CI 0.71–0.92), 0.95 (95% CI 0.84–0.99), 18.12 (95% CI 4.84–68.30), 0.17 (95% CI 0.09–0.32), and 107.91 (95% CI 22.22–524.13). The area under SROC was 0.91 (95% CI 0.88–0.93). The high sensitivity and specificity indicate that CE-EUS has significant discriminative diagnostic value. These data suggest that the reliability of CE-EUS is markedly higher than that of EUS-TA. Subsequently, we explored the ability of CE-EUS to differentiate between AIP and PC, revealing an SROC AUC as high as 0.95 (95% CI 0.93–0.97). This indicates that CE-EUS has high diagnostic value, especially in excluding malignant diseases. In a previous meta-analysis on the differential diagnosis of CE-EUS in PC, we learned that the combination of CH-EUS and EUS-FNA increased the sensitivity of EUS for pancreatic cancer from 92% to 100%. Therefore, we conjecture that CE-EUS has a complementary role to EUS-TA in differential diagnosis of AIP and may help to exclude malignant diseases such as PC [31].

To the best of our knowledge, there were no meta-analyses on the same topic that we could consult to explore whether the findings were consistent. It may be related to the fact that few relevant studies used CE-EUS to identify AIP. Therefore, during the search process, we had to reduce the precision of the search terms to improve the search scope. However, the results were not satisfactory. We found 15 articles with relevant studies, but unfortunately, only six articles were full papers and the rest were conference abstracts. Therefore, we selected two of the seven conference abstracts for inclusion in the study where the full 2×2 contingency table could be extracted.

This study has several limitations. First, items that were unclear in the quality assessment may not match the facts because complete information for the two conference abstracts was not available at the time of quality assessment. Second, significant heterogeneity in specificity and diagnostic advantage ratios may affect interpretation of the data and conclusions. Even after employing subgroup analysis, there remains a noticeable heterogeneity in the diagnostic odds ratio. However, given the limited number of studies included in our analysis, a slightly elevated  $I^2$  is deemed acceptable. Again, the included studies used multiple CE-EUS diagnostic criteria, which may have biased our conclusions somewhat. In addition, the small number of studies (<10) made it hard to draw funnel plots and detect publication bias. Finally, our analysis only included studies published in English literature, which may limit our findings.

## Conclusions

In conclusion, CE-EUS, and in particular, CEH-EUS is a promising tool for differential diagnosis of AIP. More multicenter prospective clinical trials are needed to demonstrate its validity.

## Conflict of Interest

The authors declare that they have no conflict of interest.

## References

- [1] Madhani K, Farrell JJ. Autoimmune pancreatitis: an update on diagnosis and management. *Gastroenterol Clin North Am* 2016; 45: 29–43 doi:10.1016/j.gtc.2015.10.005
- [2] Facciorusso A, Barresi L, Cannizzaro R et al. Diagnostic yield of endoscopic ultrasound-guided tissue acquisition in autoimmune pancreatitis: a systematic review and meta-analysis. *Endosc Int Open* 2021; 9: E66–E75 doi:10.1055/a-1293-7279
- [3] Jang SI, Lee DK. Contrast-enhanced endoscopic ultrasonography: advance and current status. *Ultrasonography (Seoul, Korea)* 2014; 33: 161–169 doi:10.14366/usg.14017
- [4] Kanno A, Ikeda E, Ando K et al. The diagnosis of autoimmune pancreatitis using endoscopic ultrasonography. *Diagnostics (Basel, Switzerland)* 2020; 10: 1005
- [5] Kitano M, Sakamoto H, Matsui U et al. A novel perfusion imaging technique of the pancreas: contrast-enhanced harmonic EUS (with video). *Gastrointest Endosc* 2008; 67: 141–150
- [6] Minami Y, Kudo M, Hatanaka K et al. Radiofrequency ablation guided by contrast harmonic sonography using perfluorocarbon microbubbles (Sonazoid) for hepatic malignancies: an initial experience. *Liver Int* 2010; 30: 759–764 doi:10.1111/j.1478-3231.2010.02226.x
- [7] Cioni D, Lencioni R, Bartolozzi C. Therapeutic effect of transcatheter arterial chemoembolization on hepatocellular carcinoma: evaluation with contrast-enhanced harmonic power Doppler ultrasound. *Eur Radiol* 2000; 10: 1570–1575 doi:10.1007/s003300000496
- [8] Whiting PF, Rutjes AW, Westwood ME et al. QUADAS-2: a revised tool for the quality assessment of diagnostic accuracy studies. *Ann Intern Med* 2011; 155: 529–536 doi:10.7326/0003-4819-155-8-201110180-00009
- [9] Van Houwelingen HC, Zwinderman KH, Stijnen T. A bivariate approach to meta-analysis. *Stat Med* 1993; 12: 2273–2284 doi:10.1002/sim.4780122405
- [10] Van Houwelingen HC, Arends LR, Stijnen T. Advanced methods in meta-analysis: multivariate approach and meta-regression. *Stat Med* 2002; 21: 589–624 doi:10.1002/sim.1040
- [11] Wacker C, Prkno A, Brunkhorst FM et al. Procalcitonin as a diagnostic marker for sepsis: a systematic review and meta-analysis. *Lancet Infect Dis* 2013; 13: 426–435 doi:10.1016/S1473-3099(12)70323-7
- [12] Higgins JP, Thompson SG. Quantifying heterogeneity in a meta-analysis. *Stat Med* 2002; 21: 1539–1558 doi:10.1002/sim.1186
- [13] Page MJ, McKenzie JE, Bossuyt PM et al. The PRISMA 2020 statement: an updated guideline for reporting systematic reviews. *BMJ* 2021; 372: n71 doi:10.1136/bmj.n71
- [14] Hocke M, Ignee A, Dietrich CF. Contrast-enhanced endoscopic ultrasound in the diagnosis of autoimmune pancreatitis. *Endoscopy* 2011; 43: 163–165 doi:10.1055/s-0030-1256022
- [15] Kobayashi G, Fujita N, Noda Y et al. Vascular image in autoimmune pancreatitis by contrast-enhanced color-Doppler endoscopic ultrasonography: Comparison with pancreatic cancer. *Endosc Ultrasound* 2014; 3: S13
- [16] Cho MK, Moon SH, Song TJ et al. Contrast-enhanced endoscopic ultrasound for differentially diagnosing autoimmune pancreatitis and pancreatic cancer. *Gut Liver* 2018; 12: 591–596 doi:10.5009/gnl17391



- [17] Dong Y, D'onofrio M, Hocke M et al. Autoimmune pancreatitis: Imaging features. *Endosc Ultrasound* 2018; 7: 196–203 doi:10.4103/eus.eus\_23\_17
- [18] Imazu H, Kanazawa K, Mori N et al. Novel quantitative perfusion analysis with contrast-enhanced harmonic EUS for differentiation of autoimmune pancreatitis from pancreatic carcinoma. *Scand J Gastroenterol* 2012; 47: 853–860
- [19] Ishikawa T, Hirooka Y, Itoh A et al. Usefulness of endoscopic ultrasonography (plain combined with contrast-enhanced) in the differentiation between autoimmune pancreatitis and pancreatic cancer. *Gastrointest Endosc* 2009; 69: AB246
- [20] Yamashita Y, Kato J, Ueda K et al. Contrast-enhanced endoscopic ultrasonography for pancreatic tumors. *Biomed Res Int* 2015; 2015: 491782 doi:10.1155/2015/491782
- [21] Deeks JJ, Macaskill P, Irwig L. The performance of tests of publication bias and other sample size effects in systematic reviews of diagnostic test accuracy was assessed. *J Clin Epidemiol* 2005; 58: 882–893 doi:10.1016/j.jclinepi.2005.01.016
- [22] Hardacre JM, Iacobuzio-Donahue CA, Sohn TA et al. Results of pancreaticoduodenectomy for lymphoplasmacytic sclerosing pancreatitis. *Ann Surg* 2003; 237: 853–859 doi:10.1097/01.SLA.0000071516.54864.C1
- [23] Kajiwara M, Gotohda N, Konishi M et al. Incidence of the focal type of autoimmune pancreatitis in chronic pancreatitis suspected to be pancreatic carcinoma: experience of a single tertiary cancer center. *Scand J Gastroenterol* 2008; 43: 110–116 doi:10.1080/00365520701529238
- [24] Abraham SC, Wilentz RE, Yeo CJ et al. Pancreaticoduodenectomy (Whipple resections) in patients without malignancy: Are they all 'chronic pancreatitis'? *Am J Surg Pathol* 2003; 27: 110–120
- [25] Sasson A R, Gulizia J M, Galva A et al. Pancreaticoduodenectomy for suspected malignancy: have advancements in radiographic imaging improved results? *Am J Surgery* 2006; 192: 888–893
- [26] Kennedy T, Preczewski L, Stocker SJ et al. Incidence of benign inflammatory disease in patients undergoing Whipple procedure for clinically suspected carcinoma: a single-institution experience. *Am J Surg* 2006; 191: 437–441 doi:10.1016/j.amjsurg.2005.10.051
- [27] Meng F-S, Zhang Z-H, Ji F. New endoscopic ultrasound techniques for digestive tract diseases: A comprehensive review. *World J Gastroenterol* 2015; 21: 4809–4816 doi:10.3748/wjg.v21.i16.4809
- [28] Yoon SB, Moon SH, Song TJ et al. Endoscopic ultrasound-guided fine needle aspiration versus biopsy for diagnosis of autoimmune pancreatitis: Systematic review and comparative meta-analysis. *Digest Endosc* 2021; 33: 1024–1033 doi:10.1111/den.13866
- [29] Sontum PC. Physicochemical characteristics of sonazoid, a new contrast agent for ultrasound imaging. *J Ultrasound Med Biol* 2008; 34: 824–833 doi:10.1016/j.ultrasmedbio.2007.11.006
- [30] Masuzaki R, Shiina S, Tateishi R et al. Utility of contrast-enhanced ultrasonography with Sonazoid in radiofrequency ablation for hepatocellular carcinoma. *J Gastroenterol Hepatol* 2011; 26: 759–764
- [31] He XK, Ding Y, Sun LM. Contrast-enhanced endoscopic ultrasound for differential diagnosis of pancreatic cancer: an updated meta-analysis. *J Oncotarget* 2017; 8: 66392–66401 doi:10.18632/oncotarget.18915