



A Rare Case of Dual Primary Supratentorial Glioma and Infratentorial Meningioma

Chi-Man Yip¹ Chia Ing Jan^{2,3,4,5}

¹Division of Neurosurgery, Kaohsiung Veterans General Hospital, Kaohsiung, Taiwan

²Department of Pathology and Laboratory Medicine, Kaohsiung Veterans General Hospital, Kaohsiung, Taiwan

³School of Medicine, College of Medicine, National Sun Yat-sen University, Kaohsiung, Taiwan

⁴School of Medicine, Chung Shan Medical University, Taichung, Taiwan

⁵Department of Nursing, School of Nursing, Mei-Ho University Ping-Tung, Taiwan

Address for correspondence Chia Ing Jan, MD, PhD, Department of Pathology and Laboratory Medicine, Kaohsiung Veterans General Hospital, Kaohsiung 813, Taiwan (e-mail: janc1206@yahoo.com.tw).

J Neurol Surg Rep 2024;85:e179–e183.

Abstract

Introduction Gliomas and meningiomas are two common primary brain tumors, but occurring simultaneously in the same patient is a rare entity. The authors would like to report a case of coexistence of a superior parietal lobule diffuse glioma, IDH-wild type, histologically CNS WHO grade 3 and a left posterior fossa transitional meningioma, WHO grade 1; both the tumors were successfully removed in one-stage operation.

Case Presentation A 68-year-old female having hypertension, who presented to us with the chief complaints of involuntary shaking of her left lower limb associated with her left upper limb tingle, dizziness, and neck soreness. She was found to have a lesion in her right parietal region and a tumor in her left cerebellar region. After detailed discussion with the patient and thorough preoperative evaluation, the authors performed a right parietal craniotomy and a left retrosigmoid approach in one-stage operation to remove both the tumors, which were proven to be of two distinct histological identities.

Conclusion The management for two tumors located far apart needs a case-by-case evaluation. An important aspect while dealing with such cases is to decide which tumor needs to be operated first or whether both lesions can be operated at the same time with one-stage operation.

Keywords

- ▶ dural primary brain tumors
- ▶ one-stage operation
- ▶ infratentorial meningioma
- ▶ supratentorial glioma

Introduction

Coexisting brain tumors of different histological identities in the same patient is a rare condition.¹ The incidence of multiple primary brain tumors with different histological types in the same patient is only 0.3% of all brain tumors or 10 to 15 cases/100,000 who develop primary brain tumors.^{2,3}

Glioma is the most common and aggressive primary brain tumor that originates from glial cells, representing 81% of malignant brain tumors. Meningiomas are the most common extra-axial neoplasms, accounting for 24 to 30% of all brain tumors, which develop from the arachnoid cap cells.² Glioma and meningioma are two common primary brain tumors and commonly occur as solitary lesions; both the tumors

received
August 12, 2024
accepted after revision
November 11, 2024

DOI <https://doi.org/10.1055/a-2466-7362>.
ISSN 2193-6358.

© 2024. The Author(s).

This is an open access article published by Thieme under the terms of the Creative Commons Attribution-NonDerivative-NonCommercial-License, permitting copying and reproduction so long as the original work is given appropriate credit. Contents may not be used for commercial purposes, or adapted, remixed, transformed or built upon. (<https://creativecommons.org/licenses/by-nc-nd/4.0/>)

Georg Thieme Verlag KG, Oswald-Hesse-Straße 50, 70469 Stuttgart, Germany

occurring simultaneously in the same patient is a rare occurrence. The underlying pathophysiology and growth dynamics of simultaneous occurrence of glioma and meningioma are not fully understood, but most likely may involve complex changes genetically or modifications in the tumor microenvironment.^{1,4-6} In some literatures, previous radiotherapy, genetic syndromes such as neurofibromatosis, and exposure to carcinogens are suggested to be the causative or contributory factors in the development of concomitant occurrence of glioma and meningioma.^{3,5} In this article, we report a case of coexistence of supratentorial glioma and infratentorial meningioma in the same patient without previous radiotherapy or any genetic disorders. Although both the tumors were located far apart, they were excised successfully in one-stage of operation. To our best knowledge, this is probably the first reported case of simultaneous occurrence of supratentorial glioma and infratentorial meningioma in the same patient in the English literature.

Case Presentation

A 68-year-old right-handed female known to have medical history of hypertension since 2014 with regular control visited emergency department of a local hospital in January 2024 due to sudden onset of an episode of involuntary shaking of her left lower limb associated with her left upper limb tingle, dizziness, and neck soreness. Under the impression of stroke, a non-contrast brain computed tomography (CT) was done showing no intracerebral hemorrhage but a low-density lesion of unknown nature detected in the right high parietal region (►Fig. 1); therefore, she was referred to our neurosurgery outpatient department for further evaluation.

On admission, her neurological examination and physical examination were essentially normal and her laboratory data including tumor markers were within normal limits. Brain magnetic resonance imaging (MRI) was arranged which showed an infiltrative lesion with high signal intensity

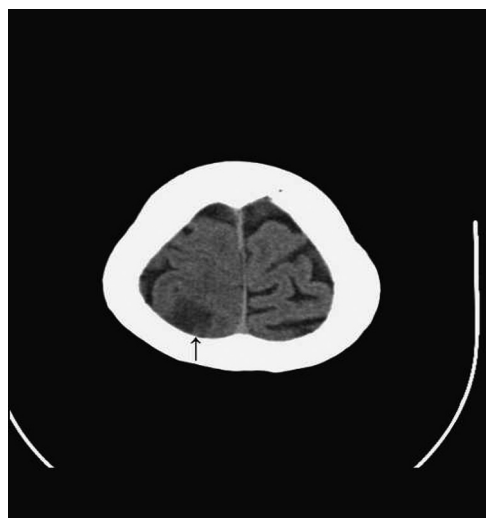


Fig. 1 Axial noncontrast brain computed tomography (CT) showing a low density lesion of unknown nature detected in the right high parietal region (arrow).

on T2-weighted image (T2WI) and fluid-attenuated inversion recovery (FLAIR) involving the right superior parietal lobule, and after gadolinium injection, this lesion showed subtle enhancement. Besides that, another well-enhancing lesion was found in the left cerebellar region (►Fig. 2). From the brain imaging, both the lesions were not of the same entity; the clinical presentation of this patient was related to the right superior parietal lobule lesion.

After detailed discussion with the patient and thorough preoperative evaluation, this patient preferred to excise both the lesions in one-stage surgery. Under general anesthesia, she was put in a lateral decubitus position with the left side up and her head was fixed by Mayfield skull clamp. Neuro-navigation was utilized to localize both supratentorial and infratentorial lesions and to plan the site and size of two craniotomies. Surgical removal of the right parietal lobule lesion was performed first. An inverted U-shaped incision was made on the right parietal scalp with midline crossing. The scalp flap was reflected; the craniotomy window was done in usual way and the dura was opened; then two prominent cortical veins with bulging gyrus in between were exposed. The bulging gyrus was further confirmed by neuronavigation to be the infiltrative lesion shown on the brain MRI. The arachnoid membrane covering the two prominent cortical veins and the neighboring sulci was incised, then dissected the target bulging gyrus from its neighboring gyri through the trans-sulci dissection, and it was gross totally removed. A small part of the excised lesion was sent for frozen section that reported suspected high-grade glioma. Hemostasis and wound closure were done in usual fashion.

Surgical excision of the left cerebellar region tumor was performed subsequently in the same-stage operation. A longitudinal incision was made on the left retromastoid region followed by the placement of a self-retaining retractor to expose the skull. A burr hole was made on the exposed skull and the size of the burr hole was enlarged by drilling. A solid tumor was exposed, and invasion of the overlying dura was noted.

The left cerebellum was also compressed by the tumor. We dissected the tumor from the underlying left cerebellum and removed it in one piece, and excised the diseased dura at the same time. Dura reconstruction with the use of dural substitute and mesh cranioplasty were performed after total tumor resection had been achieved. Hemostasis and wound closure were done in usual way.

This patient recovered well, and no neurological deficit was left after the surgery. Her early postoperative brain MRI showed the complete removal of the well-enhanced lesion in the left cerebellar region and the removal of the right superior parietal lobule infiltrative lesion with some enhancements at the peripheral and deep area of the right parietal lobe; postoperative change with or without residual tumor was considered (►Fig. 3).

Histology examination of the right superior parietal lobule lesion demonstrated that the specimen was composed of highly cellular, astrocytic, poorly differentiated tumor cells with nuclear atypia and marked pleomorphism. Mitotic activity was readily identifiable, but necrosis, with or without perinecrotic palisading, and microvascular proliferation

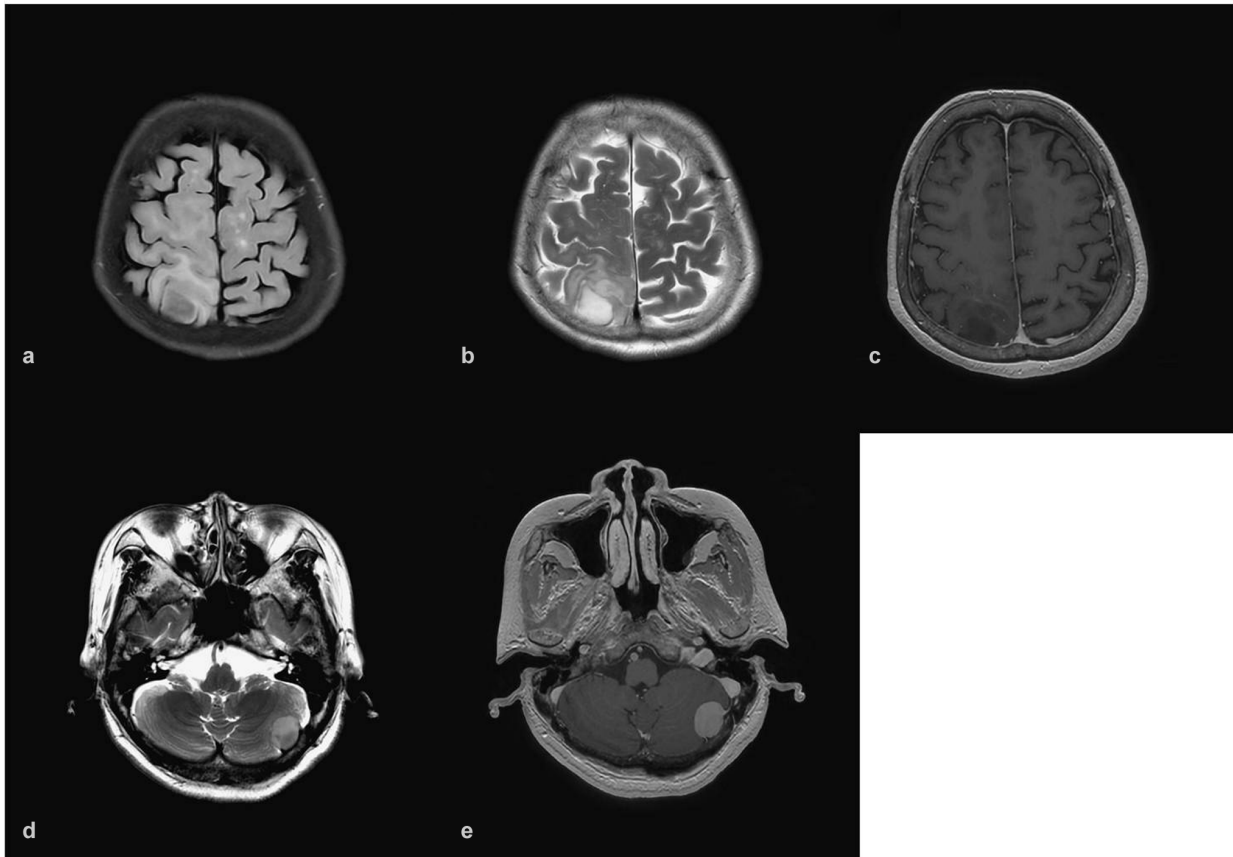


Fig. 2 Preoperative brain magnetic resonance imaging (MRI). Axial T2 fluid-attenuated inversion recovery (FLAIR) (a) and axial T2-weighted image (T2WI) (b) showing an infiltrative lesion with high signal intensity involving the right superior parietal lobule. Axial T1-weighted image (T1WI) post gadolinium injection (c) showing subtle enhancement. Axial T2WI (d) demonstrating an iso-to-high signal intensity lesion in the left cerebellar region and axial T1WI post gadolinium injection (e) revealing well enhancement.

were not identified. Immunohistochemistry revealed tumor cells were positive for glial fibrillary acidic protein (GFAP); Olig-2, SOX-2, P53, and ATRX showed retained nuclear staining. The tumor cells stained negative for IDH1 R132H antibody. The Ki-67 proliferative index was approximately 25%; MGMT immunostain revealed unmethylated status of tumor cell (► **Fig. 4**). Histologic grade 3, IDH-wild type, diffuse glioma was diagnosed according to the algorithm proposed by Brat et al.⁷ Molecular studies including TERT promoter mutation or EGFR gene amplification for the diagnosis of IDH-wild type glioblastoma in the current fifth edition of WHO classification of CNS tumors was advised but not done because these tests are not available at our hospital. Histology examination of the left cerebellar tumor showed leptomeningeal tissue with mixed fibrous and meningotheliomatous cells in focal whorling arrangement. No evidence of atypical features was identified in the specimen, and the tumor cells were positive for SSTR2A immunostain. Transitional meningioma, WHO grade 1 was diagnosed based on the morphology of the tumor cells and the result of immunohistochemical stain (► **Fig. 5**).

This patient was discharged home with the Karnofsky Performance Score of 90. Since the right superior parietal lobule lesion was proved to be high-grade glioma, postoperative adjuvant radiotherapy was arranged with the dose of 60 Gy in 30 fractions. She tolerated the radiotherapy well and is

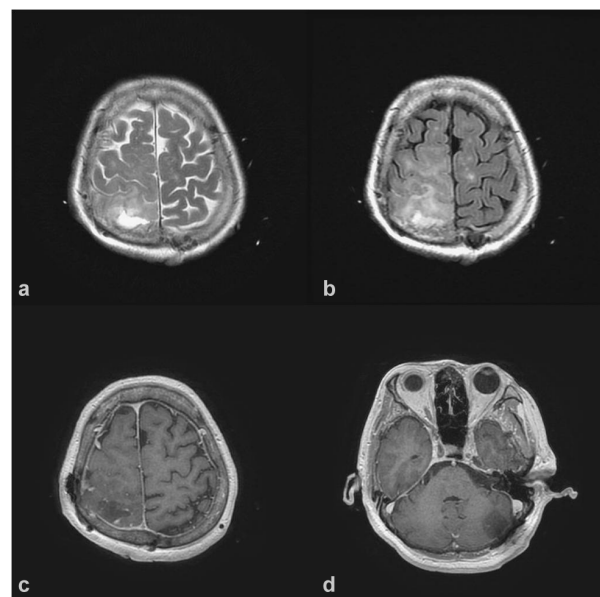


Fig. 3 Postoperative brain magnetic resonance imaging (MRI). Axial T2-weighted image (T2WI) (a) fluid-attenuated inversion recovery (FLAIR) (b) and axial T1-weighted image (T1WI) post gadolinium injection (c) showing a good resection of the right superior parietal lobule lesion with some postoperative change. Axial T1WI post gadolinium injection (d) revealing the total resection of the left cerebellar tumor without residual tumor.

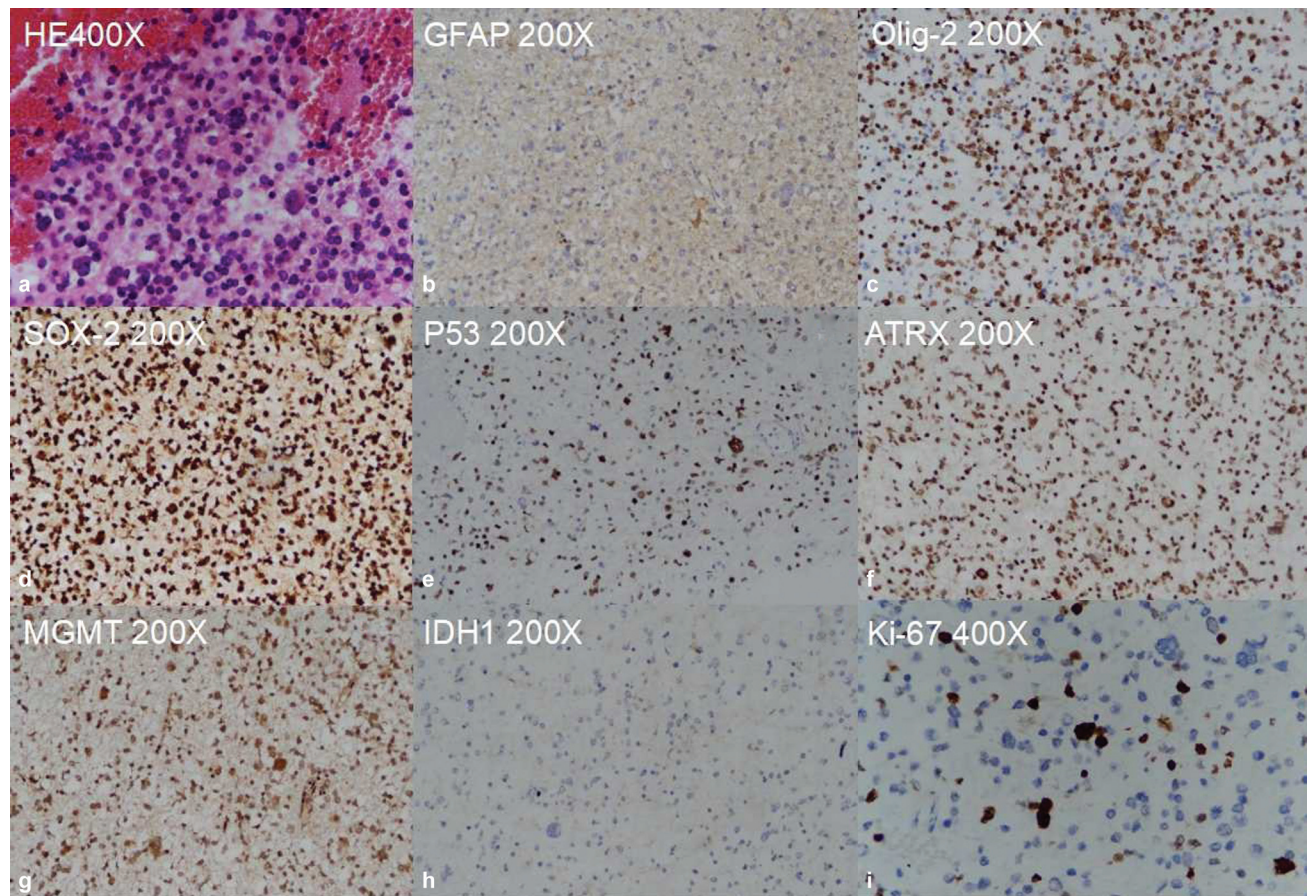


Fig. 4 Histology and immunohistochemical stains of the right superior parietal lobule lesion. Hematoxylin and eosin (HE) stain (a) showed a picture of highly cellular glioma composed of astrocytic, poorly differentiated tumor cells with nuclear atypia and marked pleomorphism. Mitotic activity was shown; pseudopalisading tumor necrosis and microvascular proliferation were not identified. Glial fibrillary acidic protein (GFAP) stain (b), Oligo-2 stain (c), SOX-2 stain (d), P53 stain (e), ATRX stain (f), and MGMT stain (g) showed positive staining. IDH1 R132H stain (h) demonstrated negative staining. Ki-67 proliferative index (i) was approximately 25%.

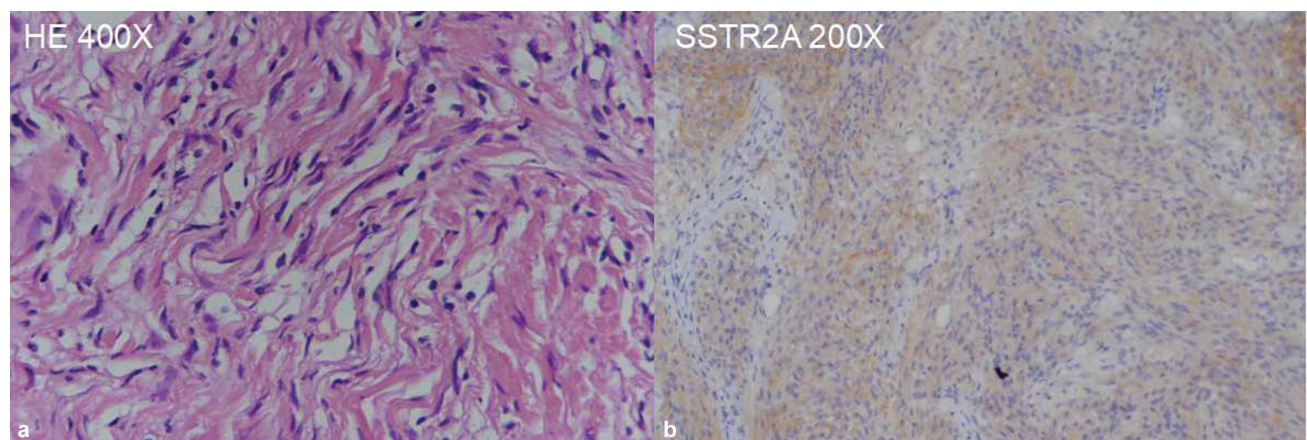


Fig. 5 Histology and immunohistochemical stains of the left cerebellar tumor. Hematoxylin and eosin (HE) stain (a) showed leptomeningeal tissue with mixed fibrous and meningotheliomatous cells in focal whorling arrangement. SSTR2A stain (b) showed positive staining.

followed up regularly at our neurosurgery outpatient department.

Discussion

The occurrence of coexisting primary brain tumors of different histology in the same patient is very rare, especially for

those without previous radiotherapy, genetic disorders, or phacomatosis.⁶ From 1976 to 2023, there were 24 cases of concomitant occurrence of glioblastoma and meningioma in the CNS reported in English literatures and the location of two lesions was close to each other in most cases.^{4,8} From 1983 to 2019, there were 14 cases of simultaneous occurrence of astrocytoma and meningioma reported in English

literatures, but none of them located separately in the supratentorial and infratentorial regions.^{3,6} Mechanisms for the simultaneous occurrence of two distinct tumor types remain unclear. In reported literatures, previous radiotherapy, genetic syndromes such as Turcot's and Sipple's syndromes, exposure to carcinogens, and some phacomatosis such as von Recklinghausen neurofibromatosis are suggested to be the causative or contributory factors in the development of concomitant occurrence of glioma and meningioma.^{3,5}

There are several hypotheses discussing the coexistence of glioma and meningioma. Some studies suggested that the initial tumor can act as an oncogenesis agent for the development of the other tumors.^{2,6} Collision tumors are two tumors at adjacent sites, which means they may share a common tumor microenvironment.⁵ Some studies of receptor tyrosine kinase (RTK) signaling molecules suggest that platelet-derived growth factor (PDGF) and platelet-derived growth factor receptor (PDGFR) are relevant factors.³ PDGF is one among numerous growth factors that regulate cell growth and division; expression of PDGFR is involved in the tumorigenesis and malignant progression of meningioma. Three subunits of PDGF, namely, PDGF-AA, PDGF-BB, and PDGF-AB, are secreted by astrocytoma; astrocytoma has PDGF- α -R and the tumor growth is stimulated by PDGF in an autocrine fashion. PDGF- β -R is found in meningioma. PDGF receptors α and β are overexpressed in glioblastoma multiforme and meningioma, indicating the oncogenic effects of activated signaling of these receptors.³ Some studies suggest that the development of meningioma and glioma is likely to be involved in common genes.³ N-myc downstream-regulated gene 2 (NDRG2) is a tumor suppressor gene, which is regarded as a potential common pathogenetic site for astrocytoma and meningioma. NDRG2 gene is expressed in normal brain tissue but downregulated in glioma; downregulation of the NDRG2 gene on 14q is shown to be associated with a high WHO grade meningioma. Therefore, inactivation of NDRG2 may play a role in the pathogenesis of both meningioma and glioma.³ Tumor microenvironment and genetic mutation are the major factors to the development of the coexistence of primary brain tumors of different histology.^{1,4-6} Back to our case, based on the distant location of both the tumors, the cause of concomitant occurrence of glioma and meningioma in this particular patient requires further investigation.

The management for two tumors located far apart needs a case-by-case evaluation.

An important aspect while dealing with such cases is to decide which tumor needs to be operated first or whether both lesions can be operated at the same time with one-stage

operation. Usually, the tumor causing symptoms or having mass effect should be treated first. Postoperative adjuvant radiotherapy or chemotherapy may be indicated based on the pathological diagnosis of the tumors. If feasible, removing both tumors in the same stage of operation can bring maximum benefit to patients. Back to our patient, if we remove the right superior parietal lobule glioma first because it was symptomatic and leave the left cerebellar meningioma for second surgery, the patient must undergo another general anesthesia. The second surgery will definitely be postponed because she has to finish the postoperative adjuvant radiotherapy for her high-grade glioma; also the patient needs time to recover from the effect of radiotherapy. We do not know whether there will be any changes to the cerebellar meningioma during this long treatment period. We put our patient in a lateral decubitus position with the left side up so that we can approach the right superior parietal lobule lesion and the left cerebellar region tumor in the same surgery. In this particular patient, this is probably the best way of treatment. Patient-centered treatment planning and performing surgery with caution are keys for us to treat our patients successfully.

Conflict of Interest

None declared.

References

- 1 Al Mashani A, Salhotra N, Al Zabin M, Ali A, Al Abri S. Rare case of coexisting meningioma and glioma in same patient: a case report. *Am J Med Case Rep* 2017;5:1-3
- 2 Velho V, Sadhwani N, Bhide A. Collision tumors: a rare case report. *Asian J Neurosurg* 2020;15(03):741-744
- 3 Hasimu A, Fu Q, Zhou Q, et al. Astrocytoma simultaneously present with meningioma—a report of two cases and review of the literature. *Chin Neurosurg J* 2016;2:9
- 4 Atallah O, Almealawy YF, Awuah WA, Conti A, Chaurasia B. Is simultaneous occurrence of meningioma and glioblastoma a mere coincidence? *Clin Neurol Neurosurg* 2024;236:108099
- 5 Zhang Z, Yang Y, Zhang K, et al. Collision tumor of glioblastoma and meningioma: case report and literature review. *World Neurosurg* 2018;117:137-141
- 6 Truong VT, Tran DDT, Dang CT. Collision occurrence of meningioma and astrocytoma: a case report and literature review. *Asian J Neurosurg* 2019;14(03):938-942
- 7 Brat DJ, Aldape K, Bridge JA, et al. Molecular biomarker testing for the diagnosis of diffuse gliomas. *Arch Pathol Lab Med* 2022;146(05):547-574
- 8 Mitsos AP, Konstantinou EA, Fotis TG, Lafazanos SA, Kontogeorgos G, Georgakoulas NV. Sphenoid wing meningioma and glioblastoma multiforme in collision—case report and review of the literature. *Neurol Neurochir Pol* 2009;43(05):479-483