

Endoscopy International Open

Radiographic, fluoroscopic, and endosonographic predictors of failed EUS-guided transgastric stent placement in patients with Roux-en-Y bypass anatomy

Benjamin M Moy, Hero Hussain, Jessica Yu, Kevin D Platt, Jorge Machicado, Richard S Kwon, Erik-Jan Wamsteker, George Philips, Allison R Schulman.

Affiliations below.

DOI: 10.1055/a-2499-3468

Please cite this article as: Moy B M, Hussain H, Yu J et al. Radiographic, fluoroscopic, and endosonographic predictors of failed EUS-guided transgastric stent placement in patients with Roux-en-Y bypass anatomy. *Endoscopy International Open* 2024. doi: 10.1055/a-2499-3468

Conflict of Interest: Allison R. Schulman is a consultant for Apollo Endosurgery, Boston Scientific, Olympus, Microtech, and Fractyl and receives research/grant support from Fractyl and GI Dynamics. The remaining authors have no conflicts of interest to declare.

Abstract:

Background and study aims: Gastric access temporary for endoscopy (GATE) via endoscopic ultrasound-guided stent placement between the gastric pouch/jejunum and remnant stomach is used in Roux-en-Y gastric bypass (RYGB) to facilitate endoscopic retrograde cholangiopancreatography or other maneuvers. This study aimed to identify radiographic predictors of GATE failure and intraprocedure reasons for aborting.

Patients and methods: Patients undergoing GATE were matched 3:1 on procedure success. Features indicating quality of the transgastric window were collected including: 1) gastric pouch/blind limb length; 2) location of remnant stomach relative to pouch or blind/roux limb; 3) pouch orientation; 4) remnant orientation; 5) length of contact; 6) tissue thickness; and 7) presence of poor contact (calcification, surgical material, intervening vasculature). Primary outcome was radiographic criteria associated with GATE failure. Secondary outcomes were endoscopic, endosonographic, and fluoroscopic intraprocedure reasons for aborting GATE.

Results: Forty patients (30 successful, 10 aborted, 82.5% failed) who underwent GATE were included. Mean (\pm SD) age and time since RYGB were 62.8 ± 11.9 and 15.1 ± 8.6 years, respectively. There were no group demographic differences. The cumulative number of contact-related risk factors was associated with GATE failure (odds ratio 26.1, 95% confidence interval 0.004-0.337; $P = 0.004$). Two or more factors increased the likelihood of GATE failure ($P < 0.05$). Echoendoscope angulation/tip deflection, intervening vasculature, distance to remnant stomach, rapid emptying and/or insufficient filling of contrast were reported in cases of GATE failure.

Conclusions: Radiographic features may predict GATE failure including intervening vasculature or insufficient contact between gastric pouch/blind limb and remnant. Patients demonstrating these features may benefit from alternative treatment approaches early in management.

Corresponding Author:

Allison R Schulman, University of Michigan, Division of Gastroenterology and Hepatology, Ann Arbor, United States, arschulm@med.umich.edu

Affiliations:

Benjamin M Moy, University of Michigan, Division of Gastroenterology and Hepatology, Ann Arbor, United States
Hero Hussain, University of Michigan, Department of Radiology, Ann Arbor, United States

Jessica Yu, University of Michigan, Division of Gastroenterology and Hepatology, Ann Arbor, United States
[...]
Allison R Schulman, University of Michigan, Department of Surgery, Ann Arbor, United States



This article is protected by copyright. All rights reserved.

Accepted Manuscript

This is a PDF file of an unedited manuscript that has been accepted for publication. As a service to our customers we are providing this early version of the manuscript. The manuscript will undergo copyediting, typesetting, and review of the resulting proof before it is published in its final form. Please note that during the production process errors may be discovered which could affect the content, and all legal disclaimers that apply to the journal pertain.

INTRODUCTION

Roux-en-Y gastric bypass (RYGB) anatomy poses unique challenges in the setting of endoscopic evaluation. Specifically, the remnant stomach, duodenum, and pancreaticobiliary tract are excluded from traditional endoscopic approaches. Historically, access into the remnant stomach or duodenum for evaluation and/or treatment of pancreaticobiliary disease after RYGB has been achieved through laparoscopic or balloon-assisted enteroscopy techniques. However, despite excellent technical and clinical success, laparoscopic approaches require coordination and operating room availability, and balloon-assisted enteroscopy is often challenging, leading to an oblique orientation of the papilla and lower success rates [1].

Endoscopic ultrasound (EUS)-guided techniques have gained significant attention given their favorable safety, efficacy, and efficiency profiles. These modalities facilitate access and stent placement into the remnant stomach in post-bariatric surgical anatomy, allowing easy entry for evaluating the remnant stomach or duodenum and/or treatment of pancreaticobiliary disease [2].

Particularly, gastric access temporary for endoscopy (GATE) is a technique whereby a lumen apposing metal stent (LAMS) is placed under EUS guidance between the gastric pouch or proximal jejunum and the remnant stomach. The most common indication for GATE placement is to facilitate endoscopic retrograde cholangiopancreatography (ERCP). Following successful LAMS placement, endoscopic ultrasound-directed transgastric ERCP (EDGE) has been reported to have a clinical success rate of over 95% [3-7]. However, initial LAMS placement in the setting of a GATE procedure is not always technically feasible.

Much of the literature investigating GATE/EDGE has centered on outcomes of the procedure post-LAMS placement. Little is known about potential obstacles to stent placement and predictors of GATE failure. Understanding predictors of GATE failure may mitigate unnecessary intervention, prevent delays of care, guide clinical decision-making, and reduce adverse events.

The current study aims to identify (1) radiographic predictors of failure in patients with RYGB anatomy undergoing GATE and (2) intraprocedural endoscopic, endosonographic, and fluoroscopic reasons for aborting GATE.

METHODS

Study Population

This was a retrospective matched controlled cohort study analyzing a prospectively collected database of patients with pre-procedure computed tomography (CT) undergoing GATE at a single high-volume academic medical center between 2018 and 2022. Inclusion criteria included patients with RYGB anatomy and no other history of bariatric surgery who required evaluation of the remnant stomach, duodenum, or pancreaticobiliary tract. Specifically, patients with prior sleeve gastrectomy anatomy were excluded from analysis. The institutional review board at our medical

center approved this study. Patients with a failed GATE were matched on a 3:1 ratio to patients with a successful GATE.

Procedural Protocol

All procedures were performed under general anesthesia. Patients were initially placed in a lazy left lateral decubitus position and adjustments were made as needed. Prior to endosonography, endoscopic evaluation of the upper gastrointestinal tract was performed to confirm no contraindications to proceeding. A linear EUS procedure was then performed. The remnant stomach was visualized under endoscopic ultrasound. Doppler was used to verify the absence of intervening vasculature. A 19-gauge fine aspiration needle (EchoTip Ultra, Cook Medical, Bloomington, IN, USA; EZ Shot 3 Plus, Olympus Medical, Westborough, MA, USA; Expect, Boston Scientific, Marlborough, MA, USA) was used to establish access under EUS guidance between the gastric pouch (gastric-gastric, G-G) or proximal jejunum (jejuno-gastric, J-G) and the remnant stomach. The remnant stomach was then filled with 500-1000 cc of 20-80 dilution contrast (Omnipaque (iohexol), GE Healthcare, Marlborough, MA) to visualize the remnant stomach.

Under fluoroscopic, endosonographic, and endoscopic guidance, a single 20 mm x 10 mm LAMS was deployed, with the distal phalange of the LAMS in the remnant stomach and the proximal phalange released in the gastric pouch or proximal jejunum. The stent was confirmed on endoscopic, endosonographic, and fluoroscopic images. The decision to attempt or abort LAMS placement was at the discretion of the advanced endoscopist (AE) and confirmed by a second AE.

Radiologic Protocol

All CT scans were performed with an identical intravenous and oral contrast protocol which is standardized at our academic medical center. Scans were performed 30 minutes after the administration of 1500 mL oral contrast (READI-CAT 2). Scans were acquired during the venous phase of enhancement following the intravenous administration of 125 mL of iodinated contrast (Isovue 300 mg iodine/mL). The contrast was injected via an antecubital vein using a power injector at a rate of 2 ml/second. Imaging parameters were as follows: 120 kVp, automatically modulated mAs, a pitch of 1, gantry rotation time of 0.5 second, a field of view of approximately 350 mm, and a matrix size of 512 × 512. Images were reconstructed using a soft tissue algorithm with a slice thickness of 2.5 mm.

Study Variables

Pre-procedure CT images were reviewed by an experienced abdominal/pancreaticobiliary radiologist blinded to procedure success. Features indicating the quality of the trans-gastric window were collected including (1) gastric pouch and blind limb length, (2) location of the remnant stomach relative to the gastric pouch, blind limb, or roux limb, respectively (anterior, posterior, superior, inferior, right or left lateral), (3) orientation of the gastric pouch (straight/curved), (4) orientation of the remnant stomach, (5) length of contact, (6) distance between the remnant stomach and the nearest access site, whether gastric pouch, blind limb, or

roux limb, and (7) presence of poor contact. Poor contact was reflected radiographically by the presence of thickened tissue (i.e. no contact or approximately 1 cm distance between the excluded stomach and gastric pouch/jejunum), calcification (linear or dystrophic including staple line calcification, calcification associated with post-surgical complications such as hematoma, abscess, or leak, or calcification in areas of post operative chronic inflammation or fibrosis), surgical material (titanium staples or metal reinforcement sutures), or intervening vasculature (vessels traversing the space between the excluded stomach and gastric pouch/jejunum including arteries or arterial branches supplying the stomach or veins draining the stomach including the gastric, short gastric, or gastroepiploic arteries and accompanying parallel veins).

Intraprocedural endoscopic, endosonographic, and fluoroscopic data were also collected. Demographic data including sex, age, procedure information, co-morbidities, weight at the time of procedure, and time since RYGB were extracted from chart review.

Outcomes

The primary outcome was radiographic criteria associated with GATE failure. Secondary outcomes were intraprocedural endoscopic, endosonographic, and fluoroscopic reasons for GATE failure. GATE failure was defined as the decision to abort LAMS placement due to endoscopic, endosonographic, or fluoroscopic concerns, while GATE success was defined as the decision to attempt LAMS placement.

Statistical Analyses

Proportions were compared using Fisher's exact test and continuous variables using the student t-test. All statistics are reported as mean±SEM. A two-tailed p-value of <0.05 was considered statistically significant. SAS 9.4 statistical software (Cary, NC) was used for all analyses.

RESULTS

Forty patients (30 successful cases, 10 failed cases) who underwent an attempt at GATE were included and matched 3:1 based on procedure success. All patients had pre-procedure computed tomography (CT). 82.5% (n=33) of the cohort was female. The mean age and time since RYGB for the cohort were 62.8±11.9 and 15.1±8.6 years, respectively (**Table 1**).

Radiographic Findings

Length, Location, Orientation

Gastric pouch length measured on CT in the GATE success and failure groups were 5.9±1.6 cm and 6.2±3.2 cm, respectively. There were no significant differences between the GATE success or failure groups regarding (1) gastric pouch and blind limb length, (2) location of the remnant stomach relative to the gastric pouch, blind limb, or roux limb, respectively (anterior, posterior, superior, inferior, or right or left lateral), (3) orientation of the gastric pouch (straight/curved), and (4) orientation of the remnant stomach (**Figure 1, Table 2**).

Contact

Representative images of the length of contact (5) and (6) thickness of the tissue between the remnant stomach and the gastric pouch, blind limb, or roux limb, or (7) factors indicating presence of poor contact, including thickened tissue, calcification, surgical material, and intervening vasculature, are shown in **Figure 2**. The cumulative number of contact-related risk factors was associated with GATE failure (OR 26.1, 95% confidence interval 0.004, 0.337; $p=0.004$) (**Table 3, Figure 3**). Two or more factors increased the likelihood of a failed GATE ($p<0.05$).

Endoscopic, Fluoroscopic, and Endosonographic Findings

Echoendoscope angulation or tip deflection, intervening vasculature, distance to remnant stomach, rapid emptying and/or insufficient filling of contrast were reasons for GATE failure. Cases were aborted when the tip deflection of the echoendoscope was extreme with such significant tension on the big wheel of the echoendoscope that there was appropriate concern that a stent would not deploy properly. Cases were also aborted if the distance to the remnant stomach was over 10 mm in length or when the excluded stomach was unable to be expanded at least 2-3 cm by fluid/contrast injection or did not remain expanded long enough to be able to safely place the LAMS. Finally, cases were aborted if intervening vessels could not be avoided in the desired pathway for stent placement.

DISCUSSION

Endoscopic evaluation in patients with RYGB anatomy is technically challenging given the exclusion of the remnant stomach, duodenum, and pancreaticobiliary tract. GATE/EDGE procedures have been increasingly performed as a safe, effective option for accessing these sections of the gastrointestinal tract. While many studies have demonstrated the high technical success and clinical efficacy of GATE and EDGE procedures, failure to attempt LAMS placement is not well characterized in existing literature. Little is known about predictors of GATE failure in patients with RYGB anatomy.

In the present study, we evaluated pre-procedure radiographic features which may predict a failed GATE procedure and potentially signal the need for an alternative approach. We found that indicators of poor contact between the gastric pouch or jejunum and remnant stomach such as thickened tissue (i.e. no contact or approximately 1 cm distance between the excluded stomach and gastric pouch/jejunum), calcification (linear or dystrophic), intervening surgical material such as staples or sutures, or intervening vasculature may lead to a higher risk of GATE failure. Additionally, the cumulative number of these radiographic risk factors was associated with GATE failure, with two or more risk factors increasing the likelihood of the procedure being aborted. This knowledge may optimize clinical decision-making and/or alternative management approaches in patients with a high likelihood of undergoing a failed procedure.

It is important to recognize the dynamic nature of these procedures and changes in the anatomy which may be visualized following contrast injection and prior to LAMS placement. Interestingly, several endoscopic, endosonographic, and fluoroscopic features were reasons for GATE failure. In this cohort, extreme tip deflection of the echoendoscope, long distances to the excluded stomach, inability to expand and/or maintain appropriate expansion of the remnant stomach with fluid/contrast injection, or inability to avoid intervening vessels in the desired pathway for stent placement were all noted as reasons for case abortion. Prospective studies to evaluate these findings considering predictive radiographic features are underway.

There are several limitations to this study. First, this study was conducted at a single tertiary care center with expertise in complex therapeutic endoscopy, a large volume of patients undergoing GATE/EDGE procedures, and the input of a second advanced endoscopist regarding decisions to proceed with GATE. As a result, the number of aborted cases may be higher at centers with lower volumes of cases. Patients with surgical sleeve gastrectomy prior to RYGB were excluded from the analysis and may have led to higher failure rates. As is known, patients with this anatomy have small excluded stomachs, which intuitively disadvantages this cohort from a successful procedure which could bias the results of radiographic review. Furthermore, the relatively small sample size may statistically limit the identification of all predictors of GATE failure. Additionally, all computed tomography images were reviewed by a single, blinded abdominal radiologist with experience in altered surgical anatomy and pancreaticobiliary disease. This level of expertise may not be widely available. Finally, given the dynamic intraprocedural nature of GATE, it is possible that despite radiographic features suggesting GATE failure, some procedures may ultimately be successful.

In summary, several radiographic features may be predictive of GATE failure including intervening vasculature or insufficient contact between gastric pouch/blind or roux limb and remnant stomach. A thorough review of cross-sectional imaging before offering GATE procedures may minimize the risk of GATE failure and streamline patient care. In patients who demonstrate these radiographic features, alternate approaches should be considered early in management.

References:

1. Amer S, Horsley-Silva JL, Menias CO, et al. Endoscopic retrograde cholangiopancreatography in patients with surgically altered gastrointestinal anatomy. *Abdom Imaging*. 2015 Oct;40(8):2921-31. doi: 10.1007/s00261-015-0532-7. PMID: 26304586.
2. Sharma P, McCarty TR, Chhoda A, et al. Alternative uses of lumen apposing metal stents. *World J Gastroenterol*. 2020 Jun 7;26(21):2715-2728. doi: 10.3748/wjg.v26.i21.2715. PMID: 32550749; PMCID: PMC7284179.
3. Kedia P, Shah-Khan S, Tyberg A, et al. Endoscopic ultrasound-directed transgastric ERCP (EDGE): A multicenter US study on long-term follow-up and fistula closure. *Endosc Int Open*. 2023 May 26;11(5):E529-E537. doi: 10.1055/a-2057-5984. PMID: 37251793; PMCID: PMC10219784.
4. Tyberg A, Nieto J, Salgado S, et al. Endoscopic Ultrasound (EUS)-Directed Transgastric Endoscopic Retrograde Cholangiopancreatography or EUS: Mid-Term Analysis of an Emerging Procedure. *Clin Endosc*. 2017 Mar;50(2):185-190. doi: 10.5946/ce.2016.030. Epub 2016 Sep 19. PMID: 27642849; PMCID: PMC5398356.
5. Ngamruengphong S, Nieto J, Kunda R, et al. Endoscopic ultrasound-guided creation of a transgastric fistula for the management of hepatobiliary disease in patients with Roux-en-Y gastric bypass. *Endoscopy*. 2017 Jun;49(6):549-552. doi: 10.1055/s-0043-105072. Epub 2017 Apr 10. PMID: 28395382.
6. Wang TJ, Thompson CC, Ryou M. Gastric access temporary for endoscopy (GATE): a proposed algorithm for EUS-directed transgastric ERCP in gastric bypass patients. *Surg Endosc*. 2019 Jun;33(6):2024-2033. doi: 10.1007/s00464-019-06715-z. Epub 2019 Feb 25. PMID: 30805786.
7. Khara HS, Parvataneni S, Park S, et al. Review of ERCP Techniques in Roux-en-Y Gastric Bypass Patients: Highlight on the Novel EUS-Directed Transgastric ERCP (EGDE) Technique. *Curr Gastroenterol Rep*. 2021 Jul 1;23(7):10. doi: 10.1007/s11894-021-00808-3. PMID: 34212281; PMCID: PMC8249251.

Figures and Figure Legends

Figure 1: Anterior orientation of remnant stomach relative to herniated gastric pouch

P: gastric pouch; RS: remnant stomach. Unusual orientation (bracket) of remnant stomach anterior to the gastric pouch, with a small pouch secondary to herniation (arrow)

Figure 2: Contact-related risk factors between gastric pouch and remnant stomach

P: gastric pouch; RS: remnant stomach. Arrows denote (A) intervening vessel, (B) thick intervening tissue, (C) intervening surgical material, (D) poor/short segment contact

Figure 3: Cumulative number of contact-related risk factors was associated with GATE failure

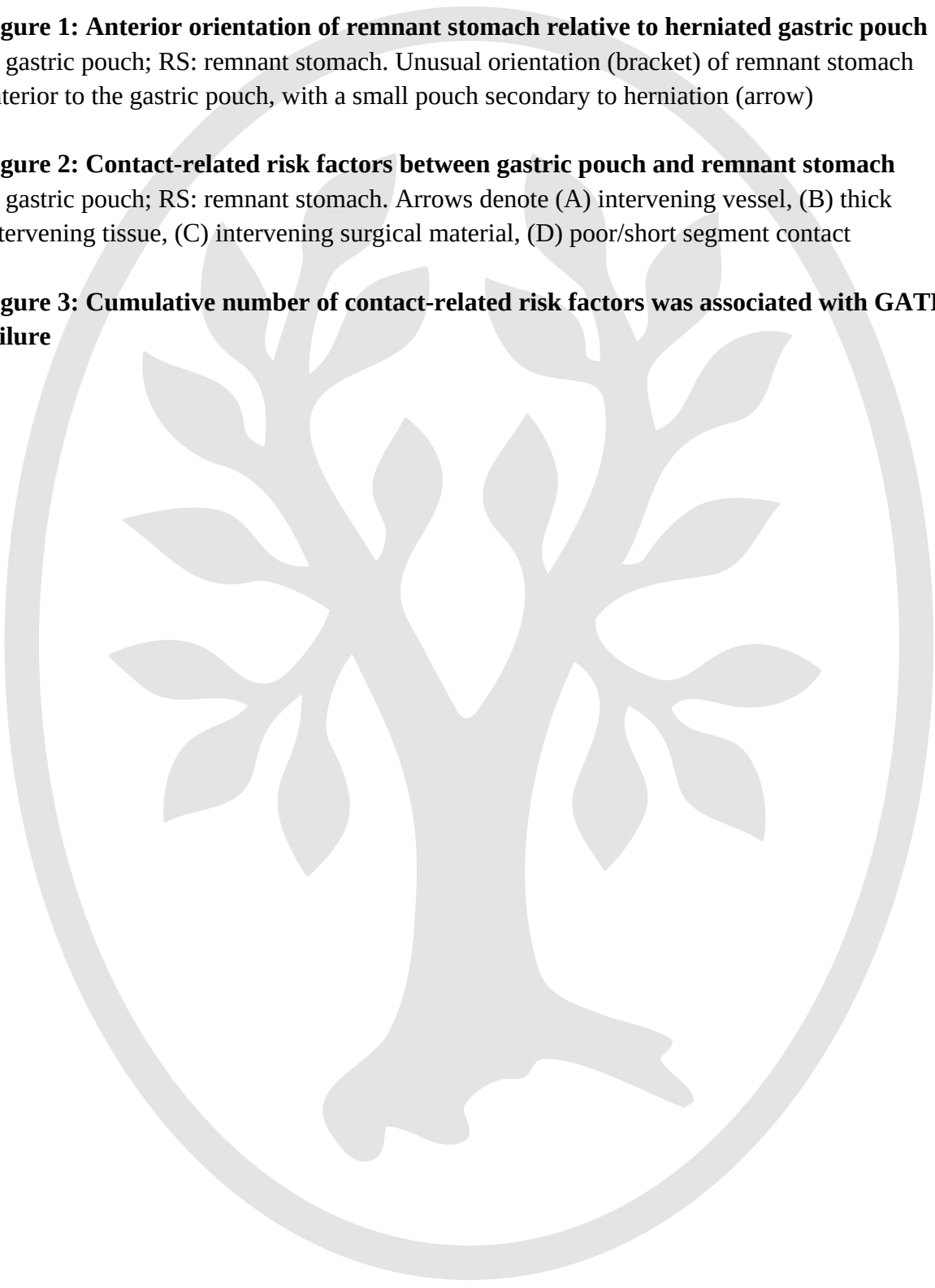


Table 1. Cohort demographics and baseline characteristics

Characteristic	GATE failure (n=10)	GATE success (n=30)
Age, years (mean±SD)	60.9±12.5	63.4±11.8
Sex, Female	10 (100)	23 (76.7)
Time since bypass, years (mean±SD)	18.7±10.2	14.0±7.9
Procedure setting		
Inpatient	9 (90)	18 (60)
Outpatient	1 (10)	12 (40)
Pouch length, cm (mean±SD)	6.2±3.2	5.9±1.6

Values presented for categorical characteristics are n (%)

Table 2. Radiographic length, location, and orientation of the gastric pouch/blind limb and remnant stomach in patients undergoing GATE

	GATE failure (n=10)	GATE success (n=30)
Pouch length, cm (mean±SD)	6.2±3.2	5.9±1.6
Blind limb length, cm (mean±SD)	4.5±2.5	3.3±1.5
Location of remnant stomach relative to gastric pouch		
Anterior	2 (20)	5 (16.7)
Posterior	0	1 (3.3)
Inferior	2 (20)	2 (6.67)
Superior	0	0
Right lateral	0	1 (3.3)
Left lateral	5 (50)	18 (60)
No contact	1 (10)	1 (3.3)
Not seen	0	2 (6.67)
Location of remnant stomach relative to blind limb		
Anterior	0	4 (13.3)
Posterior	1 (10)	2 (6.67)
Inferior	0	5 (16.7)
Superior	0	0
Right lateral	1 (10)	0
Left lateral	1 (10)	6 (20)
No contact	3 (30)	9 (30)
Not seen	4 (40)	4 (13.3)
Location of remnant stomach relative to roux limb		
Anterior	1 (10)	5 (16.7)
Posterior	0	3 (10)
Inferior	1 (10)	5 (16.7)
Superior	0	1 (3.3)
Right lateral	2 (20)	2 (6.67)
Left lateral	1 (10)	3 (10)

No contact	3 (30)	9 (30)
Not seen	2 (20)	2 (6.67)

Values presented for categorical characteristics are n (%)



Table 3. Cumulative number of contact-related risk factors associated with GATE failure

	Number of risk factors					
	0	1	2	3	4	Total
GATE failure	1	3	3	2	1	10
GATE success	26	4	0	0	0	30
Total	27	7	3	2	1	40

