

58–61

Intraoperative neuromonitoring: lessons learned from 32 case events in 2095 spine cases

Authors Matthew Eager, Faisal Jahangiri, Adam Shimer, Francis Shen, Vincent Arlet

Institution University of Virginia Health System, Department of Orthopaedic Surgery, Division of Spine Surgery, Charlottesville, Virginia, USA

ABSTRACT

Study type: Restrospective chart review

Introduction: Intraoperative neuromonitoring is becoming the standard of care for many more spinal surgeries, especially with deformity correction and instrumentation. We reviewed our institution's neuromonitored spine cases over the past 4 years to see the immediate intraoperative and postoperative clinical findings when an intraoperative neuromonitoring event was noted.

Objective: The main question addressed in this review is how multimodality intraoperative neuromonitoring has affected our ability to avoid potential neurological injury during spine surgery.

Methods: We retrospectively reviewed 2,095 neuromonitored spine cases at one institution performed over a period of 4 years. Data from the single neuromonitoring provider (Impulse Monitoring, Inc.) at our institution was collected and any cases with possible intraoperative events were isolated. The intraoperative and immediate postoperative clinical documentation of these 32 cases were reviewed (**Table 1**).

Results: There were 17 cases where changes noted on EMG, SSEP, and/or MEPs affected the course of the surgery, and prevented possible postoperative neurological deficits. Of these 17, five were related to hypotension, seven due to deformity correction, one screw had a low triggered EMG threshold and was repositioned, and four cases had changes related to patient positioning and external pressure (ie, brachial plexus stretch). None of the 17 cases had postoperative motor or sensory deficits (**Figure 1**).

No funding was provided to perform this study. This study has been IRB approved.

Four cases consisted of intradural cord biopsies or tumor resections that had various positive neuromonitoring findings that essentially serve as controls. These cases confirm that the expected changes were seen on neuromonitoring. Four cases had false-positive neuromonitoring findings due to one technical issue requiring needle repositioning, one low threshold with triggered EMG without a pedicle breach, one case had decreased MEP responses with stable SSEPs, and one case had decreased SSEPs after positioning the patient prone. None of these four cases had any postoperative deficits. Four cases showed improved SSEPs after decompression; three cervical corpectomies, and one thoracic discectomy.

Three cases of lumbar instrumentation with spontaneous EMGs each had a medial screw breach without intraoperative findings (**Figure 2**). They all had a postoperative motor deficit (foot drop). None of these three cases had triggered EMGs performed with the index procedure.

Conclusions: Overall, this review reinforces the importance of multimodality neuromonitoring for spinal surgery. The incidence of possible events in our series was 1.5%. It is difficult to determine the true incidence, since it is impossible to know of any missed events due to lack of complete documentation. In a majority of the cases with events, possible postoperative neurologic deficits were avoided by intraoperative intervention, but the possible outcomes without intervention are not known. Clearly, in the three cases with lumbar pedicle screw malposition, triggered EMGs would have likely shown low thresholds. This would allow for screw reposition, and thus avoid a postoperative lumbar radiculopathy and revision surgery. The incidence of false-positive findings was very low in this review, and unfortunately the true incidence of false-negative findings is not able to be elucidated with this database.

Figure 1 During the insertion of the convex rod: decrease of the MEP amplitude in left foot by 80% amplitude (yellow arrow). The baseline recording is in blue, the current recording in purple. The right side (non represented) will remain normal.

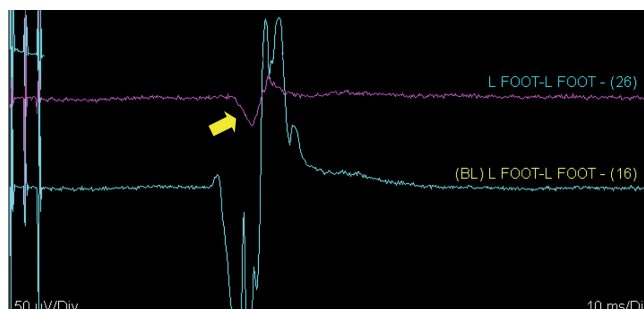


Figure 2 Left L4 pedicle screw medial breach. Triggered EMGs were not performed during the index procedure. Postoperative foot drop required a second surgery to reposition the screw.

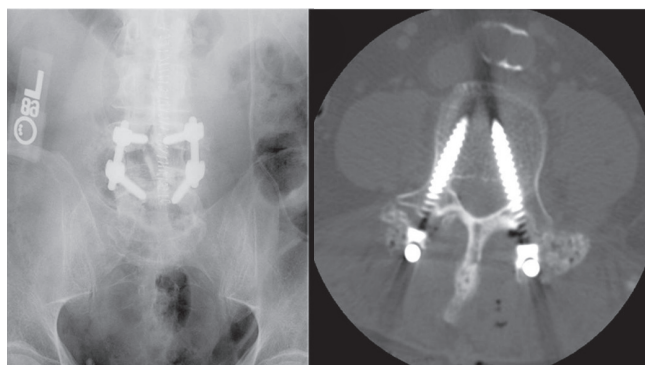


Table 1 Summary of each case event with the type of procedure, intraoperative findings, intraoperative intervention, and postoperative findings

Case	Procedure	Intraoperative findings	Intraoperative intervention	Postoperative findings
1	Posterior cervical decompression	Loss of MEP	Increased blood pressure	No deficit
2	Cervicothoracic spinal cord lesion biopsy	Loss of MEP in lower extremities	None	Bilateral lower extremity paresis
3	Thoracic spinal cord tumor debulking	Loss of MEP in right lower extremity	None	Right lower extremity paralysis
4	Posterior lumbosacral decompression/fusion TLIF	Low S1 screw threshold	Screw checked, repositioned	No deficit
5	Posterior lumbar decompression/fusion	None	None	Foot drop, medial L4 screw breach
6	Cervicomedullary spinal cord tumor resection	Loss of left upper extremity SSEP	None	Left upper extremity sensory deficit
7	Anterior thoracic discectomies/partial corpectomies	Left upper extremity decreased SSEP	Arm pressing on arm, removed	No deficit
8	Posterior lumbosacral decompression/fusion TLIF	Right upper extremity decreased SSEP	Arm repositioned	No deficit
9	C7–T1 anterior decompression/fusion	Right lower extremity decreased MEP	Increased blood pressure	No deficit
10	T11–L5 anterior discectomy/fusion	Right lower extremity decreased SSEP, MEP	Increased blood pressure	No deficit
11	Posterior thoracolumbar decompression/fusion TLIF	Left lower extremity decreased SSEP	Increased blood pressure	No deficit
12	Posterior thoracolumbar decompression/fusion costotransversectomy T11, T12, L1 partial vertebrectomies	Right lower extremity decreased SSEP, MEP	Stopped procedure, stage 1 of 2	No deficit
13	Posterior thoracolumbar decompression/fusion TLIF	Variable SSEP, MEP	Labile blood pressure	No deficit
14	Posterior occipitocervical decompression/fusion	Right upper extremity decreased SSEP	Positioning effect, arm tucked	No deficit
15	Anterior thoracic osteotomies	Right lower extremity loss of SSEP after graft placement	None	No deficit
16	Posterior thoracolumbar decompression/fusion TLIF	Right lower extremity loss MEP, SSEP stable	None	No deficit
17	Anterior cervical corpectomy and fusion	No baseline SSEPs	None	Improved SSEPs
18	Posterior thoracolumbar decompression/fusion PSO	Bilateral lower extremity SSEPs decreased with rod placement	Rods placed, baseline SSEPs returned	No deficit
19	T7 spinal cord tumor resection	Loss of bilateral lower SSEPs (no MEPs present at baseline)	None	No change from preoperative function
20	Posterior then anterior cervicothoracic fusion	Decreased SSEPs post flip	None	No deficit
21	Anterior thoracolumbar decompression/fusion	Thoracotomy, left upper extremity (down arm) loss SSEPs	Repositioned, large pt, procedure shortened	Transient sensory changes
22	Posterior thoracolumbar decompression/fusion TLIF	Right lower extremity loss of MEP	Needle repositioned, signals reacquired	No deficit
23	Posterior thoracic fusion	Bilateral lower extremity loss of MEP with distraction	Variable signal changes, returned to baseline	No deficit
24	Posterior thoracolumbar deformity correction with fusion	Left lower extremity decreased SSEP, loss of MEP during correction	Correction held, increased blood pressure	No deficit
25	Posterior cervicothoracic deformity correction with fusion	Bilateral lower extremity loss of MEP, decreased SSEPs	Correction decreased	No deficit
26	Posterior lumbosacral decompression/fusion	Low screw threshold	No breach, screw replaced	No deficit
27	Posterior lumbosacral decompression/fusion TLIF	None, spontaneous EMG only	None	Screw in canal
28	Posterior lumbar decompression/fusion	None, spontaneous EMG only	None	Foot drop, medial left L4 screw breach
29	Posterior thoracolumbar deformity correction with fusion	Bilateral lower extremity loss of MEP	Decreased correction	No deficit
30	Anterior cervical corpectomy and fusion	Improved MEP after decompression	None	Improved function
31	Anterior thoracic discectomy and fusion	Improved MEP after decompression	None	Improved function
32	Anterior cervical corpectomy and fusion	Improved MEP after decompression	None	Improved function

REFERENCES

1. **Modi HN, Suh SW, Yang JH, et al** (2009) False-negative transcranial motor-evoked potentials during scoliosis surgery causing paralysis: a case report with literature review. *Spine*; 34(24):E896–900.
2. **Kamerlink JR, Errico T, Xavier S, et al** (2010) Major intraoperative neurologic monitoring deficits in consecutive pediatric and adult spinal deformity patients at one institution. *Spine*; 35(2):240–245.
3. **Hart ES, Grottkau BE** (2009) Intraoperative neuromonitoring in pediatric spinal deformity surgery. *Orthop Nurs*; 28(6):286–292.
4. **Pelosi L, Lamb J, Grevitt M, et al** (2002) Combined monitoring of motor and somatosensory evoked potentials in orthopaedic spinal surgery. *Clin Neurophysiol*; 113(7):1082–1091.
5. **Noonan KJ, Walker T, Feinberg JR, et al** (2002) Factors related to false-verses true-positive neuromonitoring changes in adolescent idiopathic scoliosis surgery. *Spine*; 27(8):825–830.
6. **Langeloo DD, Lelivelt A, Louis Journee H, et al** (2003) Transcranial electrical motor-evoked potential monitoring during surgery for spinal deformity; a study of 145 patients. *Spine*; 28(10):1043–1050.
7. **Strahm C, Min K, Boos N, et al** (2003) Reliability of perioperative SSEP recordings in spine surgery. *Spinal Cord*; 41(9):483–489.
8. **Gonzalez AA, Jeyanandarajan D, Hansen C, et al** (2009) Intraoperative neurophysiological monitoring during spine surgery: a review. *Neurosurg Focus*; 27(4):E6.
9. **Kim DH, Zaremski J, Kwon B, et al** (2007) Risk factors for false positive transcranial motor evoked potential monitoring alerts during surgical treatment of cervical myelopathy. *Spine*; 32(26):3041–3046.
10. **Langeloo DD, Journee HL, de Kleuver M, et al** (2007) Criteria for transcranial electrical motor evoked potential monitoring during spinal deformity surgery. *A review and discussion of the literature. Neurophysiol Clin*; 37(6):431–439.
11. **Murkin JM** (2004) Perioperative multimodality neuromonitoring: an overview. *Semin Cardiothorac Vasc Anesth*; 8(2):167–71.
12. **Pajewski TN, Arlet V, Phillips LH** (2007) Current approach on spinal cord monitoring: the point of view of the neurologist, the anesthesiologist and the spine surgeon. *Eur Spine J*; 16 Suppl 2:S115–129.
13. **Quraishi NA, Lewis SJ, Kelleher MO, et al** (2009) Intraoperative multimodality monitoring in adult spinal deformity: analysis of a prospective series of one hundred two cases with independent evaluation. *Spine*; 34(14):1504–1512.