

# Diagnosis of Polyneuropathies

## Guidelines of the German Society of Neurology

### Authors

D. Heuß<sup>1</sup>, M. Auer-Grumbach<sup>2</sup>, W. F. Haupt<sup>3</sup>, W. Löscher<sup>4</sup>, B. Neundörfer<sup>5</sup>, B. Rautenstrauf<sup>6</sup>, S. Renaud<sup>7</sup>, C. Sommer<sup>8</sup>

### Affiliations

The affiliations are listed at the end of the article.

### Keywords

- polyneuropathies
- definition
- manifestation types
- clinical examination
- differential diagnosis
- neurophysiological examination
- muscle and nerve biopsy
- skin biopsy
- genetic testing
- laboratory tests

### Abstract

The most important recommendations at a glance: History and clinical findings provide the most important data for the classification of polyneuropathies (familial, acute versus chronic course, concomitant disease; involved organ systems, symmetrical versus multifocal etc.) (IV) (C). Electrophysiological examination is necessary to determine the pattern of distribution and the type of lesion (axonal versus demyelinating) in order to detect specific patterns of damage (e.g. conduction blocks) and to assess the resulting degree of muscle damage („denervation“) (B). Laboratory tests should include the most important treatable polyneuropathies (see below) (C). The examination of CSF is useful in the differential diagnosis of inflammatory polyneuropathies (B).

Genetic examinations are warranted in the case of a positive family history for polyneuropathy or in the presence of typical signs of hereditary polyneuropathy (pes cavus or hammer toes).

Nerve biopsies are recommended in the case of suspected treatable polyneuropathy that cannot be diagnosed by other means (e.g. vasculitis, atypical CIDP, amyloidosis). Nerve biopsies should be performed and analysed only in specialized centers (C).

When considering small fiber neuropathy, quantitative sensory testing and quantification of skin innervation are helpful diagnostic instruments.

### Definition

Polyneuropathies (PNP) (Dyck et al. 1993, Mendell et al. 2001, Neundörfer and Heuß 2006, Pestronk 2008) are generalised diseases of the peripheral nervous system (PNS). All elements of the motor, sensory, and autonomic nerves with their Schwann cells and ganglionic satellite

### What's new?

- ▶ Mitofusin-2-(MFN2-)mutations are the most common cause of CMT 2 neuropathies (Verhoeven et al. 2006) (III) (B).
- ▶ Antibodies to MAG or SGPG occur frequently in patients with IgM amyloidosis but their presence alone does not predict occurrence or type of polyneuropathy (Garces-Sanchez et al. 2008) (III) (B).
- ▶ Several new or recently established methods facilitate the diagnosis of small-fiber neuropathy which is not detectable by conventional electrophysiological methods (Sommer and Lauria 2007) (III) (B).
- ▶ Ultrasound and MRI examinations are helpful in the diagnosis of neuropathies according to preliminary studies (Bendszus and Stoll 2005, Nodera et al. 2006, Ito et al. 2007) (III) (B).
- ▶ Serum holo-transcobalamin (HoloTC) is the earliest marker of vitamin B deficiency (Herrmann et al. 2005, Obeid and Herrmann 2007) (IIa) (B).
- ▶ Serum holo-transcobalamin levels following oral application of vitamin B<sub>12</sub> is suitable to examine the resorption on vitamin B<sub>12</sub> (Bor et al. 2004, Bor et al. 2005) (III) (B).

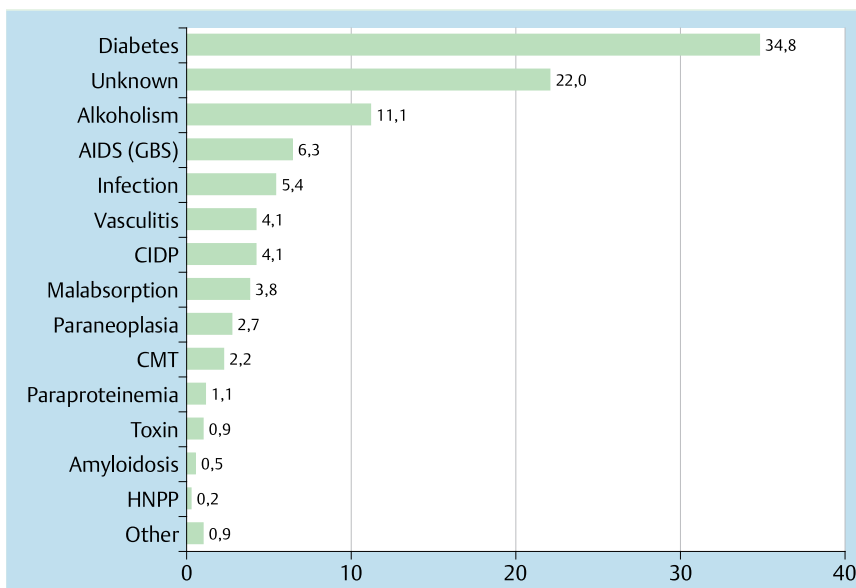
### Bibliography

DOI 10.1055/s-0029-1220453  
 Akt Neurol 2009; 36: e3–e13  
 © Georg Thieme Verlag KG  
 Stuttgart · New York ·  
 ISSN 0302-4350

### Corresponding author

**Prof. Dr. Dieter Heuß**  
 Neuromuskuläres Zentrum,  
 Neurologische Klinik des Uni-  
 versitätsklinikums Erlangen  
 Schwabachanlage 6  
 91054 Erlangen  
 dieter.heuss@uk-erlangen.de

cells, their connective tissue cover structures (peri- and epineurium) and their supplying blood and lymphatic vessels which lie outside of the central nervous system (CNS) belong to the PNS.



**Figure 1** Distribution of etiology in 1195 patients with polyneuropathy (Engelhardt 1994).

## General principles of diagnostics



The basic and complementary examinations in the diagnosis of polyneuropathies can be classified as:

- ▶ **Obligatory examinations**
  - ▶ History
  - ▶ Clinical examination
  - ▶ Neurophysiological examinations
  - ▶ Standard laboratory examinations
- ▶ **Facultative examinations**
  - ▶ Extended laboratory tests
  - ▶ CSF examination
  - ▶ Biopsy of muscle, nerve, or skin
  - ▶ Genetic examinations

## Clinical diagnostics



The clinical diagnosis of a polyneuropathy is based on the history, symptoms reported by the patient, and on the clinical signs.

### Important questions in history taking

#### Sensory plus-symptoms and deficits

- ▶ Tingling
- ▶ Pins and needles sensations
- ▶ Warm and cold paraesthesias
- ▶ Stabbing pain
- ▶ Electrifying feeling
- ▶ Numbness
- ▶ Feeling of constriction
- ▶ Swollen feeling
- ▶ Feeling of unpleasant pressure
- ▶ Feeling of walking on cotton
- ▶ Unstable gait, especially in the dark
- ▶ Loss of temperature sensation
- ▶ Painless skin injuries

#### Motor irritation and loss of function phenomena

- ▶ Fasciculations
- ▶ Muscle contractions
- ▶ Muscle cramps

- ▶ Muscle weakness
- ▶ Muscle atrophy

#### Loss of autonomic function

See [table 1](#)

### Specific history

#### Course and duration of complaints

The course of disease is relevant for the diagnosis

- ▶ <4 weeks: acute
- ▶ 4–8 weeks: subacute
- ▶ <8 weeks: chronic

Examples: Guillain-Barré syndrome (GBS) *acute*, chronic inflammatory demyelinating polyneuropathy (CIDP) *acute to subacute*, hereditary motor and sensory polyneuropathy (CMT) *chronic* with positive family history

#### Cave

vasculitic polyneuropathies can develop over years and infiltration of the PNS with lymphoma cells (neurolymphomatosis) can present as an acute axonal or demyelinating polyneuropathy.

### Questions concerning impairment or concomitant diseases

- ▶ Sports abilities as a child, problems when purchasing shoes
- ▶ Frequent stumbling (distal weakness?)
- ▶ Trouble when rising from low chairs, from squatting and when climbing stairs (proximal weakness)
- ▶ Other diseases which might cause polyneuropathies (diabetes, kidney disease, collagenosis, malignant disease) ([Fig. 1](#))
- ▶ Operations (laminectomy etc.)
- ▶ History of medications, illicit drugs, toxins, especially alcohol consumption (Neundörfer 2006)

**Medication-induced polyneuropathies:** Aside from the well-known potentially polyneuropathy-inducing medications (chemotherapy agents, INH, thalidomide, etc.) polyneuropathies have been described due to other medications, previously not

known to be neurotoxic. Statins in some cases produce sensory and sensorimotor polyneuropathies after long-term application which are reversible after discontinuation of the statin (de Langen and van Puijenbroek 2006). Bortezomib (Velcade), a new protease-inhibitor, which is used in the treatment of multiple myeloma, causes painful sensorimotor polyneuropathies which are only partially reversible (Richardson et al. 2006). Linezolid, a new antibiotic of the oxazolidinone group, produces a painful sensorimotor polyneuropathy after long-term application and a toxic opticopathy (Bressler et al. 2004, Rucker et al. 2006). Also, medications which are used in the treatment of neuropathies such as rituximab or tumor necrosis factor blockers, can cause polyneuropathies in rare cases (Richez et al. 2005, Mauermann et al. 2007).

### Systems review

- ▶ Diminished perspiration of extremities or compensatory perspiration of the trunk
- ▶ Disturbances of bowel or bladder function
- ▶ Erectile dysfunction
- ▶ Joint pain
- ▶ Dermatological signs
- ▶ Syncope

### Family history

Ask expressly for disturbances of gait, foot deformities, atrophic (thin) calves

### General examination

- ▶ Skeletal abnormalities: pes cavus, flat feet, hammer toes, scoliosis, kyphosis, Charcot arthropathy, pathological fractures
- ▶ Organomegaly
- ▶ Alterations of the skin and skin appendages: ulcers, pigmentation changes, purpura, loss of leg hair, alopecia, curved nails, thickened nails etc.
- ▶ Sicca syndrome, uveitis, cataracts, optic nerve atrophy, retinitis pigmentosa, hearing impairment

### Neurological examination

#### Examination of somatic nerves

##### Reflexes

- ▶ Diminution or loss of tendon reflexes, especially Achilles tendon reflex

##### Motor impairment

- ▶ Flaccid, atrophic paresis, in the legs, the foot and toe extensors are usually affected earlier and more prominently

##### Sensory loss (large fiber neuropathy)

- ▶ Distally more prominent impairment or loss of tactile and pain sensation in glove and stocking distribution, in advanced cases including the belly
- ▶ Impairment or loss of vibration sense (pallesthesia)
- ▶ Graphyphesthesia or -anesthesia
- ▶ Impairment of position sense

##### Sensory loss (small fiber neuropathy)

- ▶ Thermal hypesthesia
- ▶ Hyp- or analgesia

**Table 1** Results of autonomic nerve tests.

<b>Effects of efferent autonomic denervation</b>	
Somatic nerves	
– Pupillary abnormalities	
– Trophic disturbances: edema, ulcers, osteoarthropathy	
– Hyp- and anhidrosis	
– Vasomotor dysfunction: orthostatic hypotension, rubeosis plantarum	
Visceral nerves	
– Cardiovascular: resting tachycardia, unmodulated heart rate	
– Gastrointestinal: dystonia of oesophagus, gastric paresis, diarrhea, obstipation, gall bladder dysfunction	
– Liver: disturbance of glucose metabolism	
– Exocrine pancreatic function: loss of reflectory secretion	
– Urogenital: Loss of bladder control, erectile dysfunction, retrograde ejaculation	
<b>Effects of afferent autonomic denervation</b>	
– Loss of pain in cardiac ischemia	
– Loss of vegetative reaction in hypoglycaemia	
– Loss of bladder filling sensation	
– Loss of scrotal pain	
– Loss of labor pain	

**Table 2** Polyneuropathies with autonomic involvement (modified after McDougall and McLeod 1996).

<b>Pronounced autonomic involvement</b>	
– Acute pandysautonomia	
– Diabetic polyneuropathy	
– Polyneuropathy in amyloidosis	
– GBS	
– Porphyric polyneuropathy	
– Hereditary sensory-autonomic neuropathy (HSAN) type III (familial dysautonomia, Riley-Day syndrome)	
– Hereditary sensory-autonomic neuropathy (HSAN) type IV	
– Paraneoplastic polyneuropathy	

### Involvement of cranial nerves

- ▶ Cranial nerve VII (e.g. in GBS, CIDP, sarkoidosis, borreliosis)
- ▶ Cranial nerves IX and X (e.g. in GBS, diphtheria)
- ▶ Extraocular muscles (diabetic ophthalmoneuropathy, Miller-Fisher syndrome)
- ▶ Cranial nerve VIII (hearing loss, hearing impairment in hereditary neuropathy)

### Examination of autonomic nerves

See [table 1](#) and [table 2](#)

### Types of manifestation

Polyneuropathies are classified according to their temporal development (see „special history“) according to the involved systems (motor/sensory/autonomic/sensorimotor) and with respect to the distribution of signs (symmetrical/asymmetrical).

#### Distal symmetrical distribution type

- ▶ Symmetrical-sensory type
    - ▶ symmetrical predominant distal sensory deficit
    - ▶ reflex diminution or loss, usually beginning with Achilles tendon reflex loss
- Examples: alcoholic PNP, nephrogenic PNP, most diabetic PNPs, chronic axonal PNP of unknown etiology

The differential impairment of certain sensory qualities can be indicative of specific etiologies. In amyloid PNP one often finds

Sensomotor		pure sensory	
familial	acquired	familial	acquired
CMT 2	Diabetes	HSAN I–IV	cisplatin, oxaliplatin nitrates
Porphyria	Alcohol		
	Uremia		pyridoxin
	Axonal variant of GBS		paraneoplastic (Denny Brown)
	Amyloidosis		Sjögren Syndrome
	Vitamin B <sub>12</sub> deficiency	Spinocerebellar degeneration	idiopathic sensory polyneuropathy
	Metronidazol		nucleoside analogs
	Bortezomib		thalidomide
	Linezolik		
	Arsennic	SMA type Kennedy	

**Table 3** Main causes of polyneuropathies with axon loss (modified after Wilbourn 2000).

dissociated sensory loss with reduced pain sensation and preserved surface sensory function.

**Subtype small fiber neuropathy:** Distally pronounced sensory loss and pain without further signs.

▶ **Symmetrical-sensorimotor manifestation type**

- ▶ symmetrically distributed sensory and motor signs or predominantly motor impairment  
Examples: GBS, acute intermittent porphyria, hereditary motor and sensory neuropathies, critical illness PNP (CIP)

Some of these PNP develop symmetrical-sensory manifestation types.

▶ **Distal symmetrical PNP with marked autonomic disturbances**

- ▶ sensory or sensorimotor PNP with marked autonomic disturbances  
Examples: Amyloid PNP, diabetic autonomic neuropathy, hereditary sensory and autonomic neuropathy (HSAN)

### Asymmetrical manifestation types

- ▶ **Mononeuropathia multiplex** with functional loss according to the distribution of single peripheral nerves
- ▶ **Focal PNP** with additional symmetrical-sensory and /or symmetrical motor distally located functional impairment  
Examples: vasculitic neuropathy, diabetic amyotrophy, multifocal motor neuropathy (MMN), Lewis-Sumner syndrome, Borrelia neuropathy (Bannwarth syndrome), zoster neuritis, neuralgic amyotrophy

#### Cave

Caution is needed in the differential diagnostic attribution to a certain manifestation type. For example, the clinical manifestation type in morphologically proven vasculitis can often be symmetrical-sensory.

### Proximal or proximal and distal distribution

- ▶ proximal: plexus neuritis, proximal diabetic neuropathy
- ▶ proximal and distal: GBS, CIDP, porphyria (radicular involvement)

### Neurophysiological examination

In addition to the clinical examination, the neurophysiological examination is suitable to demonstrate the presence of a generalized lesion of the peripheral nervous system, to determine the distribution (symmetrical or asymmetrical PNP, focal PNP) and to demonstrate subclinical involvement of the sensory system in motor neuropathies (and vice versa).

**Table 4** Main causes of demyelinating polyneuropathies (modified after Wilbourn 2000).

familial	acquired
CMT 1, and 4	AIDP (acute inflammatory demyelinating polyneuropathy, GBS)
CMTX	CIDP (chronic inflammatory demyelinating polyneuropathy)
HNPP	CIDP variants, e. g. PNP in MGUS, POEMS

Differentiation between polyneuropathies with axonal lesions („axonal polyneuropathy“, ◉ **table 3**) and polyneuropathies with lesions of the myelin sheath („demyelinating polyneuropathy“, ◉ **table 4**) is also desirable. This can be limited, however, since in the case of loss of large and fast conduction fibers a marked slowing of nerve conduction velocity can be present, mimicking „demyelinating“ polyneuropathy.

### Differentiation of axonal PNP, demyelinating PNP and conduction block Axonal neuropathies

#### Findings on nerve conduction studies

- ▶ Generalized reduction of the amplitude of compound motor action potentials (CMAP) on proximal and distal stimulation; reduction of sensory nerve action potential amplitudes (SNAP)
- ▶ Facultative: reduction of the nerve conduction velocity (NCV) by a maximum of 30% below the age-specific lower limit of normal

#### Electromyographic findings

- ▶ Acute lesion
  - ▶ spontaneous activity (fibrillations, positive sharp waves)
- ▶ Chronic lesion
  - ▶ motor unit potentials duration increased
  - ▶ motor potential amplitude increased
  - ▶ phase count increased
  - ▶ detectable satellite potentials

#### Demyelinating neuropathies

- ▶ Distal latency prolonged
- ▶ NCV reduced
- ▶ CMAP amplitude reduced and CMAP duration increased on proximal stimulation
- ▶ F-wave latencies increased, increased chronodispersion

## Conduction block (CB)

- ▶ All definitions concerning conduction block have only class IV evidence
- ▶ The criteria should show high sensitivity so as not to overlook a treatable disease
- ▶ For clinical studies, the criteria should show high sensitivity

### Criteria for CB

(Heuß et al. 2002, Olney et al. 2003, European Federation of Neurological Societies 2006):  
definitive CB

- ▶ reduction of the amplitude of the proximal CMAP > 50%, in the presence of < 30% increased duration of the CMAP or
- ▶ reduction of the area of the proximal CMAP > 50% probable CB
- ▶ reduction of the amplitude of the proximal CMAP > 40% in the arm or > 50 in the leg regardless of the potential duration

### Cave

- ▶ Signs of CB not to be examined at predilection sites for compression syndromes
- ▶ Normal sensory NCV of the arms in nerve segments with CB in multifocal motor neuropathy

- ▶ High voltage stimulation enables supramaximal stimulation of proximal nerve segments, this procedure can produce valuable additional information (Jaspert et al. 1995).

## Nerve conduction studies (NCS)

### Sensory nerve conduction studies in legs

- ▶ sural nerve
- ▶ superficial peroneal nerve

Orthodromic and antidromic examinations of the sural nerve are equally valid; under difficult examination circumstances (e.g. edema) the examination of the sural nerve using needle electrodes produces more reliable results albeit with the loss of amplitude information.

### Sensory nerve conduction studies in arms

- ▶ median nerve
- ▶ ulnar nerve

### Cave

Watch out for nerve lesions due to additional entrapment syndromes.

- ▶ superficial radial nerve

### Cave

This nerve is affected later in distal symmetrical PNP. Advantage: only rarely affected by nerve entrapment syndromes and orthodromic as well as antidromic studies are easily performed.

### Motor nerve conduction studies in the legs

- ▶ peroneal nerve

### Cave

Pressure lesion at the fibular head?

- ▶ tibial nerve

### Cave

Supramaximal stimulation in the hollow of the knee not always possible.

Recommendation: Measurement first of the peroneal nerve, if needed, also of the tibial nerve. To demonstrated bilateral lesions measure the peroneal nerve on one side and the tibial nerve on the other.

### Motor nerve conduction studies in the arms

- ▶ Median nerve

### Cave

Carpal tunnel syndrome?

- ▶ ulnar nerve

### Cave

cubital tunnel syndrome?

Nerve conduction studies of motor nerves → involvement of proximal segments? → examine late responses such as F-waves and/or H-reflex; conduction blocks see above.

## Electromyography

- ▶ Examination of skeletal muscles with the question of neurogenic action potential changes
  - ▶ anterior tibial muscle
  - ▶ abductor hallucis or first dorsal interosseus muscle if no pathologic findings in the anterior tibial muscle are present

### Cave

Even in healthy persons, fibrillations and positive sharp waves can be encountered in the intrinsic foot muscles

- ▶ facultative examination of proximal muscles (vastus medialis or iliopsoas muscles) and of muscles of the upper extremity to estimate the extent of the lesion
- ▶ in symmetrical polyneuropathies, the bilateral examination has no further value with respect to the differentiation between axonal and demyelinating polyneuropathies
- ▶ in asymmetrical polyneuropathies, the selection of muscles and nerves to be examined should be made according the distribution of symptoms and signs

## Other procedures

Nerve conduction studies and electromyography are supplemented by methods which can provide additional information on the involvement of different fiber classes

- ▶ vibration sense: tuning fork examination
- ▶ lesions of thinly myelinated A-delta fibers (cold sensation) and unmyelinated C-fibers (heat sensation) → quantitative sensory testing (QST) of hands and feet; heat-evoked potentials (contact heat evoked potentials CHEPs) (Atherton et al. 2007); pain evoked potentials (pain related potentials, PREPs) (Obermann et al. 2007)
- ▶ cardiac autonomic neuropathy → determination of heart rate variability (HRV) in deep inspiration, Valsalva manoeuvre, Schellong test (tilt table examination)
- ▶ Lesions of sudomotor fibers → iodine-starch test, sympathetic skin response (SSR), quantitative sudomotor axon reflex testing (QSART)

### Laboratory tests in polyneuropathies

The laboratory tests should be restricted at first to frequent and treatable causes of polyneuropathies (▶ **table 5**). If these tests are negative or do not explain the extent of the polyneuropathy, further examinations should be added according to probable diagnosis established by clinical and electrophysiological examinations (▶ **table 6** and ▶ **table 7**).

### Genetic tests

Genetic tests can be helpful in the case of positive family history of polyneuropathies or in the presence of typical signs of hereditary PNP (pes cavus, hammer toes) (Neundörfer et al. 2006, Pestronk 2008) and are indicated when the differential diagnosis to other etiologies, specifically to inflammatory PNP is not clear. In the case of demyelinating hereditary PNP, the diagnosis of CMT type IA is highly probable. Here, a 1.4 Mb tandem duplication on chromosome 17p11.2–12 is frequently found which contains the *peripheral-myelin-protein-22 (PMP22)* gene. In „hereditary neuropathy with pressure palsies“ (HNPP) one finds a deletion of the *PMP22* gene which is reciprocal to the CMT IA duplication.

**Table 5** Basic laboratory investigation.

Basic diagnostics	ESR, CRP, differential blood count, liver and kidney values immunofixation, Bence Jones protein, TSH, Vit. B <sub>12</sub>
Suspicion of diabetes	fasting blood glucose, oral glucose tolerance test, glucose day profile, HbA <sub>1c</sub> as a long-term marker
Suspicion of alcoholism	Transaminases, MCV, CDT, Vitamins

**Table 6** Specialized laboratory investigation.

Disease	clinical signs	diagnostics
Funicular myelosis	impaired position sense ataxia, SEP delayed	Vitamin B <sub>12</sub> , in cases of low normal serum values test methylmalonic acid with the question of metabolic vitamin B <sub>12</sub> deficiency; Schilling test holo-Transcobalamin after oral B <sub>12</sub> , gastroscopy, parietal cell antibodies intrinsic factor antibodies
Malabsorption or Malresorption	weight loss	Xylose test Vitamins B <sub>1</sub> , B <sub>6</sub> , B <sub>12</sub> , E serum folic acid
Vasculitis	pre-existing rheumatic disease or systemic vasculitis asymmetric polyneuropathy subacute progressive paresis	rheumatic factors, ANA (if positive, ds DNA and ENA screening, p-, c- ANCA, C3, C4, C3d circulating complexes (CIC), kryoglobulines, hepatitis markers, eosinophilia
Neuroborreliosis	history of tick bite and / or Erythema chronicum migrans radiculoneuritis	anti-Borrelia antibodies in serum and CSF (serum IgM antibodies are sufficient, can be years after treated borreliosis)
Other infectious agents	Leprosy, HIV, others	„slit skin smear“ (Lepra) Serological test for mycoplasma, CMV, HIV Epstein-Barr, varicella zoster, toxin test for C. diphtheriae
Cryoglobulinemia		cryoglobulins
Paraproteinemia	chronic or subacute PNP in multiple myeloma, M. Waldenström, solitary plasmocytoma, systemic AL amyloidosis, (lambda or kappa immunoglobuline light chain), POEMS, cryoglobulinemia, monoclonal gammopathy of uncertain significance (MGUS)	immune electrophoresis immune fixation, Bence-Jones protein, 24 h urine, anti-MAG antibodies in IgM paraproteinemia – bone marrow biopsy – x-ray bones
Sarcoidosis	pulmonary involvement	angiotensin-converting enzyme (ACE) in serum
Multifocal motor neuropathy (MMN)	pure motor neuropathy conduction blocks	IgM anti-GM1 antibodies
GBS	rapidly ascending predominantly motor neuropathy	Campylobacter jejuni-, CMV-, and ganglioside antibodies, CSF (▶ <b>Tab. 7</b> ) anti-GQ 1b antibodies
Miller-Fisher syndrome	ataxia and ocular paresis	
CIDP	subacute demyelinating PNP	immune electrophoresis, CSF (▶ <b>Tab. 7</b> )
Malignant tumor	loss of weight, nocturnal sweating sensory neuropathy, Denny-Brown syndrome	hemocult test, anti-Hu antibodies, anti CV2 antibodies, immune electrophoresis
Hypoparathyroidism		Ca <sup>++</sup> , anorganic phosphate, parathormone
Porphyria		delta-aminolevulinic acid, Porphobilinogen
Intoxication		24 hour urine for arsenic, lead, thallium, mercury basophilic stippling of erythrocytes in lead poisoning phytanic acid
Refsum's disease		

**Table 7** CSF (Heuß 2007b).

Disease	clinical signs	diagnostics
AIDP (GBS)	rapidly ascending, predominantly motor PNP	CSF: cell count (< 10), elevated protein
CIDP	subacute demyelinating PNP	CSF: cell count < 10, elevated protein
Lewis-Sumner syndrome (LSS) Multifocal motor Neuropathy (MMN)	LSS: asymmetric sensory / sensorimotor neuropathy, usually arms MMN: asymmetric motor neuropathy, usually arms	CSF protein usually not or slightly elevated
Neuroborreliosis (Bannwarth's syndrome)	history of tick bite and / or erythema chronicum migrans	Borrelia-antibodies, intrathecal Ig synthesis, protein, Blood / CSF barrier disturbance (Qalb), elevated cell count (pleocytosis), CSF cytology with mixed cell pleocytosis and lymphoplasmacellular pleomorphism
Diabetic PNP		low to medium CSF barrier disturbance (Qalb, elevated protein)
Neurolymphomatosis		CSF cytology

**Table 8** Genetic tests in suspected CMT. The choice of tests depends on the inheritance mode and the neurophysiologic findings; stepwise diagnostic workup from top to bottom.

	Demyelinating	intermediate	axonal
Autosomal dominant	PMP22dup MPZ, PMP22mut NEFL, EGR2, SIMPLE	PMP22del MPZ, DNMT2 NEFL, YARS	MFN2 MPZ NEFL GARS, HSB1, HSPB8
Autosomal recessive	SH3TC2 GDAP1, PRX, FDG4, FIG4	GDAP1	GDAP1, LMNA A / C
x-chromosomal	Connexin-32 (GJB1)	Cx32	Cx32
sporadic	PMP22dup GJB1, MPZ PMP22mut, NEFL	PMP22del MPZ, GLB1 NEFL, DNMT2	MFN2 MPZ, Cx32 NEFL

**Table 9** Genetic examinations in suspected HNPP, an axonal-demyelinating polyneuropathy with pronounced demyelination at predilection sites for compression syndromes; stepwise diagnostic workup from top to bottom.

Autosomal dominant	PMP22del
	PMP22mut, Cx32
	MPZ (P0)

Both of these examinations are reasonably easy to perform and are now considered standard diagnostics. In axonal types (CMT 2), mutations in the *mitofusin-2*-(*MFN2*) gene, *Cx32*-(*GJB1*-) gene or the *MPZ* (*P0*)-gene can be examined. A comprehensive stepwise diagnostic procedure is delineated in [tables 8–11](#).

### Cave

in longstanding disease, sensory signs may be present. Stepwise diagnostics from top to bottom.

The *familial amyloid polyneuropathies* (positive family history? Dissociated sensory deficit? Autonomic disturbances?) are comprised of a heterogeneous group of usually autosomal-dominantly inherited systemic amyloidosis. Normal transthyretin (TTR) has a transport function for thyroxine and retinol. The incidence of the most common transthyretin gene mutation (chromosome 18q11.2–q12.1) with the pathological gene product ATTR varies widely according to geographical aspects. In the USA, the incidence is estimated at 1 : 100 000, and for northern Sweden at 1 : 170. The TTR mutations cause changes of the surface structure of the molecule, which leads to aggregation of molecules and

eventually to the deposit of protein fibrils. The most common form is the Portuguese (Japanese, Swedish) type (Andrade type, familial amyloid polyneuropathy type 1 = FAP1) of the hereditary amyloid polyneuropathy with the mutation Val30Met in the TTR gene.

Other forms are due to mutations in the apolipoprotein-A1-gene and gelsolin-gene.

In most cases, the diagnosis of an amyloid polyneuropathy can be secured by biopsy of the sural nerve. As a first step, biopsy of the rectal mucous tissue can be performed.

### Other Additional Examinations

- ▶ Chest x ray
- ▶ Pulmonary function
- ▶ Extended tumor screening (CT of chest and abdomen or MRI, gynaecological or urological examination, hemocult test, x ray of marrow bones and / or skull and spinal column, esophago-gastroscopy, colonoscopy, bone marrow biopsy (Jamshidi)
- ▶ Rectal biopsy
- ▶ Ophthalmological examination

### Morphological examinations

#### Nerve biopsy

A nerve biopsy is indicated if the cause of a severe and progressive polyneuropathy cannot be diagnosed with less invasive

**Table 10** Genetic examinations in suspected dHMN (distal hereditary motor neuropathies).

	< 10 <sup>th</sup> year of life	> 10 <sup>th</sup> year of life	with additional signs of spasticity
Autosomal-dominant	HSPB1 SETX (plus PBZ)	BSCL2 (Exon3) HSPB8, HSPB1 GARS	BSCL2 (Exon3) SETX GARS
Autosomal-recessive	IGHMBP2 (plus respiratory insufficiency)	GDAP1	GDAP1 LMNA A/C
x-chromosomal	–	–	–
sporadic	HSPB1, SETX (plus spastic signs)	BSCL 2 (Exon3) HSPB8, HSPB1 GARS	BSCL2 (Exon3) SETX GARS

**Table 11** Genetic tests in suspected HSN/HSAN. The autosomal-recessive forms HSN II to V begin very early in life, the autosomal-dominant forms become manifest in adult life. Beside the sensory and autonomic signs, marked pain in distal areas is characteristic. Stepwise diagnostics from top to bottom.

	< 10 <sup>th</sup> year of life	> 10 <sup>th</sup> year of life	special forms
Autosomal-dominant	–	RAB7 (ulcerations!)	
Autosomal-recessive	HSN2 HSN4, HSN5	–	familial dysautonomia KBKAP CIPA (congenital insensitivity to pain and anhidrosis) NTRK1 NGFB CIP (congenital insensitivity to pain) SCN9A
x-chromosomal	–	–	–
sporadic	HSN2 SPTLC1	RAB7 SPTLC1	familial dysautonomia IKBKAP CIPA NTNK1 NGFB CIP SCN9A

methods, and a therapeutical option may be found (Heuß 2006a, Sommer et al. 2008). This is especially important in the case of suspected vasculitis (especially isolated vasculitis of peripheral nerves) because of the necessity of immunosuppressive treatment. In the case of hereditary polyneuropathies, biopsies are becoming less important due to the progress in genetic testing; this is also the case in amyloid polyneuropathy with corresponding family history (liver transplantation!). Possibly the demonstration of inflammatory infiltrates in hereditary neuropathies may provide a treatment option, although there is no sufficient data to support this theory yet.

Since nerve biopsies are an invasive and usually not repeatable procedure, they should be performed and analysed only in specialized centers which can guarantee adherence to standardized methods and thereby render sufficient diagnostic results. In most cases, the sural nerve is biopsied at the distal calf. Alternatively, the superficial peroneal nerve can be biopsied (Collins et al 2000). In the case of suspected vasculitis, the combined nerve-muscle biopsy renders more positive findings than an isolated nerve biopsy (Leuschner et al. 2001, Vital et al. 2006). Fascicular biopsy of the sural nerve should not be performed as the epineural tissue is only contained in a whole nerve biopsy, and the epineural vessels are predominantly affected in vasculitis. The adequate workup of biopsy material should include frozen and paraffin sections as well as resin embedding for semithin slices and (in special cases) for electron microscopy. Immunohistological examinations are needed to demonstrate macrophages and T-cells. In cases of suspected inflammatory etiology,

the preparation of serial sections of the nerve are recommended, to avoid false negative findings. In special cases, teased nerve preparations may be performed to search for segmental demyelination, e.g. in CIDP (Verschuereen 2007).

#### Special indications for nerve biopsies

- ▶ Suspected isolated vasculitic polyneuropathy
- ▶ Sarcoidosis
- ▶ Asymmetric diabetic polyneuropathy (regional PNP, diabetic amyotrophy) → additional vasculitis, perhaps also in other regions of the peripheral nervous system?
- ▶ Suspected CMT or HNPP (hereditary neuropathy with liability to pressure palsies) in the presence of negative family history and negative genetic testing, especially with respect to counselling and for the differential diagnosis of inflammatory PNP.
- ▶ Atypical clinical presentation of CIDP or suspected chronic inflammatory axonal PNP (CIAP)
- ▶ Suspected leprosy
- ▶ Amyloid PNP (possible primary biopsy of rectal mucous tissue)
- ▶ Tumor infiltration, e.g. neurolymphomatosis (infiltration of PNS with lymphoma cells), phenotyping of infiltrating cells necessary
- ▶ Suspected polyglucosan-body disease
- ▶ Storage diseases with involvement of CNS and PNS (e.g. metachromatic leucodystrophy)



## Skin biopsies

In suspected small-fiber-neuropathy with distal pain and sensory loss and normal nerve conduction studies (examination of myelinated nerve fibers), a skin biopsy can be helpful.

The biopsies are usually taken by punch biopsy of 3–5 mm diameter. Typical biopsy locations are the distal calf region and the proximal thigh. According to the distribution pattern, other sites can be used, however, there are few normative data for these sites. The tissue samples are stained with antibodies to the neuronal marker PGP 9.5. This allows quantification of intraepidermal innervation and semiquantitative assessment of the subepidermal nerve plexus as well as the innervation of sweat glands and cutaneous vessels. The quantification of intraepidermal innervation is highly sensitive for the diagnosis of sensory neuropathy in the presence of normal neurophysiology (Koskinen et al. 2005, Vickova-Moracova et al. 2008).

## Special Problems

### What should be examined when diabetes mellitus or alcoholism are probable aetiologies for a polyneuropathy?

In the presence of the following findings another aetiology should be considered at first examination:

- ▶ Predominantly motor deficit
- ▶ Rapid development of signs
- ▶ Marked asymmetry, mononeuropathy, or cranial nerve involvement
- ▶ Progressive signs in spite of optimized metabolism or alcohol abstinence
- ▶ Beginning of signs on the upper extremities
- ▶ Family history of neuropathies
- ▶ Diabetes mellitus and polyneuropathy without other signs of long-term complications (retinopathy, nephropathy). It should be kept in mind that a small-fiber-neuropathy can arise even in pathological glucose tolerance, and that the dogma that only longstanding diabetes leads to polyneuropathy cannot be supported any more (Polydefkis et al. 2003).

In other situations and in the case of subclinical diabetes, the polyneuropathy should be followed up and the primary disease (diabetes, alcoholism) treated.

### Polyneuropathy diagnosed as a chance finding

In the case of polyneuropathy diagnosed by chance, especially in older age, the extent of further diagnostics and treatment should be adjusted to the extent and progression of the clinical findings and the probability of a life-threatening disease. The most common etiologies (diabetes and alcoholism) should always be examined.

### Polyneuropathy of unknown etiology

About 20 percent of polyneuropathies remain etiologically unresolved. At re-examination after 6 months to 1 year, a further third of the cases can be attributed to a cause. The most common diagnoses are: vasculitic PNP, Vitamin B<sub>12</sub> avitaminosis, or PNP in paraproteinemia.

## Expert Group

Prof. Dr. Dieter Heuß, Neurologische Klinik, Universität Erlangen Univ.-Doz. Dr. Michaela Auer-Grumbach, Institut für Humangenetik, Universität Graz  
 Prof. Dr. Walter F. Haupt, Neurologische Klinik, Universität Köln  
 Prof. Dr. Wolfgang Löscher, Neurologische Klinik, Medizinische Universität Innsbruck  
 Prof. Dr. Bernhard Neundörfer, Neurologie Am Stadtpark, Nürnberg  
 Prof. Dr. Bernd Rautenstrauß, Friedrich-Baur-Institut, Ludwig-Maximilians-Universität München  
 PD Dr. Susanne Renaud, Neurologische Klinik, Universitätsspital Basel  
 Prof. Dr. Claudia Sommer, Neurologische Klinik, Universität Würzburg  
 The consensus was achieved by a modified Delphi procedure. English language version prepared by Walter F. Haupt, University of Cologne and revised by D. Heuß and C. Sommer

### Institutsangaben

- <sup>1</sup> Department of Neurology, University of Erlangen
- <sup>2</sup> Institute for Human Genetics, University of Graz
- <sup>3</sup> Department of Neurology, University of Cologne
- <sup>4</sup> Department of Neurology, Medical University of Innsbruck
- <sup>5</sup> Neurologie am Stadtpark, Nuremberg
- <sup>6</sup> Friedrich Baur Institute, Ludwig Maximilian University, Munich
- <sup>7</sup> Department of Neurology, University Hospital, Basle
- <sup>8</sup> Department of Neurology, University of Wuerzburg

### Literature

- 1 Atherton DD, Facer P, Roberts KM, Misra VP, Chizh BA, Bountra C et al. Use of the novel Contact Heat Evoked Potential Stimulator (CHEPS) for the assessment of small fibre neuropathy: correlations with skin flare responses and intra-epidermal nerve fibre counts. *BMC Neurol* 2007; 7: 21
- 2 Bendszus M, Stoll G. Technology insight: visualizing peripheral nerve injury using MRI. *Nat Clin Pract Neurol* 2005; 1: 45–53
- 3 Bor MV, Cetin M, Aytac S, Altay C, Nexo E. Nonradioactive vitamin B<sub>12</sub> absorption test evaluated in controls and in patients with inherited malabsorption of vitamin B<sub>12</sub>. *Clin Chem* 2005; 51: 2151–2155
- 4 Bor MV, Nexo E, Hvas AM. Holo-transcobalamin concentration and transcobalamin saturation reflect recent vitamin B<sub>12</sub> absorption better than does serum vitamin B<sub>12</sub>. *Clin Chem* 2004; 50: 1043–1049
- 5 Bressler AM, Zimmer SM, Gilmore JL, Somani J. Peripheral neuropathy associated with prolonged use of linezolid. *Lancet Infect Dis* 2004; 4: 528–531
- 6 Claus D. Amyloidosen. In: Neundörfer B, Heuß D, Hrsg. *Polyneuropathien*. Stuttgart: Thieme, 2006: 92–97
- 7 Collins MP, Mendell JR, Periquet MI, Sahenk Z, Amato AA, Gronseth GS et al. Superficial peroneal nerve/peroneus brevis muscle biopsy in vasculitic neuropathy. *Neurology* 2000; 55: 636–643
- 8 de Langen JJ, van Puijlenbroek EP. HMG-CoA-reductase inhibitors and neuropathy: reports to the Netherlands Pharmacovigilance Centre. *Neth J Med* 2006; 64: 334–338
- 9 Dyck P, Thomas P, Griffin J, Low P, Poduslo J. *Peripheral neuropathy*, 3rd ed. Philadelphia: W. B. Saunders Company, 1993
- 10 Engelhardt A. *Vaskulitische Neuropathien. Theorie und Forschung Medizin*. Regensburg: Roderer Verlag, 1994
- 11 *European Federation of Neurological Societies*. Peripheral Nerve Society Guideline on management of multifocal motor neuropathy. Report of a joint task force of the European Federation of Neurological Societies and the Peripheral Nerve Society. *J Peripher Nerv Syst* 2006; 11: 1–8
- 12 Garces-Sanchez M, Dyck PJ, Kyle RA, Zeldemrust S, Wu Y, Ladha SS et al. Antibodies to myelin-associated glycoprotein (anti-Mag) in IgM amyloidosis may influence expression of neuropathy in rare patients. *Muscle Nerve* 2008; 37: 490–495

- 13 Herrmann W, Obeid R, Schorr H, Geisel J. The usefulness of holotranscobalamin in predicting vitamin B<sub>12</sub> status in different clinical settings. *Curr Drug Metab* 2005; 6: 47–53
- 14 Heuß D. Morphologische Untersuchungen bei Polyneuropathien – Nerven- und Muskelbiopsie. In: Neundörfer B, Heuß D, Hrsg. Polyneuropathien. Stuttgart: Thieme, 2006a: 19–22, Tafel I–VII
- 15 Heuß D. Untersuchungen des Liquor cerebrospinalis. In: Neundörfer B, Heuß D, Hrsg. Polyneuropathien. Stuttgart: Thieme, 2006b: 32–35, Tafel IX
- 16 Heuß D, Müller-Felber W, Schulte-Mattler W, Dengler R, Toyka K, Sommer C. Diagnostik und Therapie der multifokalen motorischen Neuropathie (MMN) Bundeseinheitliche Konsensuspapiere der Muskelzentren im Auftrag der Deutschen Gesellschaft für Muskelkranke e.V. (DGM). *Nervenheilkunde* 2002; 21: 100–107
- 17 Ito T, Kijima M, Watanabe T, Sakuta M, Nishiyama K. Ultrasonography of the tibial nerve in vasculitic neuropathy. *Muscle Nerve* 2007; 35: 379–382
- 18 Jaspert A, Claus D, Grehl H, Kerling F, Neundörfer B. Wertigkeit der proximalen Leitungsblockuntersuchung in der Diagnostik entzündlicher Neuropathien. *Nervenarzt* 1995; 66: 445–454
- 19 Koskinen M, Hietaharju A, Kylaniemi M, Peltola J, Rantala I, Udd B et al. A quantitative method for the assessment of intraepidermal nerve fibers in small-fiber neuropathy. *J Neurol* 2005; 252: 789–794
- 20 Leuschner T, Probst-Cousin S, Kayser C, Neundörfer B, Heuß D. Reliabilität morphologischer Methoden in der Diagnostik einer vaskulitischen Neuropathie. *Nervenheilkunde* 2001; 40: 20
- 21 Mauermann ML, Ryan ML, Moon JS, Klein CJ. Case of mononeuritis multiplex onset with rituximab therapy for Waldenström's macroglobulinemia. *J Neurol Sci* 2007; 260: 240–243
- 22 McDougall AJ, McLeod JG. Autonomic neuropathy, II: Specific peripheral neuropathies. *J Neurol Sci* 1996; 138: 1–13
- 23 Mendell J, Kissel J, Cornblath D. Diagnosis and management of peripheral nerve disorders. Oxford: Oxford University Press, 2001
- 24 Neundörfer B. Toxische Polyneuropathien. In: Neundörfer B, Hrsg. Polyneuropathien. Stuttgart: Thieme, 2006: 61–77
- 25 Neundörfer B, Heuß D. Polyneuropathien. Stuttgart: Thieme, 2006
- 26 Neundörfer B, Rautenstrauss B. Hereditäre Polyneuropathien. In: Neundörfer B, Heuß D, Hrsg. Polyneuropathien. Stuttgart: Thieme, 2006: 100–109
- 27 Nodera H, Sato K, Terasawa Y, Takamatsu N, Kaji R. High-resolution sonography detects inflammatory changes in vasculitic neuropathy. *Muscle Nerve* 2006; 34: 380–381
- 28 Obeid R, Herrmann W. Holotranscobalamin in laboratory diagnosis of cobalamin deficiency compared to total cobalamin and methylmalonic acid. *Clin Chem Lab Med* 2007; 45: 1746–1750
- 29 Obermann M, Katsarava Z, Esser S, Sommer C, He L, Selter L et al. Correlation of epidermal nerve fiber density with pain-related evoked potentials in HIV neuropathy. *Pain* 2007 Dec 18 [Epub ahead of print]
- 30 Olney RK, Lewis RA, Putnam TD, Campellone JV Jr. Consensus criteria for the diagnosis of multifocal motor neuropathy. *Muscle Nerve* 2003; 27: 117–121
- 31 Pestronk A. Neuromuscular disorders – hereditary neuropathies. [cited; Available from: <http://neuromuscular.wustl.edu/time/hmsn.html>] 2008
- 32 Polydefkis M, Griffin JW, McArthur J. New insights into diabetic polyneuropathy. *J Am Med Ass* 2003; 290: 1371–1376
- 33 Richardson PG, Briemberg H, Jagannath S, Wen PY, Barlogie B, Berenson J et al. Frequency, characteristics, and reversibility of peripheral neuropathy during treatment of advanced multiple myeloma with bortezomib. *J Clin Oncol* 2006; 24: 3113–3120
- 34 Richez C, Blanco P, Laguény A, Schaevebeke T, Dehais J. Neuropathy resembling CIDP in patients receiving tumor necrosis factor-alpha blockers. *Neurology* 2005; 64: 1468–1470
- 35 Rucker JC, Hamilton SR, Bardenstein D, Isada CM, Lee MS. Linezolid-associated toxic optic neuropathy. *Neurology* 2006; 66: 595–598
- 36 Sommer C, Brandner S, Dyck PJ, Magy L, Mellgren SI, Morbin M et al. 147th ENMC international workshop: guideline on processing and evaluation of sural nerve biopsies, 15–17 December 2006, Naarden, The Netherlands. *Neuromusc Disord* 2008; 18: 90–96
- 37 Sommer C, Lauria G. Skin biopsy in the management of peripheral neuropathy. *Lancet Neurology* 2007; 6: 632–642
- 38 Verhoeven K, Claeys KG, Zuchner S, Schroder JM, Weis J, Ceuterick C et al. MFN2 mutation distribution and genotype / phenotype correlation in Charcot-Marie-Tooth type 2. *Brain* 2006; 129: 2093–2102
- 39 Verschueren A. [Immune-mediated neuropathies: indications and value of nerve biopsy]. *Rev Neurol (Paris)* 2007; 163: 3S 58–3S 60
- 40 Vital C, Vital A, Canron MH, Jaffre A, Viillard JF, Ragnaud JM et al. Combined nerve and muscle biopsy in the diagnosis of vasculitic neuropathy. A 16-year retrospective study of 202 cases. *J Peripher Nerv Syst* 2006; 11: 20–29
- 41 Vckova-Moravcova E, Bednarik J, Dusek L, Toyka KV, Sommer C. Diagnostic validity of epidermal nerve fiber densities in painful sensory neuropathies. *Muscle Nerve* 2008; 37: 50–60
- 42 Wilbourn A. Multiple mononeuropathies and polyneuropathies. In: Levin K, Luders HO, eds. *Comprehensive Clinical Neurophysiology*. Philadelphia, London, New York, St. Louis, Sydney, Toronto: W. B. Saunders, 2000: 215–233

Clinical Pathway: Polyneuropathies				Findings/decision criteria Diagnostic/treatment measures
<ul style="list-style-type: none"> <li>o diabetes mellitus</li> </ul>	<ul style="list-style-type: none"> <li>o distal symmetrical PNP</li> </ul>	<ul style="list-style-type: none"> <li><input type="checkbox"/> other etiology excluded</li> </ul>	diabetic PNP	
	<ul style="list-style-type: none"> <li>o asymmetrical phenotype</li> </ul>	<ul style="list-style-type: none"> <li>o indication of other etiology</li> <li>o no indication of other etiology</li> <li>o indication of other etiology</li> </ul>	<ul style="list-style-type: none"> <li>o axonal PNP</li> </ul>	further testing for distal symmetrical PNP without diabetes mellitus  diabetic amyotrophy  further testing for asymmetric phenotype without diabetes mellitus
<ul style="list-style-type: none"> <li>o No diabetes mellitus</li> </ul>	<ul style="list-style-type: none"> <li>o distal symmetrical PNP</li> <li>o distal symmetrical PNP</li> </ul>	<ul style="list-style-type: none"> <li>o asymmetrical phenotype</li> </ul>	<ul style="list-style-type: none"> <li><input type="checkbox"/> CSF incl. cytology</li> <li><input type="checkbox"/> Borrelia-serological testing</li> <li><input type="checkbox"/> Vasculitis-serological testing</li> <li><input type="checkbox"/> Biopsy?</li> </ul>	possible diagnoses: · Bannwarth's syndrome · vasculitic PNP · meningococcal neoplasia
		<ul style="list-style-type: none"> <li>o sensory/sensorimotor/usually arms</li> <li>o demonstration of conduction blocks, demyelination</li> <li>o CSF protein: normal/slightly elevated</li> </ul>	Possible diagnosis: Lewis-Sumner syndrome (LSS)	
		<ul style="list-style-type: none"> <li>o motor/usually arms</li> <li>o demonstration of conduction blocks</li> <li>o CSF protein: normal/slightly elevated, Ig-M (I)-anti-GM1 antibodies</li> </ul>	Possible diagnosis: multifocal motor neuropathy (MMN)	
<ul style="list-style-type: none"> <li>o Obligatory examinations</li> <li><input type="checkbox"/> History</li> <li>o Sensory plus-symptoms and deficits</li> <li>o Motor plus-symptoms and deficits</li> <li>o Autonomic dysfunction</li> <li>o Course:</li> <li>o 4 weeks: acute</li> <li>o 4-8 weeks: subacute</li> <li>o &gt;8 weeks: chronic</li> <li>o Contributing diseases</li> <li>o Diabetes mellitus</li> <li>o Nephropathy</li> <li>o Immunological disease</li> <li>o Cancer, Lymphoma</li> <li>o Operations (e.g. laminectomy)</li> <li>o Drugs/toxins (esp. alcohol)</li> <li>o Family history: gait disturbance, foot deformities</li> <li><input type="checkbox"/> Neurological examination</li> <li>o Reflex attenuation or loss</li> <li>o Atrophies</li> <li>o Sensory loss (large fibers/small fibers)</li> <li>o Cranial nerve involvement</li> <li><input type="checkbox"/> Systemic review</li> <li>o Skeletal abnormalities</li> <li>o Organomegaly</li> <li>o Cutaneous signs</li> <li><input type="checkbox"/> Neurophysiology</li> <li><input type="checkbox"/> Basic laboratory investigation</li> </ul>	<ul style="list-style-type: none"> <li>o alcoholism</li> </ul>	<ul style="list-style-type: none"> <li><input type="checkbox"/> exclude other etiologies</li> <li><input type="checkbox"/> indication of other etiologies</li> </ul>	alcoholic polyneuropathy  further testing for distal symmetrical axonal PNP without alcoholism	
	<ul style="list-style-type: none"> <li>o axonal PNP</li> </ul>	<ul style="list-style-type: none"> <li><input type="checkbox"/> specialized laboratory investigation</li> <li><input type="checkbox"/> CSF</li> <li><input type="checkbox"/> history of drugs/toxins</li> <li><input type="checkbox"/> systemic disease</li> <li><input type="checkbox"/> biopsy?</li> </ul>	<ul style="list-style-type: none"> <li>o onset acute (days)</li> </ul>	possible diagnoses · vasculitic PNP · axonal GBS · vitamin-B12-deficiency (rarely acute) · hypoglycemia (rare)
	<ul style="list-style-type: none"> <li>o no alcoholism</li> </ul>	<ul style="list-style-type: none"> <li><input type="checkbox"/> onset subacute (months)</li> <li><input type="checkbox"/> course chronic (years)</li> </ul>	<ul style="list-style-type: none"> <li>o onset</li> </ul>	possible diagnoses · vasculitic PNP · CIAP (chronic inflammatory axonal PNP) · toxic PNP · vitamin deficiency · systemic disease · tumor associated · paraproteinemic PNP · PNP in other neurological diseases
	<ul style="list-style-type: none"> <li>o positive family history</li> <li>o negative family history</li> </ul>	<ul style="list-style-type: none"> <li><input type="checkbox"/> genetic examinations</li> <li><input type="checkbox"/> biopsy?</li> </ul>	<ul style="list-style-type: none"> <li>o consider biopsy</li> </ul>	possible diagnosis: CMT  possible diagnoses: · multiple myeloma, CIDP-variant · MGUS, CIDP-variant
<ul style="list-style-type: none"> <li>o demyelinating PNP</li> </ul>	<ul style="list-style-type: none"> <li>o no paraprotein</li> <li>o CSF protein raised</li> <li>o biopsy?</li> </ul>	<ul style="list-style-type: none"> <li>o possible diagnoses: · GBS · CIDP</li> </ul>		