

# Benign Paroxysmal Positional Vertigo

Terry D. Fife, M.D.<sup>1</sup>

## ABSTRACT

Benign paroxysmal positional vertigo (BPPV) is the most common cause of recurrent vertigo and has a lifetime prevalence of 2.4% in the general population. Benign paroxysmal positional vertigo is caused when calcium carbonate material originating from the macula of the utricle falls into one of the semicircular canals. Due to their density relative to the endolymph, they move in response to gravity and trigger excitation of the ampullary nerve of the affected canal. This, in turn, produces a burst of vertigo associated with nystagmus unique to that canal. Recognition of this condition is important not only because it may avert expensive and often unnecessary testing, but also because treatment is rapid, easy, and effective in >90% of cases. Two well-established methods of treating BPPV are discussed and explained in this article along with a brief discussion of the most commonly used method for treatment of horizontal canal BPPV. Recurrence rates approach 50% in those followed for at least 5 years.

**KEYWORDS:** Positional vertigo, dizziness, paroxysmal vertigo, canalith repositioning, Epley maneuver, Semont maneuver, positional nystagmus, calcium carbonate crystals

Benign paroxysmal positional vertigo (BPPV) is a common clinical disorder characterized by brief recurrent spells of vertigo often brought about by certain head position changes as may occur with looking up, turning over in bed, or straightening up after bending over. The Dix–Hallpike maneuver induces vertigo and a burst of nystagmus with characteristic directional features that permit localization to the affected side and the affected semicircular canal in most cases.

Benign paroxysmal positional vertigo is an important cause of vertigo with a prevalence of 11 to 64 per 100,000 and a lifetime prevalence in general practice of 2.4%.<sup>1–3</sup> In one study, 9% of elderly patients that underwent a comprehensive evaluation for nonbalance-related problems were found to have previously unrecognized BPPV.<sup>4</sup> Delays in the proper diagnosis and treatment of this condition are still common,<sup>5</sup> and can lead to unnecessary costs and limitations of function.<sup>3,6</sup>

The importance of recognizing this condition is underscored by the ease and effectiveness of treatment

techniques that eliminate symptoms and the need for expensive testing.<sup>7</sup> The pathophysiologic mechanisms that underlie this condition will be reviewed, as well as the clinical features of BPPV that allow its diagnosis, and the effective methods for treating BPPV.

## PATHOPHYSIOLOGY OF BENIGN PAROXYSMAL POSITIONAL VERTIGO

### Anatomic Background

The vestibular part of the membranous labyrinth consists of three semicircular canals: the anterior, posterior, and horizontal canals (Fig. 1). These canals detect turning movements of the head. The labyrinth also consists of two otolith structures, the utricle and saccule that detect linear acceleration, including detection of gravity. The cupula is the motion sensor for the semicircular canal, and it is activated by deflection caused by endolymph flow.

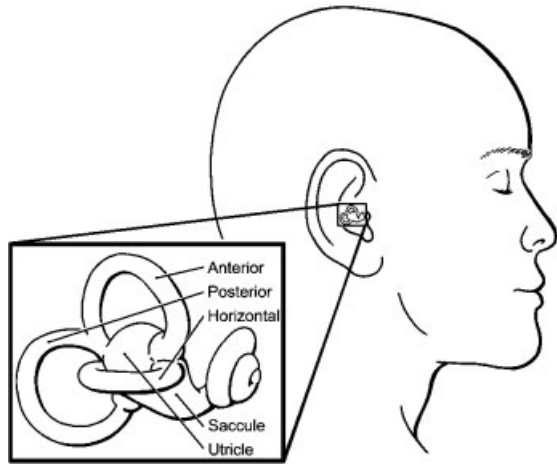
<sup>1</sup>Associate Professor of Clinical Neurology, University of Arizona College of Medicine, Barrow Neurological Institute, Phoenix, Arizona.

Address for correspondence and reprint requests: Terry D. Fife, M.D., 222 W. Thomas Road, Suite 110A, Phoenix, AZ 85013 (e-mail: tfife@email.arizona.edu).

Neurotology; Guest Editor, Robert W. Baloh, M.D.

Semin Neurol 2009;29:500–508. Copyright © 2009 by Thieme Medical Publishers, Inc., 333 Seventh Avenue, New York, NY 10001, USA. Tel: +1(212) 584-4662.

DOI 10.1055/s-0029-1241041. ISSN 0271-8235.



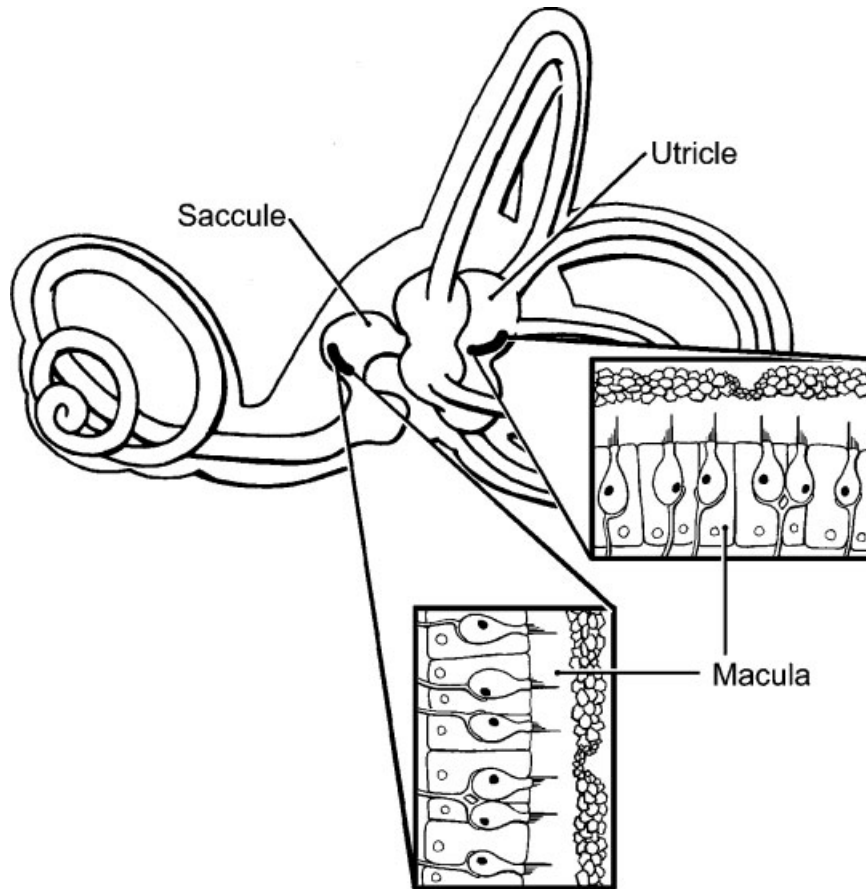
**Figure 1** Membranous labyrinth. (Reprinted with permission from Barrow Neurological Institute.)

The macula of the utricle is the presumed source of the calcium particles that cause BPPV. It consists of calcium carbonate crystals (otoconia) embedded in a gelatinous matrix, into which the stereocilia of hair cells project (Fig. 2). The calcium carbonate crystals are more than twice as dense as endolymph, so move in response to gravity and other accelerative movements. The oto-

conial membrane consists of a top heavy mass of calcium carbonate crystals overlying an elastic intermediary that makes the macular receptor very sensitive to linear acceleration.<sup>8,9</sup>

### Mechanistic Basis of BPPV

Benign paroxysmal positional vertigo is caused when otoliths composed of calcium carbonate that originate from the utricular macula dislodge and move within the lumen of one of the semicircular canals. When the calcium carbonate crystals move within the semicircular canal (canalithiasis) they cause endolymph movement that stimulates the ampulla of the affected canal, thereby causing vertigo. The direction of the nystagmus is determined by ampullary nerve excitation in the affected canal by direct connections to the extraocular muscles. Each canal affected by canalithiasis has its own characteristic nystagmus (Table 1). Canalithiasis refers to the freely moving calcium particles within the semicircular canal. Cupulolithiasis refers to the less common circumstance of calcium particles adherent to the cupula itself. A concept of “canal jam” has also been proposed to indicate calcium particles that can sometimes move, but sometimes become stuck within the canal.<sup>10</sup>



**Figure 2** Otolithic membrane of the macula showing the organization of calcium carbonate otoliths. (Reprinted with permission from Barrow Neurological Institute.)

**Table 1 Nystagmus Features by Canal Affected in Benign Paroxysmal Positional Vertigo**

Canal Affected	Direction of Paroxysmal Positional Nystagmus (Fast Phase)
Posterior canal	Upbeating + torsional top pole beating toward downward ear
Horizontal canal	Horizontal geotropic direction changing (right beating in head right position, left beating in head left position) or Horizontal apogeotropic direction changing (left beating in head right position, right beating in head left position)
Anterior canal	Downbeating possibly with a slight torsional component

The reason for this shedding of calcium crystals from the macula is not well understood. The calcium debris may break off following trauma or viral infections, but in many instances it seems to occur without identifiable illness or trauma. It may have to do with age-related changes in the protein and gelatinous matrix of the otolithic membrane. Patients with BPPV have recently been found to have more osteopenia and osteoporosis than matched controls, and those with recurrent BPPV tended to have the lowest bone density scores.<sup>11</sup> This observation suggests that the spontaneous release of otoconia may parallel bone demineralization in general. It remains to be determined if treatment of osteopenia or osteoporosis impacts on the likelihood of recurrent BPPV.

### Canal Variants

Benign paroxysmal positional vertigo may affect the posterior, horizontal, or anterior semicircular canal, and in some cases it may even involve more than one canal at a time. Due to its gravity-dependent position, the most commonly affected semicircular canal is the posterior canal. This accounts for ~85 to 90% of cases of BPPV; therefore, when not otherwise qualified, BPPV generally refers to the posterior canal form of the disorder. The horizontal semicircular canal is positioned within the membranous labyrinth such that it may also be affected by the same mechanism, and accounts for ~10% of cases of BPPV.<sup>7,12</sup> The anterior canal and polycanicular forms are the least common.<sup>13</sup>

### DIAGNOSIS

The diagnosis of BPPV can be made based upon the history and examination. Patients usually report episodes of spinning evoked by certain movements, such as lying

back or getting out of bed, turning in bed, looking up or straightening after bending over. The episodes of vertigo last 10 to 30 seconds and are not accompanied by any additional symptoms aside from nausea in some patients. Some patients that are susceptible to motion sickness may feel queasy and lightheaded for hours after the attack of vertigo, but most patients feel well between episodes of vertigo. If the patient reports spontaneous episodes of vertigo, or vertigo lasting more than 1 or 2 minutes, or if episodes never occur in bed or with head position changes, then one should question the diagnosis of BPPV.

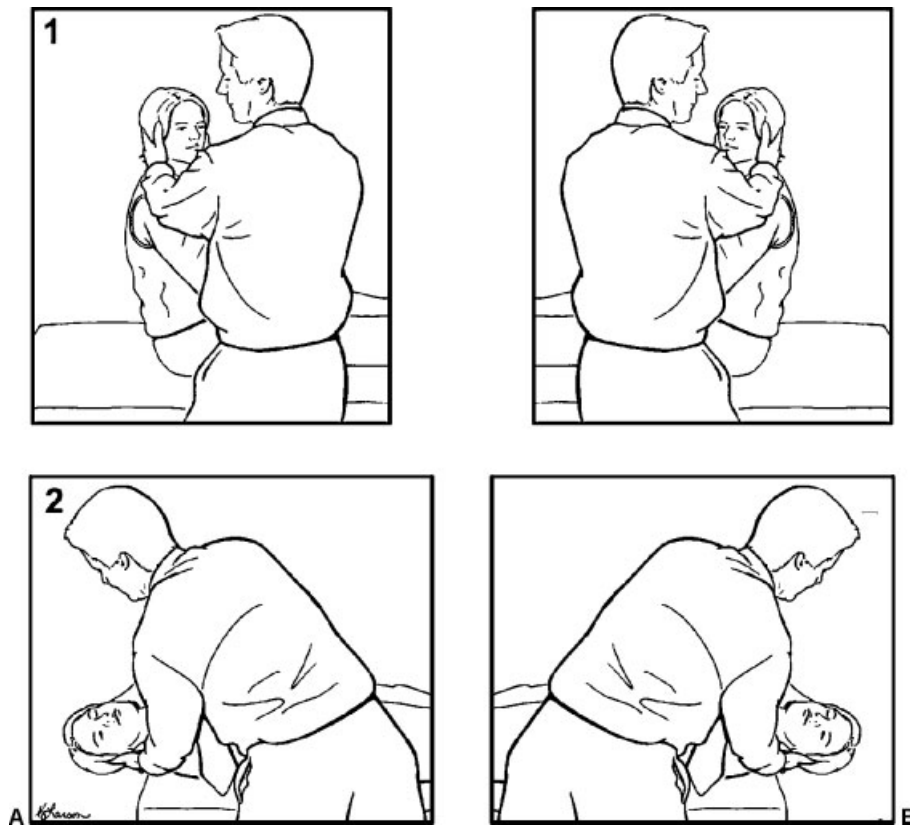
### Posterior Canal Type

The diagnosis of BPPV of the posterior canal is confirmed by observing paroxysmal positional nystagmus with the Dix–Hallpike maneuver. The Dix–Hallpike maneuver is performed by rapidly moving the head from an upright to head hanging position with one ear 45 degrees to the side. In Fig. 3, movement from sitting to head hanging comprises the Dix–Hallpike maneuver to each side. The Dix–Hallpike maneuver results in torsional upbeating nystagmus corresponding in duration to the patient's subjective vertigo, and occurring only after Dix–Hallpike positioning on the affected side (Table 1). A presumptive diagnosis can be made by history alone, but paroxysmal positional nystagmus confirms the diagnosis.

### Lateral Canal Type

Horizontal canal BPPV may sometimes be evoked by the Dix–Hallpike maneuver. However, the most reliable way to diagnose horizontal BPPV is by a supine head turn maneuver (Pagnini–McClure maneuver) (Fig. 4). The examiner looks for horizontal nystagmus upon turning the patient's head to one side, then turns the head back to the supine face-up position. Then the head is turned to the other side. The side with the most prominent horizontal nystagmus is generally assumed to be the affected side.<sup>14,15</sup>

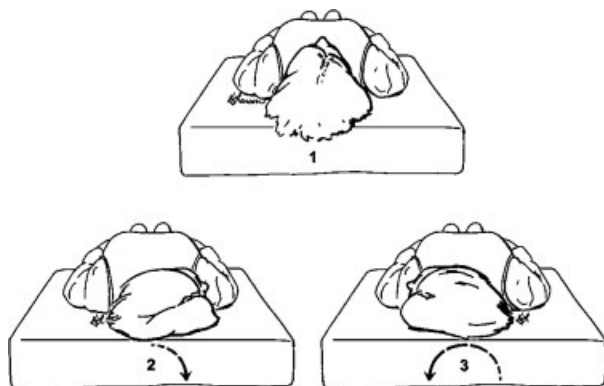
The nystagmus of horizontal canal BPPV, unlike that of posterior canal BPPV, is distinctly horizontal and changes direction with changes in head position. The paroxysmal direction changing nystagmus may be either geotropic or apogeotropic (Table 1).<sup>14</sup> Geotropic direction-changing positional nystagmus is right beating upon turning the head to the right and then left beating when turning the head back to the left side. Conversely, the apogeotropic form indicates the nystagmus is right beating with turning to the left and left beating with turning to the right. The latency is often brief, and the duration may be 15 to 60 seconds. This nystagmus appears less apt to fatigue with repeat positioning than



**Figure 3** (A) Dix–Hallpike positioning maneuver to the right. (B) Dix–Hallpike maneuver to the left. Observe for a latency of 2 to 6 seconds after positioning before the onset of nystagmus. Observe for nystagmus that is upbeating and torsional with duration of 10 to 30 seconds. The side with the downward ear is the affected side in benign paroxysmal positional vertigo of the posterior canal. (Reprinted with permission from Barrow Neurological Institute.)

in cases of posterior canal BPPV; consequently, patients are more likely to become ill with attempts to fatigue this form of BPPV.

There is speculation that apogeotropic direction-changing nystagmus suggests cupulolithiasis, and geotropic nystagmus suggests canalithiasis as the mechanism.<sup>13,16</sup>



**Figure 4** Supine head turn maneuver to determine the presence and affected side of horizontal canal benign paroxysmal positional vertigo. (Reprinted with permission from Barrow Neurological Institute.)

### Anterior Canal and Polycanicular Types

The anterior canal form of BPPV is associated with paroxysmal downbeating nystagmus, sometimes with a minor torsional component following Dix–Hallpike positioning.<sup>17–19</sup> This form may be encountered briefly in the course of treating other forms of BPPV, but occasionally presents *de novo*. Chronic or persistent anterior canal BPPV is rare. Of all the types of BPPV, anterior canal BPPV seems to resolve spontaneously most often. Its diagnosis should be considered with caution because downbeating positional nystagmus related to brainstem or cerebellar lesions can produce a similar pattern. In a review of 50 patients with downbeat positional nystagmus, Bertholon et al found that three-fourths had central nervous system (CNS) disease, while at least some of the remaining one-fourth of cases were thought to have a form of anterior canal BPPV.<sup>20</sup>

Polycanicular BPPV is uncommon, but indicates that two or more canals are simultaneously affected at the same time.<sup>19,21</sup> The most common circumstance is posterior canal BPPV combined with horizontal canal BPPV. The nystagmus will nevertheless continue to follow the patterns of single canal BPPV, although treatment may have to be undertaken in stages in some cases.

**Table 2 Features Distinguishing Central from Peripheral Causes of Positional Vertigo**

	Central	Peripheral
Severe nausea	+	+++
Worse with nonspecific head movement	++	-
Paroxysmal upbeating and torsional nystagmus with Dix–Hallpike maneuver	-	+++
Paroxysmal horizontal direction changing nystagmus (geotropic or apogeotropic) evoked by supine head turning	+	++
Persistent downbeating nystagmus in any position	+++	-
Nystagmus diminishes (fatigues) with repeat positioning	-	+++
Nystagmus and vertigo resolve following positional treatment maneuver	-	+++

### Canal Switch

Occasionally, freely mobile otoconia moving within the lumen of one semicircular canal can be moved during the course of treatment; not back to the vestibule as intended, but to one of the adjacent canals, as the canals all directly communicate with one another. This “canal switch” changes the appearance of nystagmus from that of the original affected canal to that of the newly affected canal.<sup>10,22,23</sup> The most common canal switch is from the posterior to the horizontal and posterior to anterior canals.

### Distinguishing from Central Causes

Typical BPPV is usually easily recognized as such and responds to treatment. The forms of positional vertigo that most commonly lead to confusion are those with downbeating nystagmus (see discussion on anterior canal BPPV above), or those in which the nystagmus is not truly evoked by the positional maneuver, but are nevertheless evident while the patient is in the head hanging position. Table 2 outlines some of the features that may help separate central from peripheral positional vertigo. As a general rule, if the nystagmus is anything other than the typical, or if it fails to respond readily to positioning treatments, a central cause should be considered.

### Dizziness without Nystagmus during Dix–Hallpike Positioning

Sometimes patients with a history compatible with BPPV report dizziness upon Dix–Hallpike positioning, but no nystagmus is seen. If this occurs on one side but not the other, it is suggestive of BPPV. Repeat positioning is worth trying as sometimes the nystagmus emerges on a second or third attempt, possibly based on the concept of “canal jam.” An alternative possibility, especially when the dizziness without nystagmus occurs with Dix–Hallpike positioning on both sides, is another type of vestibular disturbance that is aggravated by the process of quick motion. In the absence of any other neurologic symptoms, some home positioning exercises followed by reevaluation or a limited course of vestibular physiotherapy can be considered.

## TREATMENT

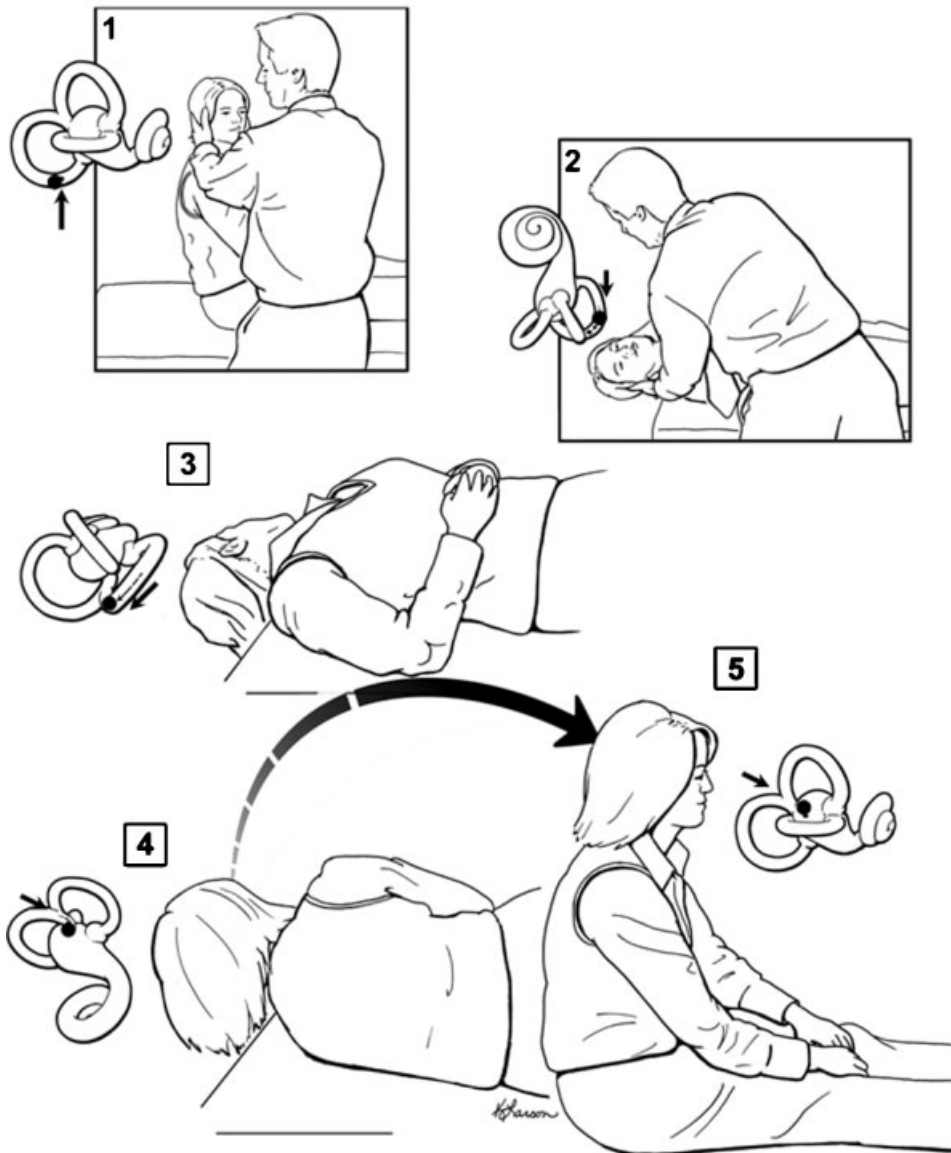
### Treatment of Posterior Canal BPPV

Treatment of BPPV is shown in Fig. 5 that depicts the canalith repositioning maneuver, sometimes referred to as the “Epley maneuver” or canalith repositioning maneuver. Fig. 6 illustrates the Semont maneuver, which is an effective alternative treatment method. Both maneuvers and variations of them are designed to clear calcium debris from the posterior semicircular canal by moving it back into the vestibule by the effects of gravity because the calcium carbonate crystals sink in the endolymph. Once the calcium carbonate crystals are back in the vestibule, they are absorbed within a period of days in most patients. If properly done, the canalith repositioning maneuver eliminates BPPV immediately in greater than 85% of patients.<sup>7,24</sup> Similar success has been reported with the Semont maneuver (Fig. 6). Patients that do not respond to canalith repositioning have calcium particles that are immobile or that are attached to the cupula. Benign paroxysmal positional vertigo that is disabling and refractory to all positioning treatments can be managed surgically, though this is rarely necessary.

Benign paroxysmal positional vertigo is a mechanically based disorder best managed by a mechanical remedy. Vestibular suppressants such as meclizine or diazepam may have a role in premedicating those patients with severe motion sickness, but are generally not helpful for BPPV because the episodes are brief and because the therapeutic maneuvers are so immediate and effective.

### Self-treatment of BPPV

Patients given instructions for self-administered canalith repositioning treatment at home show improvement that is superior to that seen on those given self-administered Brandt–Daroff exercises.<sup>25</sup> Home exercises seem to pose little risk for most patients, and may be a useful adjunct to treatment, but is probably somewhat less effective than treatment administered by an experienced clinician.<sup>26</sup>

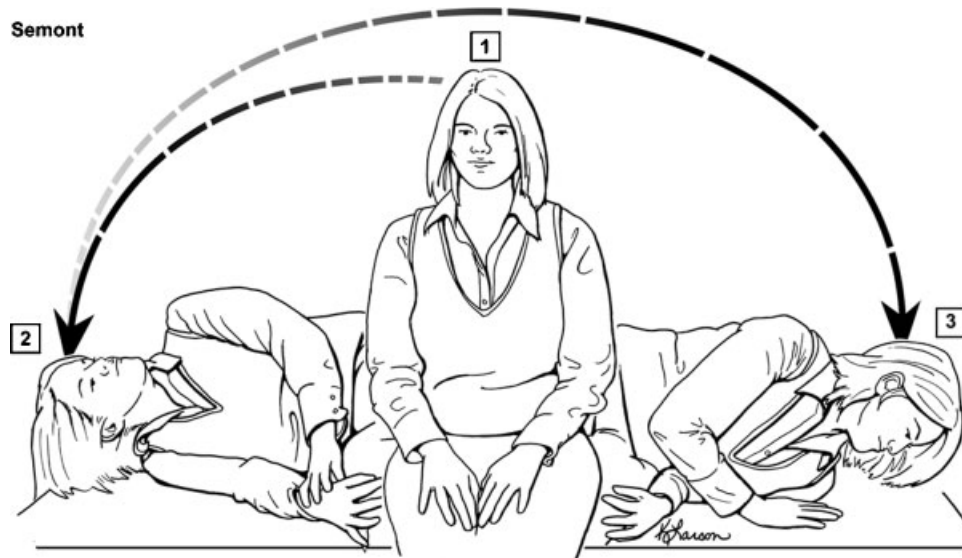


**Figure 5** Canalth repositioning maneuver. Step 1: Seat the patient on a table positioned so they may be taken back to the head hanging position with the neck in slight extension. Stabilize the head with your hands and move the head 45 degrees toward the side you will test. Move the head, neck and shoulders together to avoid neck strain or forced hyperextension. Step 2: Observe for nystagmus and hold the position for ~10 seconds after it stops. Step 3: Keeping the head tilted back in slight hyperextension, turn the head ~90 degrees toward the opposite side and wait 20 seconds. Step 4: Roll the patient all the way on to his or her side and wait 10 to 15 seconds. Step 5: From this side-lying position, turn the head to face the ground and hold it there 10 to 15 seconds. Step 6: Keeping the head somewhat in the same position, have them sit up then straighten the head. Hold on to the patient for a moment because some patients feel a sudden but very brief tilt when sitting up. REPEAT: After waiting 30 seconds or so, repeat the whole maneuver. If there is not paroxysmal nystagmus or symptoms during Dix-Hallpike positioning (Steps 1, 2) then there is a high likelihood of success. (Reprinted with permission from Barrow Neurological Institute.)

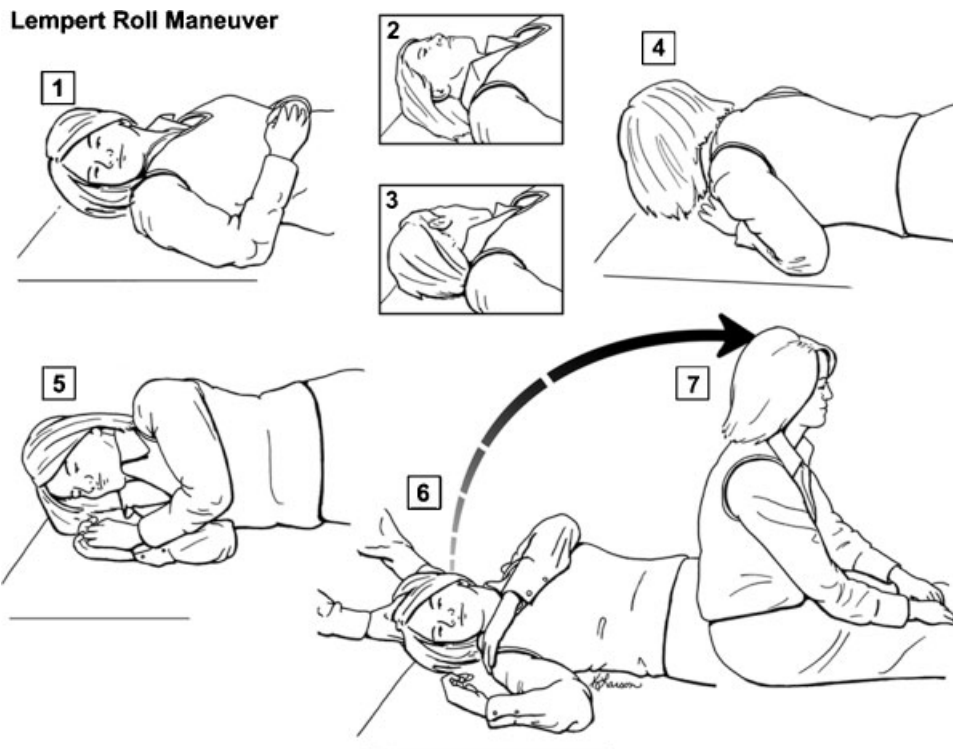
### Treating Lateral Canal BPPV

Lateral canal BPPV is often unresponsive to canalth repositioning designed to treat posterior canal BPPV,<sup>17,27,28</sup> but may respond to any of a variety of other maneuvers intended to move canaliths from the lateral canal into the vestibule. The best treatment for horizontal canal BPPV remains unclear. The most

commonly used treatment in the published literature is the roll maneuver (Lempert maneuver or barbecue roll maneuver) (Fig. 7) or similar variations.<sup>12,13,17,23,28-33</sup> The effectiveness of the roll maneuver in treating lateral canal BPPV appears to be <75%,<sup>13,33</sup> although reported response rates vary from near 50% to almost 100%. An overview of some of the other treatments for horizontal



**Figure 6** Semont liberatory maneuver. Step 1: Start with the patient sitting on a table or flat surface with head turned away from the affected side. Step 2: Quickly put the patient into the side-lying position, toward the affected side with the head turned up. Nystagmus will occur shortly after arriving at the side-lying position. Keep the patient here until at least 20 seconds after all nystagmus has ceased. Step 3: Quickly move the patient back up and through the sitting position so that he or she is in the opposite side-lying position with head facing down (head did not turn during the position change). Keep the patient in this position for ~30 seconds (some recommend up to 10 minutes). Step 4: At a normal or slow rate, bring the patient back up to the sitting position. (Reprinted with permission from Barrow Neurological Institute.)



**Figure 7** Lempert 360- (Barbeque) degree roll maneuver to treat horizontal canal BPPV. When the patient's head is positioned with the affected ear down, the head is then turned quickly 90 degrees toward the unaffected side (face up). A series of 90-degree turns toward the unaffected side is then undertaken sequentially until the patient has turned 360 degrees and is back to the affected ear-down position. From there, the patient is turned to the face-up position and then brought up to the sitting position. The successive head turns can be done in 15- to 20-second intervals even when the nystagmus continues. Waiting longer does no harm, but may lead to the patient developing nausea, and the shorter interval does not appear to detract from the effectiveness of the treatment. (Reprinted with permission from Barrow Neurological Institute.)

canal BPPV are discussed elsewhere.<sup>13,31</sup> At this time, there is insufficient evidence to support the use of any particular maneuver over another for lateral canal BPPV treatment.<sup>24</sup>

The treatment of horizontal canal BPPV depends on knowing the affected side, which is not always obvious. If the horizontal canal BPPV occurs after treatment for posterior canal BPPV, then the affected ear is likely to be the same one that had been affected by the posterior canal BPPV. As mentioned earlier, the side with the strongest nystagmus from the supine head turning test (Fig. 4) is usually assumed to be the affected side. Nevertheless, in some cases the affected side is unclear, and one must simply choose one side.

### Posttreatment Restrictions

Over the years there have been various recommendations, such as wearing a cervical collar or sleeping upright following treatments. A recent review found there was little difference in outcome between those given posttreatment restrictions and those receiving no instructions or restrictions.<sup>24</sup> At this point, evidence is lacking to recommend postmaneuver restrictions in patients treated with canalith repositioning therapies, although there is generally no associated harm associated with these instructions.

### Complications

The most common complications include nausea, vomiting, fainting, and conversion to lateral canal BPPV during the course of treatment due to “canal switch” that occurs ~6% of the time,<sup>27,34</sup> underscoring the importance of recognizing the lateral canal variant of BPPV. Patients with unstable cervical spine injury or who may not safely have their head moved should have treatment deferred, but there are otherwise no contraindications.

### PROGNOSIS

At present, the generally accepted recurrence rate of BPPV after successful treatment is 40 to 50% at 5 years of average follow up.<sup>35,36</sup> There does appear to be a subset of individuals prone to multiple recurrences.

### REFERENCES

- Mizukoshi K, Watanabe Y, Shojaku H, Okubo J, Watanabe I. Epidemiological studies on benign paroxysmal positional vertigo in Japan. *Acta Otolaryngol Suppl* 1988;447:67-72

- Froehling DA, Silverstein MD, Mohr DN, Beatty CW, Offord KP, Ballard DJ. Benign positional vertigo: incidence and prognosis in a population-based study in Olmsted County, Minnesota. *Mayo Clin Proc* 1991;66(6):596-601
- von Brevern M, Radtke A, Lezius F, et al. Epidemiology of benign paroxysmal positional vertigo: a population based study. *J Neurol Neurosurg Psychiatry* 2007;78(7):710-715
- Oghalai JS, Manolidis S, Barth JL, Stewart MG, Jenkins HA. Unrecognized benign paroxysmal positional vertigo in elderly patients. *Otolaryngol Head Neck Surg* 2000;122(5):630-634
- Fife D, FitzGerald JE. Do patients with benign paroxysmal positional vertigo receive prompt treatment? Analysis of waiting times and human and financial costs associated with current practice *Int J Audiol* 2005;44(1):50-57
- Li JC, Li CJ, Epley J, Weinberg L. Cost-effective management of benign positional vertigo using canalith repositioning. *Otolaryngol Head Neck Surg* 2000;122(3):334-339
- Bhattacharyya N, Baugh RF, Orvidas L, et al; American Academy of Otolaryngology-Head and Neck Surgery Foundation. Clinical practice guideline: benign paroxysmal positional vertigo. *Otolaryngol Head Neck Surg* 2008;139(5, Suppl 4):S47-S81
- Ross MD, Komorowski TE, Donovan KM, Pote KG. The suprastructure of the saccular macula. *Acta Otolaryngol* 1987;103(1-2):56-63
- Lins U, Farina M, Kurc M, et al. The otoconia of the guinea pig utricle: internal structure, surface exposure, and interactions with the filament matrix. *J Struct Biol* 2000;131(1): 67-78
- Epley JM. Human experience with canalith repositioning maneuvers. *Ann N Y Acad Sci* 2001;942:179-191
- Jeong SH, Choi SH, Kim JY, Koo JW, Kim HJ, Kim JS. Osteopenia and osteoporosis in idiopathic benign positional vertigo. *Neurology* 2009;72(12):1069-1076
- Prokopakis EP, Chimona T, Tsagournisakis M, et al. Benign paroxysmal positional vertigo: 10-year experience in treating 592 patients with canalith repositioning procedure. *Laryngoscope* 2005;115(9):1667-1671
- Casani AP, Vannucci G, Fattori B, Berrettini S. The treatment of horizontal canal positional vertigo: our experience in 66 cases. *Laryngoscope* 2002;112(1):172-178
- Nuti D, Vannucchi P, Pagnini P. Benign paroxysmal positional vertigo of the horizontal canal: a form of canalolithiasis with variable clinical features. *J Vestib Res* 1996; 6(3):173-184
- Pagnini P, Nuti D, Vannucchi P. Benign paroxysmal vertigo of the horizontal canal. *ORL J Otorhinolaryngol Relat Spec* 1989;51(3):161-170
- Baloh RW, Yue Q, Jacobson KM, Honrubia V. Persistent direction-changing positional nystagmus: another variant of benign positional nystagmus? *Neurology* 1995;45(7):1297-1301
- Fife TD. Recognition and management of horizontal canal benign positional vertigo. *Am J Otol* 1998;19(3):345-351
- Herdman SJ, Tusa RJ, Zee DS, Proctor LR, Mattox DE. Single treatment approaches to benign paroxysmal positional vertigo. *Arch Otolaryngol Head Neck Surg* 1993;119(4): 450-454
- Lopez-Escamez JA, Molina MI, Gamiz M, et al. Multiple positional nystagmus suggests multiple canal involvement in benign paroxysmal vertigo. *Acta Otolaryngol* 2005;125(9): 954-961
- Bertholon P, Bronstein AM, Davies RA, Rudge P, Thilo KV. Positional down beating nystagmus in 50 patients:



- cerebellar disorders and possible anterior semicircular canalithiasis. *J Neurol Neurosurg Psychiatry* 2002;72(3):366–372
21. Aw ST, Todd MJ, Aw GE, McGarvie LA, Halmagyi GM. Benign positional nystagmus: a study of its three-dimensional spatio-temporal characteristics. *Neurology* 2005;64(11):1897–1905
  22. McClure JA, Parnes LS. A cure for benign positional vertigo. *Baillieres Clin Neurol* 1994;3(3):537–545
  23. White JA, Coale KD, Catalano PJ, Oas JG. Diagnosis and management of lateral semicircular canal benign paroxysmal positional vertigo. *Otolaryngol Head Neck Surg* 2005;133(2):278–284
  24. Fife TD, Iverson DJ, Lempert T, et al; Quality Standards Subcommittee, American Academy of Neurology. Practice parameter: therapies for benign paroxysmal positional vertigo (an evidence-based review): report of the Quality Standards Subcommittee of the American Academy of Neurology. *Neurology* 2008;70(22):2067–2074
  25. Radtke A, von Brevern M, Tiel-Wilck K, Mainz-Perchalla A, Neuhauser H, Lempert T. Self-treatment of benign paroxysmal positional vertigo: Semont maneuver vs Epley procedure. *Neurology* 2004;63(1):150–152
  26. Honrubia V, Radtke A, Lempert T. Self-treatment of benign paroxysmal positional vertigo: Semont maneuver vs Epley procedure. *Neurology* 2005;64(3):583–584, author reply 583–584
  27. Herdman SJ, Tusa RJ. Complications of the canalith repositioning procedure. *Arch Otolaryngol Head Neck Surg* 1996;122(3):281–286
  28. Lempert T, Tiel-Wilck K. A positional maneuver for treatment of horizontal-canal benign positional vertigo. *Laryngoscope* 1996;106(4):476–478
  29. Nuti D, Agus G, Barbieri M-T, Passali D. The management of horizontal-canal paroxysmal positional vertigo. *Acta Otolaryngol* 1998;118(4):455–460
  30. Ciniglio Appiani G, Gagliardi M, Magliulo G. Physical treatment of horizontal canal benign positional vertigo. *Eur Arch Otorhinolaryngol* 1997;254(7):326–328
  31. Asprella Libonati G. Diagnostic and treatment strategy of lateral semicircular canal canalolithiasis. *Acta Otorhinolaryngol Ital* 2005;25(5):277–283
  32. Tirelli G, Russolo M. 360-Degree canalith repositioning procedure for the horizontal canal. *Otolaryngol Head Neck Surg* 2004;131(5):740–746
  33. Chiou WY, Lee HL, Tsai SC, Yu TH, Lee XX. A single therapy for all subtypes of horizontal canal positional vertigo. *Laryngoscope* 2005;115(8):1432–1435
  34. Yimtae K, Srirompotong S, Srirompotong S, Sae-Seaw P. A randomized trial of the canalith repositioning procedure. *Laryngoscope* 2003;113(5):828–832
  35. Hain TC, Helminski JO, Reis IL, Uddin MK. Vibration does not improve results of the canalith repositioning procedure. *Arch Otolaryngol Head Neck Surg* 2000;126(5):617–622
  36. Nunez RA, Cass SP, Furman JM. Short- and long-term outcomes of canalith repositioning for benign paroxysmal positional vertigo. *Otolaryngol Head Neck Surg* 2000;122(5):647–652