

Deep enteroscopy in patients with left ventricular assist devices: practical and technical considerations

A 73-year-old man with ischemic cardiomyopathy and a left ventricular assist device (LVAD; HeartMate II; Thoratec Inc., Pleasanton, California, USA) (● Fig. 1) [1] presented with recurrent melena.

Esophagogastroduodenoscopy (EGD) was performed multiple times, and bleeding arteriovenous malformations (AVMs) in the second portion of the duodenum were treated with argon plasma coagulation. In spite of this, the patient continued to bleed whenever his warfarin therapy was resumed.

Although a capsule endoscopy was negative, deep double-balloon enteroscopy (DBE) was performed because of the concern that the patient might be bleeding from his mid small bowel. The DBE was performed with the assistance of a cardiologist, cardiothoracic surgeon, perfusionist, and cardiac anesthesiologist. The patient was kept supine and care was taken to avoid upper abdominal pressure on or near the LVAD. In the third part of the duodenum, a large AVM was treated with argon plasma coagulation. The small bowel was intubated to a distance of 330 cm. There were no complications from the procedure.

Warfarin was restarted after the patient was discharged, but after 1 week the patient was re-admitted with melena and anemia. Angiography was performed and a branch of the gastroduodenal artery was embolized. Warfarin was empirically restarted. The patient has not had anemia or melena for several months.

LVAD recipients have a tendency to bleed from small-bowel AVMs and may require deep enteroscopy [2,3]. This can safely be performed in LVAD recipients but requires careful planning, as bowel perforation or other endoscopic complications are potentially catastrophic in these hemodynamically fragile patients. A multidisciplinary approach is required, involving a cardiologist, anesthesiologist, and perfusionist, as well as a cardiothoracic surgeon. During endoscopy, care should be taken not to exert pressure on the LVAD pump, which is typically placed within the muscles of the abdominal wall.

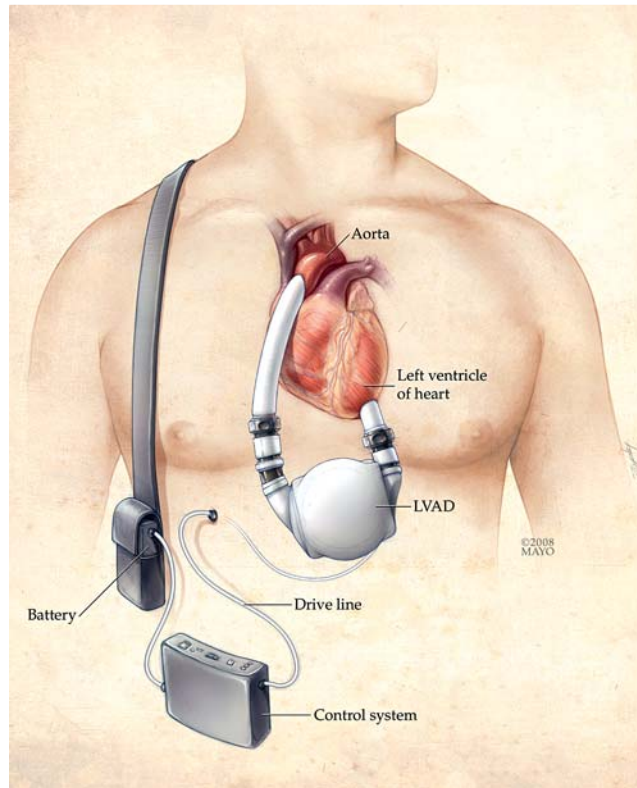


Fig. 1 Left ventricular assist device (LVAD). The latest devices use continuous-flow technology employing a rotary pump, percutaneous lead, external power source, and control system. The pump lies parallel to the diaphragm and is placed preperitoneally or within the muscles of the abdominal wall. It is attached between the apex of the left ventricle and the ascending aorta. (Copyrighted and used with permission of the Mayo Foundation for Medical Education and Research.)

Competing interests: None

Endoscopy_UCTN_Code_TTT_1AP_2AD

G. A. Decker¹, E. D. Miller¹, S. F. Pasha¹, M. E. Harrison^{1,2}, J. A. Leighton¹

¹ Division of Gastroenterology, Mayo Clinic Arizona, Scottsdale, Arizona, USA

² Division of Hepatology, Mayo Clinic Arizona, Scottsdale, Arizona, USA

References

- 1 Miller LW, Pagani FD, Russell SD et al. Use of a continuous-flow device in patients awaiting heart transplantation. *N Engl J Med* 2007; 357: 885–896
- 2 Crow S, John R, Boyle A et al. Gastrointestinal bleeding rates in recipients of nonpulsatile and pulsatile left ventricular assist devices. *J Thorac Cardiovasc Surg* 2009; 137: 208–215
- 3 Letsou GV, Shah N, Gregoric ID et al. Gastrointestinal bleeding from arteriovenous malformations in patients supported by the Jarvik 2000 axial-flow left ventricular assist device. *J Heart Lung Transplant* 2005; 24: 105–109

Bibliography

DOI 10.1055/s-0030-1255690

Endoscopy 2010; 42: E194

© Georg Thieme Verlag KG Stuttgart · New York · ISSN 0013-726X

Corresponding author

G. A. Decker, M. B. B. Ch, M. R. C. P.

Division of Gastroenterology
Mayo Clinic Arizona
13400 East Shea Boulevard
Scottsdale, AZ 85259
USA

Fax: +01-480-301-6737

decker.anton@mayo.edu