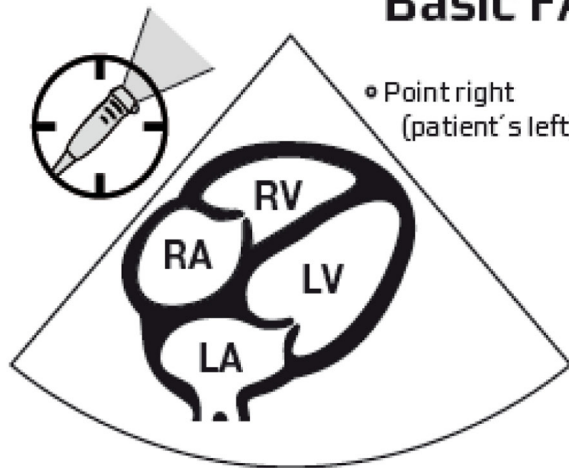


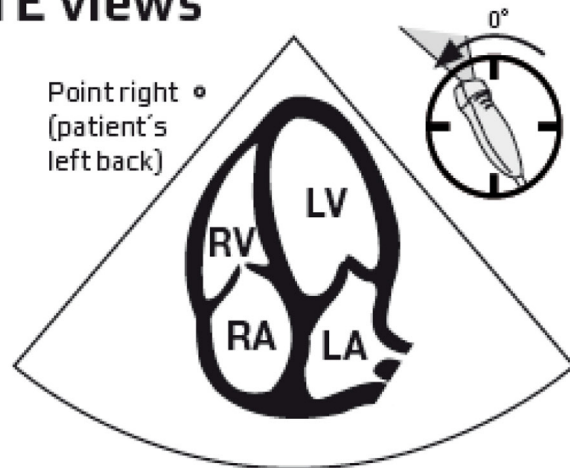
# Focus Assessed Transthoracic Echo (FATE)

Scanning through position 1-4 in the most favourable sequence

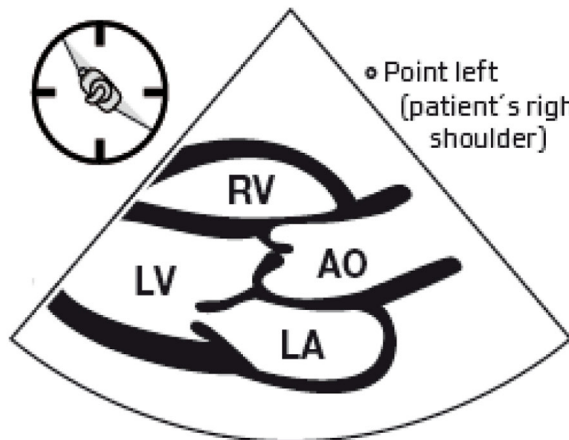
## Basic FATE views



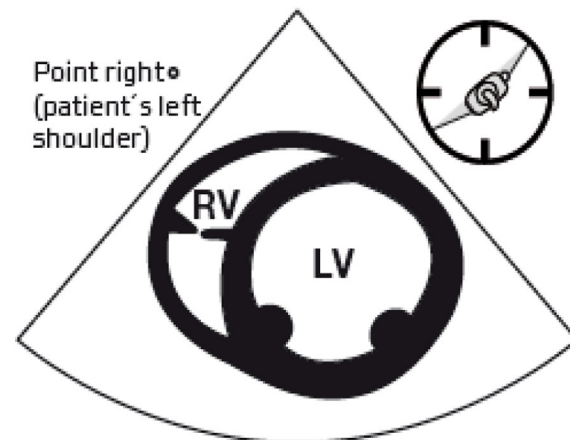
Pos 1: Subcostal 4-chamber



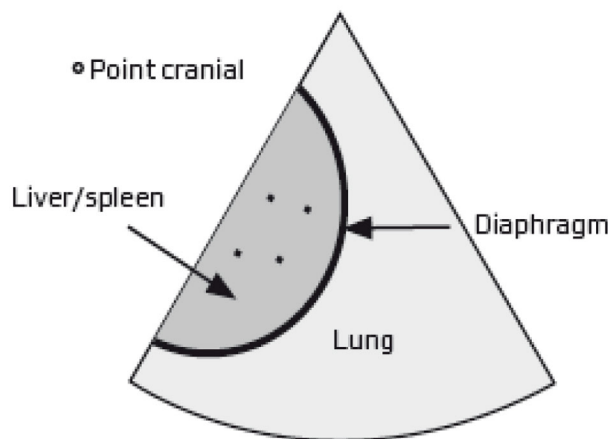
Pos 2: Apical 4-chamber



Pos 3: Parasternal long axis



Pos 3: Parasternal LV short axis



Pos 4: Pleural scanning

