

Aesthetic and Functional Male to Female Genital and Perineal Surgery: Feminizing Vaginoplasty

Harold Morgan Reed, M.D.¹

ABSTRACT

Male to female transsexuals frequently seek feminizing vaginoplasty for “below the waist” conformation, enhancement of sexual identity, and interactive sexual function. The author shares his experience with his first 250 primary surgical procedures. Included is a brief historical background, the patient selection process, some guidelines from the World Professional Association for Transgender Health (standards of care), preoperative evaluation and instructions, surgical technique, postoperative regimen, risk factors, results, complications and management. The patients all underwent feminizing vaginoplasty at the author’s ambulatory surgical facility, which includes an overnight stay. The author’s results suggest that feminizing vaginoplasty when performed vigilantly on a select group of patients is feasible.

KEYWORDS: Feminizing vaginoplasty, male to female transsexual surgery, labiaplasty, perineal urethrostomy, total penectomy, clitoroplasty, orchiectomy

Standing on the shoulders of giants, one can see very far. Herein is a colloquial report of my approach to feminizing vaginoplasty.

The first reports of vaginoplasty go back to 1930, when Dr. Kurt Warnekros, a gynecologist from Dresden, Germany operated on male to female Lili Elbe. Her memoirs are chronicled in the book “Man into Woman,”¹ which will serve as the basis for the screenplay “The Danish Girl” starring and coproduced by Nicole Kidman. Subsequently other surgeons who have amassed voluminous case experience include Dr. Georges Burou, a French surgeon practicing at his “Clinique du Parc” in Casablanca, Morocco who reported in 1973 his experience with over 3000 cases.²

Similarly large case experiences have been reported by Drs. J. Joris Hage (Holland),³ Toby Meltzer and Marci Bowers⁴ in the United States, Drs. Perovic and Djordjevic⁵ from Belgrade, Serbia, Dr. Stanley Monstrey⁶ in Gent, Belgium, Dr. Sanguan Kunaporn and Dr. Suporn Watanyusakul⁷ in Thailand to name a few.

In contrast to hospital-based surgery, since 2003 we have performed all of our procedures in our office-based facility built to State of Florida Department of Health and Rehabilitative Services (HRS) specifications. Our case experience is 250 primary cases and 500 secondary or revision procedures (ours and others). An overnight stay is mandatory for all primary procedures

¹Reed Centre for Ambulatory Urological Surgery, Bay Harbor Islands, Florida.

Address for correspondence and reprint requests: Harold Morgan Reed, M.D., Reed Centre for Ambulatory Urological Surgery, 1111 Kane Concourse, Suite # 311, Bay Harbor Islands, FL 33154-2041 (e-mail: admin@srsMiami.com).

Aesthetic and Functional Genital and Perineal Surgery: Female;

Guest Editors, Christopher J. Salgado, M.D., and Stan J. Monstrey, M.D., Ph.D.

Semin Plast Surg 2011;25:163–174. Copyright © 2011 by Thieme Medical Publishers, Inc., 333 Seventh Avenue, New York, NY 10001, USA. Tel: +1(212) 584-4662.

DOI: <http://dx.doi.org/10.1055/s-0031-1281486>.

ISSN 1535-2188.

during which an Advanced Cardiac Life Support (ACLS-) approved registered nurse and I stay with the patient throughout the night.

Complications requiring hospital admission in the first week are detailed below. Thus far, we have had no serious life-threatening complications or mortalities. Average blood loss is ~200 to 250 cc.

PATIENT SELECTION

Prospective patients receive our “long 16-page letter” prior to scheduling surgery, which contains many advisories and discloses some of the guidelines of the World Professional Association for Transgendered Health⁷ (WPATH, formerly the Harry Benjamin International Gender Dysphoria Association) of which I am a member. Two letters of therapy clearance are required, one from a licensed therapist with a doctoral degree, and the other from a therapist with at least a masters’ degree. One letter is a comprehensive review of the psychodynamics of the individual and the second letter could be regarded as a “letter of concurrence.”

The letters should be written on professional letterhead and begin by introducing the clinician’s background, education, societal memberships, and conclude with an invitation to call and discuss any concerns. The therapist should address issues such as suicidal ideation/attempts, emotional instability, drug abuse, acceptance by others, assimilation in society, possible family discord, the real life test (usually a period of one year or more when the patient has lived 24/7 in the female role), any ambiguity about the procedure, and the possibility of remorse. This information should be capped by a hearty recommendation that the patient is a suitable candidate for transgender surgery.

Letters written saying—in so many words—“Jennifer would like to have the surgery performed” (third-person expression) is usually a letter of acquiescence to a long-standing patronizing patient who is not ready, and may never be, for transsexual surgery. Pick up the phone and verify.

Female hormones are helpful to promote secondary female sexual characteristics, but may not be needed for more effeminate patients. It is not a requirement in our practice.

Although WPATH guidelines are not strict regulations etched in stone, departure should only be taken after generously conferring with the patient’s therapists. In brief what is required are (1) the real life test, (2) two letters, (3) realistic expectations, (4) knowledge that this is an irreversible procedure, and (5) the patient is “at peace” with herself (and equally as important... with you!).

All patients are evaluated as per Physical Status Classification of the American Society of Anesthesiologists (ASA). We do not accept patients with PS-3 (severe systemic disease that results in functional limi-

tations, including poorly controlled diabetes with vascular complications, angina pectoris, prior myocardial infarction, or pulmonary disease that eliminates activity. In general, type I diabetics are considered a class 3 patient unless proven otherwise by a negative thallium stress electrocardiogram (ECG) and acceptable glycosylated hemoglobin A1-C.

The surgeon must also recognize that letters of clearance from therapists are based on sessions that usually are a lot less stressful and more permissive than the stress of surgery followed by an acute postoperative period with insistence on complying with all instructions. At all times the surgeon must be vigilant for any latent psychopathology that might interfere with a smooth and respectful doctor–patient relationship. Once surgery is performed, the surgeon is considered responsible for just about everything—including managing a “lack of contingency” funds. Assisting and conferring with other doctors, medical centers, and social service agencies in the patient’s locale are all within the purview of the operating surgeon’s responsibility.

“Trans”-vaginal surgery is a procedure that has a very long-lasting postoperative period. Issues relating to urethral or meatal stenosis, wound healing, intromission, cosmesis, asymmetry, and so on, persist for sometimes months. Many of our patients are not adequately covered by insurance, so there has to be a discussion preoperatively of the need for contingency funds to provide for a revisit to the surgeon, continuity of wound care in the patient’s locale, and in our setting the remote possibility of a hospital admission.

The checkout list (Fig. 1) before surgery includes many considerations, even the availability of a friend or loved one to stay with the patient for the first few days during convalescence. A hair removal advisory (Fig. 2) is also shared with the patient.

During a phone consultation, past medical history and psychological history is reviewed as well as smoking, HIV status (not a reason for exclusion if in good control), and height–weight confirmation. Overweight patients are known to have a higher incidence of infections and poor wound healing capabilities. Fat against fat does not heal well. Massive weight on the perineal area could result in wound separation.^{8–11} The likelihood of positional neurapraxia and venous thromboses rises when in stirrups for 5 or so hours.¹² Anesthetic induction time, prepping and draping time, postsurgery cleansing, and application of compression dressings add additional time to in-stirrups positioning. Obese patients do not breathe and ambulate as well. On the other extreme, very thin patients do not heal well.¹³ Borderline thin patients are encouraged to consume a high protein diet and may have reduced blood volume reserves; 200 g of powdered protein daily with arginine supplements are advised before and after.

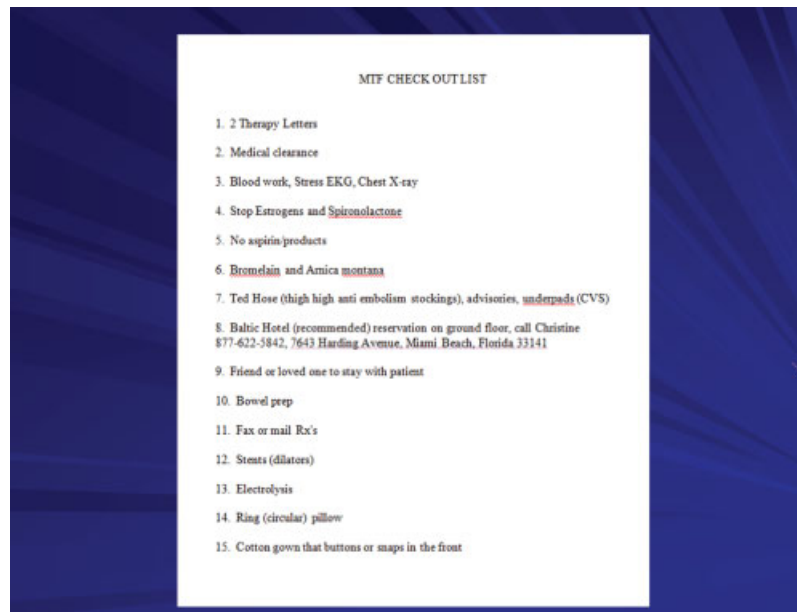


Figure 1 MTF check out list.

Age

The oldest patient we have operated on was 62 and did well—better than many other patients. The youngest patient was age 19. Once an acceptable ASA physical status is ascertained, the most predictable factor in determining ease of successful outcome is not so much age, but *patient compliance with all instructions*.

A thallium stress ECG is generally required for anyone over 40 or on antihypertensive/cardiac medications, or diabetic, or overweight. Medical clearance with an ECG and chest x-ray and coagulation studies is required for all patients regardless of age. Our anes-

thetists are masters of the slow wake up (less laryngospasm and hyperactivity) versus face slapping (“wake up, wake up, the operation is all over”). Smokers and asthmatics are given a continuous epidural without hesitation.

Hemograms in the range of 40/13.5 and above are required and if below, patients are given the choice of erythropoietins: epoetin alfa (Procrit), darbepoetin α (Aranesp), or intramuscular testosterone with iron supplements. Most will opt for testosterone. Estrogens tend to lower hemograms. High levels in males-to-females (MTFs) may signal a veiled smoking history. Arnica montana, dose 30 C, four tablets under the tongue 4 times a day; Bromelain, 500 mg, 1 tablet 2 times a day; and vitamin C, 500 mg, 3 times a day are given empirically to reduce bruising and bleeding. Our experience with these adjuncts is very positive; we can predict how many days before surgery the patient actually started the medication based upon lack of intraoperative oozing.

Usually within 2 to 4 weeks, a satisfactory response to testosterone or erythropoietins is noted. Patients’ concerns are allayed when we say we have not noted any masculinizing effect from a few injections. The cost factor of erythropoietins versus testosterone is ~100 to 1.

Medical history should exclude inflammatory bowel disease and peripheral vascular disease. The physical examination includes a rectal exam, palpation of lower extremity pulses, and stretched penile shaft skin length.

Electrolysis is preferable to laser. Subcutaneous injection of lidocaine or bupivacaine is preferable to a topical anesthetic, which is preferable to nothing at all, as good analgesia permits higher settings, and portends less hair regrowth.

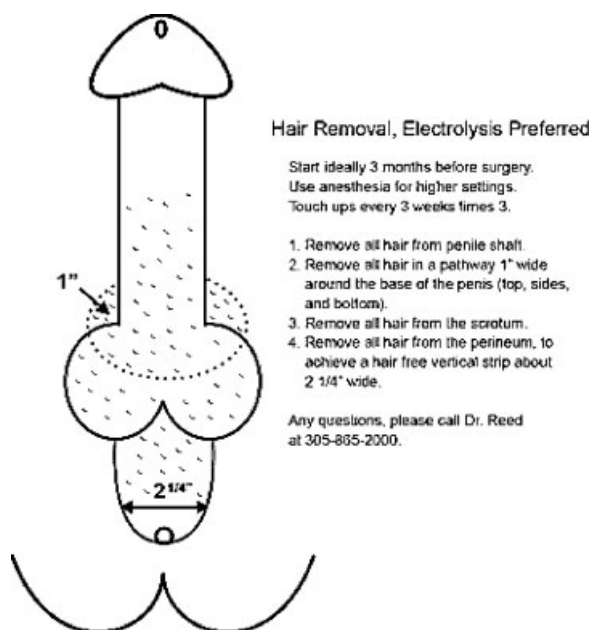


Figure 2 Hair removal advisory.

Informed consent needs to be presented following standard medical ethics as well as legal requirements days in advance of surgery. Ours is posted on our website. Unfamiliar medical terminology has to be explained. Video documentation of knowledge of the consent and the possibility of need for transfusion, hospital transfer, visceral perforation, etc., is disclosed once again to the patient. Any special advisories from the patient that need to be made known to the surgeon such as clitoral size preference, certain somatic requests, small collateral surgical procedures, all have to be discussed on camera in addition to the concept that this is irreversible surgery. I will not perform simultaneous breast implantation and vaginoplasty: too much surgery, too much pain for some patients.

A bowel prep should be started 24 hours before surgery. It includes clear liquids only, a half a bottle of citrate of magnesia at 8 AM and the other half at 4 PM, a Fleet[®] (CB Fleet, Lynchburg, VA) enema at 10 AM, 3 PM, and on the morning of surgery. Also on the day before surgery, neomycin sulfate 1 g and metronidazole 1 g, to be taken by mouth at 1 PM, 2 PM, and 11 PM should be prescribed—"Keep up fluid intake until time of sleep." Bowel preps are dehydrating. Thigh high antiembolism stockings should be tried on and the fabric must be capable of being pulled a good 2.5 cm away from the back of the knee. They are never to be washed or dried before surgery as shrinkage can cause neurapraxia.

In the operating room, ergonomic Yellofin[®] (Allen Medical Systems, Acton, MA) adjustable stirrups are used and the patient is positioned before anesthesia to ensure optimal comfort.

SURGERY

Our approach is penile skin inversion which 90% of the time is supplemented by scrotal graft extension. Preoperative stretched penile shaft skin lengths are noted. Two inches are lost going around the pubic symphysis. Therefore, a length of 4" means a vaginal depth of 2 inches—clearly inadequate. Scrotal grafts usually provide 3 or more inches of depth and with diligent stent usage postoperatively, an additional 2 inches can be gained on top of that. Personally, I do not seek to provide depth greater than 6 inches as I look upon a large cul-de-sac as a liability. Patients are counseled about what they may reasonably expect to achieve immediately postoperatively.

Minimizing Postoperative Bleeding

A fundamental tenet of outpatient surgery without immediate availability of transfusion is to minimize bleeding. Dr. James Glenn has said, "When you are knee deep in alligators it is hard to remember your primary purpose is to drain the swamp." Every step

along the way, bleeding is controlled before proceeding to another step. Using a spreading technique with the Pott-Smith dissecting scissors rather than cutting helps. Epinephrine is our great friend and for this reason, prior to incisions, the surgical planes are injected with a 50/50 solution of lidocaine 1% with epinephrine 1/100,000 and bupivacaine 0.25% without.

The coronal sulcus, the infrapubic area (deep dorsal vascular pedicle) and intertriginous areas, perineum, and base of the penis are all injected using typically 40 cc in total. A syringe filled with 10 cc of lidocaine, 1% with 1/100,000 of epinephrine, and a 25-gauge 1/2" needle is used to inject the bulbous urethra later in the case. Although average blood loss is ~200 to 250 cc, we have had cases with blood loss as low as 100 cc or less. The urethral clamp is removed periodically to drain the bladder: A full bladder compressing the venous return is a cause of venous oozing—"Don't allow bleeding with coagulation to gobble up your platelets."

Surgical Steps

1. Electrolysis is needed for virtually all patients (Fig. 2). Some may have had orchiectomy prior to this procedure; note punctate erythematous lesions of the lower pubis and scrotum (Fig. 3). Position the patient in a comfortable lithotomy position before induction of anesthesia using Yellofin[®] stirrups (Fig. 4).
2. Catheterize the patient using a 20/30 lubricous Bard Foley usually passed with a catheter guide.
3. Remove scrotal skin leaving fat below later to be used to form the labia majora (Fig. 5).
4. Orchiectomy with high ligation of the cords to avoid the "tootsie roll" effect (Fig. 6).
5. Coronal sulcus incision is followed by degloving penile skin.

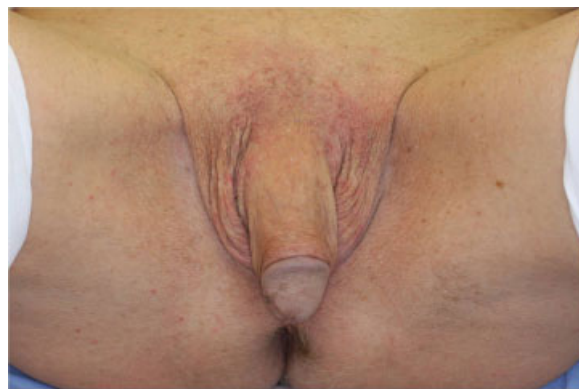

Figure 3 This patient had prior orchiectomy. Note punctate erythematous lesions of lower pubis and scrotum secondary to recent electrolysis.

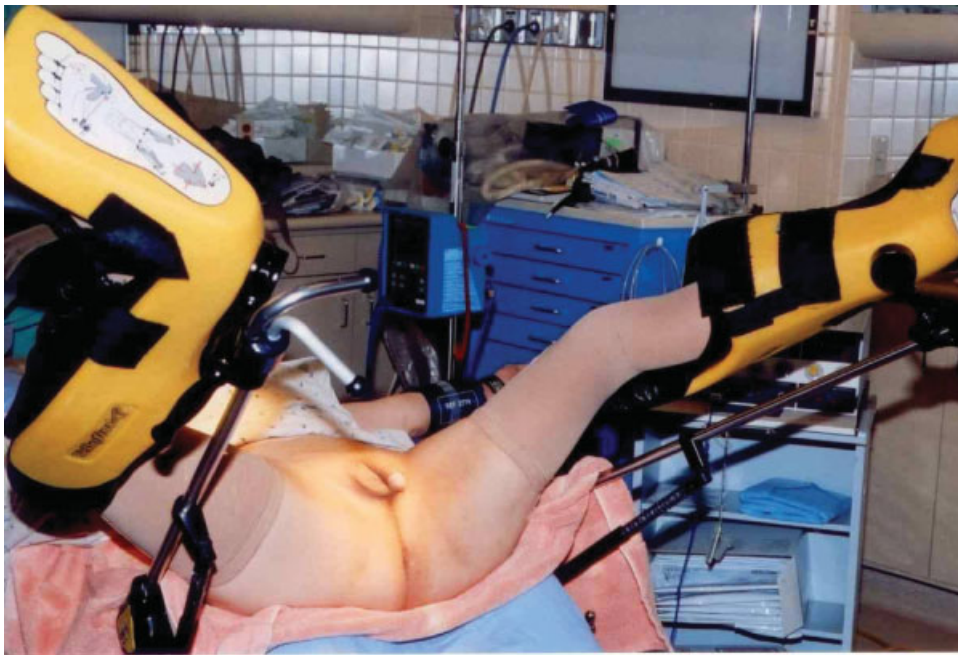

Figure 4 Patient position in stirrups.

6. Inversion of glans, corporal bodies, and urethra toward the perineum.
7. Technician works on the back table to prepare scrotal graft, tubularized over a 1 to 1½ inch stent (Fig. 7).

PREPARING A SCROTAL GRAFT EXTENSION

8. Dismemberment of the penis. The neurovascular bundle is lifted working from ventrolaterally to the midline. Any bleeding is handled exceedingly delicately with low-setting Bovie and a needle tip electrode (tap, tap, tap, not continuous electrical flow). Some surgeons will transect the entire dorsal tunica albuginea with an intact neurovascular bundle. My bias is that this causes more bleeding and some loss of anatomic detail at the hilus of the crus. As the neurovascular bundle extends distally it fans

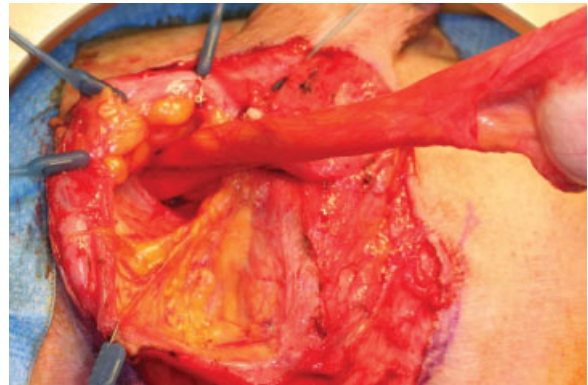


Figure 6 Orchiectomy, preparing for high ligation of the cord.

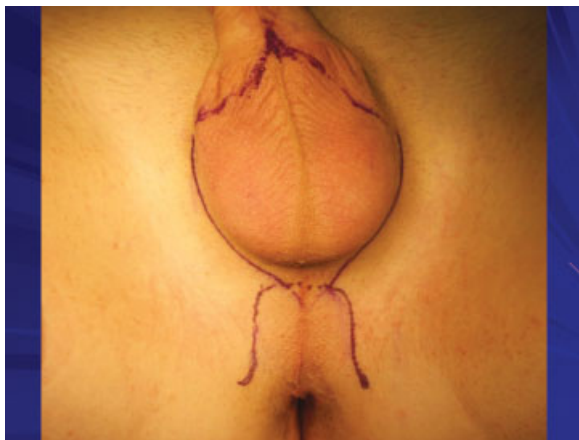


Figure 5 Suggested marking for removal of scrotal skin.

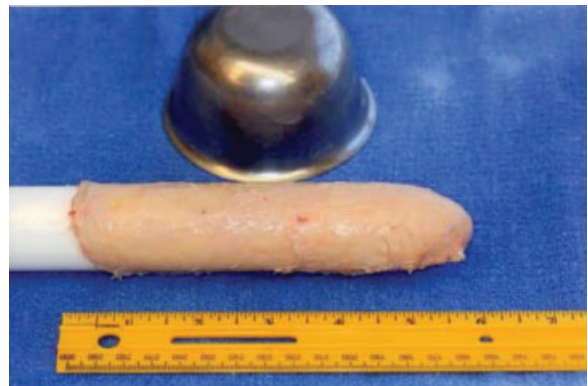

Figure 7 Preparing for scrotal graft extension.

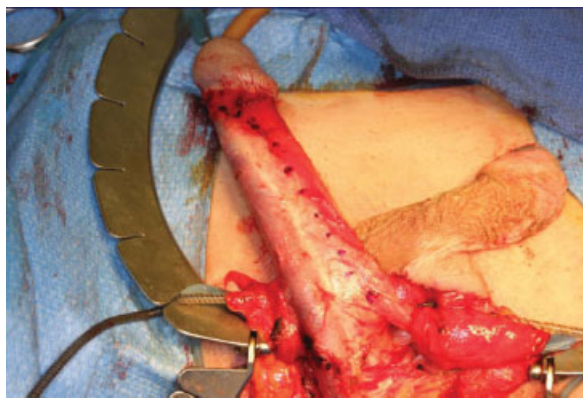


Figure 8 The distal neurovascular bundle fans out more laterally.

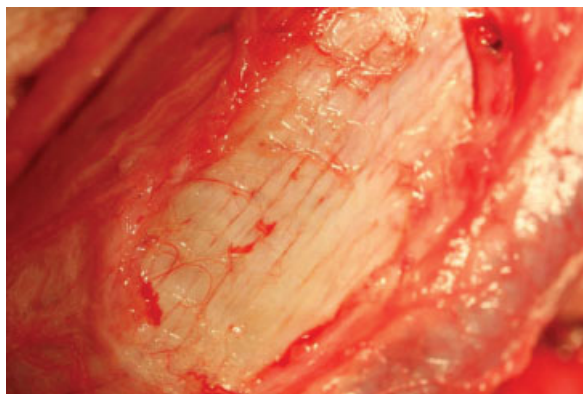


Figure 9 Longitudinal striations indicating the outer layer of tunica albuginea.

out more ventrally (Fig. 8). When lifting Bucks fascia, which envelops the neurovascular bundle, look for vertical striations to indicate the outer layer of the tunica albuginea (Fig. 9).

9. Undermine cap of glans off the dorsal corpora.
10. Remove “wings” of the cap leaving a long “clitoral” body and de-epithelialize most of proximal clitoris. Tubularized the body with 3–0 polyglactin 910 suture. The glans clitoris is the only portion that remains epithelialized (Fig. 10). Prepare a Kuna-

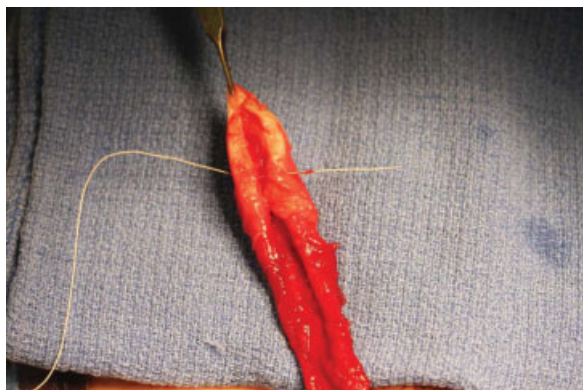


Figure 10 Forming a glans clitoris.

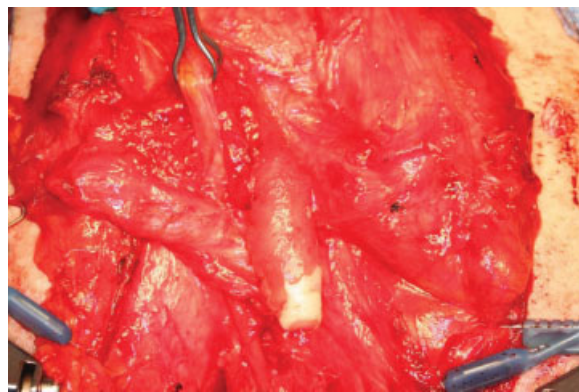


Figure 11 The Kunaporn post.

porn post (credit to Dr. Sanguan Kunaporn), a fibrous column of connective tissue under the pubic midline slightly off to the right and pass the clitoris and neurovascular bundle under the “post” and have it drop down in the vertical midline. This avoids kinking (Fig. 11).

11. Dismember urethra from the underside of corporal bodies. The more proximal the urethra, the more easy the separation. Bleeding is controlled with a noncrushing DeBakey vena cava vascular clamp.
12. Create the perineal flap incision, defatting any especially well-represented fat from the distal portion of the “tongue” to promote better flap take. Remove also fat overlying bulbous urethra and bulbous spongiosum-urethralis muscle to expose a clean serosal ventral bulbous surface. Use a Scott ring retractor to facilitate exposure.
13. Approach the rectourethralis ligament as close to the serosal surface of the bulbous urethra as possible (the gateway to the retrovesical, prerectal pelvic space). Blunt digital dissection lateral to the ligament and gentle upward traction on the bulb with a Deaver retractor usually helps. Snip, spread, snip cautiously. Use a gloved finger to verify that you are past the place of resistance. Once so, a gloved finger or Deaver will gently open a midline space quite easily with surprisingly no bleeding. Use a Deaver to gain an acceptable depth of 6” or more inches. Some bleeding is easily handled with a lap sponge previously dipped in a placenta basin containing ~300 cc of normal saline and an amp of 1 mg of epinephrine (as seen in Gent for breast surgery; Dr. Monstrey’s service). Anesthesia is prealerted, but seldom is there any tachycardia or elevated blood pressure. Some say feel for the back wall of the prostate, but in most of my patients, the prostate is so involuted one cannot truly discern its presence. Palpation of the Foley balloon may confirm you are at last at the level of the base of the bladder.

14. Now it is time to rule out rectal injury or perforation by first cleansing the anus and perineal skin with hydrogen peroxide, removing any coagulum. A lubricated double glove is passed into the rectum to confirm the absence of blood. Lack of a blood smear is highly confirmatory for "no rectal injury." If seen, feel for any perforation of the anterior wall, then oversew the perforation with a double layer of 2-0 Vicryl. By all means, continue with the surgery. Bowel diversion (in my opinion) is unnecessary.
15. Irrigate the pelvic space with 300 cc of normal saline (NS) and 1 amp of gentamicin (80 mg). Returns should be clear. Reinsert a long Deaver and feel the lateral space for any intruding shelf of the levator ani. Incise with blended cautery current gently to suit. Usually 1 cm on each side is sufficient. Again, you may wish to apply a lap sponge soaked with epinephrine to control small oozing.
16. While packing is in place, attach the scrotal graft to the inverted penile skin by passing the stent with graft through the opening of penis at the base. Secure major quadrants with 2-0 polyglactin (Vicryl) and the rest with 3-0 Vicryl. Please two Keith needles with 0 polypropylene (Prolene) traction suture through each distal "toe" edge (Fig. 12). If more depth is required prepare and attach scrotal graft. The scrotal graft is attached to the inverted penile skin (Fig. 13).
17. The pelvic lap is removed. The urethral bulb is injected with ~5 cc of lidocaine 1% with 1/100,000 of epinephrine. After a few minutes, marked shrinkage will be noted. Several plication sutures of 3-0 polyglactin 910 are passed through the spongiosum to reduce distal vascularity. Feel for the presence of the catheter dorsally before passing the needle under and along side it.
18. The bladder is drained. The patient is placed in deep Trendelenburg (viscera moves superiorly) and using a Furlow tool (American Medical Systems), the Keith needles are passed from deep inside the pelvic

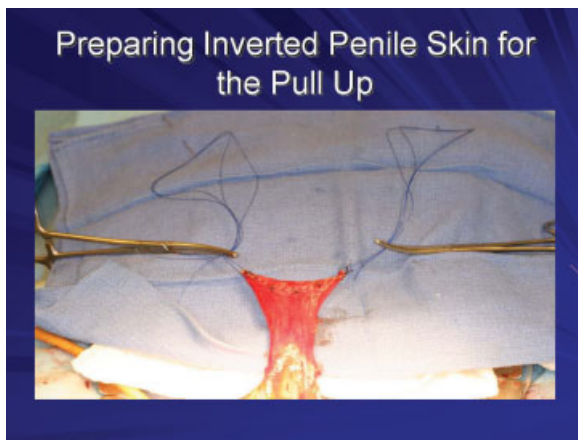


Figure 12 Pull-up sutures.

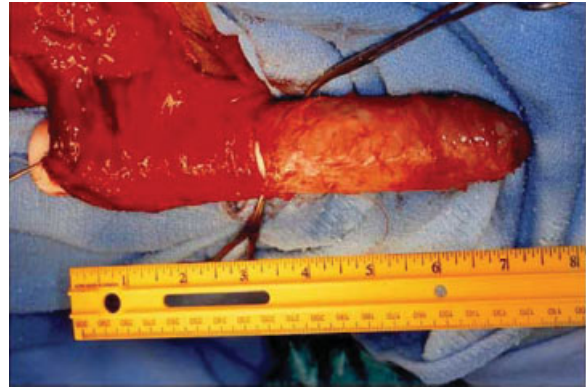


Figure 13 Scrotal graft extension.

- space to the pubis and ultimately tied over dental rolls. Tie sutures down gently. Depression of the rolls into the skin will produce permanent skin changes. An alternate method proposed by Stanojevic and group is sacrospinous ligament fixation for prevention of neovaginal prolapse.¹⁴
19. Prior to tying the Prolene sutures, place a Deaver in the vagina, apply some downward traction to gauge where the back of the wall of the penile skin will ultimately overlie the lower pubic symphysis in preparation to exteriorize both the urethra with catheter and clitoris onto the "vulvar plate." Remember, the result will always be some upward shifting of this incision, so compensate. The glans or side of the clitoral body must be temporarily fixed with a few sutures of 4-0 Vicryl or its retraction will pose a nuisance.
 20. As the vaginal stent is pulled downward, it is apparent there is pulling of the inverted penile tissue upwards toward the yoke of the inverted skin (at the level of the pubis). This tension cannot be allowed to persist, lest the patient will have an elevated posterior commissure. This tension has to be released by a long longitudinal incision on the posterior wall of the neovagina, which now permits the stent to pass into the vagina without upward retraction of the posterior introitus.
 21. The flap is sewn (advanced) into this defect and in effect becomes the back wall of the distal vagina.
 22. A Deaver is placed in the vagina to promote deep fixation of the vaginal vault and the traction sutures are then tied. Any small amount of pelvic bleeding easily responds to iodoform vaginal packing. Typically, at this time, the patient is perfectly dry. Fixation sutures of 2-0 Vicryl from the outer posterior lateral vaginal wall to connective tissue in the posterior-lateral perineal area promotes vaginal fixation (as shown by Dr. Marci Bowers).¹⁵
 23. Excessive fat in the labial majora area is lifted and clamped transversely with a Kocher and excised with cautery. After release, spend a few moments looking

for bleeding sites there, and later anywhere in the prepared labial skin margins and fat. Large double-skin hooks are helpful. Attention is then directed to removing redundant lateral intertriginous and penile skin, forming pleasing labia majora.

24. Most importantly, a towel clip or similar instrument tension is applied posterolaterally on penile skin to see what balance of approximation and tension bilaterally will produce a recessional area for the inner labia minora.

MORPHING A TABLE LINEN TO A LABIA MINORA (FIG. 14)

This will define the clitoral body and help simulate the clitoral sulci that are seen just lateral to the body. The rest of the labia sutures are applied in a bisecting tailor-tack manner removing redundant tissue along the way. The upper ends of the incision, somewhat superior to the clitoris if at all possible are directed medially and closed fairly early to preclude dog ears. A Jackson Pratt drain, which exits from the left inguinal area, drains the left labial compartment and traverses perineally underneath the vagina to pass upwardly draining the right side as well.

25. The clitoris is then permanently positioned with small exposure of the glans. An alternative approach is to leave distal dorsal penile shaft skin attached to the glans penis, which helps to create a retractable hood. Our bias is to increase the length of the clitoral body because its elongated prominence is cosmetically appealing and usually some skin will

epithelialize the inside of the hood over a glans tip in which epithelium has not been removed.

26. Note the noncrushing urethral clamp is still applied. The distal urethra is spatulated ventrally. An ideal separation between the urethral opening and the clitoris is ~2.0 to 3 cm. Any redundant urethra beyond that needed to comfortably reach the glans is excised and discarded. The noncrushing clamp that had been on the exteriorized urethra all the time is finally removed, as urethral oozing is the most likely cause of post-operative hemorrhage.

The edges are oversewn with 4-0 Vicryl Rapide. Excessive spongiosum tissue (the back wall) can be removed carefully. The urethral meatus must be just below the pubic symphysis, otherwise there will be an upward trajectory and splaying of the stream. Voiding will be directed at the rim of the commode. If necessary, a more downward extension of the opening with flaring ensures the urethra opens funnelized and is everted slightly. Sutures to promote eversion can also be placed prior to fixating the urethra to the vulvar plate (penile skin) as suggested by Dr. Monstrey (Gent, Personal communication, Belgium visit, November 19, 2007).

The patient is cleansed with warm water and hydrogen peroxide and patted dry. Benzoin is sprayed over the incision lines, the lower abdomen, and perineum and buttocks. Shur-Strips® (stretchable steri-strips are applied as needed.) The urethral area is covered with folded 4 by 4s and one to three absorbent dressings are applied that are covered with a Elastoplast swathes

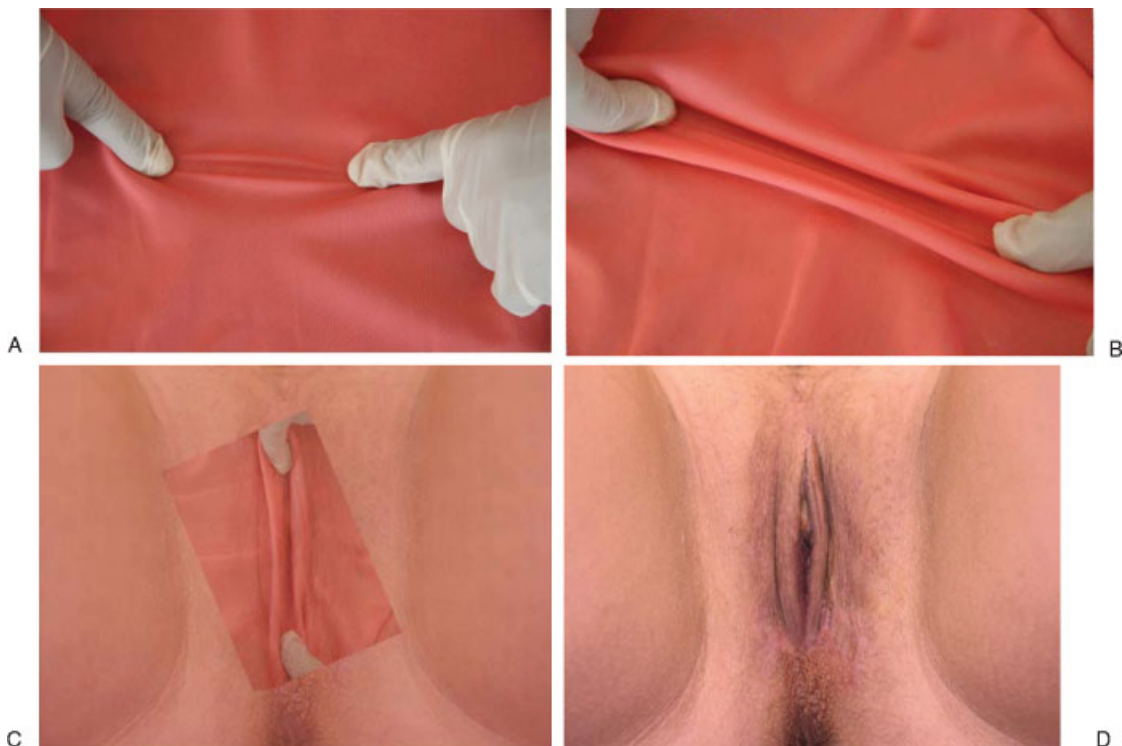


Figure 14 (A–D) Morphing a table linen into a labia minora.

divided both anteriorly and posteriorly around the anal verge.

POSTOPERATIVE CARE

An ice pack in a pillowcase elevated by a small folded towel is applied to the perineum, which reduces pain and minimizes bruising. Movement of the lower extremities (knees, feet, and toes) is encouraged “100 times” a day. Patients will be able to take fluids as tolerated the evening of surgery. The next day after transfer to a local hotel—where they have walked to their hotel room—the patient is placed on an unrestricted diet as tolerated. Most of our patients are out of bed 2 to 3 times a day the first postoperative day; by the third to fourth day are checking out local stores near the hotel.

The Jackson Pratt drain is removed when drainage is less than 15 cc in 24 hours, usually day 3 to day 5.

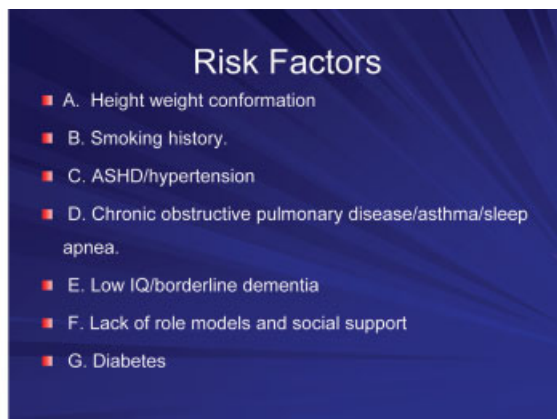
On postoperative day 7, packing is removed along with pullup sutures. Patients are instructed in the use of stents (Fig. 15) and how to douche. Discharge instruc-



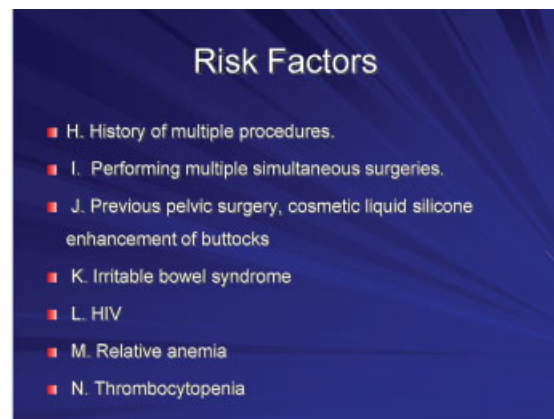
Figure 15 Vaginal stents.



Figure 16 (A–D) Mature postoperative results.



A



B

Figure 17 Risk factors.

tions are reviewed again. It is helpful to have a “significant other” present for assimilation of information. Eighty percent of patients return home that day.

The catheter is removed on postoperative day 12. This avoids the 20% who go into urinary retention when the catheter is removed on day 7 and who while traveling home, go into panic mode and incur costly medical care.

The mature postoperative results of the procedure can be seen in Fig. 16. A list of risk factors is provided in Fig. 17.

DISCUSSION

Some distinguished surgeons use a good part of penile skin for the labia minora, but the results I have seen appear floppy and draped, and are reminiscent of the way natal females present who request more delicate labia. This appearance is certainly normal for many natal females, but so is lots of pubic hair. My approach is another way. This boils down to a matter of personal aesthetics.

Some surgeons will cut into the spongiosum urethra removing a wedge as a means to avoid urethral spongiosum rest protrusion during arousal.

However, this is often a very bloody procedure whereas my objective is to minimize bleeding, knowing

that at touch-up time in 3 months after complete wound healing, I can tend to that then with very low risk.

My responsibility is to make our patients a “turn on.” About 80% will return for a touch up, for which there is no charge unless general anesthesia is required. We are seeking the best cosmetic result. Nonetheless, I would advise any transsexual patient to disclose beforehand their status to their intended intimate partner, to avoid an unforeseen and dangerous hostile reaction. In that the anterior pelvic triangle is the cradle for the neolabia, men unfortunately have a more acute angle (android pelvis), and consequently the base between the ischial tuberosities is narrower. This means the vaginal introitus must be as posterior as possible to permit ease of penetration.

CASE EXPERIENCE

Our case experience is detailed in Fig. 18.

Complications

A list of complications is given in Fig. 19. Slow bleeding may be controlled with sufficient compression and/or reinforcement with an Elastoplast[®] (Beiersdorf, Bir-

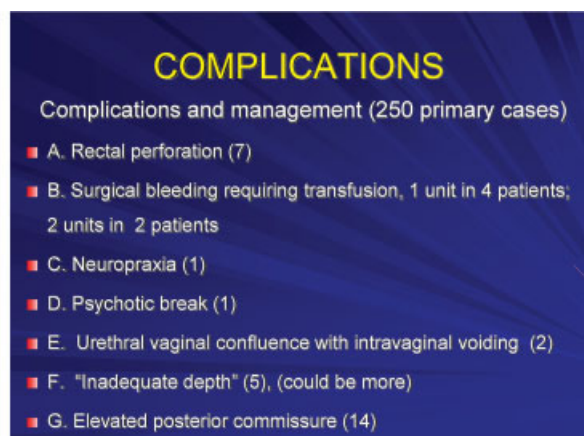
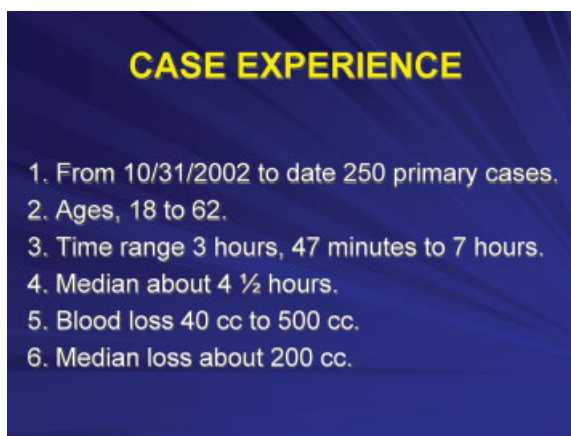
**Figure 18** Case experience.

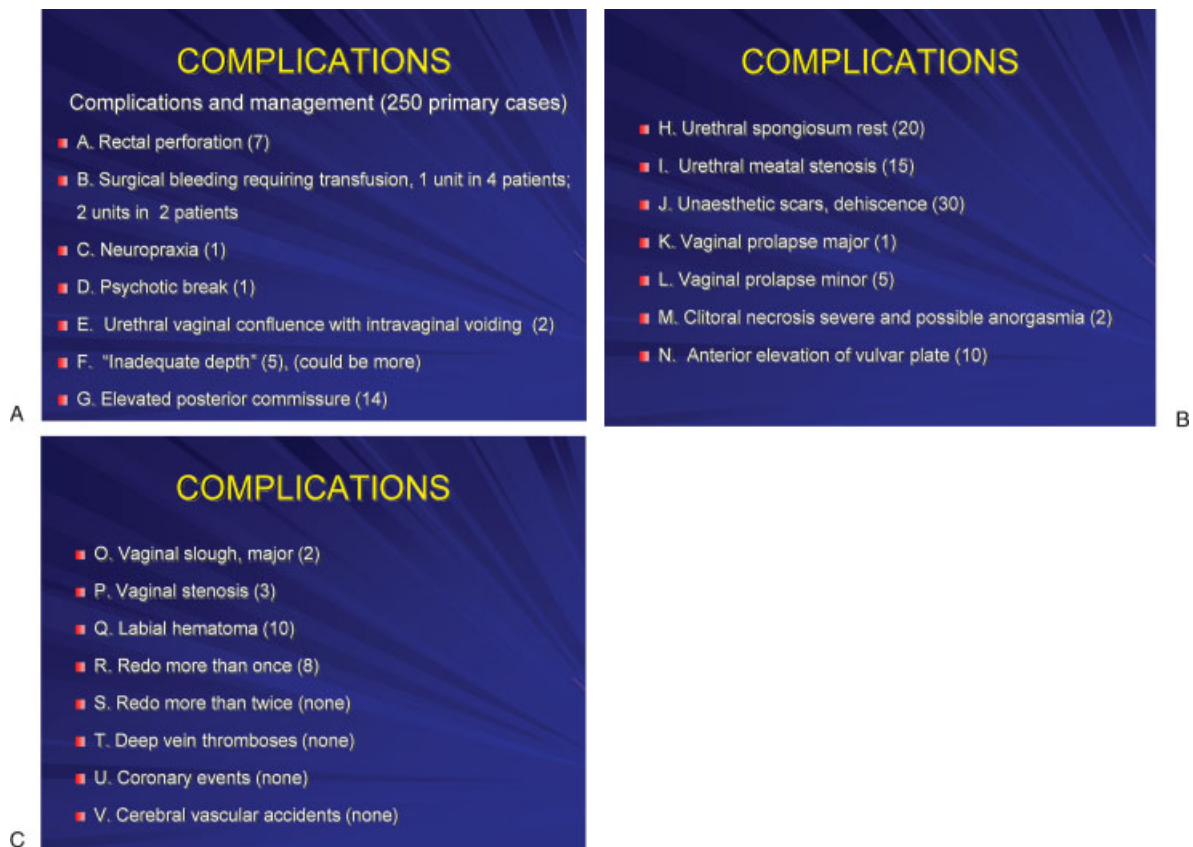

Figure 19 Complications.

mingham, UK) dressing. Meatal stenosis requires ventral opening of the meatus and more spatulation of mucosal skin. It is seldom nothing more than that, hardly ever an elongated stricture. Shedding of vaginal tissue may represent trauma or the failure of a graft or flap to take and is managed conservatively with interval debridement and perhaps metronidazole gel (MetroGel[®] vaginal; Galderma Laboratories, Ft. Worth, TX).

Rectal Perforation

Intraoperatively, all coagulum is cleansed from the anal area with hydrogen peroxide, and a double gloved finger is routinely placed in the rectum to exclude perforation (not a trace of blood on the glove). If noted, 2–0 polyglactin 910 (Vicryl) is employed to close the defect in a two-layered manner. After copious irrigation with a dilute gentamicin solution, surgery continues; we have never found it necessary to do a bowel diversion. The patient is started on fluids only, supplemented by protein diet for 10 days, and then a low residue until closed. In general, 200 g of protein a day with arginine supplements are recommended. Every perforation has healed spontaneously.

I have never seen a deep pelvic abscess in any patient with a rectal perforation in my experience. All have invariably closed. As Dr. Meltzer has said, keep dilating anteriorly, if possible. For those patients who

return for a second stage, the anterior commissure is closed with a wishbone incision (de-epithelialization of the skin within) and approximation vertically in the midline, or in the manner of Dr. Meltzer.¹⁶ Unsightly scars are revised, shifting tissues are brought back into place, elevated posterior commissures receive a secondary Y-V plasty. Concerns about asymmetry are addressed, and the urethra may be re-sited more posteriorly.

CONCLUSION

Standing on the shoulders of giants, I am indebted to the many surgeons mentioned above who have preceded me and have been highly instructive. They have influenced my surgical approach, which is still in evolution. We are all seeking near perfection. Knowing what not to do is as important as knowing what to do.

REFERENCES

1. Hoyer N, Steining HJ, Haire N. Man into Woman. New York: EP Dutton & Co; 1933
2. Laub DR, Gandy P eds.. Proceedings of the Second Interdisciplinary Symposium on Gender Dysphoria Syndrome. Stanford, CA: Stanford University Medical Center, Division of Reconstructive and Rehabilitation Surgery; 1973

3. Hage JJ. Vaginoplasty in male-to-female transsexuals by inversion of penile and scrotal skin. In: Ehrlich RM, Alter GJ eds. *Reconstructive and Plastic Surgery of the External Genitalia, Adult and Pediatric*. Philadelphia, PA: WB Saunders; 1999:294–300
4. Bowers M. 5-year experience with one-stage vaginoplasty: results and techniques. Paper presented at: Biannual Meeting of World Professional Association for Transgender Health; June 18, 2009; Oslo, Norway.
5. Perovic SV, Stanojevic DS, Djordjevic ML. Vaginoplasty in male transsexuals using penile skin and a urethral flap. *BJU Int* 2000;86(7):843–850
6. Selvaggi G, Ceulemans P, De Cuyper G, et al. Gender identity disorder: general overview and surgical treatment for vaginoplasty in male-to-female transsexuals. *Plast Reconstr Surg* 2005;116(6):135e–145e
7. Watanyusakul S. The results of sensated clitoris and labia minora reconstruction using dorsal neurovascular glans penis preputial island flap (Chonburi flap) in MTF reassignment surgery. Paper presented at: 9th Oriental Society of Aesthetic Plastic Surgery (OSAPS); December 6–10, 2004; The Shangri-La Hotel, Bangkok, Thailand
8. Meyer W, Bockting WO, Cohen-Kettenis P. The Harry Benjamin International Gender Dysphoria Association's Standards of Care for Gender Identity Disorders, Sixth Version, February 2001. Available at: <http://www.wpath.org/documents2/socv6.pdf>. Accessed March 20, 2010
9. Waitsbren E, Rosen H, Bader AM, Lipsitz SR, Rogers SO Jr, Eriksson E. Percent body fat and prediction of surgical site infection. *J Am Coll Surg* 2010;210(4):381–389
10. Spiliotis J, Tsiveriotis K, Datsis AD, et al. Wound dehiscence: is still a problem in the 21th century: a retrospective study. *World J Emerg Surg* 2009;4:12
11. Hanemann MS Jr, Grotting JC. Evaluation of preoperative risk factors and complication rates in cosmetic breast surgery. *Ann Plast Surg* 2010;64(5):537–540
12. Stoelting RK, Miller RD. Positioning and associated risks. In: *Basics of Anesthesia*. New York: Churchill Livingstone; 2000:196–208
13. Haydock DA, Hill GL. Impaired wound healing in surgical patients with varying degrees of malnutrition. *JPEN J Parenter Enteral Nutr* 1986;10(6):550–554
14. Stanojevic DS, Djordjevic ML, Milosevic A, et al; Belgrade Gender Dysphoria Team. Sacrospinous ligament fixation for neovaginal prolapse prevention in male-to-female surgery. *Urology* 2007;70(4):767–771
15. World Professional Association for Transgender Health Symposium. Chicago, IL. September 7, 2007.
16. Lawrence A. Transsexual Women's Resources. Available at: <http://www.annelawrence.com/twr/labiaplasty.html>. Accessed March 20, 2010