

Forty years without symptoms after choledochogastrostomy

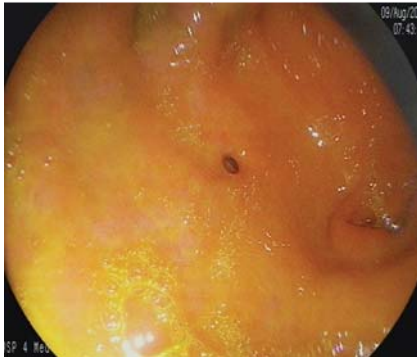


Fig. 1 Ostium of the choledochogastrostomy in the antrum of the stomach.

The preferred surgical procedures for internal biliary drainage are choledocho(hepatico)jejunostomy and choledochoduodenostomy. Cholangiogastrostomy is not recommended because of the potential risk of bile gastritis, and because reflux of gastric fluid into the biliary tree could occur and cause complications in the long run. In addition, after cholangiogastrostomy anastomotic leakage would be of both bile and gastric juice, whereas after drainage into the small bowel the leakage

would consist predominantly of bile. Cholangiogastrostomy by surgery, endoscopy, or by a combined fluoroscopic, endoscopic, and laparoscopic approach have been described [1–3]. However, these procedures were mostly used in patients with advanced malignant disease, and therefore data concerning the long-term risks of biliary drainage into the stomach are limited. To the best of our knowledge this is the first report about a patient who was free of symptoms during a follow-up period of several decades after choledochogastrostomy.

A 72-year-old white woman was admitted to hospital because of nausea and upper abdominal pain, which had started 3 days before admission. There was a history of hypertension, chronic obstructive pulmonary disease treated with corticosteroids, and cholecystectomy 40 years previously. Routine laboratory tests and abdominal sonography were normal.

During gastroscopy the endoscopist was astonished to see a small ostium with a diameter of 2 mm in the anterior wall of the antrum (► Fig. 1). There was a considerable amount of bile in the stomach. The

mucosa of the stomach and duodenum was macroscopically normal; in the esophagus white plaques were seen and a diagnosis of fungal esophagitis was established. Histologic examination of routine biopsies taken from the antrum and body of the stomach revealed only minimal inflammation. After ingestion of water-soluble contrast medium, opacification of the whole biliary tree via an anastomosis between the common bile duct and the antrum was seen (► Fig. 2). When asked about details concerning her past operations, the patient reported that due to a postoperative complication a re-laparotomy with surgical intervention on the biliary tree had been necessary a few days after cholecystectomy. No detailed information about this operation could be obtained. The fungal esophagitis was treated with nystatin and the patient was free of symptoms after 2 days.

As ingestion of contrast medium resulted in opacification of the whole biliary tree in our patient, reflux of gastric acid into the biliary tree also has to be assumed. Despite this fact, she has been without symptoms during a follow-up period of 40 years after choledochogastrostomy, indicating that after this procedure a clinical course free of complications such as cholangitis, bile duct stenosis, and bile gastritis is possible even in the long run.

Endoscopy_UCTN_Code_CCL_1AB_2AD_3AF

Competing interests: None

R. Schwarzer, A. Tischer, M. Dulic, E. Dulic-Lakovic, S. Assadi, M. Gschwantler

4th Department of Internal Medicine, Wilhelminenspital, Vienna, Austria

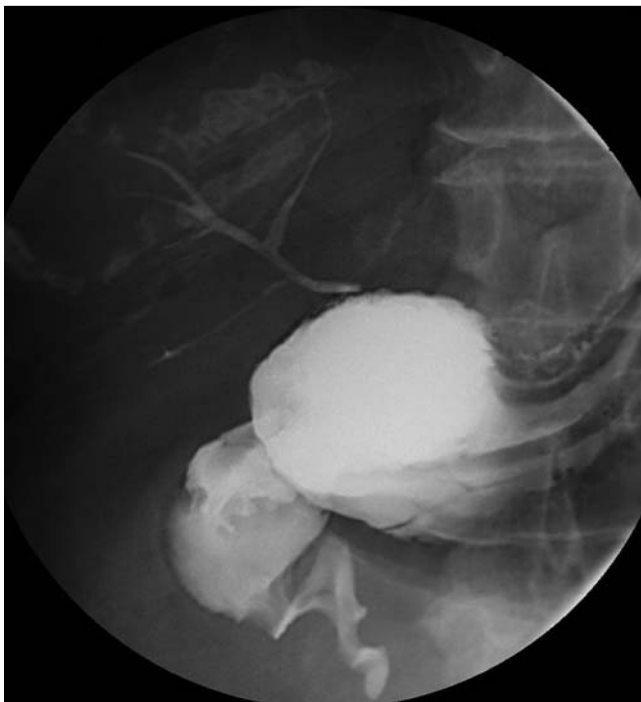

Fig. 2 Opacification of the whole biliary tree via a choledochogastrostomy after ingestion of water-soluble contrast medium.

References

- 1 *Ramesh H.* Intrahepatic cholangiostomy for malignant biliary obstruction at the hilum. *Br J Surg* 1992; 79: 1349–1350
- 2 *Chopin-Laly X, Ponchon T, Guibal A* et al. Endoscopic biliogastric stenting: a salvage procedure. *Surgery* 2009; 145: 123
- 3 *Soulez G, Thérasse E, Oliva VL* et al. Left hepaticogastrostomy for biliary obstruction: long-term results. *Radiology* 1997; 204: 780–786

Bibliography

DOI <http://dx.doi.org/10.1055/s-0032-1306902>
Endoscopy 2012; 44: E199–E200
© Georg Thieme Verlag KG
Stuttgart · New York
ISSN 0013-726X

Corresponding author

M. Gschwantler, MD
4th Department of Internal Medicine
Wilhelminenspital
Montleartstrasse 37
1160 Vienna
Austria
Phone: +43-1-491502401
Fax: +43-1-491502409
Michael.Gschwantler@wienkav.at