

Surgical and Conservative Management of Symptomatic Leiomyomas during Pregnancy: a Retrospective Pilot Study

Operatives und konservatives Therapiemanagement von symptomatischen Leiomyomen in der Schwangerschaft: eine retrospektive Pilotstudie

Authors

R. Rothmund¹, F. A. Taran¹, B. Boeer¹, M. Wallwiener², H. Abele¹, R. Campo³, D. Wallwiener¹, S. Brucker¹, K. Rall¹

Affiliations

¹ Women's Clinic, University Tübingen, Tübingen

² Women's Clinic, University Heidelberg, Heidelberg

³ Leuven Institute for Fertility and Embryology, Leuven, Belgium

Key words

- symptomatic leiomyomas pregnancy
- myomectomy
- degenerating leiomyoma

Schlüsselwörter

- symptomatische Leiomyome Schwangerschaft
- Myomektomie
- nekrotisierende Leiomyome

received 11.12.2012
revised 11.3.2013
accepted 12.3.2013

Bibliography

DOI <http://dx.doi.org/10.1055/s-0032-1328437>
Geburtsh Frauenheilk 2013; 73: 330–334 © Georg Thieme Verlag KG Stuttgart · New York · ISSN 0016-5751

Correspondence

Dr. Florin Andrei Taran
University Tübingen
Women's Clinic
Calwerstraße 7
72076 Tübingen
florin.andrei.taran@gmail.com

Abstract



Purpose: Evidence regarding distinguishing characteristics of women with symptomatic leiomyomas during pregnancy who undergo myomectomy during pregnancy and those who respond to conservative treatment is sparse because it mostly derives from case reports and small patient series. As the first of its type, the present study analyzed the characteristics of women with symptomatic leiomyomas treated with myomectomy during pregnancy and those treated conservatively.

Methods: We performed a computer search of medical records from 1 January 2001 to 31 March 2011 using the International Classification of Diseases Codes for pregnancy, myomectomy and leiomyomas during pregnancy.

Results: 27 patients were admitted during pregnancy directly related to leiomyomas; 17 of the 27 patients received conservative treatment for symptomatic leiomyomas, and 10 patients had surgery during pregnancy: 3 had undergone diagnostic surgical procedures and 7 myomectomy. Perioperative and postoperative morbidity was low in all women in our sample.

Conclusion: In our pilot study, myomectomy during pregnancy was safely performed in carefully selected patients, with subserosal or pedunculated leiomyomas that failed to respond to conservative treatment, with low perioperative and postoperative morbidity.

Introduction



Leiomyomas (fibroids or myomas) are common benign myometrial neoplasms composed of

Zusammenfassung



Fragestellung: Hinweise auf spezifische Charakteristika von Frauen mit symptomatischen Leiomyomen während der Schwangerschaft, die sich einer Myomektomie in der Schwangerschaft unterziehen, und solchen, die gut auf eine konservative Therapie ansprechen, sind sehr gering, v.a., weil sie meist aus Fallberichten und Studien mit kleinen Kollektiven stammen. Als erste Studie dieser Art verglich die vorliegende Studie die Charakteristika von konservativ und operativ behandelten Schwangeren.

Material und Methodik: Eine computergestützte Suche aller Behandlungsunterlagen aus unserer Einrichtung vom 1. Januar 2001 bis 31. März 2011 wurde durchgeführt und dabei die International Classification of Diseases (ICD) Codes für Schwangerschaft, Myomektomie und Leiomyome während Schwangerschaft verwendet.

Ergebnisse: 27 Patientinnen wurden unmittelbar wegen Myomen in der Schwangerschaft aufgenommen; 17 der 27 Patientinnen erhielten eine konservative Therapie bei symptomatischen Myomen und 10 unterzogen sich einer Operation: 3 erhielten ein diagnostisches Vorgehen und 7 eine Myomektomie. Die peri- und postoperative Morbidität war niedrig im gesamten Patientinnenkollektiv.

Schlussfolgerung: In unserer Pilotstudie erwies sich die Myomektomie in der Schwangerschaft als eine sichere Methode in einem sorgfältig ausgewählten Patientinnenkollektiv, mit serösen oder gestielten Myomen, die auf eine konservative Therapie nicht angesprochen haben, mit niedriger peri- und postoperativer Morbidität.

smooth muscle [1]. Leiomyomas represent the primary indication for hysterectomy in the United States, Germany, France and England and are estimated to occur in 20–80% of reproductive-age

women [2–4]. Leiomyomas can be asymptomatic, but can also cause a variety of symptoms such as menorrhagia, pain, pelvic pressure, and bowel and urinary tract complaints [3,5,6].

Leiomyomas have a prevalence during pregnancy of up to 20% and they have been associated with an increased obstetric complication rate, such as an increased incidence of spontaneous abortions, fetal malpresentation, intrauterine growth restriction, placenta previa, labor dystocia, placental abruption, retained placenta, preterm labor, premature rupture of membranes, postpartum hemorrhage, and an increased frequency of cesarean sections [7–11]. Nevertheless, little is known about the exact prevalence of leiomyomas in pregnancy and the rate of complications related to or caused by leiomyomas during pregnancy, most of which are asymptomatic [10,12,13].

There is, therefore, no consensus regarding the best approach to the treatment of symptomatic leiomyomas during pregnancy. Conservative treatment is the first option, but the incidence of complications after conservative treatment varies greatly, with rates of up to 38.4% [7, 14]. Evidence regarding surgical treatment for symptomatic leiomyomas during pregnancy is sparse and mostly derives from case reports and small patient series [8, 14]. The present study analyzed a group of women with symptomatic leiomyomas during pregnancy who underwent myomectomy during pregnancy and those treated conservatively.

Methods

We performed a computer search of medical records at the Department of Obstetrics and Gynaecology, University Women's Clinic, Tuebingen, Germany, from 1 January 2001 to 31 March 2011 using the International Classification of Diseases Codes for pregnancy, myomectomy and leiomyomas during pregnancy. This search identified 204 charts, which were retrieved and reviewed. The criterion for inclusion in the study was admission during pregnancy related directly to uterine leiomyomas. If the finding of leiomyoma was incidental to admission, the patient was not included in the study. Patients with first-trimester spontaneous abortions were also not included. All patients had an ultrasound scan on admission; the number and location of the leiomyomas were captured.

Data were coded and entered into an Excel spreadsheet (Microsoft, Redmond, Washington, DC, USA). Statistical analysis was carried out using JMP for Windows, 7.0.1 (SAS Institute, Cary, NC, USA). We report means and standard deviations or medians for continuous variables and frequency counts and percentages for nominal or categorical variables.

Results

Twenty-seven patients (out of 204, 13.2%) were admitted during pregnancy directly related to leiomyomas. All patients received conservative treatment upon admission, consisting of analgesic treatment, antibiotic therapy and tocolytic agents. Conservative treatment was effective in seventeen of the 27 patients (63.0%) with symptomatic leiomyomas. Ten patients (37.0%) had surgery during pregnancy: 3 (11.1%) had undergone diagnostic surgical procedures and received conservative treatment and 7 (26.0%) patients underwent myomectomy; indication for surgery were symptomatic leiomyomas during pregnancy that failed to respond to conservative treatment. The patients who had under-

Table 1 Subject characteristics and pathological findings of the two patient groups.

	Myomectomy group (n = 7)	Conservative treatment group (n = 20)
Age (mean ± SD)	34.8 ± 4.3	31.3 ± 4.9
Gestational age at admission (mean ± SD)	16.8 ± 2.5	22.7 ± 4.6
Gestational age at delivery (mean ± SD)	38.1 ± 3.9	38.0 ± 0.3
Mode of delivery		
▶ Cesarean section, n (%)	6 (85.7)	8 (47.1)
Duration hospitalization	15.3 ± 9.7	8.7 ± 6.6
Diameter largest leiomyoma (mean ± SD)	15.5 ± 4.0	8.7 ± 2.7
Total number of leiomyomas (mean ± SD)	2.6 ± 0.9	1.8 ± 0.9
Location largest leiomyoma		
▶ pedunculated/subserosal, n(%)	7 (100)	5 (29.4)

gone diagnostic surgery were also included in the group of patients with symptomatic leiomyomas during pregnancy who received conservative treatment. The indications for admission, inpatient course, operations, clinical and pregnancy outcomes of the patients were retrieved.

Among the 27 patients admitted with symptomatic leiomyomas during pregnancy, 26 had singleton pregnancies and one patient had a twin pregnancy. Among the twenty patients (74.0%) with symptomatic leiomyomas during pregnancy from the conservative treatment group; 17/20 (85.0%) received conservative treatment and 3/20 (15.0%) received conservative treatment and underwent diagnostic surgery because of symptoms or an uncertain diagnosis. One patient who received conservative treatment was lost to follow-up. Subject characteristics and pathological findings of the two patient groups are listed in **Table 1**.

Seven patients (26.0%) with symptomatic leiomyomas underwent myomectomy during pregnancy (**Fig. 1, 2 and 3**) (**Table 2**). The mean time elapsed between admission and decision to perform surgery was 62.2 hours (range 24.0–120.0 hours). During surgery, 13 leiomyoma specimens were taken; 7 were pedunculated and 6 were subserosal.

Among the 3 women with symptomatic leiomyomas during pregnancy (mean gestational age: 20.0 weeks [range 17.5–24.4]), who underwent diagnostic surgery, 2 had laparoscopy (one for refractory pain and one for refractory pain and a presumed ovarian mass) and the third underwent exploratory laparotomy for refractory pain and to rule out appendicitis. Myomectomy was not performed in these patients as the lesions were located transmurally and intramurally. All 3 patients had uneventful pregnancies. The patient who underwent laparotomy had a cesarean delivery on request, and the two other patients delivered vaginally at term.

In the group of patients who underwent myomectomy, 6 had preoperative abdominal pain, and 1 had premature labor and abdominal pain. In the group who received conservative treatment for symptomatic leiomyomas, premature labor occurred in 7 (35.0%) and abdominal pain occurred in 9 (45.0%); 3 (15.0%) had both premature labor and abdominal pain, and 1 was admitted for vaginal bleeding.

The mean gestational age at admission in the patients who underwent myomectomy was 16.8 ± 2.5 weeks (range 15.0–21.1) and 22.7 ± 4.6 weeks (range 15.2–33.2) in the patients who received conservative treatment (**Table 1**).

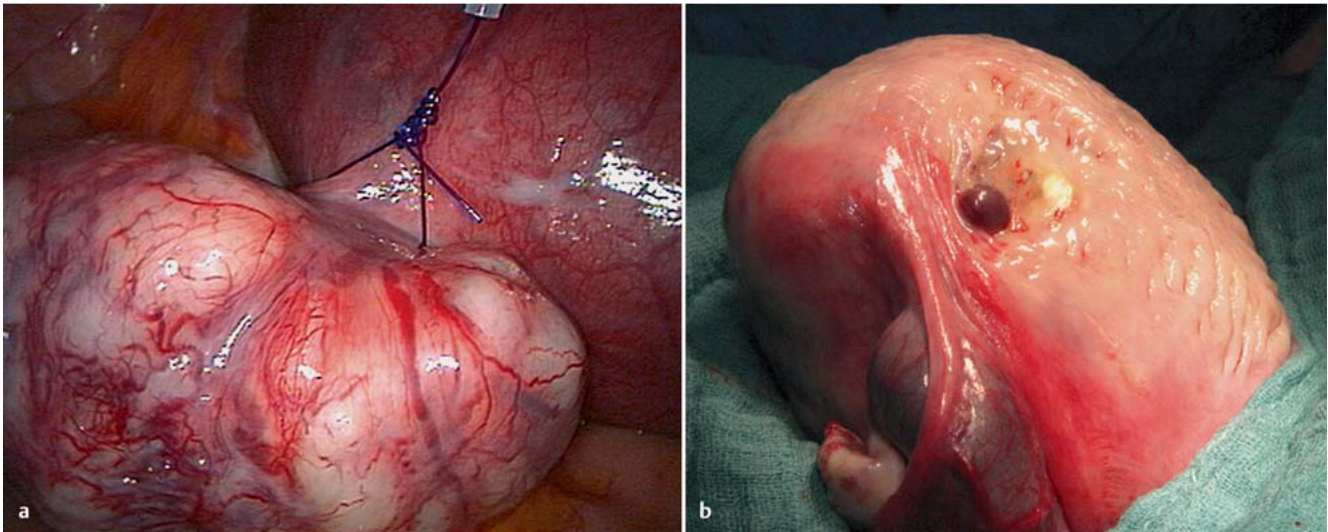


Fig. 1 a and b Case 1 (see [Table 2](#)): **a** the leiomyoma stalk is grasped during laparoscopy with the Röder-loop; **b** uterus after removal of the leiomyoma (image captured during cesarean section).

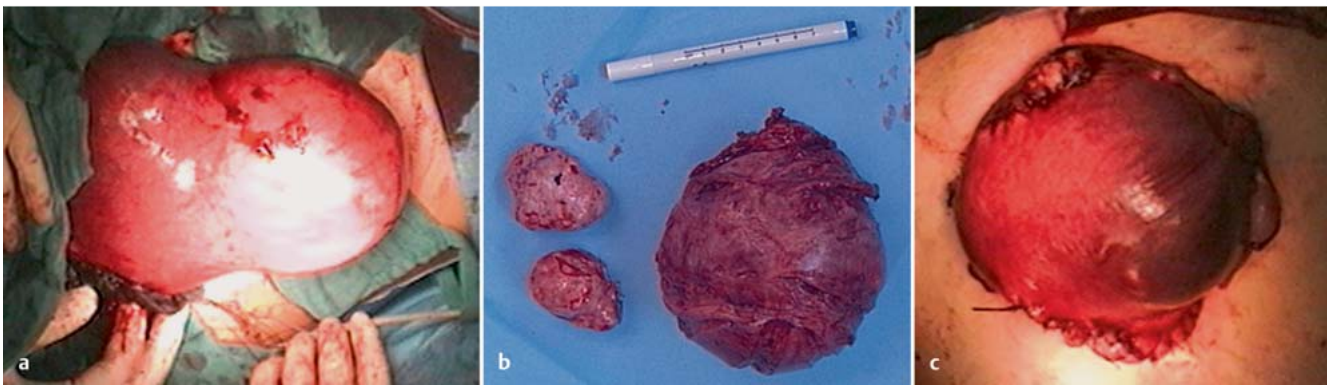


Fig. 2 a to c Case 2 (see [Table 2](#)): **a** intraoperative view of the largest leiomyoma located on the anterior lower uterine segment; **b** excised leiomyomas; **c** uterus after removal of the leiomyomas.

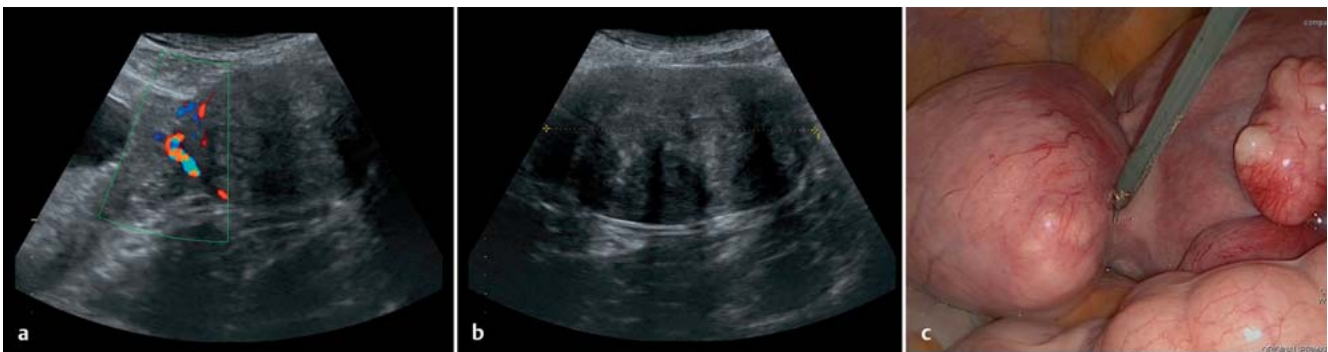

Fig. 3 a to c Case 7 (see [Table 2](#)): **a** ultrasound view of source of blood flow to the leiomyoma; **b** ultrasound view of the uterine mass; **c** laparoscopic exposure of the leiomyoma stalk.

Table 2 Myomectomy group: characteristics of subjects, surgical interventions, pathology findings and gestational age at delivery.

Case	Age (years)	Gravidity/parity	Gestational age at diagnosis (weeks)	Indication for surgery	Surgery type	Diameter largest myoma (cm)	Location largest myoma	Number excised myomas	Histologic diagnosis largest myoma	Gestational age at delivery (weeks)
1	37	1/0	15	enlarging fibroids	laparoscopy	6.5	fundus, pedunculated	2	leiomyoma with signs of infarction	38
2	38	1/0	17	degenerating fibroid	laparotomy	15.5	anterior lower uterine segment, subserosal	3	leiomyoma with necrotic changes and hyalinization	38
3	29	1/0	15	abdominal pain	laparotomy	21.0	fundus, pedunculated	1	clear-cell epitheloid leiomyoma with necrotic changes	38
4	33	1/0	16	degenerating fibroid	laparotomy	27.0	anterior wall, pedunculated	1	leiomyoma with necrotic changes	39
5	38	1/0	22	premature labor	laparotomy	9.0	fundus, pedunculated	4	leiomyoma with necrotic changes and hyalinization	38
6	39	3/2	18	abdominal pain, degenerating fibroid	laparotomy	8.5	left uterine segment, pedunculated	1	leiomyoma with necrotic changes and signs of infarction	39
7	37	1/0	17	abdominal pain, degenerating fibroid	laparoscopy	7.0	fundus, pedunculated	1	leiomyoma with necrotic changes and hyalinization	39

Six patients who underwent myomectomy during pregnancy delivered by cesarean section, while this was the case for 8 of the patients who received conservative treatment (8 out of 17 patients; 47.1%) for symptomatic leiomyoma (Table 1). One patient from the myomectomy group delivered spontaneously. We recommended a primary cesarean section to one patient from the myomectomy group (14.3%); the other five patients received a cesarean section on request, with two patients receiving a secondary cesarean section. Gestational age at delivery was 38.1 ± 3.9 weeks (range 25.2–41.2) in the myomectomy group and 38.0 ± 0.3 weeks (range 37.7–38.5) in the conservative treatment group. Duration of hospitalization was 15.3 ± 9.7 days (range 7–26) in the myomectomy group and 8.7 ± 6.6 days (range 1–29) in the conservative treatment group (Table 1). Postpartum hysterectomy was not performed in either group.

Patients who underwent myomectomy had a larger diameter (median 15.5 cm) for the largest leiomyoma than those who received conservative treatment (median 7.1 cm). All 7 women who underwent myomectomy had pedunculated and subserosal leiomyomas; this was the case in only one third of the women who received conservative treatment; 5/17 women (29.4%) had subserosal leiomyomas (Table 1). All but one of the 7 patients who underwent myomectomy had histologic signs of degeneration of the largest leiomyoma. Evidence of leiomyoma degeneration at ultrasound was found for only 3 of the 17 women who received conservative treatment. Eight (61.5%) of the 13 fibroid specimens taken showed necrotic changes, and there was 1 case of clear-cell epitheloid leiomyoma. Regressive changes, hyalinization, and infarction of the leiomyomas had also been reported.

Perioperative and postoperative morbidity was low in all women in our sample. No haemorrhages or surgical infections occurred postoperatively, nor were there any fetal losses after surgery. Re-laparotomy on the fourth postoperative day was necessary in one case due to symptoms of intestinal obstruction. Adhesions of the small intestine within the area of the myomectomy scar were found and removed. The further postoperative course of the patient was uneventful and the pregnancy ended with a cesarean delivery at term.

The patient with the twin pregnancy had a 7 cm fundal intramural leiomyoma and was admitted with premature labor at 22/2 weeks of gestation. She received conservative treatment and suffered a premature rupture of the membranes of the first twin five days after admission. Intrauterine death of the first twin occurred at 24/0 weeks of gestation. Directly after vaginal delivery of the first twin, the pregnancy for the second twin was prolonged by renewed tocolysis. At 25/2 weeks of gestation, cesarean section of the second twin was performed due to pathological antenatal cardiotocography (CTG) recording. A liveborn preterm infant was delivered and the further postoperative course was uneventful.

Discussion

The present study analyzed a group of women with symptomatic leiomyomas during pregnancy who underwent myomectomy during pregnancy and those treated conservatively. It was interesting to note that most women who underwent myomectomy had leiomyomas with histologic signs of necrosis. Abdominal pain, imaging and histologic signs of necrosis seem to be a common feature in symptomatic leiomyoma in pregnancy and have

been described in a majority of patients who undergo myomectomy during pregnancy [7, 8, 12–16].

Some authors advise against myomectomy during pregnancy because of possible perioperative and postoperative complications: hemorrhage, premature rupture of membranes, preterm labor, abortion, and fetal loss [14]. However, in some cases, for example where conservative management fails, the leiomyoma is in a critical location in the lower uterine segment, or, if the diagnosis is uncertain, surgery may be unavoidable [8].

Laparoscopic surgery, also called minimally invasive surgery, has multiple advantages (decreased blood loss, faster recovery and improved visibility) due to the fact that operations in the abdomen are performed through small incisions (usually 0.5–1.0 cm) as opposed to the larger incisions needed in laparotomy. Both laparoscopy and laparotomy for removal of symptomatic leiomyomas are considered safe in selected patients during the first and second trimesters of pregnancy [17]. In the present study one patient with a pedunculated leiomyoma underwent laparoscopic myomectomy in the second trimester; the pregnancy progressed to term without further complications. However, regardless of the surgical technique, myomectomy during pregnancy is associated with an increased risk of cesarean section. Thus, consistent with previous data, we found that women who underwent myomectomy for symptomatic leiomyomas during pregnancy had a higher rate of cesarean sections than those treated conservatively [8, 14–16].

Several criteria for myomectomy during pregnancy have been proposed. Burton et al. suggested that surgical removal should be limited to pedunculated leiomyomas, whereas Exacoustos and Rosati suggested myomectomy for both pedunculated and subserosal leiomyomas. In our study, one of the largest leiomyomas removed was subserosal, and 5 were pedunculated. Recurrent pain, large or rapidly growing leiomyomas, medium or large leiomyomas located in the lower uterine segment, and leiomyomas in the immediate vicinity of the placenta have been suggested as possible indications for surgery [8, 14–16].

Mollica et al. reported a lower incidence of premature labor, premature rupture of membranes and preterm labor in a group of women who underwent elective myomectomy during pregnancy than in a group who received conservative treatment and a control group of pregnant women with no evidence of leiomyomas [16]. The authors concluded that elective myomectomy during pregnancy as a preventative measure before the onset of acute complications is a safe option when done early in carefully selected patients [16]. Nevertheless, the first option in symptomatic patients should always be the conservative treatment of leiomyomas during pregnancy.

Major limitations of this study are the small number of patients included and its retrospective design. Our results therefore need to be interpreted with caution. Nevertheless, patients with large (>6 cm), symptomatic, subserosal or pedunculated leiomyomas with signs of degeneration that fail to respond to conservative treatment may require myomectomy during pregnancy. Little is known about the relationship between leiomyomas and adverse pregnancy outcomes. Also, the shift in the demographics of maternity will lead to larger proportions of women affected by leiomyomas during pregnancy [9]. Further studies with larger co-

orts are therefore required for a better understanding of the risks and benefits of myomectomy during pregnancy.

In our study, myomectomy during pregnancy for symptomatic, subserosal or pedunculated leiomyomas with signs of degeneration that failed to respond to conservative treatment was performed safely in carefully selected patients with low perioperative and postoperative morbidity.

Acknowledgements



We thank Alistair Reeves for editing a near-final draft of the manuscript.

Conflict of Interest



None.

References

- 1 Walker CL, Stewart EA. Uterine fibroids: the elephant in the room. *Science* 2005; 308: 1589–1592
- 2 Marshall LM, Spiegelman D, Barbieri RL et al. Variation in the incidence of uterine leiomyoma among premenopausal women by age and race. *Obstet Gynecol* 1997; 90: 967–967
- 3 Stewart EA. Uterine fibroids. *Lancet* 2001; 357: 293–298
- 4 Fernandez H, Farrugia M, Jones SE et al. Rate, type, and cost of invasive interventions for uterine myomas in Germany, France, and England. *J Minim Invasive Gynecol* 2009; 161: 40–46
- 5 David M, Kröncke T. Uterine fibroid embolisation – potential impact on fertility and pregnancy outcome. *Geburtsh Frauenheilk* 2013; 73: 247–255
- 6 Scheurig-Münkler C, David M, Kröncke TJ. Uterusarterienembolisation bei Patientinnen mit symptomatischen Gebärmuttermyomen: prospektive Studie zu klinischem Erfolg und Veränderung der Lebensqualität im langfristigen Verlauf. *Geburtsh Frauenheilk* 2011; 71: 653–658
- 7 Döring GK, Lärm S. Conservative procedures in 64 pregnant patients with myoma: the course of pregnancy, labor, and the puerperium. *Geburtsh Frauenheilk* 1987; 47: 26–29
- 8 Burton CA, Grimes DA, March CM. Surgical management of leiomyomata during pregnancy. *Obstet Gynecol* 1989; 74: 707–709
- 9 Laughlin SK, Baird DD, Savitz DA et al. Prevalence of uterine leiomyomas in the first trimester of pregnancy: an ultrasound-screening study. *Obstet Gynecol* 2009; 113: 630–635
- 10 Shavell VI, Thakur M, Sawant A et al. Adverse obstetric outcomes associated with sonographically identified large uterine fibroids. *Fertil Steril* 2012; 971: 107–110
- 11 Coronado GD, Marshall LM, Schwartz SM. Complications in pregnancy, labor, and delivery with uterine leiomyomas: a population-based study. *Obstet Gynecol* 2000; 95: 764–769
- 12 Katz VL, Dotters DJ, Droegemueller W. Complications of uterine leiomyomas in pregnancy. *Obstet Gynecol* 1989; 73: 593–596
- 13 Wong L, Ching TW, Kok TL et al. Spontaneous hemoperitoneum from a uterine leiomyoma in pregnancy. *Acta Obstet Gynecol Scand* 2005; 84: 1208–1209
- 14 De Carolis S, Fatigante G, Ferrazzani S et al. Uterine myomectomy in pregnant women. *Fetal Diagn Ther* 2001; 16: 116–119
- 15 Exacoustos C, Rosati P. Ultrasound diagnosis of uterine myomas and complications in pregnancy. *Obstet Gynecol* 1993; 82: 97–101
- 16 Mollica G, Pittini I, Minganti E et al. Elective uterine myomectomy in pregnant women. *Clin Exp Obstet Gynecol* 1996; 23: 168–172
- 17 Sentilhes L, Sergent F, Verspyck E et al. Laparoscopic myomectomy during pregnancy resulting in septic necrosis of the myometrium. *BJOG* 2003; 110: 876–878