

Translunate Perilunate Injuries—A Spectrum of This Uncommon Injury

Gregory Ian Bain, FRACS, PhD¹ Samuel Pallapati, MBBS, DOrtho, DipNB (ortho)² Kevin Eng, FRACS³

¹University of Adelaide, South Australia, Australia

²Paul Brand Centre of HLRS, Christian Medical Centre, Vellore, India

³Department of Orthopaedic Surgery, Modbury Public Hospital, Adelaide, Australia

Address for correspondence Associate Professor Gregory I. Bain, FRACS, PhD, 196 Melbourne Street, North Adelaide 5006, South Australia, Australia (e-mail: greg@gregbain.com.au).

J Wrist Surg 2013;2:63–68.

Abstract

Purpose To review a series of translunate perilunate dislocations to analyze the, mechanism of injury, diagnosis, management, and outcome.

Methods A literature review and a survey of the International Wrist Investigators Workshop were performed to locate cases.

Results Translunate perilunate injuries are rare. There is a spectrum of severity. The mechanism of injury is usually high-energy, and multiple fractures are the norm. High-energy mechanism, perilunate dislocation, comminuted lunate fracture and delayed presentation greater than 7 days are associated with a higher likelihood of a salvage procedure being required.

Discussion Translunate injuries are a complex variant of perilunate dislocations. Early diagnosis is critical in understanding the complexity of the injury. Lunate fixation should be performed prior to bony and ligamentous stabilization of the proximal row. In delayed or highly comminuted cases, salvage procedures are the preferred option. Including a translunate arc in addition to the greater and lesser carpal arc would lead to a more inclusive classification.

Level of Evidence Level IV.

Keywords

- translunate
- perilunate
- dislocation
- fracture

The translunate, perilunate fracture dislocation is a rare injury. In a series of 157 cases of perilunate dislocation there were no translunate fractures reported.¹ There are only case reports in the literature. Johnson classified perilunate fracture dislocations according to the structures involved.² If there is a fracture and only the surrounding ligaments of the lunate are involved; these are termed *lesser arc* injuries. If a fracture of the carpal bones occurs, these are termed *greater arc* injuries. Combinations of greater and lesser arc injuries may occur.

Johnson's classification did not include lunate fractures. Isolated lunate fractures themselves are rare (0.5%).³ Bain introduced the translunate arc concept in a case series of three patients.⁴ The arc is complementary to the greater and lesser arcs. It includes a path of injury through the lunate producing a lunate fracture, with associated perilunate injury

(fracture, dislocation, or subluxations). Graham introduced an inferior arc, in which the path of injury is through the radiocarpal plane.⁵

Purpose

To review a series of translunate perilunate dislocations to analyze the, mechanism of injury diagnosis, management, and outcome.

Methods

A literature search was performed in pubmed, medline, and google scholar using terms “translunate,” or “lunate fracture.” Cases were included if they contained a fractured lunate, with a path of injury along the greater or lesser arc, and/or the

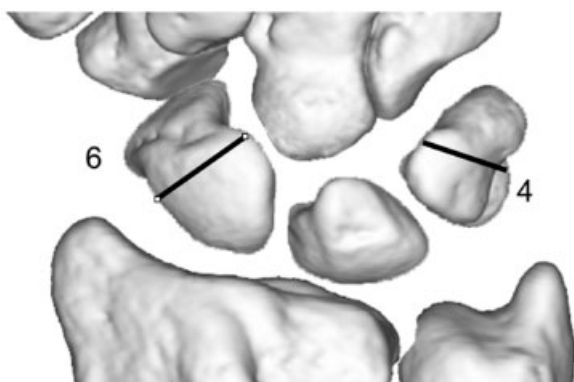


Fig. 1 Frequency of associated fractures in translunate subluxations.

radial or ulna styloids. A total of 285 articles were identified, of which 17 articles included a translunate injury. The largest series was 3 cases. The senior author also contacted the members of the International Wrist Investigators Workshop (IWIW). As a result, cases were received for inclusion.

Results

There were 34 cases reported spanning a period from 1976 to 2011.^{4,6-20} Eleven were from personal correspondence. They included a spectrum of injury from minimally displaced fractures to complex fracture dislocations. No cases of acute carpal tunnel or avascular necrosis were noted. No cases were

open. The cases were divided into a subluxated group and a dislocated group.

Subluxation Group

A total of 10 cases (4 cases from IWIW correspondence and 6 from articles) were reported with translunate arc injuries that were not dislocated at the time of imaging studies. These ranged from minimally displaced fractures to subluxations.

The mean age of the patients was 23 years. Injury mechanisms tended to be low energy. There were 7 falls from a standing height and two patients had punching injuries.

Eight of the lunate fractures were coronal. Six cases had associated scaphoid fractures. Four had scaphoid and triquetral fractures (►Fig. 1).

Three patients presented in a delayed fashion and underwent salvage with lunate excision and scaphocapitate fusion. The lunate fracture was initially missed in these cases.

Six lunates were internally fixed. Four cases utilized screws (►Fig. 2a,b; ►Fig. 3). One patient with undisplaced fractures had a plaster cast.

Seven patients had follow-up. Average follow-up was 12 months, and five patients reported near normal results.

Dislocation Group

Twenty-four cases (8 cases from IWIW, 16 from the literature) were identified involving perilunate dislocation.

The mean age was 29 years (range 16–66). The mechanisms of injury mostly involved high-energy trauma. The most common mechanisms were motor vehicle accidents (10) and fall from a greater than standing height (9).

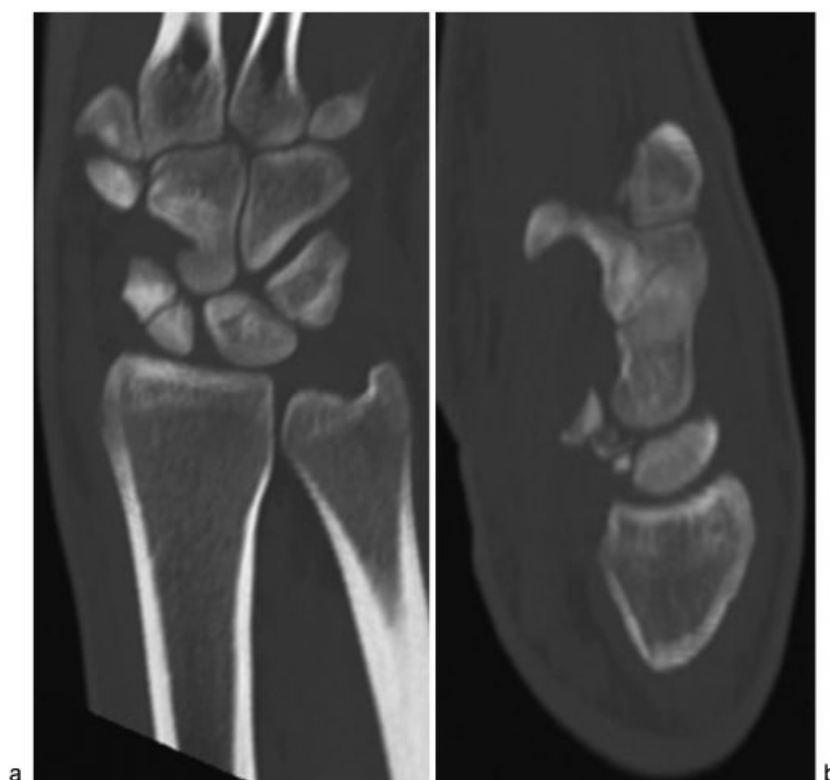


Fig. 2a,b Examples of transscaphoid translunate subluxation (a) in coronal plane; (b) in sagittal plane. (Courtesy of Dr Luc De Smet.)

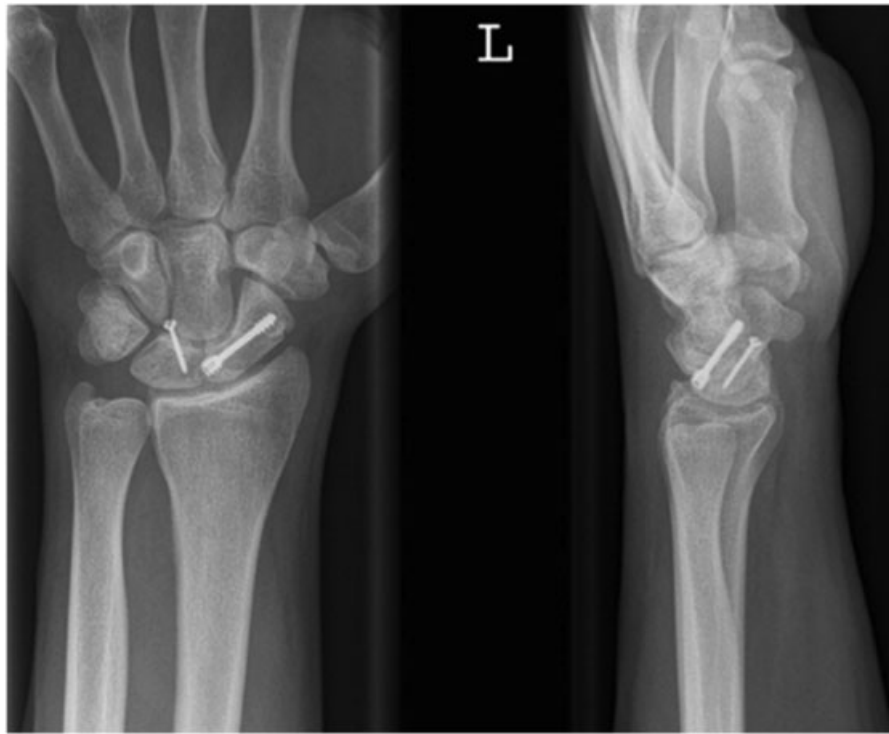

Fig. 3 Internal fixation with screws. (Courtesy of Dr Luc De Smet.)

Three cases presented in a delayed fashion (8 days, 4 weeks and 6 weeks) to the reporting surgeon. Two were internally fixed. The 6-week case underwent a proximal row carpectomy.

The lunate fracture pattern was recorded in 19 cases. Fourteen were in the coronal plane. Multiple other injuries were noted. The most frequent associated fracture was the radial styloid (15), followed by the scaphoid (11). Thirteen patients had two or more associated fractures as well as the lunate fracture (► **Fig. 4**).

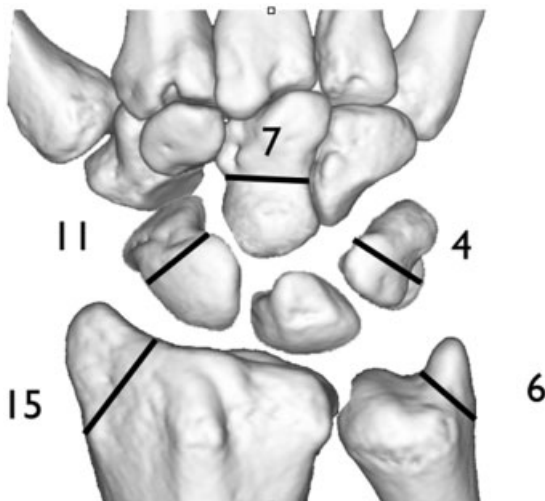


Fig. 4 Diagram of associated fractures in translunate perilunate dislocations.

In four cases the fixation method of the lunate was not stated. Wires were the most common form of fixation (11). Four cases were treated without internal fixation of the lunate. An external fixator was used in two cases: in one case as a neutralization device and in the other as the primary fixation.

Primary salvage was performed in five cases. The techniques used were proximal row carpectomy (PRC), lunate excision, and a transarticular wire.

Secondary salvage was required in one case with a comminuted coronal fracture of the lunate, and it involved a total wrist arthrodesis (► **Figs. 5a,b**; ► **Fig. 6a,b**).

The follow-up of these patients was incomplete, and the outcome data recorded were variable, limiting our results.

Discussion

Although translunate injury is rare, we identified 34 cases. Surgeons need to be mindful of this, and expect that they may come across this complex injury in their practicing lifetime.

Our series included a wide spectrum of injuries that included the translunate arc. It is possible that some of the undisplaced or subluxated cases were spontaneous reductions. These had better clinical outcomes, compared with the dislocation group.

Associated fractures were very common. The radial styloid was the most common associated fracture in the dislocation group. In contrast, Herzberg found that a transscaphoid injury was the most common (91%) in greater arc perilunate fracture dislocations.¹

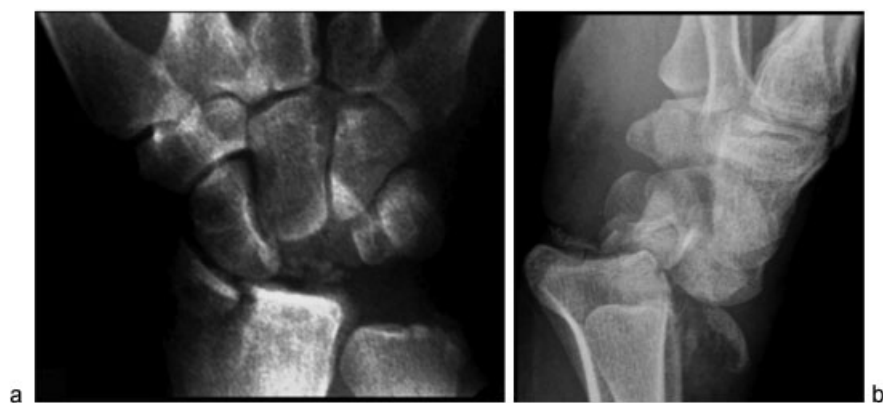

Fig. 5a,b Examples of translunate fracture perilunate dislocation (a) in coronal plane; (b) in sagittal plane.

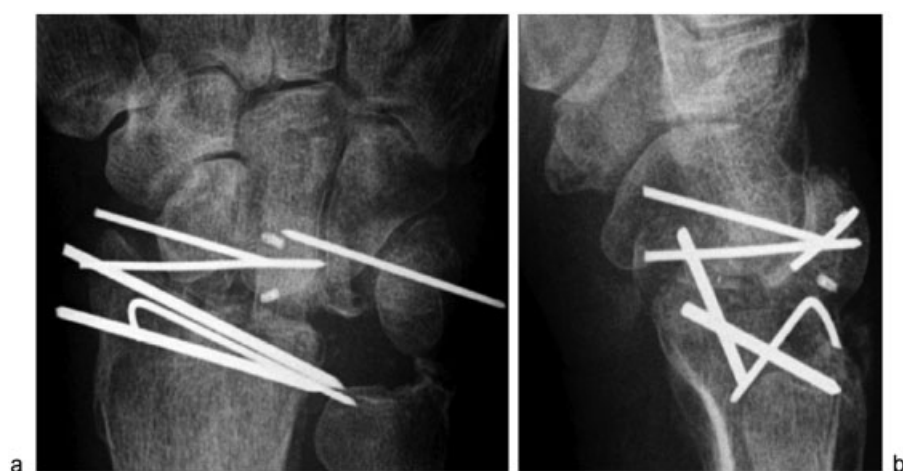

Fig. 6a,b Failed internal fixation with K-wires due to comminution of the lunate (a) in coronal plane; (b) in sagittal plane.

In several cases, the lunate fracture was not identified initially and the presentation was delayed. This is particularly the case in the subluxation group, where the displacement was less obvious. To aid in identifying all injuries preoperatively, we use longitudinal traction radiographs to eliminate carpal bone overlap. The pathological separation of structures is noted. A separation between carpal bones occurs in purely ligamentous injuries, and fractures are allowed to gap.²¹

The pathomechanics of the translunate perilunate dislocation is unclear, and our series contained no information on this. Mayfield suggested that extension, intercarpal supination, and ulna deviation lead to a perilunate dislocation.²² It is likely that a variation of this leads to a translunate perilunate injury. The most common plane of lunate fracture was the coronal plane, similar to a Teisen's type V fracture.³ We postulate that this may be due to a longitudinal impaction of the capitate on the lunate.²³ The capitate shearing against the lunate in the axial plane may cause a coronal "lip" or "rim" (Teisen type I) fracture of the lunate.¹⁸ This may be accentuated by the tension of the volar radiolunate ligaments. Others have suggested an avulsion mechanism for the lunate fracture, with the wrist in hyperextension and the hand being forced into supination against a pronated forearm.²⁰

The traditional classification of greater and lesser arc injuries can be expanded. When grouped together with the translunate and radiocarpal arcs, the four arcs represent a more inclusive classification of carpal fracture/dislocations

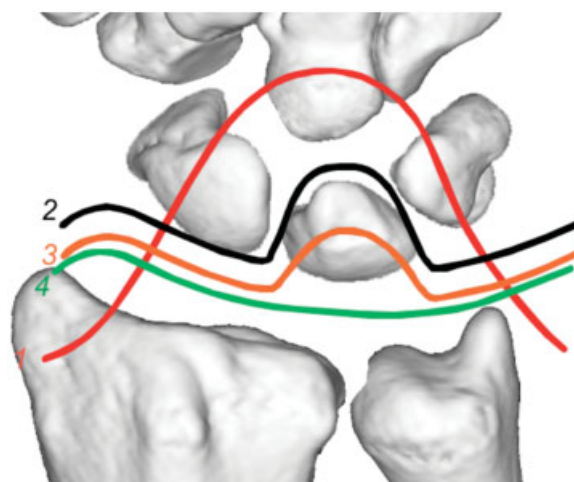


Fig. 7 Arc injuries, coronal plane. 1: greater arc; 2: lesser arc; 3: translunate arc, 4: inferior arc.

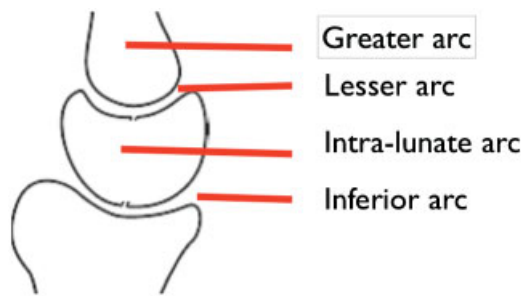


Fig. 8 Arc injuries, sagittal plane.

(► **Figs. 7, 8**). It is based on the level of injury to the lunate or “central column” and guides diagnosis and treatment.

A perilunate dislocation, comminuted lunate fracture, and delayed presentation were more likely to lead to a salvage procedure.

Due to the inconsistent outcome data, we cannot recommend specific treatments.

The senior author previously recommended fixation of the lunate first, often considered the “keystone” of the proximal row.² This is followed by repair of any coincident fractures, followed by ligamentous repair, in a manner similar to treatment of greater arc injuries.⁴ Having now reviewed 34 cases by multiple surgeons, we note that a similar principle is being utilized of internal fixation of the lunate first, followed by other fracture fixation then ligament repair. Two cases used external fixation, but these cases are from older literature.¹⁶ The senior author would recommend their use as a neutralization device.²⁴

Our study is a retrospective review and contains only case reports. There is a wide variability in the data that are reported, leading to an incomplete dataset. Outcomes were not reported in all cases, and a bias toward positive outcomes is likely. The spectrum of injuries was variable, and multiple surgical techniques employed. The cases were collected over a period of more than 30 years, and surgical techniques, implants, and patient expectations have changed over this time. However, the study is unique in that it provides a better understanding of the spectrum of a rare and complex injury.

Acknowledgments

The authors would like to thank the following surgeons for sharing cases of translunate injury: Emmanuel Apergis, David G Dennison, Luc De Smet, Guillaume Herzberg, PC Ho, David Slutsky, WL Tse, Ronit Wollstein, Clara Wong.

Conflict of Interest

None

References

- 1 Herzberg G, Comtet JJ, Linscheid RL, Amadio PC, Cooney WP, Stalder J. Perilunate dislocations and fracture-dislocations: a multicenter study. *J Hand Surg Am* 1993;18(5):768–779
- 2 Johnson RP. The acutely injured wrist and its residuals. *Clin Orthop Relat Res* 1980;(149):33–44
- 3 Teisen H, Hjarbaek J. Classification of fresh fractures of the lunate. *J Hand Surg [Br]* 1988;13(4):458–462
- 4 Bain GI, McLean JM, Turner PC, Sood A, Pourgiezis N. Translunate fracture with associated perilunate injury: 3 case reports with introduction of the translunate arc concept. *J Hand Surg Am* 2008;33(10):1770–1776
- 5 Graham TJ. The inferior arc injury: an addition to the family of complex carpal fracture-dislocation patterns. *Am J Orthop* 2003;32(9, Suppl):10–19
- 6 Enoki NR, Sheppard JE, Taljanovic MS. Transstyloid, translunate fracture-dislocation of the wrist: case report. *J Hand Surg Am* 2008;33(7):1131–1134
- 7 Noble J, Lamb DW. Translunate scapho-radial fracture. A case report. *Hand* 1979;11(1):47–49
- 8 Conway WF, Gilula LA, Manske PR, Kriegshauser LA, Rholl KS, Resnik C. Translunate, palmar perilunate fracture-subluxation of the wrist. *J Hand Surg Am* 1989;14(4):635–639
- 9 Ruijters R, Kortmann J. A case of translunate luxation of the carpus. *Acta Orthop Scand* 1988;59(4):461–463
- 10 Mason GC, Bowman MW, Fu FH. Translunate, perilunate fracture-dislocation of the wrist. A case report. *Orthopedics* 1986;9(7):1001–1004
- 11 Toft P, Bertheussen K, Otkjaer S. Translunate, transmetacarpal, scapho-radial fracture with perilunate dislocation. A case report. *J Hand Surg [Br]* 1985;10(3):382–384
- 12 Ran Y, Copel L, Aghasi M, Halperin N. Translunate, transscaphoid, transcapitate, perilunate fracture dislocation. *J Trauma* 2009;67(1):E8–E10
- 13 Amaravati RS, Saji MJ, Rajagopal HP. Greater arc injury of the wrist with fractured lunate bone: a case report. *J Orthop Surg (Hong Kong)* 2005;13(3):310–313
- 14 Briseño MR, Yao J. Lunate fractures in the face of a perilunate injury: an uncommon and easily missed injury pattern. *J Hand Surg Am* 2012;37(1):63–67
- 15 Hofmeister EP, Faruqi S. Two unusual cases of coronal lunate fracture. *Orthopedics* 2009;32(4):
- 16 Habernek H, Weinstabl R, Kdolsky R, Fialka C, Barisani G. Volar lunate fracture-dislocations of the wrist: case report for two patients treated with external frame and internal open reduction. *J Trauma* 1998;45(5):975–978
- 17 Yakoubi M, Meziani N, Yahia Cherif M, Kasdi A, Benbakouche R. Carpal dislocation combined with a lunate fracture: a new clinical form. Report of a case [in French]. *Chir Main* 2007;26(4-5):247–249
- 18 Teisen H, Hjarbaek J. Classification of fresh fractures of the lunate. *J Hand Surg* 1988;13B:458–462
- 19 Buijze GA, Mudgal CS. Nondisplaced fractures of the proximal carpal row: case report. *J Hand Surg Am* 2011;36(8):1310–1312
- 20 Christodoulou L, Palou CH, Chamberlain ST. Proximal row transcarpal fracture from a punching injury. *J Hand Surg [Br]* 1999;24(6):744–746 (British and European Volume)
- 21 Blazar PE, Murray P. Treatment of perilunate dislocations by combined dorsal and palmar approaches. *Tech Hand Up Extrem Surg* 2001;5(1):2–7
- 22 Mayfield JK. Patterns of injury to carpal ligaments. A spectrum. *Clin Orthop Relat Res* 1984;(187):36–42
- 23 Vasireddy A, Lowdon I. Lunate fracture in an amateur soccer player. *J Orthop Sports Phys Ther* 2009;39(12):884
- 24 Fernandez DL, Mader K. The treatment of complex carpal dislocations by external fixation. *Injury* 2000;31(Suppl 1):92–101