

Understanding Midfacial Rejuvenation in the 21st Century

Scott Randolph Chaiet, MD^{1,2} Edwin F. Williams, III, MD, FACS^{1,2}

¹Department of Facial Plastic and Reconstructive Surgery, Williams Center Plastic Surgery Specialists, Latham, New York, New York

²Division of Otolaryngology, Head and Neck Surgery, Department of Surgery, Facial Plastic and Reconstructive Surgery, Albany Medical Center, New York, New York

Address for correspondence and reprint requests Edwin F. Williams, III, MD, FACS, Williams Center for Excellence, 1072 Troy Schenectady Road, Latham, New York, NY 12110 (e-mail: edwilliams@nelasersurg.com).

Facial Plast Surg 2013;29:40–45.

Abstract

Keywords

- ▶ subperiosteal midface-lift
- ▶ facial rejuvenation
- ▶ rhytidectomy
- ▶ endoscopic midface-lift

Facial rejuvenation has largely focused on surgical procedures of the lower and upper one thirds of the face. Over the past 15 years, research focus on the midface has given aesthetic facial surgeons more tools to improve the signs of aging. The term *midface* has been used with various definitions, but includes the lower eyelid subunit beginning at the inferior border of the tarsal plate and cheek, down to the nasolabial fold. Many surgical approaches to the midface have been described including skin tightening with direct excision, skin–muscle flaps, fat repositioning, and, our preferred method of endoscopic browlift approach, subperiosteal lifting. We will describe the anatomy and aging of the midface, review surgical and adjunctive techniques, describe our method of the subperiosteal midface-lift including its limitations and risks, and discuss current challenges.

As surgical treatment of facial rejuvenation became popular in the 20th century, treatment of the midface was largely ignored. The aging process in this region is notable for descent of tissue including the malar fat pad as well as volume depletion. Not only has this area been neglected, but our lack of understanding of midface aging also contributed to aesthetically unfavorable results in patients undergoing lower eyelid rejuvenation with poor malar projection compounded by volume loss. The excision of skin and fat in these patients' blepharoplasty surgery exacerbated the appearance of midface aging.

Our anatomic understanding of the midface was accelerated by Mitz and Peyronie's discovery of the superficial musculoaponeurotic system (SMAS) in 1976.¹ Hamra brought further attention by extending rhytidectomy surgery to elevate the malar soft tissue through a sub-SMAS dissection and deep plane and composite facelifts.² In the following years, a new subperiosteal approach was described, including a report by Tessier (in a communication to the Craniofacial Meeting in Rome, 1982) on treatment of the upper face and also by Psillakis to access the midface through a bicoronal incision.³

In the 1990s, Ramirez furthered Hamra's goal of elevating midface soft tissue by pioneering and popularizing the endoscopic approach to the midface.⁴ He described an elevation under the periosteum of the inferior orbital rim and malar areas through temporal and Caldwell-Luc approaches, demonstrating an elevation of the cheek–lower lid subunit junction.

Surgical approaches to the lower eyelid and midface have been fervently debated in the literature to limit postoperative scarring, achieve longevity, and avoid complications such as lower lid retraction. Since 1995, the senior author has been using the subperiosteal approach through temporal incisions used for an endoscopic browlift procedure, with the addition of an oral incision during the first 75 procedures. Brow and aging of the upper face may be simultaneously addressed with the midface-lift, which avoids bunching of lifted tissue near the region of the lateral canthus.

The evolution of the subperiosteal plane approach of the senior surgeon was born out of facial trauma experience and has evolved during a 17-year experience with over 1,200 cases. For example, the superior scalp approach allows access

Issue Theme Aesthetic Treatment of the Eyelids and Midface; Guest Editors, Michael M. Kim, MD, and Tom D. Wang, MD, FACS

Copyright © 2013 by Thieme Medical Publishers, Inc., 333 Seventh Avenue, New York, NY 10001, USA.
Tel: +1(212) 584-4662.

DOI <http://dx.doi.org/10.1055/s-0033-1333839>.
ISSN 0736-6825.

to fractures such as the zygomatic arch and to the maxilla, while safely dissecting deep to the frontal branch of the facial nerve.

Ramirez's work furthered the understanding of surgical access to the lower eyelid and midface by avoiding dissection through the preseptal orbicularis.⁴ If lower eyelid blepharoplasty is indicated, we utilize transconjunctival fat excision and a skin pinch excision that avoids violation of the orbicularis oculi. By avoiding disruption of the middle lamella, the senior author believes that the endoscopic brow approach yields a safe and powerful surgical technique for midface aging without the potentially disastrous risk of lower lid retraction.

Subperiosteal lifting of the midface can also achieve rejuvenation of the lower lid and lower face. As the malar fat pad and overlying ptotic tissue are elevated, the orbicularis oculi sling is tightened, shortening the lower lid subunit to create a more youthful appearance. Second, vertical vector elevation of the midface will relieve some tissue crowding in the jowl area. This topic will be further explored, but even with effective malar fat pad repositioning, the nasolabial fold will not be effectively effaced. At the current state of facial rejuvenation surgery, these are results we are willing to accept while considering new innovations.

The subperiosteal plane approach yields excellent aesthetic results via dissection planes well known to the facial plastic surgeon, avoiding potentially unsafe lower eyelid dissection.

Aging

Soft tissue aging of the midface involves both ptosis and laxity of skin and muscle, as well as volume loss. Over time, the increased laxity results in descent of the lower lid–cheek junction. Additionally, pseudoherniation of fat through the orbital septum creates visual irregularities, with pronounced visualization of the infraorbital rim. The space left by descending malar fat pads is labeled the tear trough deformity and leads to the appearance of prominent nasolabial folds inferiorly.⁵ Anecdotally, we observe volume loss in the malar region that may progress at a rate independent to volume change elsewhere in the face. Careful examination and photographic analysis can aid in assessing the contribution of tissue descent and volume loss (→ Fig. 1).

The final piece to understanding the anatomic basis for aging of the midface is the underlying bone structure. Shaw et

al's work comparing bone volume changes using computed tomography imaging reveals actual volume loss of bone in malar projection with age.⁶ The underlying skeletal support may also be congenitally deficient such as in the negative vector where the vertical plane of the cheek falls behind the vertical plane of the anterior globe. The loss of midface volume without underlying malar projection exacerbates the visual signs of aging of the lower lid subunit, causing vertical elongation of the lid. Without volume correction in the negative vector patient, surgically excised pseudoherniated fat in blepharoplasty surgery can give a hallowed appearance. Adjunctive volume replacement to the midface–lift with either autologous fat or alloplastic graft materials may be required to correct a deficient skeletal structure (→ Figs. 2, 3).⁷

Midface Anatomy

The anatomy of the midface can be thought of as an inverted triangle with its base at the lower eyelid subunit and apex at the nasolabial fold. The tissue is bordered laterally by a line connecting the lateral canthus to the oral commissure; medially a line from the medial canthus is connected to the nasolabial fold. We suggest the superior border begins at the inferior border of the lower eyelid tarsus, incorporating the lower eyelid subunit inclusive of the orbicular oculi sling.

Study of the deeper tissue anatomy allows an understanding of the anatomical changes seen in aging. In Mendelson's dissections, he describes two distinct regions of the midface: the prezygomatic region overlying the bony zygoma and maxilla and the infrazygomatic region covering the oral cavity vestibule.⁸ Descent of the malar fat pad from the prezygomatic to infrazygomatic region leaves the upper midfacial skin deflated. The infrazygomatic region has now gained the descended tissue mound causing deepening of the jowl tissue and weight to the lower face, effacing the jaw line.

The zygomaticocutaneous retaining ligament also described by Mendelson divides the prezygomatic region and further explains midface changes with age.⁸ The ligament's firm hold from the zygoma to skin will create a lower eyelid festoon in the aging face, even as the remaining malar fat pad descends. Fat herniation through a weak orbital septum creates a double bubble of the orbital festoon superiorly and ptotic malar fat pad inferiorly. Excision of herniated fat from the anatomic zone above the ligament risks worsening

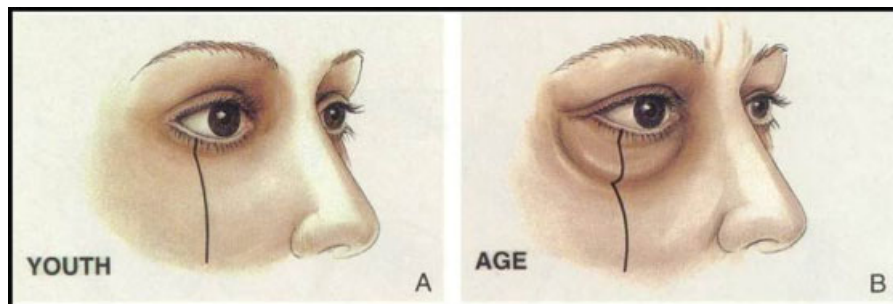


Fig. 1 Soft tissue descent and volume loss of the midface creating an elongated lower eyelid. (Reprinted with permission from Hamra ST. Arcus marginalis release and orbital fat preservation in midface rejuvenation. *Plast Reconstr Surg* 1995;96(2):354–362.)

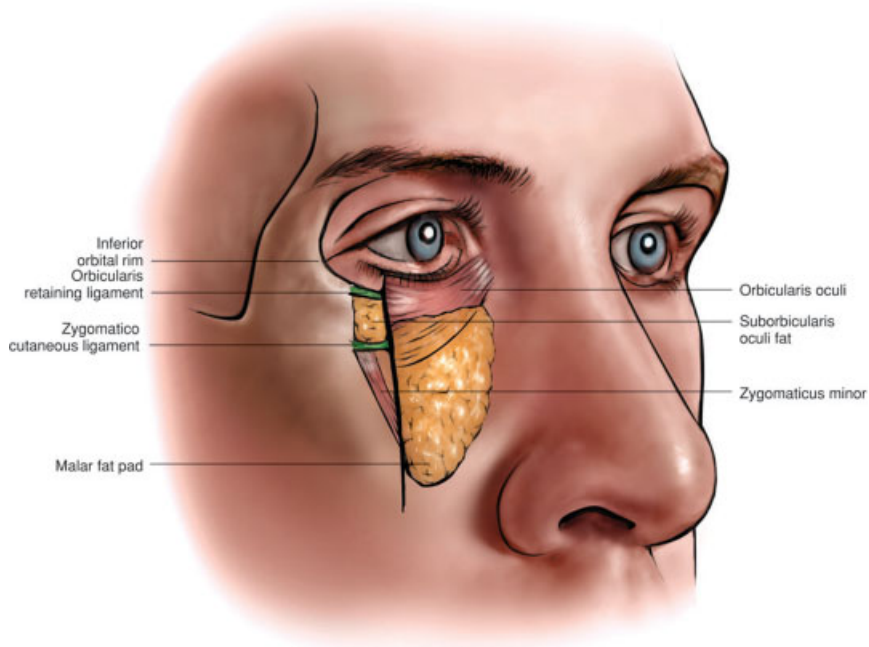


Fig. 2 Cross-sectional diagram of midface anatomy.

the deflated elongated appearance of the lower eyelid subunit in setting of a negative vector as previously discussed.

A subperiosteal midface-lift will elevate not only the malar fat below the ligament, but also raise the orbicularis oculi complex, relieving the downward pressure of the ptotic tissue. To achieve these results, the zygomaticocutaneous retaining ligament must be released. An understanding of

the midface anatomy allows surgical elevation of the lower lid–cheek junction to a more youthful, superior position.

Surgical Treatment of the Midface

Surgical therapy of the midface includes soft tissue rearrangement, volume addition, or both. Here we will discuss the

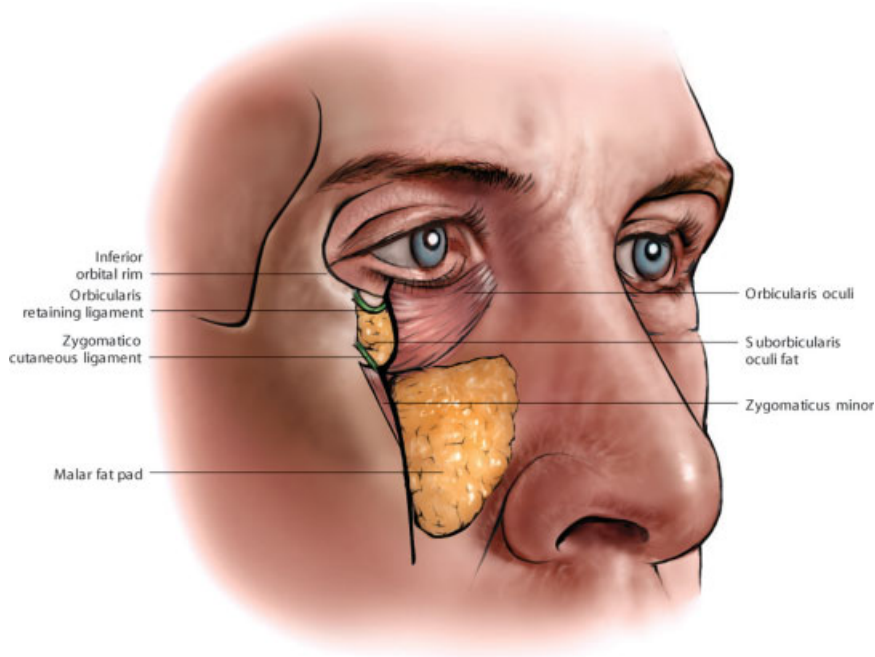


Fig. 3 Cross-sectional diagram of aging in the midface including soft tissue ptosis.

evolution of surgical rejuvenation leading to the endoscopic approach subperiosteal midface-lift.

As mentioned, our anatomic understanding of the midface deepened with the discovery of the SMAS by Mitz and Peyronie in 1976.¹ Based on the course of the facial nerve deep to the SMAS layer containing the mimetic musculature of the face, Hamra described lifting the malar pad and overlying tissue off of the zygomatic muscles in a deep plane facelift.^{2,9} The malar tissue is repositioned superiorly without manipulation of the orbicularis oculi muscle; the lower lid-cheek junction does not rise.²

Hamra added a suborbicularis oculi dissection to the deep plane rhytidectomy with an additional subciliary incision to create a composite flap.¹⁰ The skin-muscle bipedicle flap is elevated and shortens the lower lid unit. The extensive anterior lamellar dissection can create disastrous postoperative complications, even in experienced surgical hands. We believe the morbidity of the skin-muscle flap gives an unacceptable risk of lower lid malposition.

A masked randomized review by four facial plastic surgeons compared SMAS plication and deep plane rhytidectomy, finding the deep plane approach did not offer superior results over SMAS plication in those younger than 70.¹¹ Many others have and will continue to argue for the deep plane approach or SMAS manipulation to yield the greatest improvement with long-term results in the midface.

Concurrent to the debate for lower-face rhytidectomy, the subperiosteal approach appeared in the literature with upper- and midface-lifting by Psillakis et al.³ Via the bicoronal incision, Psillakis et al described dissection under the periosteum of the zygoma to give access to midface elevation. Sutures placed into the deep surface of the zygomatic musculature and malar fat pad were used to elevate the facial soft tissue envelope of the midface, improve orbital festoons, and soften the nasolabial fold. Not surprisingly, this approach resulted in forehead paresthesias and paralysis, albeit temporary. The authors critically evaluated the dissection technique over the zygoma that had included aggressive coagulation and traction.³

The senior author's experience grew from the 1990s work of Ramirez on the endoscopic approach to the midface using a subperiosteal dissection.⁴ He approached the inferior orbital rim and malar areas by safely dissecting beneath the temporal-parietal fascia containing the frontal branch of the facial nerve through small browlift temporal incisions. A transoral Caldwell-Luc approach was added to aid in subperiosteal elevation of the cheek and lower lid subunit.

Other authors have accessed the subperiosteal plane through the transmalar approach,¹² percutaneous incision,¹³ and via a lateral canthal skin incision, horizontally transecting the lateral orbicular oculi muscles.¹⁴ We avoid transection (and resection) of orbicularis oculi to limit scarring that can result in devastating lower lid retraction. Even minor lid retraction alters palpebral shape, worsening the appearance of aging.¹⁵

Last, aging is not limited to simply the midface. When addressing a ptotic brow, we believe there is merit to adjunctive midface treatment. The complementary techniques provide facial aesthetic improvement and avoid bunching of tissue in the region of the lateral canthus as the malar tissue is suspended.

When midface aging is isolated, alternate procedures such as volume enhancement with autologous fat may obviate the need for the midface-lift. The senior author has seen a trend in recent years toward fat transfer alone or in conjunction with SMAS flap rhytidectomy to address those without upper facial aging. The combination of these surgical tools can be tailored to a patient's pattern of aging and cosmetic desires.

Subperiosteal Operative Procedure

A complete description of the senior authors' technique is described thoroughly elsewhere¹⁶ and a summary is provided here. The patient is given either general or intravenous sedation. The patient's hair tufts are prepared with paper tape and the scalp is marked for the standard 2-cm central, paramedian, and lateral incisions for endoscopic browlift. These are infiltrated with local anesthetic as well as the midfacial tissue injected in a subperiosteal plane around the orbital rim. Next, the endoscopic browlift is performed if planned with subperiosteal release of the supraorbital attachments, procerus, and conjoin tendons. Lateral dissection is made by visually dissecting through the temporoparietal fascia at the temporal incision site and continued inferiorly along the deep temporal fascia safely below the temporal branch of the facial nerve.

With endoscopic or plain visualization, dissection is made to the zygomatic arch under the temporoparietal fascia. Excessive dissection through the superficial temporal fat pad is avoided by following the superficial layer of the deep temporal fascia over the zygomatic arch, using blunt technique to prevent disruption or transection of the overlying frontal branch of the facial nerve.

Dissection continues 1 cm past the arch onto the masseteric fascia releasing the osteocutaneous ligament and zygomaticus major. This key step will allow repositioning of midfacial tissues. Next, the periosteum is carefully incised along the maxilla to gain access to the subperiosteal plane. Finally, the periosteum along the orbital rim must be elevated while avoiding injury to the infraorbital nerve. The malar fat pad can then be visually identified with the zygomatic major muscle as a nearby landmark; it is vertically suspended to the deep temporal fascia in the scalp, in addition to any brow suspension sutures.

An intraoral incision may be utilized to assure good periosteal release over the maxilla, but the senior author abandoned this approach early to avoid its associated prolonged tissue edema.

Limitations

Although the subperiosteal midface-lift returns ptotic tissue to a more youthful position and shortens the lower lid subunit, it does not address the second key sign of aging: volume loss. The deficit is particularly seen at the junction of the cheek and lower eyelid. Autologous fat grafting, popularized in the 1990s by Coleman, gives volume restoration to the aging midface either alone or in combination with a vertical lift.^{17,18} The addition of volume can reverse the visible effects of aging on tissues for many years.

The literature reports varying percentages of volume retention of injected autologous fat. A recent study by Meier et al using three-dimensional photography shows only 31.8% of fat injected into the midface, with or without other adjunctive surgical procedures, remained at 16 months.¹⁹ This lower take rate may not translate into patient dissatisfaction; the addition of adjunctive procedures may possibly change the anatomic borders in the photograph analysis.

A recently published review of 99 patients in our practice undergoing only periorbital lipotransfer, excluding those undergoing adjunctive procedures, showed subjective improvement in 86.4% of patients for the first 3 years by independent evaluators.²⁰ Furthermore, patients of Meier et al were largely satisfied with a revision rate of 24%.¹⁹

Nonautologous injectable fillers including hyaluronic acid, calcium hydroxyapatite, and poly-L-lactic acid may also be considered to avoid the operating suite, downtime, and donor site morbidity with notable shorter longevity. However, younger patients with fewer signs of aging who do not need surgical excision of redundant lower lid skin may benefit from volume replacement with fillers.²¹

The second notable limitation of the subperiosteal midface-lift is the modest result in the lower face. In those patients with significant lower-face aging, additional surgical therapy such as cervical liposuction, rhytidectomy, and neck lift may improve aesthetic outcome. Despite pioneering rhytidectomy, in his long-term analysis of 20 patients who underwent deep plane rhytidectomy, Hamra showed the recurrence of nasolabial folds. He advocates the abandonment of lateral dissection and instead using direct excision as the only reliable option.⁹

The subperiosteal lift was once thought to be an answer to the shortcomings of deep plane rhytidectomy. In a retrospective analysis of 5 years of the senior author's isolated subperiosteal approach to midface surgery, three independent reviewers graded the postoperative improvement of the nasolabial fold after 1 year as mild in 60% of cases; little or none, 4%; and none, 36%.²² In contrast, 70% showed marked improvement in the malar-infraorbital complex and 30% marked improvement in the jawline.

Despite our progress in understanding the surgical treatment of aging, our interventions fall short in softening the nasolabial fold. In fact, the failure to achieve long-term aesthetic rejuvenation to the jowls continues to challenge surgeons. At the current state of facial rejuvenation surgery, we are willing to accept the limitations on lower-face aging.

Complications

Major and minor complications can occur, with most attention during dissection paid to respect the course of the facial nerve branches to prevent neuropraxia. The senior author critically evaluated retrospective charts of patients who underwent midfacial rejuvenation via the browlift incision over a 5-year period.²² Of 325 patients, three developed temporary frontal-branch weakness and one developed temporary buccal-branch weakness, all with complete resolutions at 6 months. Infraorbital dissection resulted in permanent anesthesia in one patient.

Also, two developed malar subperiosteal abscesses, for which one required an alloplastic implant for volume loss. After the first 75 cases, the senior author eliminated the oral cavity communication as a possible contamination source, anecdotally resulting in less postoperative edema. In the paramedian hair incision, alopecia developed in five cases requiring revision; no further alopecia was seen after modification from the implantable screw to the bone-tunnel technique.

Last, lateral canthus elevation was seen only temporarily with resolution at the 1-year follow-up examination. The aforementioned retrospective critical review by the senior author randomly selected 50 patients with 1-year photographic follow-up to measure lateral canthal movement and found a mean position change of less than 1%.²² There were no significant correlations to perceived change by the reviewer or patients.

A notably absent complication is lower lid malposition. The transconjunctival approach fat excision blepharoplasty avoids transecting through the middle lamella; transciliary skin excision also avoids dissection along the middle lamella, which can result in inflammation, scarring, shortening, and cicatricial tethering of the lower lid.²³

Other complications not reported are temporal wasting and prolonged postoperative bruising and edema.²⁴ Postoperative periorbital varicosities are avoided by limiting coagulation of sentinel veins in the temporal dissection by avoiding excessive cautery outside the tunnel needed for midface access.

Challenges

The greatest shortcoming seen by the senior author as of 2002 was not addressing the volume loss associated with aging of the midface. This prompted incorporating lipotransfer to the procedure; generally 25 to 30 mL of autologous fat is injected into the lower lids and midface. An underlying poor bony structure may give limited results that cannot be overcome with fat injection alone.

Alloplastic implants have become popular and are a logical step to enhance volume and even correct the tear trough deformity.²⁵ The implant can aid in projecting a congenitally deficient malar prominence or in those with bony loss from aging.⁶ Yaremchuk reported a 10% rate of revision procedures, including surgery for asymmetry, displeasing contours, and infraorbital nerve dysfunction.²⁶ Additionally, one must consider the small, but present, risk of infection with alloplastic implant and the surgical morbidity of oral incision.

Regardless of surgical approach and the judicious use of adjunctive volume repletion such as lipotransfer, the longevity of facial rejuvenation continues challenge surgeons. Our retrospective review after the subperiosteal lift shows maintained results in 5-year photographs but not in 10-year photographs. The frustration of longevity of the procedure is balanced by reliable safety. We accept its shortcoming on addressing the nasolabial folds, and advocate the use of injectable fillers for softening the area. As discussed, a pioneer of facelift surgery critically looked back 20 years to discover

his own composite facelift failed to adequately efface the folds.⁹

Last, surgical repositioning and reflation with autologous fat or filler will not address surface changes from sun damage and aging. Adding concurrent skin resurfacing with laser resurfacing or peel will add improvement in aesthetic results but must be balanced to the increased risks of post-operative edema, pain, and lower lid malposition if excessive skin excision blepharoplasty is also performed.

Conclusion

The endoscopic approach subperiosteal midface-lift is a powerful surgical tool to address facial aging. We accept the limitation of fully addressing the nasolabial folds but utilize the technique for its safe dissection that avoids the risk of lower lid retraction. Adjunctive procedures such as lipotransfer and skin resurfacing can fully address the signs of aging.

References

- Mitz V, Peyronie M. The superficial musculo-aponeurotic system (SMAS) in the parotid and cheek area. *Plast Reconstr Surg* 1976; 58:80-88
- Hamra ST. The deep-plane rhytidectomy. *Plast Reconstr Surg* 1990;86:53-61, discussion 62-63
- Psillakis JM, Rumley TO, Camargos A. Subperiosteal approach as an improved concept for correction of the aging face. *Plast Reconstr Surg* 1988;82:383-394
- Ramirez OM. Endoscopic full facelift. *Aesthetic Plast Surg* 1994; 18:363-371
- DeFatta RJ, Williams EF. Evolution of midface rejuvenation. *Arch Facial Plast Surg* 2011;11:6-12
- Shaw RB Jr, Katzel EB, Koltz PF, et al. Aging of the facial skeleton: aesthetic implications and rejuvenation strategies. *Plast Reconstr Surg* 2011;127:374-383
- Yeh CC, Williams EF. Fat management in lower lid blepharoplasty. *Facial Plast Surg* 2009;25:234-244
- Moss CJ, Mendelson BC, Taylor GI. Surgical anatomy of the ligamentous attachments in the temple and periorbital regions. *Plast Reconstr Surg* 2000;105:1475-1490, discussion 1491-1498
- Hamra ST. A study of the long-term effect of malar fat repositioning in face lift surgery: short-term success but long-term failure. *Plast Reconstr Surg* 2002;110:940-951, discussion 952-959
- Hamra ST. Composite rhytidectomy. *Plast Reconstr Surg* 1992; 90:1-13
- Becker FF, Bassichis BA. Deep-plane face-lift vs superficial musculoaponeurotic system plication face-lift: a comparative study. *Arch Facial Plast Surg* 2004;6:8-13
- Finger ER. A 5-year study of the transmalar subperiosteal midface lift with minimal skin and superficial musculoaponeurotic system dissection: a durable, natural-appearing lift with less surgery and recovery time. *Plast Reconstr Surg* 2001;107:1273-1283, discussion 1284
- Keller GS, Namazie A, Blackwell K, Rawnsley J, Khan S. Elevation of the malar fat pad with a percutaneous technique. *Arch Facial Plast Surg* 2002;4:20-25
- Williams JV. Transblepharoplasty endoscopic subperiosteal midface lift. *Plast Reconstr Surg* 2002;110:1769-1775, discussion 1776-1777
- Yaremchuk MJ. Restoring palpebral fissure shape after previous lower blepharoplasty. *Plast Reconstr Surg* 2003;111:441-450, discussion 451-452
- Williams EF III, Lam SM. *Comprehensive Facial Rejuvenation: A Practical and Systematic Guide to Surgical Management of the Aging Face*. 4th ed. Philadelphia, PA: Lippincott Williams & Wilkins; 2003
- Coleman SR. Long-term survival of fat transplants: controlled demonstrations. *Aesthetic Plast Surg* 1995;19:421-425
- Coleman SR. Facial recontouring with lipostructure. *Clin Plast Surg* 1997;24:347-367
- Meier JD, Glasgold RA, Glasgold MJ. Autologous fat grafting: long-term evidence of its efficacy in midfacial rejuvenation. *Arch Facial Plast Surg* 2009;11:24-28
- Yeh CC, Williams EF. Long-term results of autologous periorbital lipotransfer. *Arch Facial Plast Surg* 2012;13:252-258
- Buckingham ED, Bader B, Smith SP. Autologous fat and fillers in periocular rejuvenation. *Facial Plast Surg Clin North Am* 2010; 18:385-398
- Williams EF III, Vargas H, Dahiya R, Hove CR, Rodgers BJ, Lam SM. Midfacial rejuvenation via a minimal-incision brow-lift approach: critical evaluation of a 5-year experience. *Arch Facial Plast Surg* 2003;5:470-478
- Mack WP. Complications in periocular rejuvenation. *Facial Plast Surg Clin North Am* 2010;18:435-456
- Pontius AT, Williams EF III. The extended minimal incision approach to midface rejuvenation. *Facial Plast Surg Clin North Am* 2005;13:411-419
- Flowers RS. Tear trough implants for correction of tear trough deformity. *Clin Plast Surg* 1993;20:403-415
- Yaremchuk MJ. Secondary malar implant surgery. *Plast Reconstr Surg* 2008;121:620-628