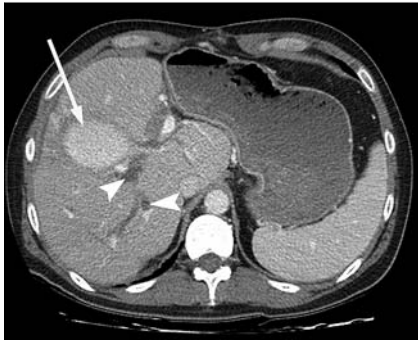

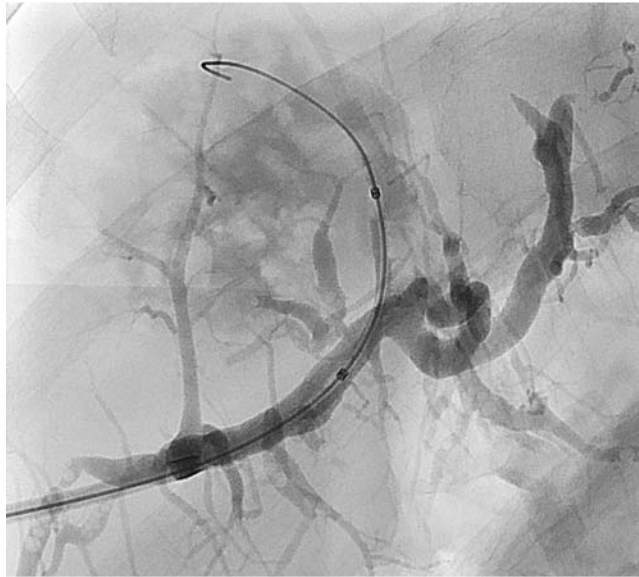## Percutaneous transhepatic biliary drainage and endoscopic retrograde cholangiography in biloma – a rendezvous procedure



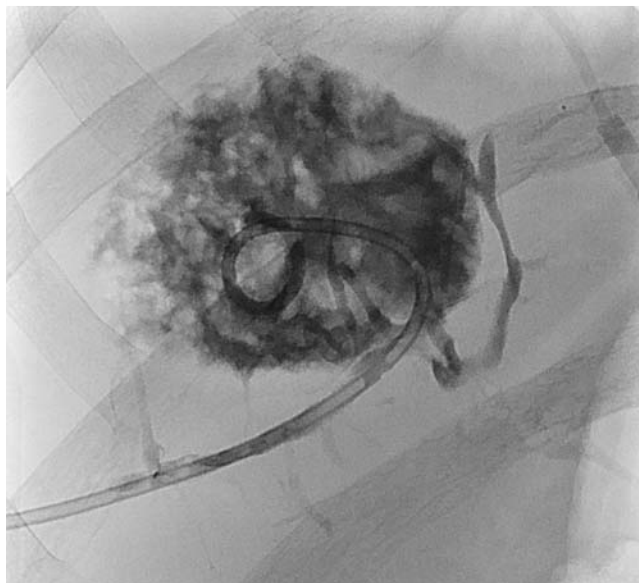
**Fig. 1** Computed tomography performed on the day after endoscopic retrograde cholangiography, showing contrast-enhanced biloma (arrow) and dilated intrahepatic bile ducts (arrowheads).

A 54-year-old man presented with jaundice and an elevated serum bilirubin level of 11.86 mg/dL after radiofrequency ablation of hepatic metastases from rectal carcinoma. A high-grade stenosis at the common bile duct (CBD) was diagnosed on endoscopic retrograde cholangiography (ERC), and computed tomography showed a 7-cm intrahepatic biloma compressing the CBD (Fig. 1). A subsequent attempt to bypass the biloma by percutaneous transhepatic biliary drainage (PTBD) failed because the exit of the biloma could not be probed. A pigtail catheter was placed to drain the biloma externally (Fig. 2, Fig. 3).

In a second procedure the patient underwent ERC and PTBD simultaneously. The biloma was successfully probed by ERC with a guide wire, which was caught and extracted with a gooseneck snare via the PTBD access (Fig. 4) to achieve a pathway through the biloma (Fig. 5). A pigtail catheter was positioned with its tip lying in the duodenum and its side holes in the bile duct peripheral to the biloma. The regression of the patient's serum bilirubin concentration to 0.91 mg/dL and complete occlusion of the biloma 6 months after the procedure showed this treatment strategy to have been successful (Fig. 6). The principle of healing a bile duct leak is to generate a low-pressure system along the biliary tract by means of internal or external drainage [1–4]. Sciumè et al. [5] described a technique employing “rendezvous” between ERC and PTBD in high-grade stenosis of bile ducts.



**Fig. 2** Percutaneous transhepatic cholangiography guide wire placed in the biloma.



**Fig. 3** Biloma drainage with a pigtail catheter placed via the percutaneous transhepatic cholangiography tract.

In our patient, wall necrosis of a central bile duct after radiofrequency ablation led to a valve mechanism that induced formation of a large biloma obstructing the CBD; this in turn led to overpressure, ending in a vicious circle. In this case, it was necessary to puncture the necrotic bile duct accurately and place an internal drain that would bridge the leak and drain the biloma by generating a low-pressure system distal and proximal to the leakage – otherwise the valve mechanism would persist and the leak would remain open. Combining ERC and PTBD in a “rendezvous” technique avoided further surgery.

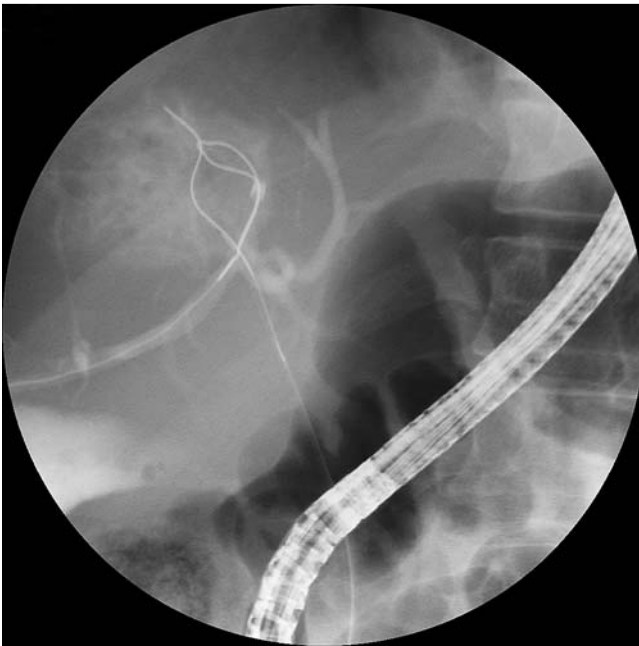Endoscopy\_UCTN\_Code\_TTT\_1AR\_2AJ

**Competing interests:** None

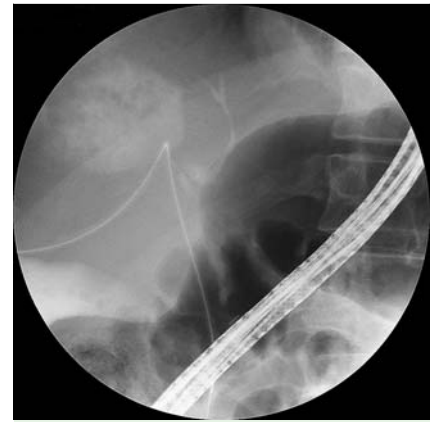**D. Bohlsen<sup>1</sup>, P. Kalmar<sup>1</sup>, F. Schreiber<sup>2</sup>, R. H. Portugaller<sup>1</sup>**

<sup>1</sup> Department of Radiology, LKH University Clinic, Medical University Graz, Graz, Austria

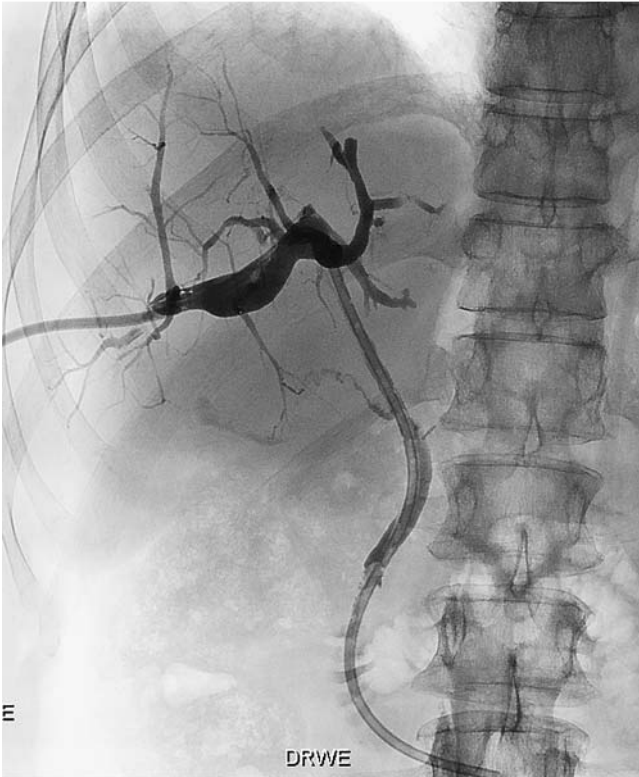<sup>2</sup> Department of Gastroenterology and Hepatology, LKH University Clinic, Medical University Graz, Graz, Austria



**Fig. 4** Rendezvous: the gooseneck snare catches the endoscopic retrograde cholangiography guide wire.



**Fig. 5** The pull-through guide wire provides a percutaneous pathway from the peripheral bile duct to the common bile duct and on into the duodenum.



**Fig. 6** After temporary placement of an 8.3-Fr pigtail catheter, a 12-Fr Munich percutaneous drainage catheter (Peter Pflugbeil GmbH, Zorneding, Germany) finally crosses the duct necrosis. The bile drains into the duodenum. The external end of the Munich catheter is capped.

## References

- 1 Portugaller RH, Hausegger KA. Image-guided interventions. 2. vol. Saunders Elsevier; 2008: 1449–1457
- 2 Vazquez JL, Thorsen MK, Dodds WJ et al. Evaluation and treatment of intraabdominal bilomas. *AJR Am J Roentgenol* 1985; 144: 933–938
- 3 Saab S, Martin P, Soliman GY et al. Endoscopic management of biliary leaks after T-tube removal in liver transplant recipients: nasobiliary drainage versus biliary stenting. *Liver Transpl* 2000; 6: 627–632
- 4 Tsukamoto T, Hirohashi K, Osugi H et al. Percutaneous management of bile duct injuries after cholecystectomy. *Hepatogastroenterology* 2002; 49: 113–115
- 5 Sciumè C, Geraci G, Pisello F et al. “Rendezvous” technique for palliation of neoplastic jaundice: personal experience. *Ann Ital Chir* 2004; 75: 643–647

## Bibliography

DOI <http://dx.doi.org/10.1055/s-0033-1344573>  
*Endoscopy* 2013; 45: E292–E293  
 © Georg Thieme Verlag KG  
 Stuttgart · New York  
 ISSN 0013-726X

## Corresponding author

**D. Bohlsen, MD**  
 Department of Radiology  
 LKH University Clinic  
 Medical University Graz  
 Auenbrugger Platz 9  
 8036 Graz  
 Austria  
[dennis.bohlsen@medunigraz.at](mailto:dennis.bohlsen@medunigraz.at)