

## Gastric gastrointestinal stromal tumor lost in the peritoneum after endoscopic resection

Submucosal tumors of the stomach are occasional findings during routine upper gastrointestinal endoscopy [1]. They may arise from any of the layers of the intestinal wall and are classified as nonepithelial or mesenchymal neoplasms [2]. The most common type is the gastrointestinal stromal tumor (GIST), first described by Mazur and Clark in 1983 [3].

A 71-year-old patient was admitted to our endoscopic unit with the diagnosis of a gastric tumor of the fundus based on gastroscopy performed in the outpatient setting. Endoscopic ultrasonography (EUS) provided a presumed diagnosis of a GIST 3×2.5 cm in size. Because the tumor was well defined, we decided to remove it by endoscopic submucosal dissection (ESD). First, we injected methylene-blue-stained saline containing epinephrine 1:100 000 submucosally. The tumor was then easily resected with a hook knife (▶ Fig. 1). However, an attempt to salvage it with a Roth net failed owing to its size. The whole procedure was then performed in reverse. By the time this was finished, the gastric wall had been perforated. The perforation site was sealed using an over-the-scope (OTS) clip. Unfortunately, once the sealing was complete and the site cleared, the tumor had been lost from sight. Duodenoscopy did not reveal it. Laparoscopy was therefore carried out and the tumor was found between the spleen and the stomach. The tumor was smoothly retrieved using the laparoscopic bag system. During the laparoscopy, leakage was tested for by injection of methylene blue solution via a feeding tube, confirming that the clipping had provided adequate closure.

▶ **Fig. 2** shows the OTS clip in the stomach 7 days after the procedure. Histopathology revealed a completely resected GIST measuring 3×2.5 cm in size.

ESD is becoming increasingly widely used for the treatment of early neoplastic lesions of the stomach and has been proposed for the treatment of submucosal tumors [4].

Endoscopy\_UCTN\_Code\_CPL\_1AH\_2AK

**Competing interests:** None

**Frank Schwandner, Ernst Klar, Leif Schiffmann**

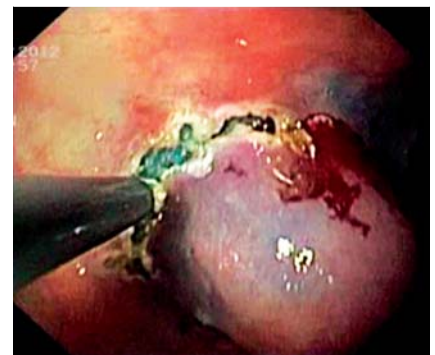Department of Surgery, University of Rostock, Rostock, Germany

### References

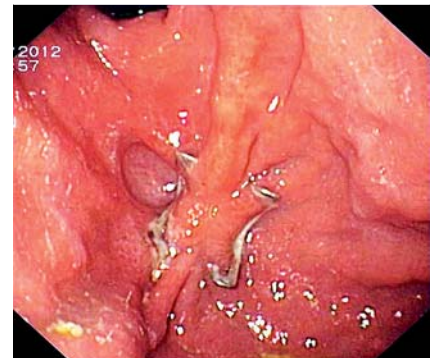
- 1 Hwang JH, Kimmey MB. The incidental upper gastrointestinal subepithelial mass. *Gastroenterology* 2004; 126: 301–307
- 2 Miettinen M, Sarlomo-Rikala M, Lasota J. Gastrointestinal stromal tumors: recent advances in understanding of their biology. *Hum Pathol* 1999; 30: 1213–1220
- 3 Mazur MT, Clark HB. Gastric stromal tumors. Reappraisal of histogenesis. *Am J Surg Pathol* 1983; 7: 507–519
- 4 Kato T, Itoh Y, Mohri T et al. Endoscopic enucleation of gastrointestinal stromal tumors of the stomach: report of five cases. *World J Gastroenterol* 2008; 14: 2609–2611

### Bibliography

**DOI** <http://dx.doi.org/10.1055/s-0034-1365814>  
*Endoscopy* 2014; 46: E349  
 © Georg Thieme Verlag KG  
 Stuttgart · New York  
 ISSN 0013-726X



**Fig. 1** Endoscopic submucosal dissection of a gastrointestinal stromal tumor with a hook knife.



**Fig. 2** Endoscopic follow-up 7 days after treatment with the over-the-scope clip.

### Corresponding author

**Frank Schwandner, MD**

Department of General, Thoracic, Vascular and Transplantation Surgery  
 University of Rostock  
 Schillingallee 35  
 18057 Rostock  
 Germany  
 Fax: +49-381-4946002  
[frank.schwandner@med.uni-rostock.de](mailto:frank.schwandner@med.uni-rostock.de)