

Ruptured Internal Carotid Artery Aneurysm Presenting with Catastrophic Epistaxis after Repeated Stereotactic Radiotherapies for Anterior Skull Base Tumor: Case Reports and Review of the Literature

Koji Fujita¹ Manabu Tamura² Osamu Masuo¹ Takahiro Sasaki¹ Toshikazu Yamoto¹ Junya Fukai¹ Naoyuki Nakao¹

¹Department of Neurological Surgery, Wakayama Medical University, Wakayama, Japan

²Tokyo Women's Medical University, Institute of Advanced Biomedical Engineering and Science, Tokyo, Japan

Address for correspondence Koji Fujita, Department of Neurological Surgery, Wakayama Medical University, 811-1 Kimiidera, Wakayama 641-0012, Japan (e-mail: kfujita@wakayama-med.ac.jp).

J Neurol Surg Rep 2014;75:e200–e205.

Abstract

Keywords

- ▶ carotid artery aneurysm
- ▶ radiation-induced aneurysm
- ▶ stereotactic radiotherapy
- ▶ stereotactic radiosurgery
- ▶ anterior skull base tumor

Objectives Radiation-induced aneurysm is a rare complication for head and neck tumors. Only seven cases of an aneurysm after stereotactic radiosurgery and/or stereotactic radiotherapy (SRT) have been described. We report two patients with a ruptured internal carotid artery (ICA) aneurysm presenting with catastrophic epistaxis after repeated SRT for an anterior skull base tumor.

Results Two male patients received repeated SRT in various combinations following surgery for an anterior skull base tumor. They presented with significant epistaxis due to rupture of the aneurysm of the ICA 6 and 77 months after the final SRT, respectively. The aneurysms were located within the radiation field. Preoperative angiography had revealed no aneurysms. Thus the aneurysms in these cases were most likely induced by the repeated SRT.

Conclusions This is a proven report of aneurysm formation following repeated SRT without conventional radiotherapy. SRT may be very effective to control malignant skull base tumors. However, the possible development of radiation-induced aneurysm of the ICA should be considered in the case of repeated SRT. The surviving patients who have received SRT should undergo sequential follow-up for possible vascular involvement.

Introduction

Radiation-induced aneurysm is a rare complication for head and neck cancer, and the pathogenesis is not fully understood.^{1–8} But the mechanism is likely to be similar to that of radiation-induced chronic vascular damage.^{9–12}

Several authors have reported ~ 30 cases of radiation-induced intracranial aneurysms with subsequent rup-

ture.^{1,2,5,8,13} These aneurysms were diagnosed from 10 months to 21 years after radiation therapy. So far, only seven cases of aneurysm after stereotactic radiosurgery (SRS) and/or stereotactic radiotherapy (SRT) have been described.^{14–20} All of these patients underwent repeated radiotherapies in various combinations.

We present two cases of catastrophic epistaxis due to a ruptured internal carotid artery (ICA) aneurysm induced by

received
July 10, 2014
accepted after revision
May 7, 2014
published online
August 5, 2014

DOI <http://dx.doi.org/10.1055/s-0034-1383859>.
ISSN 2193-6358.

© 2014 Georg Thieme Verlag KG
Stuttgart · New York

License terms



repeated SRT for an anterior skull base tumor and successfully treated by endovascular surgery. This is a proven report of aneurysm formation following repeated SRT without conventional radiotherapy. SRT for skull base tumors may be very effective to control these tumors. However, these cases suggest that the development of a radiation-induced aneurysm should be considered a possible serious complication in the case of repeated SRT. Case 1 described here was reported previously in this journal.²¹

Case Reports

Case 1

A 29-year-old man was referred to our institution for the treatment of a large Ewing primitive neuroectodermal tumor (PNET) that occupied the right orbit and ethmoid and maxillary sinus with right progressive visual loss in four years earlier (►Fig. 1A). The tumor was resected totally via the transbasal approach. Preoperative angiography revealed no abnormality. The right ICA was not injured during the surgery. Postoperatively, the patient underwent adjuvant chemotherapy and SRT with a dose ranging from 45 to 54.9 Gy in 15 fractions that produced a complete response. The right petrous ICA and surrounding structure were located within the radiation field. The recurrent tumor in the right maxillary sinus was seen 28 months after surgery. Therefore, the second

SRT was performed with a dose ranging from 53.5 to 62.3 Gy in 15 fractions that resulted in the partial response. However, 42 months after surgery, tumor relapse was revealed in the right orbit that remarkably had eroded the sphenoid bone. He underwent the third SRT with a dose ranging from 52.8 to 60.0 Gy in 15 fractions. Magnetic resonance imaging (MRI) demonstrated the tumor had almost disappeared after SRT (►Fig. 1B), and he was followed regularly as an outpatient.

The patient was admitted to our hospital with complaints of significant epistaxis with hypovolemic shock 6 months after the final SRT. A computed tomography scan revealed a hematoma at the middle cranial fossa and paranasal sinuses, and pneumocephalus (►Fig. 1C). Cerebral angiography showed a right petrous ICA aneurysm with slight stenosis of the adjacent ICA (►Fig. 1D). Because of rebleeding during the cerebral angiography, we urgently performed endovascular parent-artery occlusion without balloon test occlusion (BTO) to save his life. Cerebral angiography after the endovascular treatment showed complete disappearance of the aneurysm with a tolerable cross-flow via the anterior communicating artery (ACoA) (►Fig. 1E). The postoperative course was uneventful. Postoperative MRI revealed no ischemic or hemorrhagic complications. He recovered fully and was discharged 3 weeks after surgery without new neurologic deficits. But 6 months after endovascular treatment, he died from an untreatable tumor relapse.

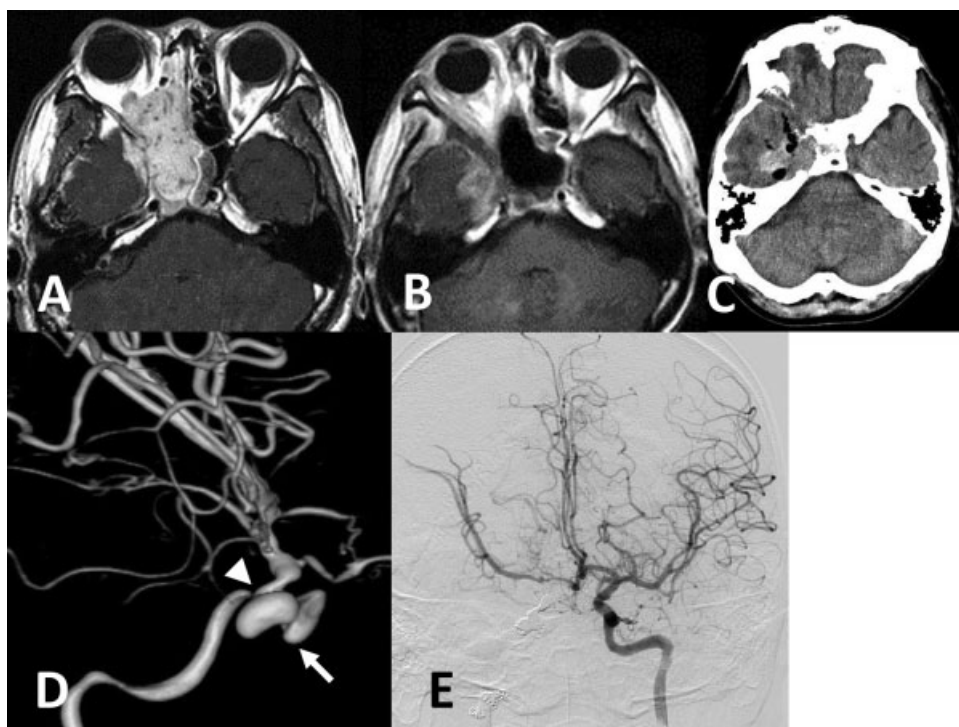


Fig. 1 (A) Axial T1-weighted magnetic resonance image with gadolinium (MRI-Gd) before the surgery revealed the tumor in the orbit and ethmoid sinus adjacent to the right internal carotid artery (ICA). (B) Axial MRI-Gd after the third stereotactic radiotherapy demonstrated remarkable shrinkage of the tumor. (C) Computed tomography scan on emergent admission due to massive epistaxis revealed the hematoma at the middle cranial fossa and pneumocephalus. (D) Right internal carotid angiogram showed a right petrous ICA aneurysm (arrow) with slight stenosis of the adjacent ICA (arrowhead). (E) Left internal carotid angiogram after the endovascular treatment revealed the tolerable cross-flow via the anterior communicating artery.

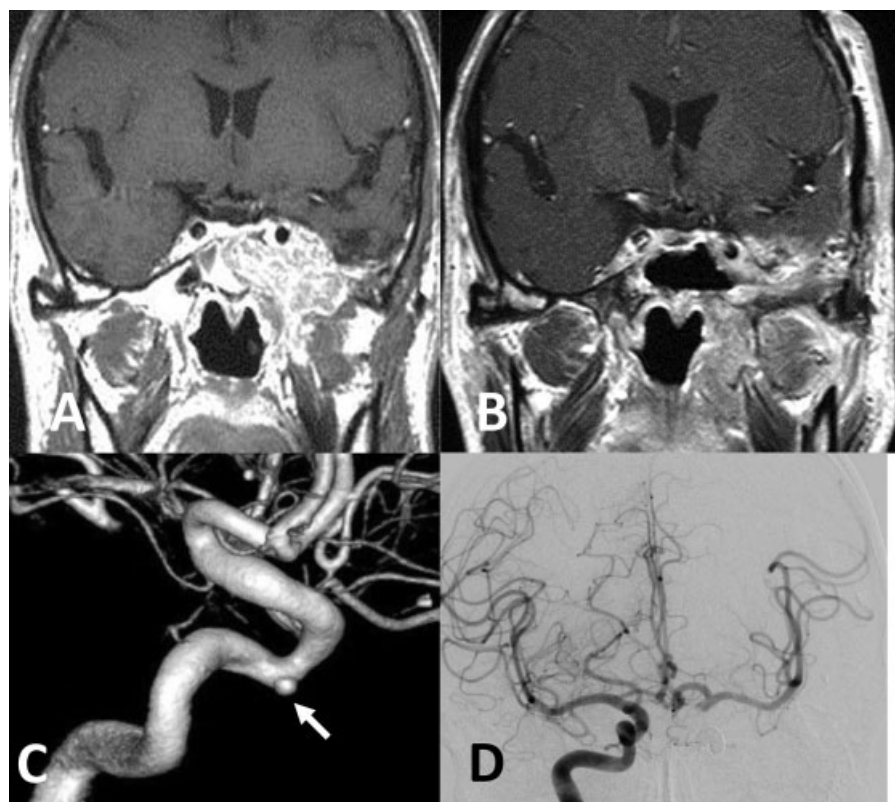


Fig. 2 (A) Coronal T1-weighted magnetic resonance image with gadolinium (MRI-Gd) after stereotactic radiosurgery revealed tumor recurrence in the cavernous sinus and the left infratemporal fossa surrounding the left internal carotid artery (ICA). (B) MRI-Gd after stereotactic radiosurgery and stereotactic radiotherapy demonstrated an almost disappearance of the tumor. (C) Left internal carotid angiogram demonstrated a small aneurysm at the left cavernous ICA (arrow). (D) Right internal carotid angiogram after the endovascular treatment showed enough collateral flow via the anterior communicating artery.

Case 2

A 61-year-old man was admitted to our hospital for the treatment of a left large sphenocavernous meningioma in 1999 at 48 years of age. The tumor was partially resected via the orbitozygomatic approach without removal of the cavernous mass. The left ICA was not damaged during the surgery. The pathologic diagnosis was atypical meningioma. The left cavernous tumor had gradually grown 23 months after the initial surgery and was treated by SRS using gamma knife. The tumor margin was covered by the 50% isodose line, and 12 Gy were delivered to the margin. The left cavernous ICA was located within the radiation field. However, the rest of the tumor continued to grow to the infratemporal fossa (→Fig. 2A). Two surgeries, using the infratemporal fossa approach and transsphenoidal approach, were required to remove the extracranial tumor without removal of the cavernous tumor 83 months after the first operation. Preoperative angiography revealed no abnormality. The left ICA was not injured during the operations. The following month, the patient underwent SRT using cyber knife with a dose ranging from 30.0 to 47.6 Gy in five fractions that produced a complete response (→Fig. 2B). He was followed up on an outpatient basis.

The patient was admitted to our hospital with complaints of massive epistaxis 77 months after the last SRT. Cerebral angiography showed a small aneurysm located at the cavern-

ous portion of the left ICA (→Fig. 2C). BTO of the left ICA demonstrated the presence of collateral flow via the ACoA without a reduced regional cerebral oxygenation state on the occluded side under the monitoring of near-infrared spectroscopy. Therefore, we decided to perform endovascular internal trapping of the left ICA. Cerebral angiography after the endovascular treatment showed complete disappearance of the aneurysm with enough collateral flow via the ACoA (→Fig. 2D). The postoperative course was uneventful. Postoperative MRI revealed no complications. He was discharged 2 weeks after the endovascular treatment without any new neurologic deficits.

Discussion

Radiation-induced carotid artery aneurysm is a rare complication of radiation therapy for head and neck carcinoma, but it is a life-threatening situation. The pathogenesis of radiation-induced aneurysm remains speculative.¹⁻⁸ However the mechanism is likely to be similar to that of radiation-induced vasculopathy, due to chronic vascular damage such as obstruction of the vasa vasorum, premature atherosclerosis, adventitial fibrosis, and necrosis of the arterial wall.⁹⁻¹² Combined with high blood pressure of the great vessel, it could result in the rupture of the arterial wall and even dissection with extravasation blood.^{13,22,23} Therefore, even

Table 1 Reported cases of internal carotid artery aneurysm after stereotactic radiotherapy

Study	Auyeung et al ¹⁵	Cheng et al ¹⁶	Endo et al ¹⁷	Case 1 (the present report) Tamura et al ²¹	Case 2 (the present report)
Age, y/Sex	52/F	57/M	62/F	29/M	61/M
Diagnosis	Nasopharyngeal carcinoma	Nasopharyngeal carcinoma	Pituitary adenoma	Ewing PNET	Atypical meningioma
Surgical resection of the tumor/ICA injury	None	None	Two transsphenoidal/No ICA injury	Transbasal/No ICA injury	Three times (orbitozygomatic, infratemporal fossa, transsphenoidal)/No ICA injury
Aneurysm rupture after the final surgery, mo	–	–	156	48	78
RT course and dose, Gy	1. Conventional RT (not described) 2. SRS (not described)	1. Conventional RT (70.4) 2. 3DCRT (40) + brachytherapy (18)	1. SRS (25–35) 2. Conventional RT (55.2)	1. SRT (45.0–54.9) 2. SRT (53.5–62.3) 3. SRT (52.8–60.0)	1. SRS (12.0–25.0) 2. SRT (30.0–47.6)
Aneurysm rupture after the final RT, mo	3	7	156	6	77
Aneurysm location	Petrous	Petrous	Petrous	Petrous	Cavernous
Presentation	Epistaxis	Epistaxis	Epistaxis	SAH, epistaxis	Epistaxis
Treatment	Stent	None (self-thrombosis)	ECIC bypass; coil	Coil	Coil
Outcome	Good (follow-up for 3 mo)	Good (follow-up for 18 mo)	Good (follow-up for 2 mo)	Died 6 mo afterward due to tumor relapse	Good (follow-up for 24 mo)

Abbreviations: 3D-CRT, three-dimensional conformal radiotherapy; ECIC bypass, external carotid-internal carotid artery bypass; ICA, internal carotid artery; PNET, primitive neuroectodermal tumor; RT, radiotherapy; SAH, subarachnoid hemorrhage; SRS, stereotactic radiosurgery; SRT, stereotactic radiotherapy.

a small radiation-induced aneurysm is more prone to rupture than other common saccular aneurysms.²⁴

The clinical characteristics of radiation-induced aneurysms differ from other saccular aneurysms.¹³ Radiation-induced aneurysms originate directly from the arterial wall, which is less likely to be influenced by the direction of the blood flow, in contrast to other saccular aneurysms. Therefore, the formation of an aneurysm after irradiation might occur at any location on the vessel included within the radiation fields. In our cases, these aneurysms were not located at a branching site and were included within the radiation field. The angiography before the initial surgery revealed no aneurysm formation. In addition, the carotid arteries were not injured during the surgery. These findings suggest that the SRT was responsible for the formation of the carotid artery aneurysm.

Several authors have reported ~ 30 cases of radiation-induced intracranial aneurysms with subsequent rupture.^{1,2,5,8,13} These aneurysms were diagnosed from 10 months to 21 years after radiation therapy. However, our literature review yielded only seven cases of aneurysm induced by SRS and/or SRT.^{14–20}

Among them, four cases were presented as anterior inferior cerebellar artery aneurysm induced by SRS (gamma knife) for vestibular schwannoma.^{14,18–20} The remaining three cases were reported as ICA aneurysms^{15–17} (→Table 1). With the inclusion of our cases, these patients were three men and two women (mean age: 52.2 years; range: 29–62 years). There were two cases of nasopharyngeal carcinoma, and one each of pituitary adenoma, atypical meningioma, and Ewing PNET. Three patients underwent operations without ICA injury before the final radiotherapy. All patients received repeated radiotherapies in various combinations. In addition, only our cases received repeated SRS or SRT without conventional radiotherapy. Although the interval between the latest radiotherapy and the diagnosis of the aneurysm varied from 3 months to 13 years (mean: 49.8 months), three cases developed within a year. These results indicated that repeated SRT causes an aneurysm to occur earlier than conventional radiotherapy or single SRT.

SRT makes it possible to deliver efficacious therapeutic doses accurately to the targeted lesion with secure preservation of adjacent normal anatomical structures. However, if these structures are located within the targeted lesion, they must be involved in the radiation field. Excessive doses into them by repeated SRT can lead to critical complications. Therefore the surviving patients who have received SRT should undergo sequential follow-up for possible vascular involvement.

Treatment for radiation-induced aneurysms includes clipping,^{2,3,5,24–26} trapping,^{11,27} and wrapping the aneurysm and parent artery.^{2,5,28,29} In addition, parent artery occlusion using an endovascular technique is effective.^{19,28,30} Because of the high risk of mortality, if the radiation-induced aneurysm ruptures, aggressive surgical intervention or endovascular treatment should be considered for the aneurysm. Sacrifice of the carotid artery would lead to severe cerebrovascular events, and therefore a BTO should be performed. If a

BTO is successful, trapping or parent artery occlusion becomes an option. If the patient cannot tolerate the test, an extracranial-to-intracranial bypass surgery should be considered. In case 1 of our series, the patient was semicomatose and in a state of hypovolemic shock due to repeated massive epistaxis. Therefore, an immediate salvage procedure was needed to save his life without performing BTO. In case 2, the patient could tolerate the test adequately. Hence ICA was sacrificed for parent artery occlusion.

We have presented two cases of a ruptured ICA aneurysm induced by repeated SRT for anterior skull base tumor. It was definitely difficult to clarify accurately the timing of aneurysm formation in our cases. In addition, although the primary factor was presumed the high dose delivered to the ICA by the repeated SRT, an unrecognized carotid injury at the former surgical intervention to the tumor or direct damage to the vessel wall by the tumor could also have been the probable causes. There are some reports on iatrogenic intracranial traumatic aneurysms after the resection of skull base tumors.^{31–33} It was suggested that most traumatic intracranial aneurysms have a symptomatic onset within 4 weeks after injury of the vessel wall.³² In our cases, however, the hemorrhagic presentation appeared 48 and 78 months after the final surgery, respectively. Therefore, we are convinced that the aneurysms in our cases were most likely induced by the repeated SRT and indicated a low probability of traumatic origin. Histologic analysis, if possible, might contribute to an understanding of the entity of these lesions.

Conclusions

We present two cases of catastrophic epistaxis due to ICA aneurysm that were most likely induced by repeated SRT for anterior skull base tumors. The SRT may be very effective to control the residual tumor as well as tumor relapse. However, the possible development of radiation-induced aneurysm of the carotid artery should be considered in the case of repeated SRT for malignant skull base tumors.

References

- 1 Azzarelli B, Moore J, Gilmor R, Muller J, Edwards M, Mealey J. Multiple fusiform intracranial aneurysms following curative radiation therapy for suprasellar germinoma. Case report. *J Neurosurg* 1984;61(6):1141–1145
- 2 Casey AT, Marsh HT, Uttley D. Intracranial aneurysm formation following radiotherapy. *Br J Neurosurg* 1993;7(5):575–579
- 3 Jensen FK, Wagner A. Intracranial aneurysm following radiation therapy for medulloblastoma. A case report and review of the literature. *Acta Radiol* 1997;38(1):37–42
- 4 Lee JK, Chelvarajah R, King A, David KM. Rare presentations of delayed radiation injury: a lobar hematoma and a cystic space-occupying lesion appearing more than 15 years after cranial radiotherapy: report of two cases. *Neurosurgery* 2004;54(4):1010–1013; discussion 1013–1014
- 5 Maruyama K, Mishima K, Saito N, Fujimaki T, Sasaki T, Kirino T. Radiation-induced aneurysm and moyamoya vessels presenting with subarachnoid haemorrhage. *Acta Neurochir (Wien)* 2000;142(2):139–143

- 6 Murros KE, Toole JF. The effect of radiation on carotid arteries. A review article. *Arch Neurol* 1989;46(4):449–455
- 7 O'Connor MM, Mayberg MR. Effects of radiation on cerebral vasculature: a review. *Neurosurgery* 2000;46(1):138–149; discussion 150–151
- 8 Pereira P, Cerejo A, Cruz J, Vaz R. Intracranial aneurysm and vasculopathy after surgery and radiation therapy for craniopharyngioma: case report. *Neurosurgery* 2002;50(4):885–887; discussion 887–888
- 9 Kiyosue H, Okahara M, Tanoue S, et al. Dispersion of coils after parent-artery occlusion of radiation-induced internal carotid artery pseudoaneurysm. *AJNR Am J Neuroradiol* 2004;25(6):1080–1082
- 10 Okamura HO, Kamiyama R, Takiguchi Y, Kimizuka K, Ishikawa N, Kishimoto S. Histopathological examination of ruptured carotid artery after irradiation. *ORL J Otorhinolaryngol Relat Spec* 2002;64(3):226–228
- 11 Sciubba DM, Gallia GL, Recinos P, Garonzik IM, Clatterbuck RE. Intracranial aneurysm following radiation therapy during childhood for a brain tumor. Case report and review of the literature. *J Neurosurg* 2006;105(2, Suppl):134–139
- 12 Silverberg GD, Britt RH, Goffinet DR. Radiation-induced carotid artery disease. *Cancer* 1978;41(1):130–137
- 13 Benson PJ, Sung JH. Cerebral aneurysms following radiotherapy for medulloblastoma. *J Neurosurg* 1989;70(4):545–550
- 14 Akamatsu Y, Sugawara T, Mikawa S, et al. Ruptured pseudoaneurysm following gamma knife surgery for a vestibular schwannoma. *J Neurosurg* 2009;110(3):543–546
- 15 Auyeung KM, Lui WM, Chow LC, Chan FL. Massive epistaxis related to petrous carotid artery pseudoaneurysm after radiation therapy: emergency treatment with covered stent in two cases. *AJNR Am J Neuroradiol* 2003;24(7):1449–1452
- 16 Cheng KY, Lee KW, Chiang FY, Ho KY, Kuo WR. Rupture of radiation-induced internal carotid artery pseudoaneurysm in a patient with nasopharyngeal carcinoma—spontaneous occlusion of carotid artery due to long-term embolizing performance. *Head Neck* 2008;30(8):1132–1135
- 17 Endo H, Fujimura M, Inoue T, et al. Simultaneous occurrence of subarachnoid hemorrhage and epistaxis due to ruptured petrous internal carotid artery aneurysm: association with transsphenoidal surgery and radiation therapy: case report. *Neurol Med Chir (Tokyo)* 2011;51(3):226–229
- 18 Park KY, Ahn JY, Lee JW, Chang JH, Huh SK. De novo intracranial aneurysm formation after gamma knife radiosurgery for vestibular schwannoma. *J Neurosurg* 2009;110(3):540–542
- 19 Takao T, Fukuda M, Kawaguchi T, et al. Ruptured intracranial aneurysm following gamma knife surgery for acoustic neuroma. *Acta Neurochir (Wien)* 2006;148(12):1317–1318; discussion 1318
- 20 Yamaguchi S, Kato T, Takeda M, Ikeda H, Kitamura K. Ruptured distal anterior inferior cerebellar artery aneurysm following stereotactic irradiation for vestibular schwannoma: case report. *Neurol Med Chir (Tokyo)* 2009;49(5):202–205
- 21 Tamura M, Kogo K, Masuo O, et al. Formation and rupture of the internal carotid artery aneurysm after multiple courses of intensity-modulated radiation therapy for management of the skull base Ewing sarcoma/PNET: Case report. *J Neurol Surg Rep* 2013;74(2):111–117
- 22 Chen HC, Lin CJ, Jen YM, et al. Ruptured internal carotid pseudoaneurysm in a nasopharyngeal carcinoma patient with skull base osteoradionecrosis. *Otolaryngol Head Neck Surg* 2004;130(3):388–390
- 23 Mok JS, Marshall JN, Chan M, van Hasselt CA. Percutaneous embolization to control intractable epistaxis in nasopharyngeal carcinoma. *Head Neck* 1999;21(3):211–216
- 24 Gonzales-Portillo GA, Valdivia JM. Uncommon presentation of pediatric ruptured intracranial aneurysm after radiotherapy for retinoblastoma. Case report. *Surg Neurol* 2006;65(4):391–395; discussion 395–396
- 25 Aichholzer M, Gruber A, Haberler C, Bertalanffy A, Slavic I, Czech T. Intracranial hemorrhage from an aneurysm encased in a pilocytic astrocytoma—case report and review of the literature. *Childs Nerv Syst* 2001;17(3):173–178
- 26 Yucsey K, Feiz-Erfan I, Spetzler RF, Han PP, Coons S. Anterior communicating artery aneurysm following radiation therapy for optic glioma: report of a case and review of the literature. *Skull Base* 2004;14(3):169–173
- 27 McConachie NS, Jacobson I. Bilateral aneurysms of the cavernous internal carotid arteries following yttrium-90 implantation. *Neuroradiology* 1994;36(8):611–613
- 28 Murakami N, Tsukahara T, Toda H, Kawakami O, Hatano T. Radiation-induced cerebral aneurysm successfully treated with endovascular coil embolization. *Acta Neurochir Suppl (Wien)* 2002;82:55–58
- 29 Nishi T, Matsukado Y, Kodama T, Hiraki T. Multiple intracranial aneurysms following radiation therapy for pituitary adenoma. Case report. [in Japanese]. *Neurol Med Chir (Tokyo)* 1987;27(3):224–228
- 30 Cheng KM, Chan CM, Cheung YL, Chiu HM, Tang KW, Law CK. Endovascular treatment of radiation-induced petrous internal carotid artery aneurysm presenting with acute haemorrhage. A report of two cases. *Acta Neurochir (Wien)* 2001;143(4):351–355; discussion 355–356
- 31 Ciceri EFM, Regna-Gladin C, Erbetta A, et al. Iatrogenic intracranial pseudoaneurysms: neuroradiological and therapeutic considerations, including endovascular options. *Neurol Sci* 2006;27(5):317–322
- 32 Mathews SS, Kumar RM, Rupa V. Iatrogenic pseudoaneurysm: a rare complication of sinonasal surgery. *Am J Otolaryngol* 2011;32(6):607–610
- 33 Chen Z, Zhang J, Miao H, Niu Y, Feng H, Zhu G. Delayed rupture of iatrogenic cerebral pseudoaneurysms after neurosurgical procedures: report of two cases. *Clin Neurol Neurosurg* 2013;115(8):1552–1554