

Can Platelet-Rich Plasma Enhance Anterior Cruciate Ligament and Meniscal Repair?

Ian D. Hutchinson, MD¹ Scott A. Rodeo, MD² Gabriel S. Perrone, MS³ Martha M. Murray, MD³

¹Department of Orthopaedic Surgery, Wake Forest Baptist Health, Winston Salem, North Carolina

²Sports Medicine and Shoulder Service, Hospital for Special Surgery, New York, New York

³Department of Orthopaedic Surgery, Boston Children's Hospital, Harvard Medical School, Boston, Massachusetts

Address for correspondence Scott A. Rodeo, MD, Sports Medicine and Shoulder Service, Hospital for Special Surgery, 535 East 70th Street, New York, NY 10021 (e-mail: rodeos@hss.edu).

J Knee Surg 2015;28:19–28.

Abstract

Keywords

- ▶ ACL
- ▶ meniscus
- ▶ PRP
- ▶ biologics
- ▶ meniscal repair
- ▶ ACL reconstruction

The use of platelet-rich plasma (PRP) to improve clinical outcome following a soft tissue injury, regeneration, and repair has been the subject of intense investigation and discussion. This article endeavors to relate clinical and basic science strategies focused on biological augmentation of the healing response in anterior cruciate ligament (ACL) and meniscus repair and replacement using PRP. Therein, a translational feedback loop is created in the literature and targeted towards the entire multidisciplinary team. Ultimately, it is hoped that the theoretical benefits of PRP on soft-tissue interfacial healing will emerge clinically following a careful, focused characterization at the benchtop, and prospective randomized controlled clinical study.

Intra-articular tissues such as the anterior cruciate ligament (ACL) and meniscus have an intrinsically poor healing capacity. This has led to an intense interest in discovering methods to augment the biological responsiveness of cells in these tissues. Platelet-rich plasma (PRP) contains various growth factors, including transforming growth factor β -1 (TGF- β 1), fibroblast growth factor-2 (FGF-2), insulin-like growth factor (IGF-1), epidermal growth factor, platelet-derived growth factor (PDGF), and vascular endothelial growth factor (VEGF) that have demonstrated positive effects on cell proliferation, cell migration, angiogenesis, and extracellular matrix production in numerous cell types both *in vivo* and *in vitro* models.^{1–5} The primary cell in the ACL is the fibroblast. The fibroblast has receptors for many of the growth factors released by platelets, including PDGF, TGF- β , and FGF. PDGF (▶ **Table 1**) stimulates fibroblast growth, migration, and biosynthetic activity.⁶ Similar effects are seen with TGF- β and FGF. *In vitro*, ACL cell migration has been stimulated by TGF- β 1, while PDGF and FGF stimulate cell proliferation in a three-dimensional (3D) collagen scaffold.⁷ In this review, we will explore the current data relating to the use of PRP and

related materials in the augmentation of ACL and meniscus healing.

The current surgical treatment for ACL injuries is ACL reconstruction where the torn ACL is replaced with a graft of the tendon. However, the recent research has focused on the use of platelets and PRP to heal the injured ligament, rather than replace it. These studies have not yet progressed to a clinical trial, and in this section we will review the basic science behind the preclinical development of this new technique.

Previous studies have demonstrated that ligaments which exist outside of joints (extra-articular) heal with an orderly progression of events. The first basic process is bleeding and then formation of a fibrin-platelet clot within the wound site, which fills in the gap between the torn ends of the tissue and forms a provisional scaffold for the surrounding cells to move into and remodel into a functional scar. However, in the intra-articular environment, after an injury, there is an upregulated production of urokinase plasminogen activator by synovio-cytes (▶ **Fig. 1**), which converts the inactive plasminogen molecule present in synovial fluid into its active form, plasmin.⁸ Plasmin quickly degrades fibrin. Therefore, if a tissue is

received

March 25, 2014

accepted after revision

June 25, 2014

published online

August 7, 2014

Copyright © 2015 by Thieme Medical Publishers, Inc., 333 Seventh Avenue, New York, NY 10001, USA.
Tel: +1(212) 584-4662.

DOI <http://dx.doi.org/10.1055/s-0034-1387166>.
ISSN 1538-8506.

Table 1 Growth factors associated with PRP

Name	Effect ^a	Source ^b
Platelet-derived growth factor	Proliferation, migration, angiogenesis, and collagen production	Platelets
Platelet-derived angiogenesis factor	Stimulation of proliferation of endothelial cells and angiogenesis	Platelets
Platelet-derived endothelial growth factor	Stimulate wound healing via proliferation of fibroblasts and keratinocytes	Platelets
Platelet factor 4	Stimulates migration of neutrophils, acts as chemoattractor for fibroblasts, heparin antagonist	Platelets
Vascular endothelial growth factor	Angiogenesis and unclear effect on fibroblasts	Platelets
Transforming growth factor- β 1	Proliferation, differentiation, collagen production, and fibronectin production	Platelets
Transforming growth factor- β 2	Embryonic development and wound healing	Platelets
Fibroblast growth factor	Fibroblast and myoblast stimulation	Platelets
Epidermal growth factor	Cell proliferation (mesenchymal and epithelial). Complex interaction with other growth factors	Platelets
Hepatocyte growth factor	Migration, angiogenesis, and antifibrotic effect	Plasma ^c
Insulin-like growth factor-1	Fibroblast and myoblast stimulation, muscle growth and regeneration	Plasma ^c

Abbreviation: PRP, platelet-rich plasma.

Source: Reprinted with permission from Murray et al.⁹⁴

^aAs known.

^bSome growth factors are released from the cells other than platelets.

^cAll growth factors are not released by the platelets.

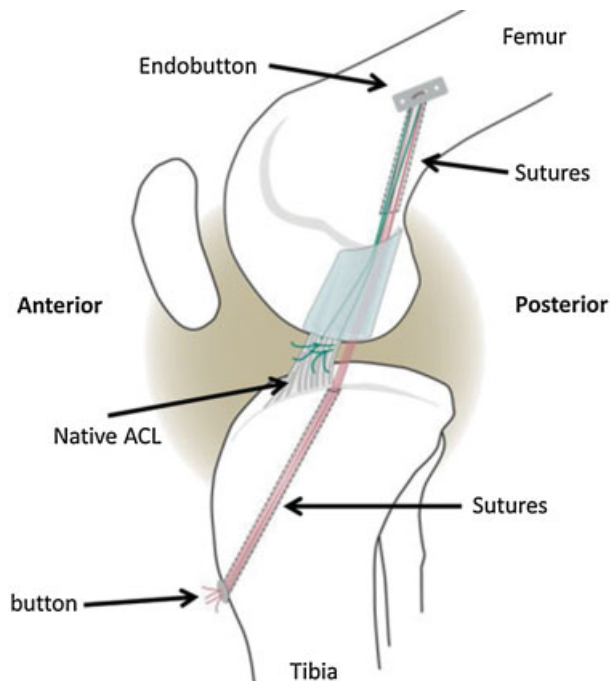


Fig. 1 Diagram depicting the bio-enhanced repair of the ACL with the ECM scaffold in place. Sutures were fixed proximally with an Endobutton (Smith & Nephew, Inc., Andover, MA). The scaffold is threaded onto four of the trailing suture ends (red), which were then passed through the tibial tunnel and tied over a button to provide initial knee stability. The remaining two suture ends (green) were tied to the sutures in the tibial stump of the ACL. Autologous blood of platelet-rich plasma can then be placed into the scaffold to provide a biologic boost for healing.^{15,16} ACL, anterior cruciate ligament; ECM, extracellular matrix. (Reprinted with permission from Fleming et al.⁹⁵)

exposed to synovial fluid after injury, the ends may bleed, but the fibrin is unable to form a stable clot as it is degraded too quickly.^{9–11} The early loss of this provisional scaffold has been thought to be a major reason why tissues within joints, such as the ACL or meniscus, fail to heal after the injury.^{9,10}

PRP has been evaluated in animal models to stimulate healing of the ACL with suture repair; unfortunately, it has been found to be ineffective.¹² In a larger animal study using 4-month-old Yorkshire pigs, the addition of a 3 \times PRP to the suture repairs did not improve knee laxity or the maximum tensile load of the suture repairs after 14 weeks in vivo. The strength of all repairs at 14 weeks was less than 11% of the intact ligaments, suggesting minimal healing with all repairs.¹² The use of PRP therefore, may have failed because the main structural protein within PRP is also fibrin. Therefore, the fibrin in the PRP is degraded by the active plasmin within the joint and the PRP is unable to stay in the ACL wound site. Interestingly, when collagen is combined with fibrin, a copolymer is formed which is resistant to degradation by plasmin.¹³ Further studies using a collagen-based scaffold material to deliver the PRP have had greater success in stimulating ACL healing in animal models as the carrier stabilizes and protects the fibrin and platelets in the ACL wound site.^{14–16}

Collagen—Platelet Composites in Anterior Cruciate Ligament Repair

While the use of PRP alone was ineffective at stimulating ACL healing and repair, the use of PRP in combination with an

extracellular matrix protein scaffold containing collagen has resulted in a new technique for ACL treatment. This treatment of “bio-enhanced ACL repair” has been evaluated in two recent large animal studies in the porcine model, both of which reported no significant difference in mechanical properties when the bio-enhanced ACL repair and ACL reconstruction using an allograft tendon were compared at 3 months¹⁵ and 1 year¹⁵ after the surgery. The mean values for yield load were identical in the repaired and reconstructed groups at 3 months after the surgery, while the mean values for maximum load and linear stiffness were higher in the bio-enhanced repair group at 3 months; however, these differences were not statistically significant, possibly due in part to the variability seen in both the groups.¹⁵ In addition, at 3 months, the mean values for the anteroposterior laxity of the knee were lower in the bio-enhanced ACL repair group than in the ACL reconstructed group, although again, these differences were not statistically significant, which may also be due in part to the variability in both the groups.¹⁵ For the porcine knees studied at 1 year after ACL repair (►Fig. 1) using bioenhancement with an extracellular matrix scaffold loaded with whole blood resulted in repairs with the same maximum load, stiffness, and knee laxity as animals treated with a bone-patellar tendon-bone allograft, but the animals treated with bio-enhanced repair had no more cartilage damage at 1 year than the contralateral knee, while the animals treated with ACL reconstruction had large lesions noted, particularly on the medial femoral condyle,¹⁵ which is the same anatomic location seen in human patients at 10 to 15 years after ACL reconstruction.

The 1-year study in the porcine model referred to above¹⁵ used whole blood as the biological adjuvant. It is possible that the results would be even better if a higher concentration of platelets were used in the form of PRP placed within a carrier to allow it to persist for a long enough period in the wound site. It has previously been reported that biological relationships are not always linear, but are often confined to a small window of effectiveness (i.e., the dose–response curve is not linear). In addition, as PRP is a stimulator of other cells, a higher concentration may or may not be helpful because its effects are dependent on the presence of responsive cells.¹⁷ If only a limited number of cells capable of responding are available, then the highest concentration of PRP may not be able to produce a result better than a lower concentration. Finally, while there is evidence for many positive effects of PRP on wound healing, there is also an evidence for some negative effects.^{18–21} It is not known how higher concentrations of platelets affect the balance between positive and negative effects of PRP.^{18,20,21}

Experimental data examining the effect of various concentrations of platelets in PRP on ACL cells in vitro and in vivo have been performed. The use of higher concentrations of platelets (3× or 5×) in vitro were not as effective as 1× platelet preparations at stimulating types I and III collagen gene expression and cell metabolism and preventing apoptosis.²² Increasing the platelet concentration in vivo from 3× to 5× did not result in any improvement in the structural properties of the healing ACL,²³ although the group treated

with 5× PRP did have a higher cell number seen in the healing tissue. While not statistically significant, the means of the mechanical properties of the group treated with the 3× platelet concentration were better than the 5× group. Thus, in vitro and in vivo data currently suggests that the use of concentrations of platelets greater than 1× within extracellular matrix scaffolds may not be as effective at stimulating ACL healing as physiologic concentrations. However, the inclusion of plasma with platelets has been found to improve ACL fibroblast collagen gene expression. In vitro studies looking at the combination of platelets and plasma on ACL cells have found that while exposing ACL fibroblasts to platelets or plasma resulted in decreased cell death and an increased metabolic activity of the cells in a collagen hydrogel, the combination of both platelets and plasma was required to stimulate type I and type III collagen gene expression.²⁴

In summary, suture repair of the ACL is not improved with the use of PRP alone, but the ACL can be effectively repaired with the use of whole blood containing a physiological concentration of platelets in an extracellular matrix-based scaffold. The results of this bio-enhanced repair technique are similar to ACL reconstruction in terms of the mechanical properties of the healing tissue and graft, but the bio-enhanced repairs resulted in less posttraumatic osteoarthritis in large animals.

Anterior Cruciate Ligament Reconstruction and Platelet-Rich Plasma

The use of platelets to improve the mechanical properties and performance of an ACL graft seems a reasonable approach to improving outcomes of this operation. As noted above, when platelets are combined with collagen, the combination can help heal partial and complete transections of the ACL.^{25–28} Thus, it seems reasonable to assume that a platelet-based preparation could also stimulate ACL graft healing.

Use of a collagen–platelet composite to enhance ACL graft healing has recently been studied in large animal models. In goats, the use of a collagen–platelet composite resulted in a 30% reduction in knee laxity over grafts treated with a collagen scaffold alone.²⁹ The platelet preparation used in this study was whole blood (1× platelets).

Another study in pigs evaluated the performance of a 5× PRP solution in combination with a collagen scaffold on graft healing in immature animals.³⁰ Significant improvements in the graft tensile properties were found with the use of the 5× PRP–collagen composite with a 60% increase in failure load of the graft and decreased laxity of the PRP knees at 3 months after surgery.³⁰ These data provide encouragement regarding the efficacy of the platelet-enhanced ACL reconstruction approach in immature animals.

However, when a similar study was performed in adolescent animals, the results were not as promising. The use of a 1× PRP–collagen composite resulted in improved stiffness of the graft, but higher concentrations (3× and 5×) did not. The use of the collagen–platelet composite did, however, result in less cartilage damage to the knees when evaluated

at 3 months after surgery than the knees treated with graft reconstruction alone.³¹

While no clinical trials for the use of collagen-platelet composites have been conducted till date, several clinical studies evaluating the effect of the addition of exogenous platelets on graft healing have been performed. A recent systematic review identified eight studies, seven of which focused on graft maturation and five on bone-tendon healing in the tunnel.³² Four of the seven studies reported significantly better maturation “outcomes” in the grafts treated with concentrated platelets compared with those that were not.^{33–36} In one study, evaluation of the grafts with magnetic resonance imaging (MRI) revealed that the signal intensity of a graft treated with 9× platelet solution at the time of surgery matched that of the intact PCL in 100% of the patients as compared with only 78% of those treated with a graft alone at 6 months after surgery.³³ However, no differences in clinical outcomes between the treated and untreated groups were reported.³³ A second study using MRI also found that the use of a 9× platelet concentrate reduced the average time to achieve a normal MRI signal intensity value from 369 to 177 days.³⁵ Qualitatively, it has been observed that grafts treated with concentrated platelets (3 ×) showed higher arthroscopic ratings for synovial coverage, graft width, and graft tension in the platelet-treated group when compared with the controls.³⁴ Histology revealed that the ligament maturity index²⁶ was significantly greater in the platelet-treated grafts.³⁴ Other studies have found no differences between the grafts treated with platelets versus untreated grafts in any outcome measures.^{37–39}

The majority of studies evaluating graft-bone healing have found no improvements in healing at the graft-bone junction.^{33,36,38,40} In summary, the review of the literature suggests that the use of platelet concentrates may improve the rate at which grafts achieve low-signal intensity on MRI or an improved ligament maturity index on histology^{33–35}; however, none of them showed an improvement of clinical or patient oriented outcome even at 2 years,^{32,33,36,39} or significantly improved bone-tendon healing.^{33,36,38,40}

The results of the preliminary studies provide credence to the concept of bio-enhancing healing of an ACL graft with the application of platelets at the time of surgery. However, only two of the eight clinical studies that have been published meet the standards of level 1 evidence and none of them report long-term outcomes (> 2 years). Thus, the effects of these concentrated platelet preparations on cartilage health and overall knee joint function after ACL injury and reconstruction remain unknown. In addition, the PRP and platelet concentrate formulations used in the various studies differed not only in platelet concentration, but also in the concentration of white blood cells and PRP activation technique. It is extremely likely that the other blood constituents in some of the preparations of PRP (i.e., leukocytes, erythrocytes) may be important in ACL graft healing.⁴¹ As noted earlier, for ACL repair, the delivery of the platelet preparation may also prove to be important for graft healing as well. Future studies will be required to find the best way to deliver a platelet preparation, as well as how to optimize the biologic adjunct to maximally

stimulate the healing response of the graft, and to improve the long-term outcomes after ACL reconstruction, particularly in terms of preventing the development of posttraumatic osteoarthritis.

Biological Enhancement of Meniscal Restoration

The meniscus functions in the knee joint by distributing load, improving congruency, enhancing stability, and provides joint lubrication contributing to the reproducible articulation between the femur and the tibia.^{2,5} When the integrity of the meniscus is disrupted, contact stresses are increased, leading to a well-established association with osteoarthritis.^{42–45} Thus, current treatment paradigms advocate for meniscal restoration where possible and biological strategies have focused on expanding operative intervention to allow repair and healing of tears with unfavorable healing characteristics.⁵ The use of exogenous fibrin clot is representative of earlier augmentation techniques in meniscal repair and has demonstrated some success in animal and clinical studies despite the technical difficulties of keeping the clot in situ at the repair site.^{46–49}

Vascularization of the meniscus is inextricably linked to the success of meniscal repair and delineates zonal variations in cellular and biochemical composition of the meniscal tissue.² During prenatal development the meniscus is a fully vascularized and relatively homogenous tissue; during childhood, there is a regression of the peripheral vascularization. By the age of 10 years, the peripheral (10–30%) meniscus is vascularized and this changes minimally to 10 to 25% by skeletal maturity.⁵⁰ For the purpose of preclinical study and clinical correlation, the meniscus has been divided into three zones: the red-red zone (vascularized), red-white zone (partial vascularization), and white-white zone (avascular). Biological augmentation techniques have been focused on improving clinical outcome for tears that extend into the avascular zone.⁵¹

When specific tear or patient characteristics are unfavorable for primary repair, partial or total meniscectomy is often undertaken to relieve patient symptoms.⁵² In orthopedic centers currently outside the United States, biodegradable meniscal scaffolds (Collagen meniscus implant, Ivy Sports Medicine, Montvale, NJ; Actifit, Orteq Limited, London, United Kingdom) are implanted immediately following partial meniscectomy in knees that demonstrate minimal degenerative cartilage changes; ligamentous repair, cartilage restoration, and realignment procedures may be performed concomitantly.⁵ The goal of implanting a meniscal scaffold is to promote meniscal tissue regeneration on a 3D matrix in the defect space. Scaffolds are fixed to adjacent meniscal tissue from the peripheral rim through the body of the meniscus using sutures; the meniscal-scaffold interface often extends from the red-red vascularized zone to the inner white-white avascular zone. Cellular infiltration and matrix deposition across the meniscus-scaffold interface (constituting biological integration) are critical for the success of meniscal scaffolds that have been associated with promising

clinical results.^{53–56} Biological enhancement of meniscal repair at the meniscus–meniscus tissue interface shares common biological goals with meniscal regeneration at the meniscus–scaffold interface in terms of cellular migration and matrix deposition at the regeneration site and warrants consideration in anticipation of biological augmentation of meniscal scaffold technology.

The primary cell in the meniscus is the fibrochondrocyte. However, fibrochondrocytes are subject to zonal variations in morphology and behavior likely relating to the surrounding matrix and the presence of vascularity.⁵⁷ Inner white–white zone fibrochondrocytes are more chondrocyte-like and are situated in a glycosaminoglycan (GAG) rich matrix that has higher levels of type II collagen (relative to the rest of the meniscus) and approximate the composition of articular cartilage. In contrast, the outer meniscus contains fibrochondrocytes that are more fibroblast-like in a vascularized matrix consisting of mainly type I collagen and relatively less GAG than the inner zones.² In addition, a surface layer fibrochondrocyte cell type has also been described.⁵⁷ Accordingly, many *in vitro* studies have differentially tested fibrochondrocytes by zone when assessing cell behavior and this is important in the translational interpretation of preclinical *in vitro* testing of biologics toward improved meniscal repair.^{4,57–59}

Platelet-Rich Plasma: Potential Benefits in Biologically Unfavorable Meniscal Tears

The various cytokines in PRP are known to positively affect fibrochondrocyte migration and extracellular matrix production *in vitro*.^{1–5} Accordingly, Ishida et al reported a preclinical study of the effects of PRP on meniscal tissue regeneration using a gelatin hydrogel.⁶⁰ In their study, PRP was prepared using a double spin technique. The *in vitro* section of the study investigated the effects of PRP on rabbit fibrochondrocytes harvested from the inner two-thirds of the meniscus; specifically, PRP was compared with platelet poor plasma (PPP) and in the control group the media was supplemented with 1% fetal bovine serum (FBS). Platelet counts were recorded and growth factor compositional analysis revealed significantly more PDGF-BB, TGF- β 1, and VEGF in the PRP compared with the PPP. *In vitro* results demonstrated the significant positive effects of PRP on cell viability/proliferation and matrix production (sulfated GAG). Gene expression analysis revealed no difference in type I collagen expression, significant upregulation of biglycan and decorin, and significant downregulation of aggrecan expression in the PRP-treated cells. During the *in vivo* study arm, 30 μ L of PRP was incorporated in cross-linked, lyophilized gelatin hydrogels in a dropwise fashion, and the hydrogel was incubated for 1 hour to facilitate PRP incorporation. Hydrogel groups (PRP, PPP, and control—phosphate buffered saline) were implanted in a 1.5 mm defect in the anterior inner two-thirds of the meniscus in skeletally mature rabbits. A semiquantitative repair scoring system was used based on histological analysis (hematoxylin-eosin and safranin-O). The findings demonstrated increased tissue bonding, fibrochondrocyte number,

and GAG matrix in the PRP group as compared with the PPP and the control at 4, 8, and 12 weeks. The hydrogel persisted to the 4 week time point and the increased tissue regeneration trends in the PRP group were significant at 12 weeks. Of note, the PPP and control groups were seen to have a more fibrous repair with relatively decreased GAG staining. The whole joint assessment revealed slight synovial hypertrophy in some animals (groups not specified) and no clear degeneration of the articular cartilage was found in any group.

Meniscal Tears: Treating the Whole Joint

It is important to remember that the treatment of meniscal deficiency should always be undertaken within the context of treating the whole knee joint. Ultimately, mitigating the effects of temporal or absolute meniscal deficiency on premature knee joint degeneration represents the extended goal of meniscal surgery; patients with untreated meniscal tears have an odds risk of 5.7 of developing osteoarthritis and successful meniscal repair has demonstrated improved long-term outcome.^{61,62} Incorporating the use of PRP in the surgical treatment of biologically unfavorable meniscal tears must account for the knee functioning as an organ with significant interplay of the soft tissues.⁶³ In this regard, consideration of the delivery and exposure of bioactive growth factors from biologics including PRP is critically important. Intra-articular administration of PRP has been undertaken in patients with acute chondral lesions and symptomatic early joint degeneration.^{64–67} The potential benefits of intra-articular administration of PRP in the setting of meniscal deficiency and repair relates to: (1) anti-inflammatory effects within the whole joint impacting the meniscal tissue healing response and the integrity of the unaffected meniscal and articular cartilage tissue and (2) direct stimulation of synoviocytes that have been implicated in contributing to meniscal repair and maintaining the whole joint health.

Following acute meniscal (and ACL) injury, proteoglycan fragments in the synovial fluid are seen to peak acutely and persist to at least 4 years.⁶⁸ Characterization of the posttraumatic knee joint synovial fluid has documented elevated levels of IL-1 β , IL-6, IL-8, IL-10, and tumor necrosis factor (TNF)- α and may account for the release (and increased turnover) of cartilage matrix constituents following injury.⁶⁹ Exposure of meniscal tissue to IL-1 and TNF- α has been shown to result in decreased matrix production and GAG composition, particularly in the setting of altered loading; this is likely the consequence of activation of catabolic pathways involving nitric oxide, matrix metalloproteinases, and prostaglandin E₂.^{70–72} It follows that using an established *in vitro* model of meniscal repair, McNulty and colleagues demonstrated the detrimental effects of IL-1 and TNF- α on simulated meniscal tear healing *in vitro*; enhanced integrative repair of the porcine meniscal tissue was subsequently achieved following inhibition of IL-1 and TNF- α .^{73,74} PRP has been documented to have anti-inflammatory properties through its effects on the canonical nuclear factor κ B signaling pathway in multiple cell types, including synoviocytes and chondrocytes.⁷⁵ Sundman et al demonstrated this effect of

PRP on knee joint tissues using cocultured chondrocytes and synoviocytes harvested from osteoarthritic patients. In their study, treatment of the osteoarthritic cocultures with PRP decreased concentrations of TNF- α released into the media (IL- β 1 levels were undetectable overall).⁷⁶ Degenerative meniscal tears in arthritic joints are generally considered unsuitable for repair and are often resected in symptomatic patients who fail conservative measures. However, emerging evidence from Stone et al, suggests that the arthritic meniscus may play an active biological role in knee joint degeneration and patients with degenerative tears may also benefit from an anti-inflammatory effect of PRP.⁷⁷

Intra-articular administration of PRP in the presence of an acute meniscal tear in an otherwise healthy knee may also be of benefit by directly stimulating synoviocytes in the knee joint. Synovial fibroblasts (type B synoviocytes) have previously been implicated to contribute to meniscal repair and tissue regeneration using meniscal scaffolds.^{46,78,79} In addition, synoviocytes (types A and B) have been recruited in surgical strategies to improve outcome following meniscal repair including synovial advancement flap, synovial–meniscal rasping, and conduits from abaxial synovial perimeniscal capillary plexus to the repair site.⁸⁰ In the equine model, coculture of synoviocytes and chondrocytes from the site of an acute cartilage injury demonstrated a protective effect of healthy synoviocyte coculture in preventing the damaged chondrocytes from developing an osteoarthritis phenotype in vitro, suggesting that they may have a role in maintaining knee joint health following acute soft tissue injury.⁸¹ However, it has recently been suggested by Braun et al that PRP composition may be particularly important when targeting synoviocytes during intra-articular administration; in their study leukocyte-rich PRP and red blood cells (RBCs) resulted in synoviocyte cell death and proinflammatory mediator production.⁸² Based on these findings, the authors recommend leukocyte poor, RBC-free PRP formulations for intra-articular administration.

Meniscal Tears: Targeting the Tear Interface

Treatment strategies using PRP may also be customized to target the tear interface directly. Some PRP preparations have

adhesive properties, although these are likely to be short lived in the acutely injured joint secondary to the increased plasmin, as previously discussed. Therefore, not unlike the use of blood clot, a significant limitation of in situ PRP administration to the tear interface is delivery—maintaining position and directing bioactive growth factors to the surrounding tissue.^{46,47} Delivering PRP using a scaffold or hydrogel matrix represents a potential solution to this problem, as demonstrated in vivo.^{60,83} Of particular interest are collagen-based scaffolds and hydrogels given that: (1) the collagen–fibrin copolymer is resistant to degradation by plasmin; (2) collagen scaffolds are already used in the treatment of meniscal defects, and (3) collagen matrices have been used to deliver biologics to meniscal tears.^{13,84,85}

Platelet-rich fibrin (PRF) represents an exciting alternative to PRP in targeting interfacial biological augmentation of meniscal repair. In addition to having increased ease of surgical handling, PRF provides a growth factor-laden 3D matrix environment, facilitating cellular population across the tear interface.^{86,87} PRF has demonstrated increased and prolonged release of TGF- β 1, a growth factor shown to improve meniscal healing, as compared with blood clots, in vitro.^{3,86} Zumstein et al characterized growth factor release from leukocyte and platelet rich fibrin (L-PRF) and whole blood and demonstrated increased and prolonged release of growth factors, including TGF- β 1, IGF-1, PDGF-AB, and VEGF. In a subsequent prospective controlled pilot study, the same group demonstrated increased early vascularization (6 weeks) of rotator cuff repair in tears treated with PRF; it is postulated that increased vascularization may ultimately increase early cellular responses during healing.⁸⁸ Preliminary data from ongoing in vitro work in the senior author's laboratory (S. A. R.) suggests that PRF may increase fibrochondrocyte migration to a simulated meniscal tear interface. Using a novel, one-dimensional meniscal explant growth factor diffusion model (\rightarrow Fig. 2), directional cell migration was stimulated through explant tissue by PRF and was compared with blood clotting and control (empty) study groups. Briefly, the red–white zone mature bovine explants were cultured in full media (10% FBS) and cellular migration was determined by parameterizing the cellular distribution in

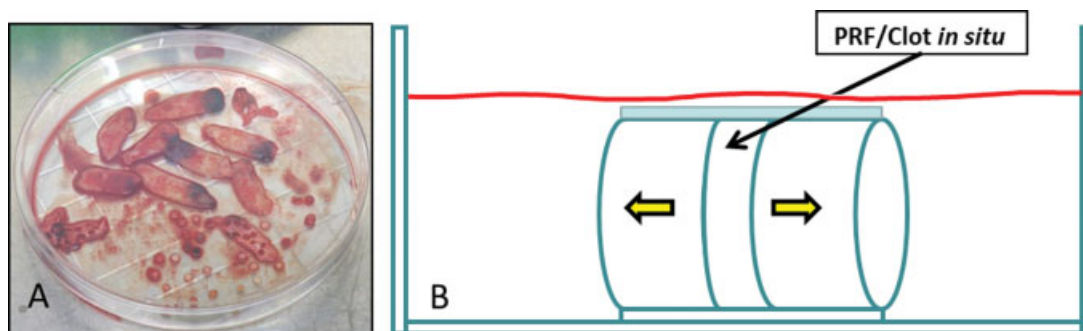


Fig. 2 (A) PRF matrices were prepared using peripheral venous blood that was centrifuged at 400g for 12 minutes using a table-top centrifuge specifically designed for this application. The PRF was then allowed to congeal on a custom draining system after which, the PRF was cored using a 6-mm biopsy punch and sandwiched between the two meniscal cores. (B) A schematic representation of the simulated meniscal interface in vitro. Within the 6-mm cloning tube, a one-dimensional growth factor diffusion gradient is created (yellow arrows). PRF, platelet-rich fibrin. (Image courtesy of Marco Demange, MD and Michael Schär, Hospital for Special Surgery, New York, NY.)

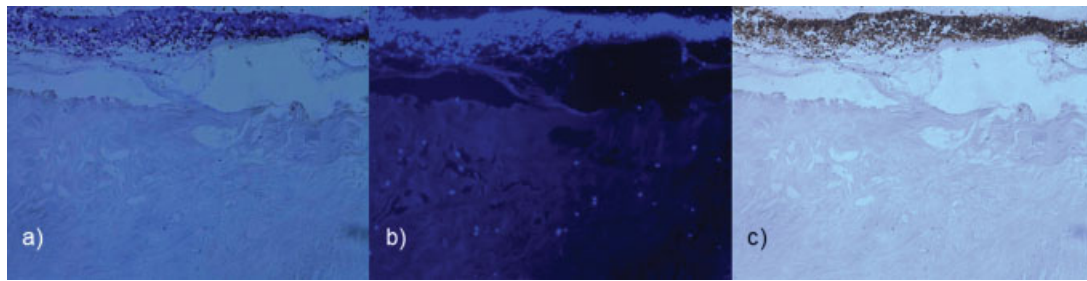


Fig. 3 Contiguous sections of meniscus explant at the PRF interface. The colocalization of leucocytes and fibrochondrocytes is analyzed using a manual subtraction technique. (a) DAPI stain (demonstrating cells in the PRF), (b) DAPI (demonstrating fibrochondrocytes in the explant), and (c) CD45⁺ staining cells (general hematopoietic cell marker, excluding platelets and erythrocytes). PRF, platelet-rich fibrin.

the explant relative to the simulated interface; cells were counted using a manual subtraction technique of CD-45 (general hematopoietic cell marker—excluding platelets and erythrocytes) and 4',6-diamidino-2-phenylindole-stained cells in the explants (►Fig. 3). Cell migration to the simulated interface was significantly increased in the PRF group at 28 days (►Fig. 4, $p < 0.05$ for $N = 6$).⁸⁹

Future Meniscal Repair Augmentation: Cells, Scaffolds, and Biologics

Regardless of the method of administration or physical form of the biologic, quantitative biological characterization of the repair process is significant to ensure impactful clinical translation. It is clear that PRP may vary significantly depending on processing.^{90,91} Recently, Howard et al⁹² suggested that differential PRP preparation techniques may result in different amounts of constituent growth factors from the same donor samples. In their study, the simple centrifuge protocol technique resulted in the highest IGF-1 release and the SmartPrep technique (Harvest Technologies Corp., Plymouth, MA) resulted in the highest levels of TGF- β 1 and PDGF-AB. This may hold potential to target differential

growth factor delivery (migratory, anabolic, and proliferative) using differential PRP preparation techniques applied to the healing meniscal interface.

As a final point of discussion, the combination of cells, biologic augmentation strategies, and scaffolds holds promise. However, introducing such complexity to meniscal repair preclinical studies at this point may confound interpretation given that respective contributions of PRP, cell types, and specific scaffolds types of meniscal healing remain poorly understood. In an attempt to relate the respective contributions of mesenchymal stem cells (MSCs), bone marrow aspirate, and leukocyte-rich PRP, Zellner et al used a hyaluronan-collagen matrix in the rabbit model in vitro and an in vivo 2-mm punch defect in the avascular zone with outcome measures out to 12 weeks.⁹³ Their study compared the aforementioned groups head-to-head without combination groups. In the PRP group they failed to find any significant advantage to adding leukocyte-rich PRP to the matrix. Interestingly, undifferentiated MSCs resulted in the best meniscal healing and this was superior to MSCs precultured in chondrogenic medium for 2 weeks. The emerging use of bone marrow aspirate in combination with a collagen matrix using an arthroscopic wrapping technique also holds promise to biologically augment meniscal repair.⁸⁴

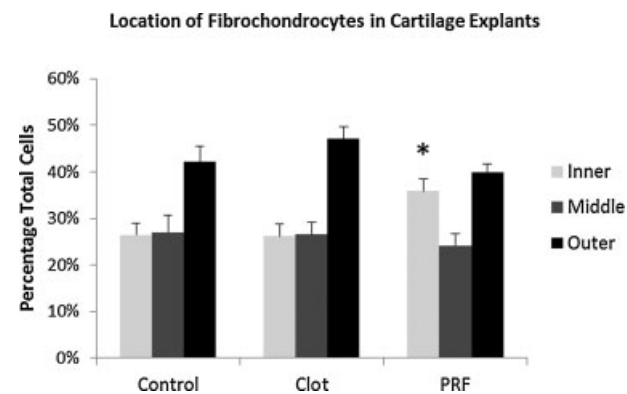


Fig. 4 Distribution of fibrochondrocytes in meniscal tissue explants exposed to a one-dimensional growth factor diffusion gradient using clot and PRF. The inner zone represents the interface with the biologic and the outer zone constitutes the open end of the tube and the point of media exposure. There were significantly more cells in the inner interfacial zone for the PRF group as compared with the clot and control groups. PRF, platelet-rich fibrin. * $p < 0.05$.

Conclusion

Overall, the use of biologics in ACL and meniscal surgery has demonstrated some clinical benefit and remains promising, but the existing data should be considered preliminary due to a lack of definitive evidence. At present, objective interpretation of existing clinical and preclinical evidence regarding the use of PRP in ACL and meniscal surgery fails to demonstrate a clear benefit. Perhaps the discrepancy between theoretical benefit and existing evidence may be accounted for by the fact that PRP, and related products, are not currently formulated to meet the specific requirements of a given tissue or biologic environment, although this trend is changing. For example, it seems extremely unlikely that the same preparation techniques (and composition) will be best suited to intra-articular administration to the acutely injured joint, bone tunnel osteointegration in ACL surgery, and meniscal healing at a tear interface. To move forward in this area, tailoring preparation techniques to targeted tissue effects within the joint in

ACL and meniscal surgery represents an optimized platform for further investigation. Whole joint assessment of intra-articular biological strategies will also be essential.

References

- Ionescu LC, Lee GC, Huang KL, Mauck RL. Growth factor supplementation improves native and engineered meniscus repair in vitro. *Acta Biomater* 2012;8(10):3687–3694
- Makris EA, Hadidi P, Athanasiou KA. The knee meniscus: structure-function, pathophysiology, current repair techniques, and prospects for regeneration. *Biomaterials* 2011;32(30):7411–7431
- McNulty AL, Guilak F. Integrative repair of the meniscus: lessons from in vitro studies. *Biorheology* 2008;45(3-4):487–500
- Bhargava MM, Attia ET, Murrell GA, Dolan MM, Warren RF, Hannafin JA. The effect of cytokines on the proliferation and migration of bovine meniscal cells. *Am J Sports Med* 1999;27(5):636–643
- Hutchinson ID, Moran CJ, Potter HG, Warren RF, Rodeo SA. Restoration of the Meniscus: Form and Function. *Am J Sports Med* 2014;42(4):987–998
- Molloy T, Wang Y, Murrell G. The roles of growth factors in tendon and ligament healing. *Sports Med* 2003;33(5):381–394
- Meaney Murray M, Rice K, Wright RJ, Spector M. The effect of selected growth factors on human anterior cruciate ligament cell interactions with a three-dimensional collagen-GAG scaffold. *J Orthop Res* 2003;21(2):238–244
- Rość D, Powierza W, Zastawna E, Drewniak W, Michalski A, Kotschy M. Post-traumatic plasminogenesis in intraarticular exudate in the knee joint. *Med Sci Monit* 2002;8(5):CR371–CR378
- Murray MM, Martin SD, Martin TL, Spector M. Histological changes in the human anterior cruciate ligament after rupture. *J Bone Joint Surg Am* 2000;82-A(10):1387–1397
- Spindler KP, Murray MM, Devin C, Nanney LB, Davidson JM. The central ACL defect as a model for failure of intra-articular healing. *J Orthop Res* 2006;24(3):401–406
- Murray MM, Spindler KP, Devin C, et al. Use of a collagen-platelet rich plasma scaffold to stimulate healing of a central defect in the canine ACL. *J Orthop Res* 2006;24(4):820–830
- Murray MM, Palmer M, Abreu E, Spindler KP, Zurakowski D, Fleming BC. Platelet-rich plasma alone is not sufficient to enhance suture repair of the ACL in skeletally immature animals: an in vivo study. *J Orthop Res* 2009;27(5):639–645
- Kroon ME, van Schie ML, van der Vecht B, van Hinsbergh VW, Koolwijk P. Collagen type 1 retards tube formation by human microvascular endothelial cells in a fibrin matrix. *Angiogenesis* 2002;5(4):257–265
- Steiner ME, Murray MM, Rodeo SA. Strategies to improve anterior cruciate ligament healing and graft placement. *Am J Sports Med* 2008;36(1):176–189
- Murray MM, Fleming BC. Use of a bioactive scaffold to stimulate anterior cruciate ligament healing also minimizes posttraumatic osteoarthritis after surgery. *Am J Sports Med* 2013;41(8):1762–1770
- Vavken P, Fleming BC, Mastrangelo AN, Machan JT, Murray MM. Biomechanical outcomes after bioenhanced anterior cruciate ligament repair and anterior cruciate ligament reconstruction are equal in a porcine model. *Arthroscopy* 2012;28(5):672–680
- Vavken P, Saad FA, Fleming BC, Murray MM. VEGF receptor mRNA expression by ACL fibroblasts is associated with functional healing of the ACL. *Knee Surg Sports Traumatol Arthrosc* 2011;19(10):1675–1682
- Choi BH, Zhu SJ, Kim BY, Huh JY, Lee SH, Jung JH. Effect of platelet-rich plasma (PRP) concentration on the viability and proliferation of alveolar bone cells: an in vitro study. *Int J Oral Maxillofac Surg* 2005;34(4):420–424
- Graziani F, Cei S, Ducci F, Giuca MR, Donos N, Gabriele M. In vitro effects of different concentration of PRP on primary bone and gingival cell lines. Preliminary results. *Minerva Stomatol* 2005;54(1-2):15–22
- Graziani F, Ivanovski S, Cei S, Ducci F, Tonetti M, Gabriele M. The in vitro effect of different PRP concentrations on osteoblasts and fibroblasts. *Clin Oral Implants Res* 2006;17(2):212–219
- Hsu CW, Yuan K, Tseng CC. The negative effect of platelet-rich plasma on the growth of human cells is associated with secreted thrombospondin-1. *Oral Surg Oral Med Oral Pathol Oral Radiol Endod* 2009;107(2):185–192
- Yoshida R, Cheng M, Murray MM. Increasing platelet concentration in platelet-rich plasma inhibits anterior cruciate ligament cell function in three-dimensional culture. *J Orthop Res* 2014;32(2):291–295
- Mastrangelo AN, Vavken P, Fleming BC, Harrison SL, Murray MM. Reduced platelet concentration does not harm PRP effectiveness for ACL repair in a porcine in vivo model. *J Orthop Res* 2011;29(7):1002–1007
- Cheng M, Wang H, Yoshida R, Murray MM. Platelets and plasma proteins are both required to stimulate collagen gene expression by anterior cruciate ligament cells in three-dimensional culture. *Tissue Eng Part A* 2010;16(5):1479–1489
- Murray MM, Magarian E, Zurakowski D, Fleming BC. Bone-to-bone fixation enhances functional healing of the porcine anterior cruciate ligament using a collagen-platelet composite. *Arthroscopy* 2010;26(9, Suppl):S49–S57
- Murray MM, Spindler KP, Ballard P, Welch TP, Zurakowski D, Nanney LB. Enhanced histologic repair in a central wound in the anterior cruciate ligament with a collagen-platelet-rich plasma scaffold. *J Orthop Res* 2007;25(8):1007–1017
- Murray MM, Spindler KP, Abreu E, et al. Collagen-platelet rich plasma hydrogel enhances primary repair of the porcine anterior cruciate ligament. *J Orthop Res* 2007;25(1):81–91
- Joshi SM, Mastrangelo AN, Magarian EM, Fleming BC, Murray MM. Collagen-platelet composite enhances biomechanical and histologic healing of the porcine anterior cruciate ligament. *Am J Sports Med* 2009;37(12):2401–2410
- Spindler KP, Murray MM, Carey JL, Zurakowski D, Fleming BC. The use of platelets to affect functional healing of an anterior cruciate ligament (ACL) autograft in a caprine ACL reconstruction model. *J Orthop Res* 2009;27(5):631–638
- Fleming BC, Spindler KP, Palmer MP, Magarian EM, Murray MM. Collagen-platelet composites improve the biomechanical properties of healing anterior cruciate ligament grafts in a porcine model. *Am J Sports Med* 2009;37(8):1554–1563
- Fleming BC, Proffen BL, Vavken P, Shalvoy MR, Machan JT, Murray MM. Increased platelet concentration does not improve functional graft healing in bio-enhanced ACL reconstruction. *Knee Surg Sports Traumatol Arthrosc* 2014
- Vavken P, Sadoghi P, Murray MM. The effect of platelet concentrates on graft maturation and graft-bone interface healing in anterior cruciate ligament reconstruction in human patients: a systematic review of controlled trials. *Arthroscopy* 2011;27(11):1573–1583
- Orrego M, Larrain C, Rosales J, et al. Effects of platelet concentrate and a bone plug on the healing of hamstring tendons in a bone tunnel. *Arthroscopy* 2008;24(12):1373–1380
- Sánchez M, Anitua E, Azofra J, Prado R, Muruzabal F, Andia I. Ligamentization of tendon grafts treated with an endogenous preparation rich in growth factors: gross morphology and histology. *Arthroscopy* 2010;26(4):470–480
- Radice F, Yáñez R, Gutiérrez V, Rosales J, Pinedo M, Coda S. Comparison of magnetic resonance imaging findings in anterior cruciate ligament grafts with and without autologous platelet-derived growth factors. *Arthroscopy* 2010;26(1):50–57
- Ventura A, Terzaghi C, Borgo E, Verdoia C, Gallazzi M, Failoni S. Use of growth factors in ACL surgery: Preliminary study. *J Orthop Traumatol* 2005;6:76–79

- 37 Vogrin M, Ruppreht M, Dinevski D, et al. Effects of a platelet gel on early graft revascularization after anterior cruciate ligament reconstruction: a prospective, randomized, double-blind, clinical trial. *Eur Surg Res* 2010;45(2):77–85
- 38 Figueroa D, Melean P, Calvo R, et al. Magnetic resonance imaging evaluation of the integration and maturation of semitendinosus-gracilis graft in anterior cruciate ligament reconstruction using autologous platelet concentrate. *Arthroscopy* 2010;26(10):1318–1325
- 39 Nin JR, Gasque GM, Azcárate AV, Beola JD, Gonzalez MH. Has platelet-rich plasma any role in anterior cruciate ligament allograft healing? *Arthroscopy* 2009;25(11):1206–1213
- 40 Silva A, Sampaio R. Anatomic ACL reconstruction: does the platelet-rich plasma accelerate tendon healing? *Knee Surg Sports Traumatol Arthrosc* 2009;17(6):676–682
- 41 Boswell SG, Cole BJ, Sundman EA, Karas V, Fortier LA. Platelet-rich plasma: a milieu of bioactive factors. *Arthroscopy* 2012;28(3):429–439
- 42 Bedi A, Kelly N, Baad M, et al. Dynamic contact mechanics of radial tears of the lateral meniscus: implications for treatment. *Arthroscopy* 2012;28(3):372–381
- 43 Bedi A, Kelly NH, Baad M, et al. Dynamic contact mechanics of the medial meniscus as a function of radial tear, repair, and partial meniscectomy. *J Bone Joint Surg Am* 2010;92(6):1398–1408
- 44 McDermott I. Meniscal tears, repairs and replacement: their relevance to osteoarthritis of the knee. *Br J Sports Med* 2011;45(4):292–297
- 45 Roos H, Laurén M, Adalberth T, Roos EM, Jonsson K, Lohmander LS. Knee osteoarthritis after meniscectomy: prevalence of radiographic changes after twenty-one years, compared with matched controls. *Arthritis Rheum* 1998;41(4):687–693
- 46 Arnoczky SP, Warren RF, Spivak JM. Meniscal repair using an exogenous fibrin clot. An experimental study in dogs. *J Bone Joint Surg Am* 1988;70(8):1209–1217
- 47 Kamimura T, Kimura M. Repair of horizontal meniscal cleavage tears with exogenous fibrin clots. *Knee Surg Sports Traumatol Arthrosc* 2011;19(7):1154–1157
- 48 Henning CE, Lynch MA, Yearout KM, Vequist SW, Stallbaumer RJ, Decker KA. Arthroscopic meniscal repair using an exogenous fibrin clot. *Clin Orthop Relat Res* 1990;(252):64–72
- 49 Henning CE, Yearout KM, Vequist SW, Stallbaumer RJ, Decker KA. Use of the fascia sheath coverage and exogenous fibrin clot in the treatment of complex meniscal tears. *Am J Sports Med* 1991;19(6):626–631
- 50 Clark CR, Ogden JA. Development of the menisci of the human knee joint. Morphological changes and their potential role in childhood meniscal injury. *J Bone Joint Surg Am* 1983;65(4):538–547
- 51 Noyes FR, Barber-Westin SD. Management of meniscus tears that extend into the avascular region. *Clin Sports Med* 2012;31(1):65–90
- 52 Maak TG, Fabricant PD, Wickiewicz TL. Indications for meniscus repair. *Clin Sports Med* 2012;31(1):1–14
- 53 Verdonk R, Verdonk P, Huyse W, Forsyth R, Heinrichs EL. Tissue ingrowth after implantation of a novel, biodegradable polyurethane scaffold for treatment of partial meniscal lesions. *Am J Sports Med* 2011;39(4):774–782
- 54 Ronga M, Grassi FA, Manelli A, Bulgheroni P. Tissue engineering techniques for the treatment of a complex knee injury. *Arthroscopy* 2006;22(5):e1–e3
- 55 Reguzzoni M, Manelli A, Ronga M, Raspanti M, Grassi FA. Histology and ultrastructure of a tissue-engineered collagen meniscus before and after implantation. *J Biomed Mater Res B Appl Biomater* 2005;74(2):808–816
- 56 Stone KR, Steadman JR, Rodkey WG, Li ST. Regeneration of meniscal cartilage with use of a collagen scaffold. Analysis of preliminary data. *J Bone Joint Surg Am* 1997;79(12):1770–1777
- 57 Son M, Levenston ME. Discrimination of meniscal cell phenotypes using gene expression profiles. *Eur Cell Mater* 2012;23:195–208
- 58 Croutze R, Jomha N, Uludag H, Adesida A. Matrix forming characteristics of inner and outer human meniscus cells on 3D collagen scaffolds under normal and low oxygen tensions. *BMC Musculoskelet Disord* 2013;14:353
- 59 Saliken DJ, Mulet-Sierra A, Jomha NM, Adesida AB. Decreased hypertrophic differentiation accompanies enhanced matrix formation in co-cultures of outer meniscus cells with bone marrow mesenchymal stromal cells. *Arthritis Res Ther* 2012;14(3):R153
- 60 Ishida K, Kuroda R, Miwa M, et al. The regenerative effects of platelet-rich plasma on meniscal cells in vitro and its in vivo application with biodegradable gelatin hydrogel. *Tissue Eng* 2007;13(5):1103–1112
- 61 Englund M, Guermazi A, Roemer FW, et al. Meniscal tear in knees without surgery and the development of radiographic osteoarthritis among middle-aged and elderly persons: The Multicenter Osteoarthritis Study. *Arthritis Rheum* 2009;60(3):831–839
- 62 Stein T, Mehling AP, Welsch F, von Eisenhart-Rothe R, Jäger A. Long-term outcome after arthroscopic meniscal repair versus arthroscopic partial meniscectomy for traumatic meniscal tears. *Am J Sports Med* 2010;38(8):1542–1548
- 63 Loeser RF, Goldring SR, Scanzello CR, Goldring MB. Osteoarthritis: a disease of the joint as an organ. *Arthritis Rheum* 2012;64(6):1697–1707
- 64 Filardo G, Kon E, Roffi A, Di Matteo B, Merli ML, Marcacci M. Platelet-rich plasma: why intra-articular? A systematic review of preclinical studies and clinical evidence on PRP for joint degeneration. *Knee Surg Sports Traumatol Arthrosc* 2013
- 65 Filardo G, Kon E, Buda R, et al. Platelet-rich plasma intra-articular knee injections for the treatment of degenerative cartilage lesions and osteoarthritis. *Knee Surg Sports Traumatol Arthrosc* 2011;19(4):528–535
- 66 Patel S, Dhillon MS, Aggarwal S, Marwaha N, Jain A. Treatment with platelet-rich plasma is more effective than placebo for knee osteoarthritis: a prospective, double-blind, randomized trial. *Am J Sports Med* 2013;41(2):356–364
- 67 Hsu WK, Mishra A, Rodeo SR, et al. Platelet-rich plasma in orthopaedic applications: evidence-based recommendations for treatment. *J Am Acad Orthop Surg* 2013;21(12):739–748
- 68 Lohmander LS, Dahlberg L, Ryd L, Heinegård D. Increased levels of proteoglycan fragments in knee joint fluid after injury. *Arthritis Rheum* 1989;32(11):1434–1442
- 69 Irie K, Uchiyama E, Iwaso H. Intraarticular inflammatory cytokines in acute anterior cruciate ligament injured knee. *Knee* 2003;10(1):93–96
- 70 LeGrand A, Fermor B, Fink C, et al. Interleukin-1, tumor necrosis factor alpha, and interleukin-17 synergistically up-regulate nitric oxide and prostaglandin E2 production in explants of human osteoarthritic knee menisci. *Arthritis Rheum* 2001;44(9):2078–2083
- 71 Shin SJ, Fermor B, Weinberg JB, Pisetsky DS, Guilak F. Regulation of matrix turnover in meniscal explants: role of mechanical stress, interleukin-1, and nitric oxide. *J Appl Physiol* (1985) 2003;95(1):308–313
- 72 Fermor B, Jeffcoat D, Hennerbichler A, Pisetsky DS, Weinberg JB, Guilak F. The effects of cyclic mechanical strain and tumor necrosis factor alpha on the response of cells of the meniscus. *Osteoarthritis Cartilage* 2004;12(12):956–962
- 73 Wilusz RE, Weinberg JB, Guilak F, McNulty AL. Inhibition of integrative repair of the meniscus following acute exposure to interleukin-1 in vitro. *J Orthop Res* 2008;26(4):504–512
- 74 McNulty AL, Moutos FT, Weinberg JB, Guilak F. Enhanced integrative repair of the porcine meniscus in vitro by inhibition of interleukin-1 or tumor necrosis factor alpha. *Arthritis Rheum* 2007;56(9):3033–3042
- 75 Andia I, Maffulli N. Platelet-rich plasma for managing pain and inflammation in osteoarthritis. *Nat Rev Rheumatol* 2013;9(12):721–730

- 76 Sundman EA, Cole BJ, Karas V, et al. The anti-inflammatory and matrix restorative mechanisms of platelet-rich plasma in osteoarthritis. *Am J Sports Med* 2014;42(1):35–41
- 77 Stone AV, Loeser RF, Vanderman KS, Long DL, Clark SC, Ferguson CM. Pro-inflammatory stimulation of meniscus cells increases production of matrix metalloproteinases and additional catabolic factors involved in osteoarthritis pathogenesis. *Osteoarthritis Cartilage* 2014;22(2):264–274
- 78 Welsing RT, van Tienen TG, Ramrattan N, et al. Effect on tissue differentiation and articular cartilage degradation of a polymer meniscus implant: A 2-year follow-up study in dogs. *Am J Sports Med* 2008;36(10):1978–1989
- 79 Klomp maker J, Veth RP, Jansen HW, Nielsen HK, de Groot JH, Pennings AJ. Meniscal replacement using a porous polymer prosthesis: a preliminary study in the dog. *Biomaterials* 1996;17(12):1169–1175
- 80 Fox DB, Warnock JJ. Cell-based meniscal tissue engineering: a case for synoviocytes. *Clin Orthop Relat Res* 2011;469(10):2806–2816
- 81 Lee CM, Kisiday JD, McIlwraith CW, Grodzinsky AJ, Frisbie DD. Synoviocytes protect cartilage from the effects of injury in vitro. *BMC Musculoskelet Disord* 2013;14:54
- 82 Braun HJ, Kim HJ, Chu CR, Dragoo JL. The effect of platelet-rich plasma formulations and blood products on human synoviocytes: implications for intra-articular injury and therapy. *Am J Sports Med* 2014;42(5):1204–1210
- 83 Zellner J, Hierl K, Mueller M, et al. Stem cell-based tissue-engineering for treatment of meniscal tears in the avascular zone. *J Biomed Mater Res B Appl Biomater* 2013;101(7):1133–1142
- 84 Piontek T, Ciemniowska-Gorzela K, Szulc A, Stomczykowski M, Jakob R. All-arthroscopic technique of biological meniscal tear therapy with collagen matrix. *Pol Orthop Traumatol* 2012;77:39–45
- 85 Monllau JC, Gelber PE, Abat F, et al. Outcome after partial medial meniscus substitution with the collagen meniscal implant at a minimum of 10 years' follow-up. *Arthroscopy* 2011;27(7):933–943
- 86 Visser LC, Arnoczky SP, Caballero O, Egerbacher M. Platelet-rich fibrin constructs elute higher concentrations of transforming growth factor- β 1 and increase tendon cell proliferation over time when compared to blood clots: a comparative in vitro analysis. *Vet Surg* 2010;39(7):811–817
- 87 Bielecki T, Dohan Ehrenfest DM. Leukocyte- and platelet-rich Plasma (L-PRP)/fibrin (L-PRF) in medicine - past, present, future. *Curr Pharm Biotechnol* 2012;13(7):i–ii
- 88 Zumstein MA, Rumian A, Lesbats V, Schaer M, Boileau P. Increased vascularization during early healing after biologic augmentation in repair of chronic rotator cuff tears using autologous leukocyte- and platelet-rich fibrin (L-PRF): a prospective randomized controlled pilot trial. *J Shoulder Elbow Surg* 2014;23(1):3–12
- 89 Frawley RJ, Hutchinson ID, Schar M, et al. Quantification of the chemotactic effects of platelet rich fibrin and blood clot in a novel one-dimensional explant diffusion model; simulating a meniscal interface in vitro. Paper presented at: 60th Annual Meeting of the Orthopaedic Research Society (ORS); March 15–18, 2014; New Orleans, LA
- 90 Castillo TN, Pouliot MA, Kim HJ, Dragoo JL. Comparison of growth factor and platelet concentration from commercial platelet-rich plasma separation systems. *Am J Sports Med* 2011;39(2):266–271
- 91 Weibrich G, Kleis WK, Streckbein P, Moergel M, Hitzler WE, Hafner G. Comparison of point-of-care methods for preparation of platelet concentrate (platelet-rich plasma). *Int J Oral Maxillofac Implants* 2012;27(4):762–769
- 92 Howard D, Shepherd JH, Kew SJ, et al. Release of growth factors from a reinforced collagen GAG matrix supplemented with platelet rich plasma: Influence on cultured human meniscal cells. *J Orthop Res* 2014;32(2):273–278
- 93 Zellner J, Mueller M, Berner A, et al. Role of mesenchymal stem cells in tissue engineering of meniscus. *J Biomed Mater Res A* 2010;94(4):1150–1161
- 94 Murray MM, Vavken P, Fleming BC. *The ACL Handbook*. New York: NY: Springer; 2013
- 95 Fleming BC, Magarian EM, Harrison SL, Paller DJ, Murray MM. Collagen scaffold supplementation does not improve the functional properties of the repaired anterior cruciate ligament. *J Orthop Res* 2010;28(6):703–709