

Retroperitoneal fibrosis with a complex cystic lesion mimicking an inferior vena cava tumor

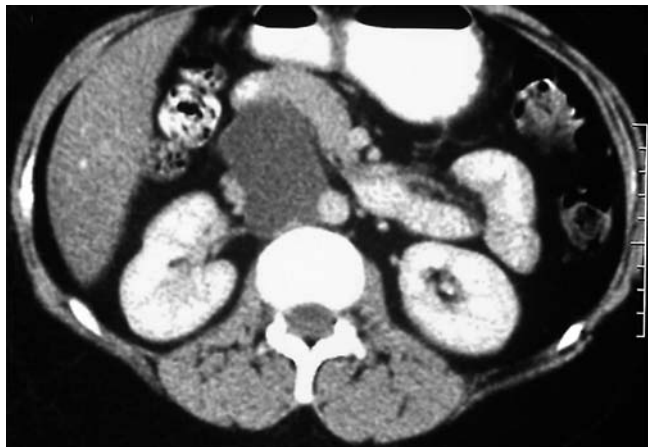

Fig. 1 A 32-year-old woman presented with a dull aching abdominal pain of 2 months duration. A computed tomography (CT) abdominal scan revealed a 4-cm cystic lesion near the head of the pancreas.

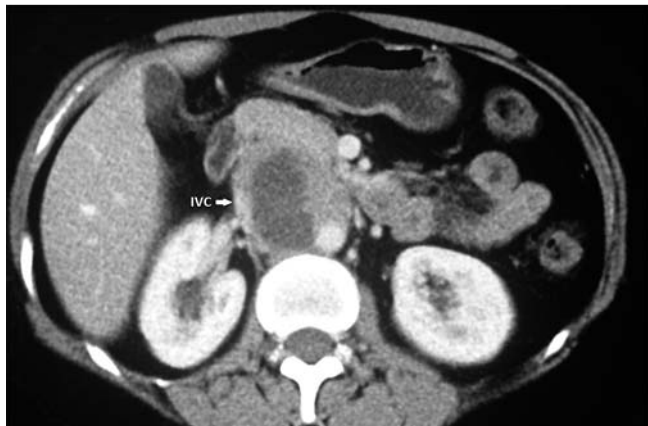

Fig. 2 A repeat contrast enhanced CT abdominal scan showed a complex thick-walled cystic lesion measuring ~5 cm in size, located near the head of the pancreas and invading the medial wall of the inferior vena cava (IVC).

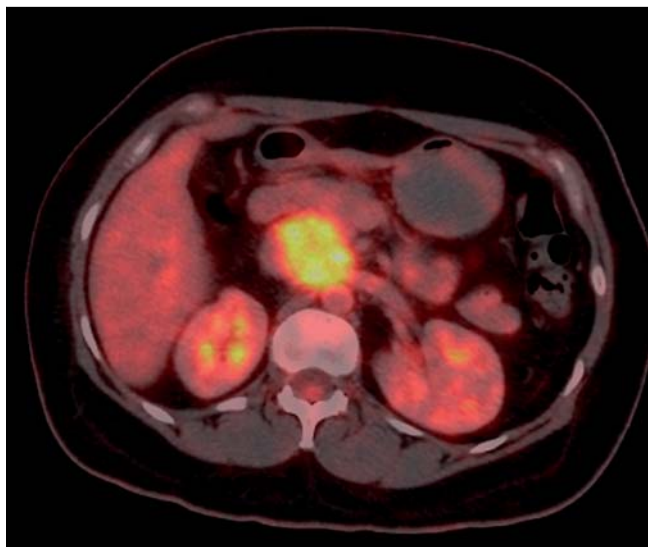


Fig. 3 Subsequent 18-fluorodeoxyglucose positron emission tomography revealed intense 18-fluorodeoxyglucose uptake in the lesion.

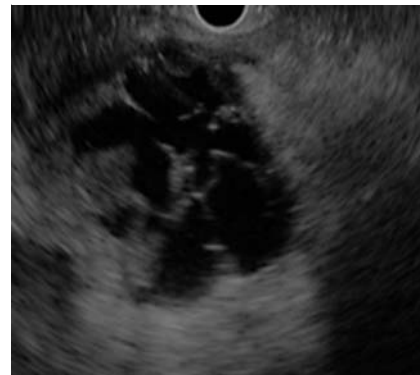

Fig. 4 Endoscopic ultrasound (EUS) revealed a 5-cm complex septated cystic lesion located near the head of the pancreas and abutting the inferior vena cava.

A 32-year-old woman presented with a dull aching abdominal pain of 2 months duration. She had similar complaints 18 months earlier and on evaluation, she was found to have a 4-cm cystic lesion near the head of the pancreas (● Fig. 1). A

repeat contrast enhanced computed tomography scan of the abdomen revealed a complex thick-walled cystic lesion measuring ~5 cm in size, located near the head of the pancreas and invading the medial wall of the inferior vena cava and

involving the left renal vein (● Fig. 2). Subsequent 18-fluorodeoxyglucose positron emission tomography showed intense uptake in the lesion with a maximum standardized uptake value of 9.0 (● Fig. 3). Endoscopic ultrasound (EUS) revealed a 5-cm complex septated cystic lesion in relation to the head of the pancreas abutting the inferior vena cava (● Fig. 4). EUS guided aspiration of the cyst revealed a serosanguinous fluid that was rich in lymphocytes and no malignant cells were seen. The cyst was completely emptied and fluid cancer antigen 19-9, carcinoembryonic antigen, and triglyceride were within normal limits, whereas fluid amylase and lipase were elevated. The patient underwent laparotomy and a 6-cm hard lesion arising from the infrahepatic inferior vena cava was observed. There was extensive desmoplastic reaction surrounding the lesion involving the aorta, and superior mesenteric artery. The lesion was removed and reconstruction of the inferior vena cava and left renal vein was performed using a polytetrafluoroethylene vascular graft. The biopsy from the resected specimen revealed a lymphoplasmacytic infiltrate with storiform fibrosis and obliterative phlebitis suggesting a diagnosis of idiopathic retroperitoneal fibrosis.

Retroperitoneal fibrosis is a rare entity characterized by nonspecific chronic inflammation of the retroperitoneum that can be caused by trauma, radiation or drugs such as methylsergide [1,2]. Treat-

ment is usually medical in the form of immunosuppression with or without surgical intervention depending upon the stage of the disease and the type of organ involved in the disease process [3]. Formation of a pseudocyst is an unusual complication of retroperitoneal fibrosis [4].

Endoscopy_UCTN_Code_CCL_1AF_2AG_3AB

Competing interests: None

Surinder Singh Rana¹, Vishal Sharma¹, Puneet Chhabra¹, Ravi Sharma¹, Rajesh Gupta², Bhagwant R. Mittal³, Deepak Kumar Bhasin¹

¹ Department of Gastroenterology, Post Graduate Institute of Medical Education and Research (PGIMER), Chandigarh, India

² Department of Surgery, Post Graduate Institute of Medical Education and Research (PGIMER), Chandigarh, India

³ Department of Nuclear Medicine, Post Graduate Institute of Medical Education and Research (PGIMER), Chandigarh, India

References

- 1 Liang B, Yin Z, Guo Q et al. Diagnosis and treatment of retroperitoneal fibrosis. *Exp Ther Med* 2013; 5: 1236–1238
- 2 Khosroshahi A, Carruthers MN, Stone JH et al. Rethinking Ormond's disease: "idiopathic" retroperitoneal fibrosis in the era of IgG4-related disease. *Medicine (Baltimore)* 2013; 92: 82–91

3 Swartz RD. Idiopathic retroperitoneal fibrosis: a review of the pathogenesis and approaches to treatment. *Am J Kidney Dis* 2009; 54: 546–553

4 Jansen I, Hendriksz TR, Vans Bommel EF. Pseudocyst formation in retroperitoneal fibrosis relapse. *Br J Radiol* 2010; 83: e111–e113

Bibliography

DOI <http://dx.doi.org/10.1055/s-0034-1390716>
Endoscopy 2015; 47: E26–E27
© Georg Thieme Verlag KG
Stuttgart · New York
ISSN 0013-726X

Corresponding author

Surinder Singh Rana, DM

Department of Gastroenterology
PGIMER
Chandigarh – 160 012
India
Fax: +91-172-2744401
drsurinderrana@yahoo.co.in