

Cold polypectomy for nonampullary duodenal adenoma

Cold polypectomy for colorectal polyps has been widely performed in Western countries and is now becoming widespread in Japan. Both cold forceps polypectomy (CFP) and cold snare polypectomy (CSP) are safe and efficient for colorectal polyps [1,2]. These procedures are excellent in regard to safety, in particular because electrocautery is not needed; thus, perforation or delayed bleeding rarely occurs [1,2]. However, there have been no reports of cold polypectomy for duodenal polyps.

A 70-year-old woman had a type Ila nonampullary duodenal lesion (4-mm diameter) in the second portion of the duodenum (Fig. 1 a). CFP planned with two bites of a jumbo forceps (Radial Jaw 4 Jumbo Biopsy Forceps; Boston Scientific,

Natick, Massachusetts, USA) was used to resect the lesion (Fig. 1 b). The pathological diagnosis was low grade adenoma. A 57-year-old man had a type I s nonampullary duodenal polyp (4-mm diameter) in the third portion of the duodenum. CSP with an oval snare (Profile Polypectomy Snare, 11 mm; Boston Scientific) was used to resect the lesion endoscopically en bloc without submucosal injection or electrocautery (Fig. 2 a, Fig. 2 b). The final pathological diagnosis was also low grade adenoma.

In both cases, the lesions were diagnosed as low grade adenoma before resection by magnifying endoscopy with narrow-band imaging [3]. The ulcers were closed after resection with endoscopic clips, and neither patient had a complication, such

as perforation or delayed bleeding. Both underwent upper gastrointestinal endoscopy 3 months after resection, which confirmed the morphological and pathological absence of residual tumor via biopsy findings (Fig. 1 c, Fig. 2 c).

To the best of our knowledge, this is the first report of cold polypectomy for duodenal lesions. Nonampullary duodenal adenomas/carcinomas are usually resected by endoscopic mucosal resection (EMR) or endoscopic submucosal dissection (ESD). However, when either EMR or ESD is performed for duodenal tumors, the risk for complications, such as perforation and delayed bleeding, is higher than when the procedure is performed for lesions in other parts of the digestive tract [4,5]. Cold polypectomy is exceptionally safe and may be effective treatment for nonampullary duodenal adenomas, especially smaller lesions.

Endoscopy_UCTN_Code_TTT_1AR_2AF

Competing interests: None

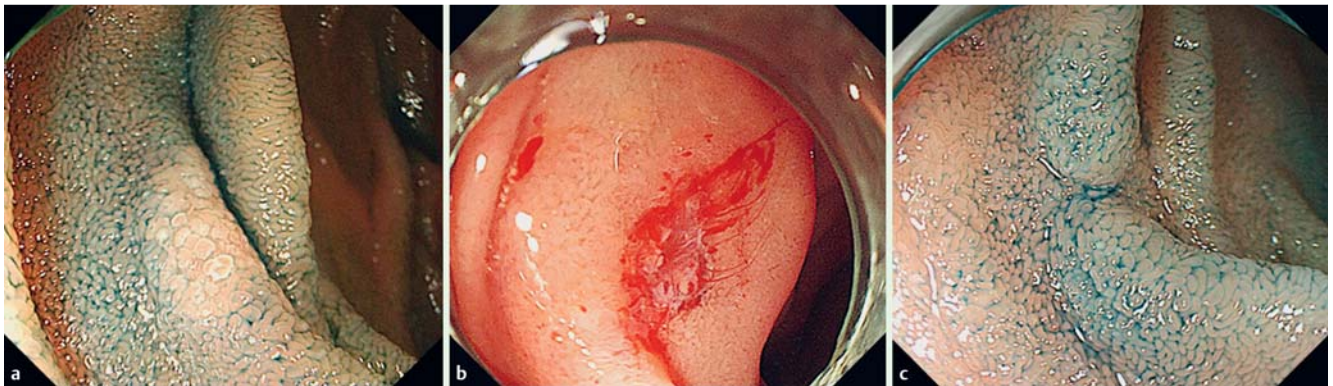


Fig. 1 Cold forceps polypectomy (CFP) for nonampullary duodenal adenoma. **a** Type Ila nonampullary duodenal polyp (4-mm diameter) in the second portion of the duodenum in a 70-year-old woman. CFP planned with two bites of a jumbo forceps was used to resect the lesion. **b** Following resection, the mucosa around the ulcer was easily assessed by submucosal infusion with a water jet to identify morphologically residual tumor. **c** No residual tumor was found in or around the scar 3 months after CFP.

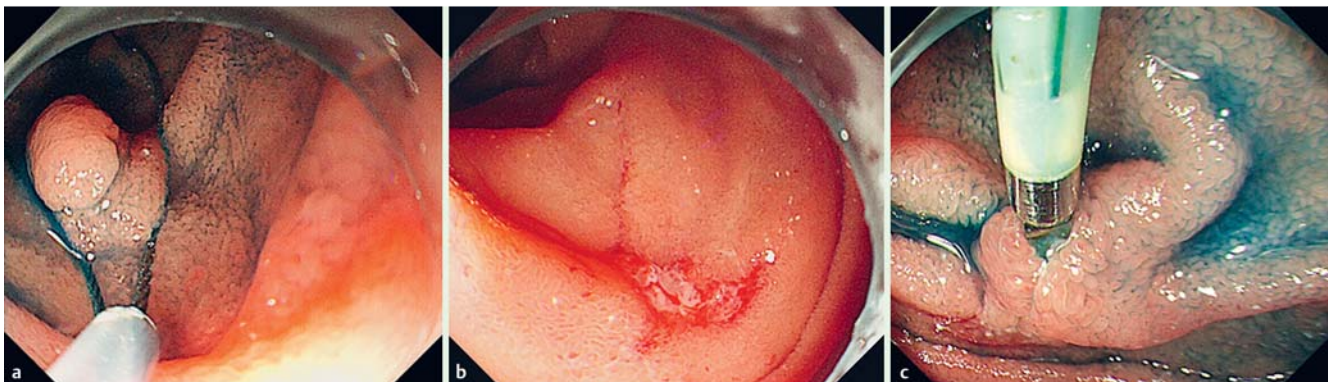


Fig. 2 Cold snare polypectomy (CSP) for type I s nonampullary duodenal polyp (4-mm diameter) in the third portion of the duodenum in a 57-year-old man. **a** The lesion was resected en bloc by CSP with an oval snare. **b** Following resection, the ulcer and surrounding mucosa were assessed with the application of water jet to the area. **c** No residual tumor was found 3 months after CSP, although there was mild inflammation caused by a retained endoscopic clip.

**Daisuke Maruoka^{1,2}, Makoto Arai¹,
Hideaki Ishigami¹, Kenichiro Okimoto¹,
Tomoaki Matsumura¹, Tomoo Nakagawa¹,
Osamu Yokosuka¹**

¹ Department of Gastroenterology and Nephrology, Graduate School of Medicine, Chiba University, Chiba, Japan

² Clinical Research Center, Chiba University Hospital, Chiba, Japan

References

- 1 Repici A, Hassan C, Vitetta E et al. Safety of cold polypectomy for <10mm polyps at colonoscopy: a prospective multicenter study. *Endoscopy* 2012; 44: 27–31
- 2 Ichise Y, Horiuchi A, Nakayama Y et al. Prospective randomized comparison of cold snare polypectomy and conventional polypectomy for small colorectal polyps. *Digestion* 2011; 84: 78–81
- 3 Maruoka D, Arai M, Matsumura T et al. Efficacy of magnifying endoscopy with narrow band imaging in the differential diagnosis of sporadic nonampullary duodenal adenoma and adenocarcinoma. *Endoscopy* 2012; 44 (Suppl. 01): A361
- 4 Ono H, Nonaka S, Uedo N et al. Clinical issues of duodenal EMR/ESD [in Japanese with English abstract]. *Stomach and Intestine (Tokyo)* 2011; 46: 1669–1677
- 5 Maruoka D, Arai M, Kishimoto T et al. Clinical outcomes of endoscopic resection for non-ampullary duodenal high-grade dysplasia and intramucosal carcinoma. *Endoscopy* 2013; 45: 138–141

Bibliography

DOI <http://dx.doi.org/10.1055/s-0034-1392668>
Endoscopy 2015; 47: E477–E478
© Georg Thieme Verlag KG
Stuttgart · New York
ISSN 0013-726X

Corresponding author

Makoto Arai, MD, PhD

Department of Gastroenterology and Nephrology
Graduate School of Medicine
Chiba University
Inohana 1-8-1
Chuo-Ku
Chiba City 260-8670
Japan
Fax: +81-43-226-2088
araim-cib@umin.ac.jp