

Transaortic endoscopic ultrasound-guided fine-needle aspiration of a positron emission tomography-positive abdominal para-aortic lymph node

Endoscopic ultrasound-guided fine-needle aspiration (EUS-FNA) is an important diagnostic tool for the evaluation of lesions affecting the gastrointestinal tract and adjacent organs [1]. Major vessels serve as procedural landmarks and provide an anechoic interface that allows the clear visualization of nodes/masses on the opposite side. Major vessels have for several decades been a target of interventional radiology; however, interposition of the aorta between the EUS probe and a target lesion has been considered a contraindication to EUS-FNA.

Since 2007, when it was first described [2], EUS-FNA traversing the thoracic aorta has been reported in a few cases [2–4], and recently, a case of EUS-FNA traversing the abdominal aorta has been reported [5]. This limited number of cases reflects a concern for complications, although none has been reported so far. We report herein an additional case, that of a 73-year-old man who had been treated for an intrahepatic biliary cystadenocarcinoma 5 years earlier.

EUS-FNA of a 27×22-mm positron emission tomography-positive lymph node was performed by traversing the abdominal aorta with multiple needle passes. The procedure was done with a therapeutic linear echoendoscope (GF-UCT140-AL5; Olympus Medical Systems Europe, Ham-

burg, Germany) while the patient was under conscious sedation.

Transduodenal endoscopic ultrasound (EUS) examination confirmed the presence of a 27×22-mm lymph node in the para-aortic region. The lymph node was visualized from the second part of the duodenum, and a window through which it could be punctured without traversing the aorta could not be found (● Fig. 1 a). Therefore, EUS-guided transaortic FNA with a 25-gauge needle (EchoTip Ultra; Cook Medical, Bloomington, Indiana, USA) was attempted (● Fig. 1 b).

The needle without the stylet was advanced through the aorta into the target lesion under real-time EUS guidance. Care was taken to avoid the intimal plaques that covered the entire abdominal segment of the aorta. After the needle tip had reached the target lesion, negative-pressure suction was applied, and to-and-fro movements of the needle were made inside the lesion. After the needle had been retracted, no ultrasonographic signs of overt bleeding, oozing from the aortic wall, or other complications were observed. Therefore, two additional needle passes were performed to increase the diagnostic yield. Three needle passes were needed because rapid on-site cytopathological evaluation was not available (● Video 1).

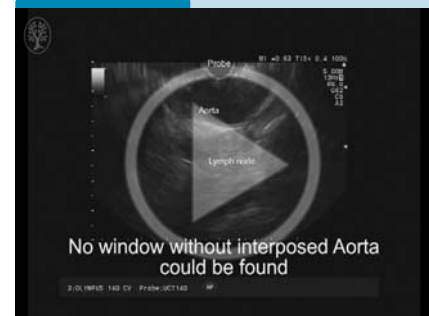
The collected specimens were placed into a preservative solution (ThinPrep technique and Cytolyt solution; Cytoc Corporation, Boxborough, Massachusetts, USA) for later evaluation and staining. The patient was discharged on the day after the procedure without evidence of any complications.

Cytological examination showed atypical cells, suggestive of a lymphoproliferative disorder. The lymph node was removed laparoscopically, and further examination indicated a follicular non-Hodgkin lymphoma.

Endoscopy_UCTN_Code_TTT_1AS_2AC

Competing interests: Dr. Larghi is a consultant for Cook Medical and Boston Scientific. The other authors have no conflicts of interest to disclose.

Video 1



Endoscopic ultrasound-guided fine needle aspiration (EUS-FNA) of a 27×22-mm positron emission tomography-positive lymph node was performed by traversing the abdominal aorta with multiple needle passes.

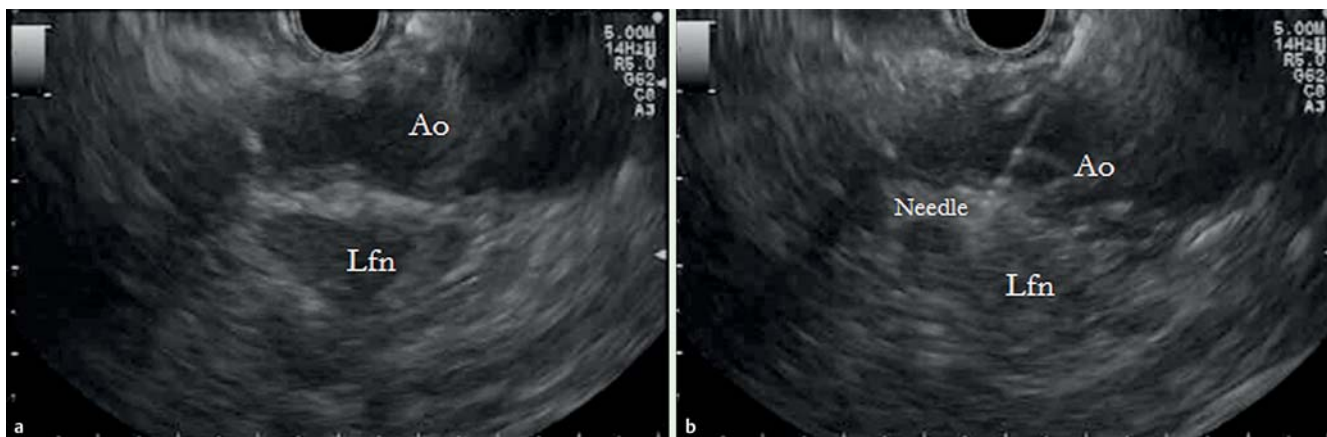


Fig. 1 a Endoscopic ultrasound (EUS) imaging of a positron emission tomography-positive lymph node and the interposed aorta in a 73-year-old man previously treated for intrahepatic biliary cystadenocarcinoma. Ao, aorta; Lfn, lymph node. b EUS-guided fine-needle aspiration of the target lymph node with passage of a 25-gauge needle through the aorta. Ao, aorta; Lfn, lymph node.

**Domenico Galasso¹, Mihai Rimbaş²,
Fabia Attili¹, Filippo Lococo³,
Alberto Larghi¹**

¹ Digestive Endoscopy Unit, Catholic University, Rome, Italy

² Gastroenterology Department, Colentina Clinical Hospital, Bucharest, Romania

³ Unit of Thoracic Surgery, IRCCS-Arcispedale Santa Maria Nuova, Reggio Emilia, Italy

References

- 1 *Dumonceau JM, Polkowski M, Larghi A et al.* Indications, results, and clinical impact of endoscopic ultrasound (EUS)-guided sampling in gastroenterology: European Society of Gastrointestinal Endoscopy (ESGE) Clinical Guideline. *Endoscopy* 2011; 43: 897–912
- 2 *Wallace MB, Woodward TA, Raimondo M et al.* Transaortic fine-needle aspiration of centrally located lung cancer under endoscopic ultrasound guidance: the final frontier. *Ann Thorac Surg* 2007; 84: 1019–1021
- 3 *von Bartheld MB, Rabe KF, Annema JT.* Transaortic EUS-guided FNA in the diagnosis of lung tumors and lymph nodes. *Gastrointest Endosc* 2009; 69: 345–349
- 4 *Bang JY, Varadarajulu S.* Diagnosis of a metastatic neuroendocrine tumor of the pancreas by transaortic endoscopic ultrasound-guided fine-needle aspiration. *Am Surg* 2012; 78: E183–E184
- 5 *Lee NK, Park S, Park S et al.* EUS-guided trans-aortic fine-needle aspiration for intra-abdominal plasmacytoma in a patient with multiple myeloma. *Gastrointest Endosc* 2015; 81: 1479–1780

Bibliography

DOI <http://dx.doi.org/10.1055/s-0034-1393149>
Endoscopy 2015; 47: E536–E537
© Georg Thieme Verlag KG
Stuttgart · New York
ISSN 0013-726X

Corresponding author

Alberto Larghi, MD, PhD
Digestive Endoscopy Unit
Catholic University
Largo F. Vito 1, 00168
Rome
Italy
Fax: +39-6-3015-6581
alberto.larghi@yahoo.it