

Fluoroless endoscopic ultrasound-guided biliary drainage after failed ERCP with a novel lumen-apposing metal stent mounted on a cautery-tipped delivery system

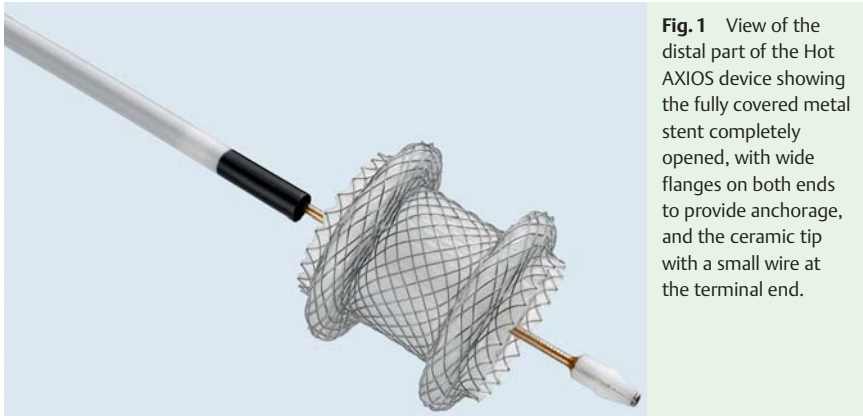


Fig. 1 View of the distal part of the Hot AXIOS device showing the fully covered metal stent completely opened, with wide flanges on both ends to provide anchorage, and the ceramic tip with a small wire at the terminal end.

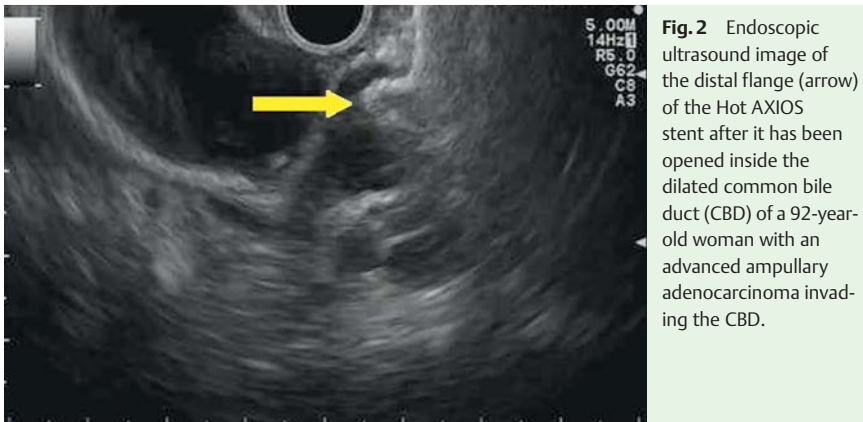


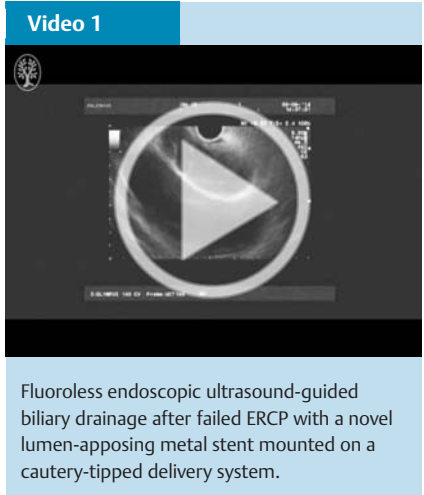
Fig. 2 Endoscopic ultrasound image of the distal flange (arrow) of the Hot AXIOS stent after it has been opened inside the dilated common bile duct (CBD) of a 92-year-old woman with an advanced ampullary adenocarcinoma invading the CBD.

Endoscopic ultrasound (EUS)-guided biliary drainage in patients in whom endoscopic retrograde cholangiopancreatography (ERCP) has failed is rapidly gaining acceptance as a valid alternative to percutaneous drainage [1]. In the last few years, fully covered self-expandable metal stents specifically designed for EUS transmural drainage procedures have become available [2,3]. Recently, one of these stents has been incorporated into an electrocautery-enhanced delivery system (Hot AXIOS; Boston Scientific, Natick, Massachusetts, USA) [4,5] (► Fig. 1), allowing the procedure, from puncturing to delivery of the stent, to be performed in one step.

We present the case of a 92-year-old woman with an advanced ampullary ade-

nocarcinoma invading the common bile duct (CBD). ERCP had failed in this patient because of an inability to cannulate the duct. She consented to undergo EUS-guided biliary drainage.

The dilated CBD (17 mm) was visualized from the duodenal bulb. A Hot AXIOS device with a stent 8 mm long and 8 mm wide was advanced outside the working channel to obtain full contact with the duodenal wall. Current with pure cut was then applied, allowing the device to enter the CBD. Once fully inside the CBD, the distal flange was opened under EUS guidance (► Fig. 2, ► Video 1). Subsequently, the flange was retracted toward the EUS transducer under ultrasound guidance, and once a change in its shape from flat to oval had been noted, the proximal



Fluoroless endoscopic ultrasound-guided biliary drainage after failed ERCP with a novel lumen-apposing metal stent mounted on a cautery-tipped delivery system.

flange was released. Good drainage of bile was observed at the end of the procedure (► Video 1). No complications occurred, and the stent remained completely patent until the patient died 4 months later.

This case shows the possibility of accomplishing EUS-guided biliary drainage in a one-step procedure with the Hot AXIOS device, which allows performance of the procedure completely under EUS guidance, without fluoroscopy. This eliminates the need for accessories exchange, theoretically decreasing the risk for complications, in particular bile leak.

Endoscopy_UCTN_Code_CPL_1AN_2AD

Competing interests: Alberto Larghi is a consultant for Boston Scientific Corp., Natick, Massachusetts, USA. The other authors have no relevant competing interests to declare.

Fabia Attili¹, Mihai Rimbaş^{1,2}, Domenico Galasso¹, Alberto Larghi¹

¹ Digestive Endoscopy Unit, Catholic University, Rome, Italy

² Colentina Clinical Hospital, Bucharest, Romania

References

- 1 *Fuccio L, Attili F, Vanella G* et al. Interventional endoscopic ultrasonography. *Curr Treat Options Gastroenterol* 2014; 12: 183–210
- 2 *Itoi T, Binmoeller KF, Shah J* et al. Clinical evaluation of a novel lumen-apposing metal stent for endosonography-guided pancreatic pseudocyst and gallbladder drainage (with videos). *Gastrointest Endosc* 2012; 75: 870–876
- 3 *Song TJ, Lee SS, Park do H* et al. Preliminary report on a new hybrid metal stent for EUS-guided biliary drainage (with videos). *Gastrointest Endosc* 2014; 80: 707–711
- 4 *Teoh AY, Binmoeller KF, Lau JY*. Single-step EUS-guided puncture and delivery of a lumen-apposing stent for gallbladder drainage using a novel cautery-tipped stent delivery system. *Gastrointest Endosc* 2014; 80: 1171
- 5 *Galasso D, Baron TH, Attili F* et al. Endoscopic ultrasound-guided drainage and necrosectomy of walled-off pancreatic necrosis using a metal stent with an electrocautery-enhanced delivery system and hydrogen peroxide. *Endoscopy* 2015; 47 (Suppl. 01) UCTN: E68

Bibliography

DOI <http://dx.doi.org/10.1055/s-0034-1393669>
Endoscopy 2015; 47: E619–E620
© Georg Thieme Verlag KG
Stuttgart · New York
ISSN 0013-726X

Corresponding author

Alberto Larghi, MD, PhD
Digestive Endoscopy Unit
Catholic University
Largo A. Gemelli 8
00168 Rome
Italy
Fax: +39-06-30156581
alberto.larghi@yahoo.it