

C-Arm Cone-Beam CT Combined with a New Electromagnetic Navigation System for Guidance of Percutaneous Needle Biopsies: Initial Clinical Experience

C-Bogen Flachdetektor-CT in Kombination mit einem neuartigen elektromagnetischen Navigationssystem bei der Steuerung perkutaner Biopsien: Erste klinische Erfahrungen

Authors

R. Kickuth, C. Reichling, T. Bley, D. Hahn, C. Ritter

Affiliation

Institute of Diagnostic and Interventional Radiology, University Hospital of Würzburg, Würzburg, Germany

Key words

- biopsy
- abdomen
- thorax
- interventional procedures

Zusammenfassung



Ziel: Evaluation der Durchführbarkeit und Effizienz der Kombination aus C-Arm Flachdetektor-CT (FD-CT) und elektromagnetischer Navigation (EMN) bei der Steuerung perkutaner Nadelbiopsien.

Material und Methoden: Insgesamt wurden 53 Patienten wegen thorakaler (n=19) und abdominalen (n=34) Läsionen zugewiesen. Mithilfe einer mit FD-CT ausgerüsteten Angiografieanlage wurden dreidimensionale CT-artige Schnittbilder der anatomischen Region-of-Interest generiert. Diese Bilder wurden auf ein EMN-System transferiert. Eine koaxiale, mit einem Sensor versehene Punktionsnadel wurde mit dem EMN-System verbunden und in ein elektromagnetisches Wechselfeld, welches zuvor durch einen Feldgenerator erzeugt wurde, eingebracht. Die innerhalb dieses Feldes erzeugten Daten wurden mit den FD-CT-Bildern fusioniert. Auf einem Monitor wurden dann die anatomische Region-of-Interest und die Nadelposition angezeigt, sodass eine präzise Nadelinsertion in Richtung Zielläsion möglich war. Durch die Koaxialnadel wurden Zylinder für die histologische Untersuchung gewonnen. Erfasst wurden die Anzahl an Stanzbiopsaten/Patient, die Gesamtprozedurzeit, das Dosisflächenprodukt, die Fluoroskopiezeit und die Komplikationen.

Ergebnisse: 53 FD-CT-/EMN-gesteuerte Biopsien wurden durchgeführt, von denen 48 (91%) repräsentative Gewebeproben ergaben. Vier Stanzbiopsate wurden von jedem Patienten gewonnen. 40 (75%) Läsionen waren maligne und 13 (25%) Läsionen benigne. Die Gesamtprozedurzeit betrug 9 min ± 5 min (Spannweite, 3–23 min), die Gesamtfluoroskopiezeit lag bei 0,8 min ± 0,4 min (Spannweite, 0,4–2 min). Das Flächendosisprodukt (cGy cm²) betrug im Mittel 7373 (Spannweite, 895–26904). Die Gesamtrate an Komplikationen (1 Pneumothorax, 2 Hämoptysen) lag bei 6%.

Abstract



Purpose: To evaluate the feasibility and efficacy of C-arm fluoroscopic cone-beam computed tomography (CACT) in combination with a new electromagnetic tracking (EMT) system for needle guidance during percutaneous biopsies.

Materials and Methods: 53 patients were referred for biopsy of thoracic (n=19) and abdominal (n=34) lesions. CT-like images of the anatomical region of interest (ROI) were generated using a flat panel-based angiographic system. These images were transmitted to an EMT system. A coaxial puncture needle with a sensor in its tip was connected with the navigation system and tracked into an electromagnetic field created via a field generator. Data generated within this field were merged with the CACT images. On a monitor both the anatomical ROI and needle tip position were displayed to enable precise needle insertion into the target. Through the coaxial needle, biopsy specimens for the histologic evaluation were extracted. Number of representative biopsy samples, number of core biopsies/patient, total procedure time, dose-area product, fluoroscopic time, and complications were recorded.

Results: 53 CACT/EMT-guided biopsy procedures were performed, 48 of which (91%) yielded representative tissue samples. Four core biopsies were obtained from each patient. 40 (75%) lesions were malignant and 13 (25%) lesions were benign. The total procedure time was 9 ± 5 min (range, 3–23 min), fluoroscopic time was 0.8 ± 0.4 min (range, 0.4–2 min). The mean dose-area product (cGy cm²) was 7373 (range, 895–26904). The rate of complications (1 pneumothorax, 2 hemoptyses) was 6%.

Conclusion: CACT combined with EMT appears to be a feasible and effective technique for the guidance of percutaneous biopsies with a low rate of therapeutically relevant complications.

received 15.7.2014

accepted 13.2.2015

Bibliography

DOI <http://dx.doi.org/10.1055/s-0034-1399313>
 Published online: 2015
 Fortschr Röntgenstr 2015; 187: 569–576 © Georg Thieme Verlag KG Stuttgart · New York · ISSN 1438-9029

Correspondence

Prof. Dr. Ralph Kickuth
 Institute of Diagnostic and Interventional Radiology,
 University Hospital of Würzburg
 Oberdürrbacher Straße 6
 97080 Würzburg
 Germany
 Tel.: ++49/931/20 13 49 57
 Fax: ++49/931/201 63 40 01
 Kickuth_R@ukw.de

Schlussfolgerung: Die Kombination aus FD-CT und EMN ist eine durchführbare und effektive Technik für die Steuerung perkutaner Biopsien mit einer niedrigen Rate an therapeutisch relevanten Komplikationen.

Kernaussagen:

- ▶ Die Steuerung perkutaner Biopsien mit einer Kombination aus FD-CT und EMN ist technisch durchführbar.
- ▶ FD-CT-/EMN-gesteuerte Biopsien sind mit einer guten diagnostischen Ausbeute verbunden.
- ▶ Die Rate an Komplikationen für diese Steuerungstechnik scheint niedrig zu sein.

Key Points:

- ▶ Guidance of percutaneous biopsies with a combination of CACT and EMT is technically feasible.
- ▶ CACT/EMT-guided biopsies are associated with a good diagnostic yield.
- ▶ The rate of complications appears to be low for this guidance technique.

Citation Format:

- ▶ Kickuth R., Reichling C., Bley T. et al. C-Arm Cone-Beam CT Combined with a New Electromagnetic Navigation System for Guidance of Percutaneous Needle Biopsies: Initial Clinical Experience. *Fortschr Röntgenstr* 2015; 187: 569–576

Introduction

Since the pioneering study of *Haaga* and *Alfidi* [1], who initially described computed tomography (CT) as an interventional guidance tool in 1976, CT has become an accepted and effective method for assisting percutaneous biopsies [2–6].

CT offers high spatial resolution, good image contrast, a wide field of view, good reproducibility and applicability to bony and air-filled structures. Conventional CT with an intermittent control mode as well as fluoroscopic CT with a real-time mode play an important role especially in thoracic and abdomino-pelvic biopsy approaches which cannot be adequately guided by fluoroscopy or ultrasonography [7–14].

With the development of C-arm fluoroscopic cone-beam computed tomography (CACT), an additional guidance tool in the interventional armamentarium has become available with increasing acceptance in radiology [15–17]. In general, CACT provides the capability to generate CT-like cross-sectional images using a state-of-the-art flat-panel detector C-arm angiographic system [15]. However, C-arm cone-beam CT images provide restricted image quality in terms of contrast resolution [15–19]. An approach to improve the accuracy of tumor targeting despite lower image quality may be the coupling of C-arm cone-beam CT with an electromagnetic navigation system in the guidance of biopsies [20].

To date, only a few studies addressing the role of C-arm cone-beam CT-based electromagnetic tracking (EMT) of percutaneous biopsies have been published, and this guiding technique seems to be relatively new to the field of interventional radiology [17, 20]. Preliminary work describing the clinical efficacy of cone-beam CT coupled with electromagnetic navigation in biopsy procedures has been reported [20]. The outcome of these procedures has been reported in a small case series of patients with target lesions not sensitive for respiratory motion.

Consequently, the purpose of this study was to evaluate cone-beam CT-based electromagnetic navigation of biopsy procedures in a larger series of patients with special focus on target lesions in greater part potentially influenced by respiratory misregistration.

Materials and Methods

Study Sample

53 patients (22 women, 31 men; mean age, 62 years ± 15; age range, 26–83 years) were referred to cone-beam CT-based electromagnetic navigation of biopsy procedures. All patients had an indication for percutaneous CT-guided needle biopsy which had

been approved by an interventional radiologist. All patients had received contrast-enhanced CT imaging prior to the intervention. All interventions were performed by two board-certified interventional radiologists. Patients were selected on an intent-to-treat basis defined just before initiation of the biopsy approach. Exclusion criteria were pulmonary nodules smaller than 10 mm in greatest diameter, ascites, pacemaker patients, thrombocytopenia, elevated prothrombin time (> 13.5 s), or increased international normalized ratio (> 1.3). All patients were examined and treated as part of routine care and gave informed consent prior to the intervention. The local institutional review board waived its approval.

CACT/EMT -Guided Biopsy Procedures

All biopsy procedures were carried out in the angiography suite equipped with a state-of-the-art flat-panel detector C-arm angiographic system (Axiom Artis, Siemens AG, Healthcare Sector, Forchheim, Germany) including dedicated software for the acquisition of cross-sectional cone-beam CT-like images (DynaCT, Siemens AG, Healthcare Sector, Forchheim, Germany). The C-arm angiographic system was coupled with a sophisticated EMT system (iGuide CAPP, CAS innovations GmbH, Erlangen, Germany). Biopsy mode for cone-beam CT parameters were: tube potential 90 kVp, body-weight adapted tube current setting ranging from 160 to 465 mA, standardized system dose 0.36 µGy per pulse, C-arm rotation time 8 s, total projection angle 240°, and 0.5° projection increment. CACT raw data were acquired without zoom, 480 mm field of view, 185 mm cylindrical volume coverage in craniocaudal orientation, 225 mm sagittal and transverse orientation. Using 2 × 2 binning, the in-plane spatial resolution was 0.46 mm². After raw data acquisition, data were transferred to a dedicated workstation (syngo Workplace, Siemens AG, Healthcare Sector, Forchheim, Germany) for multiplanar reformats with an isovolumetric voxel size of 0.4 mm³. The slice thickness of those multiplanar reformats ranged between 10 and 20 mm. CACT/EMT-guided thoracic or abdominal biopsy procedures were conducted as follows: Patients were positioned in a prone or supine position to ensure the most direct access. Prior to the procedure an oval reference frame and an additional motion sensor both connected with the EMT system were fixed in close proximity to the region of interest on the skin of the patients. Five radiopaque markers and an electromagnetic sensor with weak current were integrated within the reference frame.

Short-time fluoroscopy was used to ensure that the area of interest was placed in the isocenter and the reference frame within the area of interest. All procedures started with a CACT acquisition of the region of interest. During CACT acquisition contrast media was not used, since all patients had undergone prior con-

trast-enhanced CT for correlation imaging in terms of lesion detection. Thereafter, the C-arm was moved away from the patient and an electromagnetic field generator (Aurora, Northern Digital, Waterloo, ON, Canada), connected to the EMT system, was pivoted to the area of interest. As a next step the length of the needle path (distance between skin surface and center of the lesion) was measured on the cathode-ray tube monitor of the imager.

CACT images were transferred to the EMT system providing a resolution of 1280×1024 pixels. Due to the spatial relation of the electromagnetic sensor to the radiopaque markers within the reference frame, an automatic allocation of imaging space and electromagnetic space was conducted.

All biopsy procedures were performed under sterile conditions. Local anesthesia consisted of subcutaneous injection of 1% mepivacaine. A coil-integrated coaxial tracking needle (11- to 18-gauge, needle length between 50 and 150 mm; Amedo, Bochum, Germany) with an introducer stylet was steered into the electromagnetic space. The size of the selected coaxial tracking needle strongly depended on the aimed target tissue and the restricted assortment provided by the manufacturer. The current induced into the tracking needle coil was usually low and depended on its location and direction. By gentle manipulation of the tracking needle, electromagnetic data and CACT imaging data were merged to a real-time image displaying the anatomic region of interest as well as a virtual needle on the monitor (• Fig. 1). Thus, precise needle insertion into the target lesion was possible. The initial puncture was conducted without penetrating the pleura or peritoneum. If the coil-integrated coaxial tracking needle had not been maneuvered within the correct course, the needle track or puncture site was changed. Each approach was considered to be successful whenever the needle had been accurately visualized within the target lesion (• Fig. 2–5). We usually aimed for the periphery of a lesion in order to avoid necrosis. The needle end position was verified by the virtual fusion image alone. In general, CACT acquisitions for thoracic and upper abdominal biopsy procedures were obtained in end-inspiration

technique. This technique was used to avoid inadvertent puncture of critical anatomical or non-target structures with better patient compliance in comparison to end-expiration breath holding.

All tissue biopsies were completed with a detachable, 16- or 20-gauge cutting needle biopsy system (Angiotech, Gainesville, FL, USA) consisting of an outer coaxial cutting needle around a central notched stylet (length of the specimen notches measuring 10 or 20 mm). The needle length ranged from 100 to 200 mm. The central notched detachable stylet allowed withdrawal of a core biopsy specimen while leaving the cutting needle in place. After removal of the introducer stylet from the coaxial tracking needle, the cutting needle was positioned and the biopsy system was released. No on-site cytopathologist was present during the procedures. The tissue core biopsies were defined as being suitable for histopathological examination if a solid cylinder with a length of at least 6 to 10 mm was obtained. The tissue core biopsies were fixed in a formalin solution for histopathological examination. CACT/EMT-guided biopsies were defined as successful if representative tissue for a definitive histopathological diagnosis was obtained and agreed with the final diagnosis. Referring to this, all malignant diagnoses were categorized as representative. Benign diagnoses were classified as representative if a benign neoplasm or specific infection was diagnosed and as non-representative if the biopsy sample yielded nonspecific benign changes (e.g. inflammation, inflammatory epiphenomena, or fragments of fibrosis). Non-diagnostic specimens (e.g. samples showing scanty tissue, skeletal muscle cells, or blood) were also considered as non-representative. All non-representative tissue samples were verified by repeated CT-guided percutaneous biopsy procedures, surgical biopsy or 6 to 12-week follow-up CT examinations.

After each thoracic biopsy procedure, single-shot C-arm fluoroscopic controls were performed to evaluate the presence of complications. After abdominal CACT/EMT-guided biopsies, ultrasound controls were conducted on-site. An additional MSCT

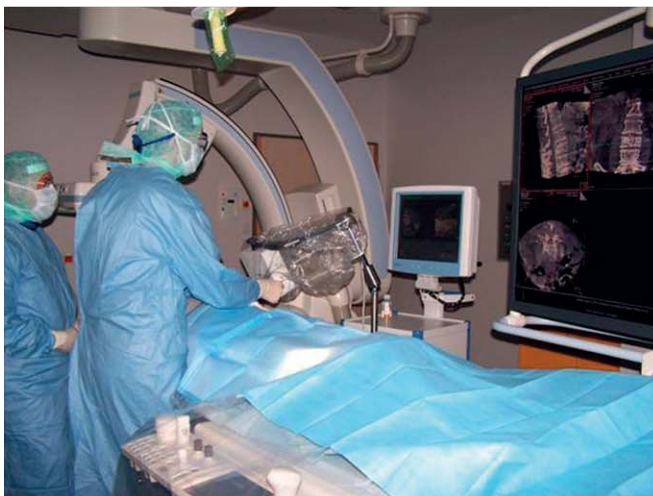

Fig. 1 Situation during a CACT/EMT-guided biopsy maneuver after CACT acquisition. Left image: Under sterile conditions the coaxial tracking needle is steered within the electromagnetic space and a merged CACT/EMT image is displayed on a separate monitor so that accurate needle insertion into the target lesion is possible. Right image: Note manipulation of the tracking needle in close proximity to the fixed field generator creating the electromagnetic space.

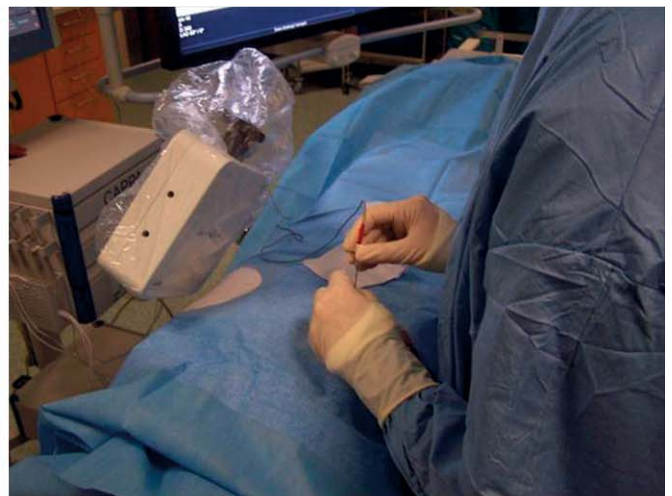

Abb. 1 Situation während einer FD-CT-/EMN-gesteuerten Biopsie nach FD-CT-Akquisition. Linkes Bild: Unter sterilen Bedingungen wird die koaxiale Führungsnadel innerhalb des elektromagnetischen Wechselfeldes gesteuert, und ein fusioniertes FD-CT-/EMN-Bild wird auf einem separaten Monitor wiedergegeben, sodass eine präzise Nadelinsertion in die Zielläsion möglich ist. Rechtes Bild: Die Manipulation der Führungsnadel in unmittelbarer Nähe zum fest installierten Feldgenerator erzeugt das elektromagnetische Wechselfeld.

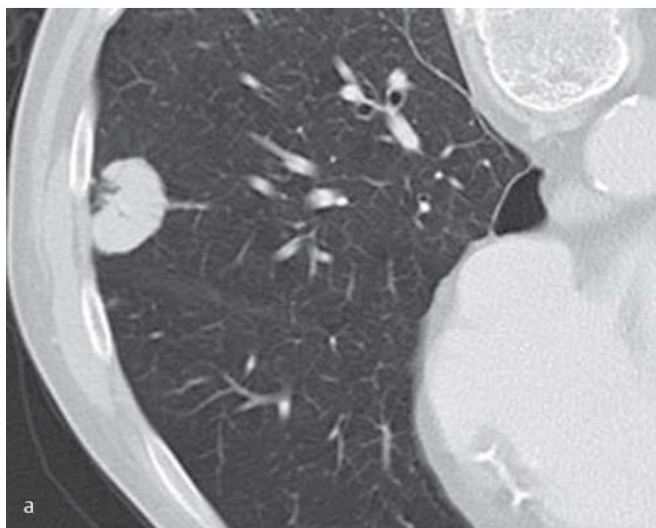


Fig. 2 CACT/EMT-assisted biopsy of a subpleural pulmonary nodule in segment 8 of the right lobe. **a** Preprocedural diagnostic axial MSCT scan of a 71-year-old man in prone position clearly depicts the pulmonary lesion. **b** CACT/EMT-guided biopsy images in axial and coronal projection demonstrate accurate advancement of the virtual coaxial tracking needle toward the lesion. Correct needle position is verified by the fusion image alone, although the situation is very sensitive to respiratory motion. Histopathological examination yielded non-small cell lung cancer.

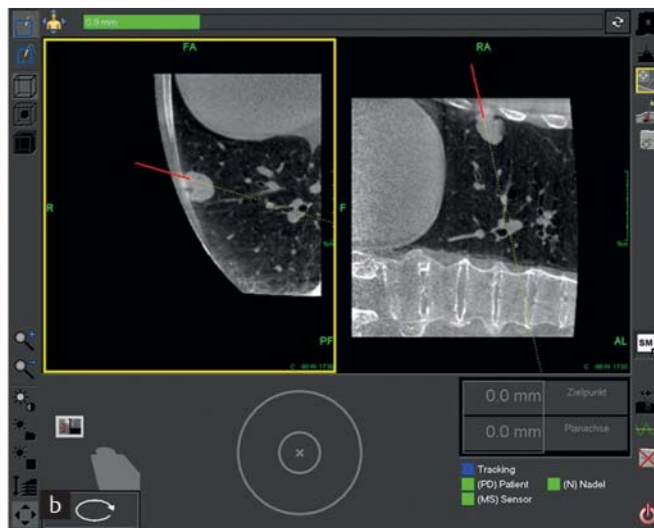


Abb. 2 FD-CT-/EMN-gestützte Biopsie eines subpleuralen Lungenrundherdes im Segment 8 des rechten Lappens. **a** Die präprozedurale diagnostische axiale MSCT-Aufnahme eines 71 Jahre alten Mannes in Bauchlage zeigt deutlich die pulmonale Läsion. **b** Die FD-CT-/EMN-gesteuerten Biopsiebilder in axialer und koronarer Projektion demonstrieren eine präzise Positionierung der virtuellen koaxialen Führungsnadel innerhalb der Läsion. Die korrekte Nadelposition wird anhand des alleinigen Fusionsbildes verifiziert, obwohl die Position als sehr anfällig in Bezug auf Atembewegungen gilt. Die histopathologische Untersuchung erbrachte ein nicht-kleinzelliges Bronchialkarzinom.

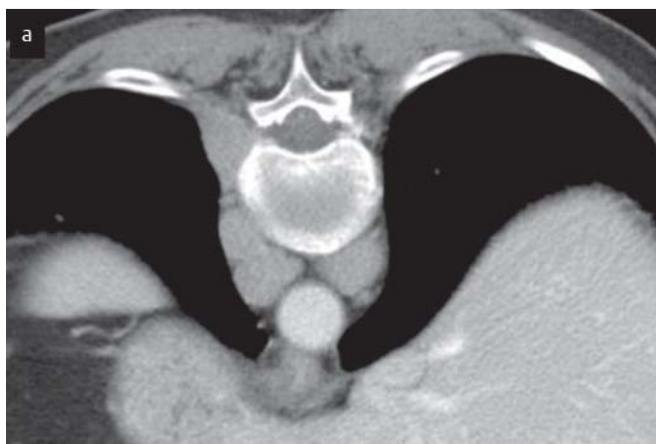

Fig. 3 CACT/EMT-guided biopsy of a lymph node within the retrocrural space. **a** Preinterventional axial MSCT scan obtained in a 74-year-old woman in a prone position shows multiple lymph nodes within the retrocrural space. **b** During CACT/EMT-assisted biopsy that is displayed in axial and sagittal projection, the virtual coaxial tracking needle is correctly inserted into a left-sided lymph node. The diagnosis was recurrent lymphoma.

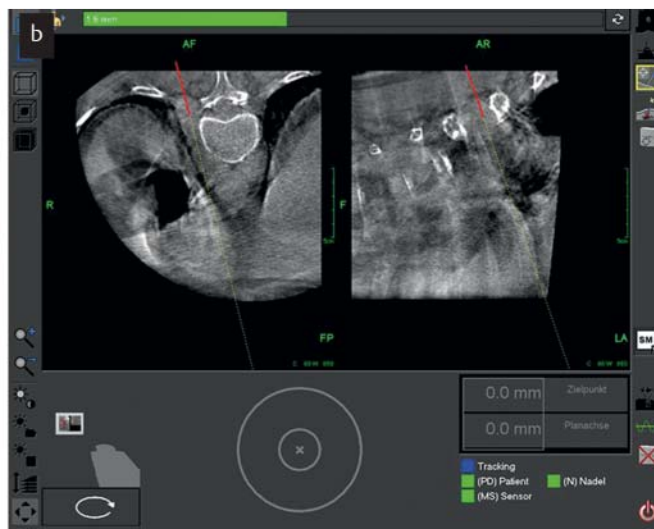


Abb. 3 FD-CT-/EMN-gesteuerte Biopsie eines Lymphknotens innerhalb des Retrokruralraums. **a** Die präinterventionelle axiale MSCT-Aufnahme einer 74 Jahre alten Frau in Bauchlage zeigt multiple Lymphknoten innerhalb des Retrokruralraums. **b** Während der FD-CT-/EMN-gestützten Biopsie in axialer und sagittaler Projektion wird die virtuelle koaxiale Führungsnadel korrekt in einen linksseitigen Lymphknoten geführt. Die Diagnose ergab ein Rezidiv eines Lymphoms.

examination was only initiated in cases of inconclusive fluoroscopy or ultrasound studies.

Primary endpoints of the study were the number of representative biopsy samples and the rate of complications. In addition, the mean diameter of the target lesions, the mean needle path length, the mean number of core biopsy specimens, the mean number of individual CACT acquisitions, the mean total proce-

dure time (from starting CACT until obtaining a suitable biopsy sample), the mean fluoroscopy time, and the mean effective dose were evaluated.

Complications of treatment were classified on the basis of outcome according to the quality improvement guidelines for percutaneous needle biopsy of the Society of Interventional Radiology [21]. Minor complications included those resulting in no therapy

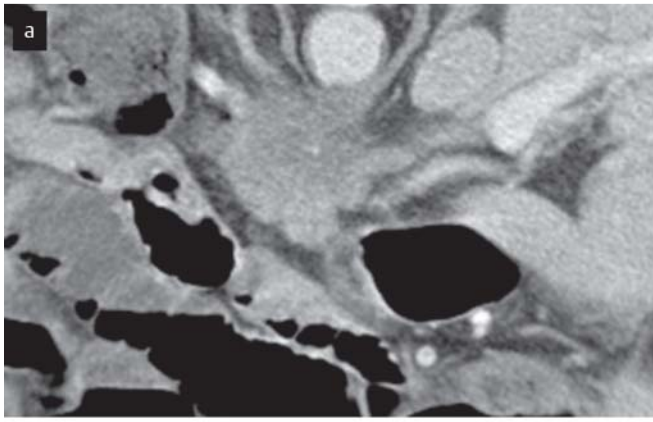


Fig. 4 CACT/EMT-guided biopsy of a mass in the head of the pancreas. **a** Preinterventional axial MSCT scan of a 74-year-old man in a prone position demonstrates the mass within the pancreatic head. **b** CACT/EMT images in axial and sagittal projection show the virtual needle with its tip within the mass that established the diagnosis of adenocarcinoma.

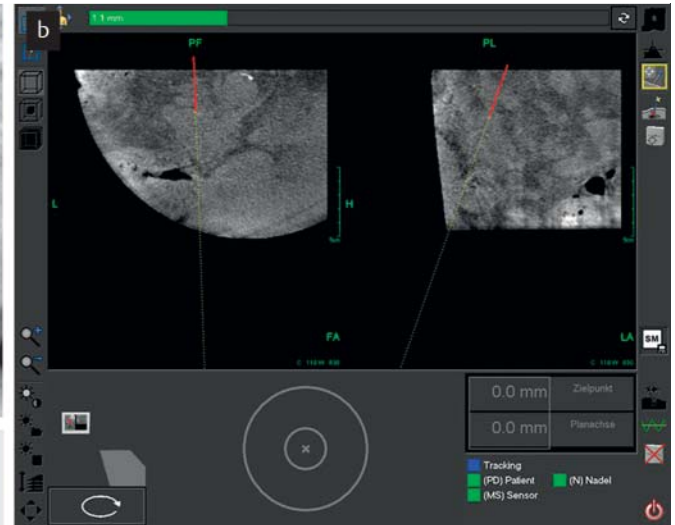


Abb. 4 FD-CT-/EMN-gesteuerte Biopsie einer Massenläsion im Pankreas-kopf. **a** Die präinterventionelle axiale MSCT-Aufnahme eines 74 Jahre alten Mannes in Bauchlage zeigt die Massenläsion innerhalb des Pankreas-kopfes. **b** Die FD-CT-/EMN-Bilder in axialer und sagittaler Projektion zeigen die virtuelle Nadel mit ihrer Spitze innerhalb der Massenläsion, bezüglich der die Diagnose eines Adenokarzinoms gestellt wurde.

and no consequence (class A) or minimal therapy and no consequence including overnight admission for observation only (class B). Major complications included those that required therapy or minor hospitalization for less than 48 hours (class C); those that required major therapy, unplanned increase in level of care, or prolonged hospitalization for more than 48 hours (class D); those that resulted in permanent adverse sequelae (class E); and those that resulted in death (class F).

Statistical Analysis

Descriptive data are presented as arithmetic means with standard deviation and range, if appropriate; categorical data are given as counts and percentages. Statistical analysis was performed with a specialized computed algorithm (MedCalcSoftware, version 6, Mariakerke, Belgium).

Results

19 thoracic and 34 abdominal biopsy procedures were performed in 53 patients (22 women, 31 men) with cone-beam CT-based electromagnetic navigation. Details pertaining to the location of the lesions and kind of target tissue biopsied are presented in the **Table 1**.

The mean (\pm SD) number of core biopsy specimens obtained in each patient was 3.9 ± 1.3 (range, 1–8 core biopsy specimens). The mean (\pm SD) diameter of the target lesion was 45 ± 23 mm (range, 12–97 mm). The mean needle path length (\pm SD) (distance between the skin surface and the center of the target lesion) was 69 ± 31 mm (range, 19–140 mm). The mean (\pm SD) number of individual CACT acquisitions was 1.4 ± 0.7 (range, 1–4 acquisitions). The mean total procedure time (\pm SD) was 9 ± 5 minutes (range, 3–23 minutes). The mean (\pm SD) fluoroscopy time was 0.8 ± 0.4 minutes and ranged between 0.4 and 2 minutes. The mean dose-area product was 7373 ± 5075 cGy cm^2 with a range between 895 and 26904 cGy cm^2 . Applying the

Table 1 Location of lesions and kind of target tissue biopsied using cone-beam CT-based electromagnetic navigation.

Tab. 1 Lokalisation der Läsionen und Art des Zielgewebes, die unter Flachdetektor-CT-basierter elektromagnetischer Navigation biopsiert wurden.

characteristic		no.
location of lesions	thorax	
	supraclavicular/cervical	3
	pulmonary	9
	mediastinal	5
	pleural	1
	paravertebral	1
	abdomen	
intraoperative	16	
retroperitoneal	7	
pelvic	9	
vertebral	2	
target tissue	lung tissue	9
	hepatic tissue	14
	lymphatic tissue	17
	soft tissue	8
	osseous tissue	3
	pancreatic tissue	1
	nerval tissue	1

mean dose-area product and an effective dose conversion factor of $0.0012 \text{ mSv} \times \text{Gy}^{-1} \times \text{cm}^{-2}$ given by the manufacturer, an estimated mean effective dose of 7 mSv was calculated for CACT acquisitions.

Of 53 CACT/EMT-guided biopsy procedures, 40 (75%) lesions were malignant and 13 (25%) lesions were benign. A representative benign histopathological diagnosis was obtained in 13 biopsy procedures and a representative malignant histopathological diagnosis was obtained in 35 biopsy procedures, which was consistent with a technical success rate of 91%. 5 of 53 (9%) histopathological tissue samples were non-representative, 2 of them were non-diagnostic and 3 of them were nonspecific. In four patients with a non-representative CACT/EMT-guided biopsy sam-

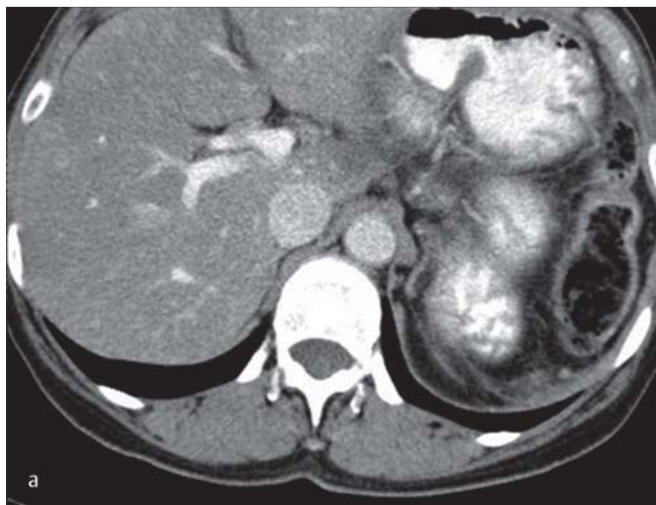


Fig. 5 CACT/EMT-navigated biopsy of periportal lymphatic tissue 7 months after total pancreatectomy due to carcinoma. **a** Preprocedural diagnostic MSCT of a 58-year-old woman in a supine position reveals circumscribed periportal tissue. **b** During CACT/EMT-guided biopsy that is illustrated in axial and sagittal projection, the coaxial tracking needle is carefully navigated toward the tissue margin. Histopathological examination did not yield malignancy.

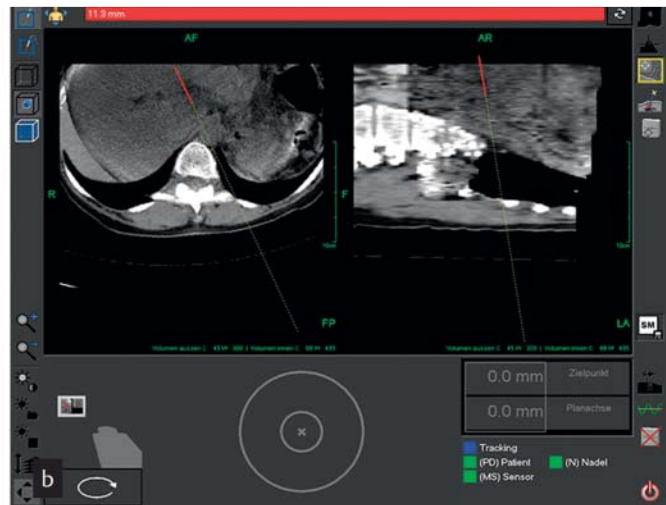


Abb. 5 FD-CT-/EMN-navigierte Biopsie periportalen lymphatischen Gewebes 7 Monate nach totaler Pankreasresektion wegen eines Karzinoms. **a** Die präprozedurale diagnostische axiale MSCT-Aufnahme einer 58 Jahre alten Frau zeigt das umschriebene periportale Gewebe. **b** Während der FD-CT-/EMN-gesteuerten Biopsie in axialer und sagittaler Projektion wird die koaxiale Führungsnadel vorsichtig in Richtung Randbereich des Gewebes navigiert. Die histopathologische Untersuchung erbrachte keine Malignität.

ple, definitive malignant diagnoses were confirmed by surgical biopsy. In one further patient with a non-representative specimen, CT-guided biopsy was performed and yielded malignancy. The locations of the non-representative results were the liver (metastatic liver disease in two patients, hepatocellular carcinoma in one patient), the lung (non-small cell lung cancer in one patient), and the supraclavicular fossa (lymphoma in one patient).

The overall rate of complications following the coupling of CACT- and EMT-guided biopsies was 6%. Minor complications categorized as class B occurred in two patients who suffered from self-limiting hemoptysis. A further minor class B complication was observed in one patient who developed a pneumothorax that did not require tube drainage. Major complications such as life-threatening hemorrhage or unintentional puncture of critical anatomical structures did not occur.

Discussion

The usefulness of CT-guided percutaneous thoracic and abdominopelvic biopsy has been extensively studied [1, 4, 7, 12–14]. Definitely, CT has been proven to be an effective guidance technique for obtaining diagnostic specimens especially in anatomical regions which are considered inaccessible when utilizing alternative guidance modalities such as conventional fluoroscopy or ultrasonography [7, 13, 14]. Some investigators who examined the usefulness of CT coupled with magnetic guidance inferred that this combination might be beneficial in terms of accuracy and safety, especially in out-of-plane biopsy approaches [22].

In a most recent phantom study, Appelbaum et al. [23] evaluated the combination of CT and EMT in biopsy guidance of small lesions. The authors concluded that CT/EMT guidance led to high accuracy with regard to needle placement, thus reducing time and potentially radiation exposure in comparison with conventional CT alone. CACT/EMT guidance is a relatively new innova-

tive technique [20, 23]. Compared with data obtained with exclusive CT or CACT guidance in the literature [7, 12, 14, 24–26], our results showed comparable diagnostic yield values for CACT/EMT-guided biopsy procedures. In our opinion, the reason is twofold: First, despite a slight degradation in image quality electromagnetic navigation per se ensured good control of the virtual needle tip during the procedure in real-time. Due to simultaneous monitoring in a second plane, angling of the needle to avoid transgressing anatomical structures did not represent a major problem, and the correct course of the needle toward the target could be immediately imaged. Second, the phenomenon of respiratory misregistration could be minimized by creation of a monitored warning signal (red bar instead of green bar), as long as breath-hold levels had been subject to great variations. Nevertheless, verification of needle positioning by virtual fusion image alone, especially in regions very sensitive for varying tumor position due to different respiratory motion cycles, as performed in our study, might be problematic. In this context, it may be hypothesized that visualization of the needle end position by an additional CACT acquisition might have increased the number of representative specimens. However, it should be mentioned that exclusive CACT-guided biopsies without EMT in special anatomic regions may result in high success rates that leave little room for improvement [19, 24–26].

The purpose of our study was to evaluate cone-beam CT-based electromagnetic navigation of biopsy procedures in a larger series of patients with a special focus on target lesions in greater part influenced by respiratory misregistration. These lesions were predominantly located in the thoracic cavity, liver, or pancreas, and therefore might have been affected by respiration. Aside from the well-known problem of respiratory motion in the thoracic cavity, there is clear evidence that intraperitoneal organs such as the liver and the spleen move considerably with respiration because of their close proximity to the diaphragm [27]. As a consequence, accurate placement of biopsy needles may be impeded. Motion of intraperitoneal organs with respiration is

generally regarded to be a complex feature that combines cranio-caudal, lateral, and anterior-posterior movements as well as movement due to tissue elasticity [27, 28]. It has also been documented that the pancreas, although located in the retroperitoneal space, may be affected by respiratory excursions [28].

One may criticize that our cohort study does not provide accuracy data. A control C-arm CT image with the needle in place could have been fused with the planning CT to calculate all relevant targeting errors such as total error, lateral error, longitudinal error, and angular error. However, a recent study has already addressed this topic and revealed accurate needle location in phantoms as well as in patients [20]. For that reason our study focused on the technical success of lesion targeting.

An interesting alternative approach has been studied by Schullian et al. [29] who evaluated CT-guided stereotactic liver biopsy by coupling an optical-based navigation system and a stereotactic aiming device. The authors reported high targeting accuracy data in terms of lateral and angular errors, and a diagnostic yield of 97.8% that was even slightly higher than that in our cohort study. Most recently, promising targeting accuracy results with the use of a modified guidance technique, consisting of CACT and stereotactic navigation, have also been found for the puncture of a liver lesion in a phantom study [30]. A subsequent trial further compared CACT-guided versus multislice CT (MSCT)-guided stereotaxy in the puncture of liver lesions. In this phantom study, the investigators concluded that CACT enabled stereotactic targeting accuracy similar to that of MSCT. However, those phantom studies were limited by missing respiratory motion and patient movement that would be found in a clinical setting [30, 31].

Concerning the non-representative samples in our study, it might be speculated that contrast-enhanced CACT acquisitions might have increased the diagnostic yield in those three patients with malignant liver disease. In our opinion, respiratory motion was the reason for a further non-representative sample in a patient with non-small cell lung cancer in his left lower lobe. The reason for another non-representative sample in a patient with supraclavicular lymphoma remains unclear.

In the present study, the estimated mean effective patient dose for CACT/EMT-guided biopsy procedures was lower than the dose for CT-guided biopsies. This finding was in accordance with data reported in clinical literature [10, 19], although we would have expected much lower values for CACT. We believe that these results are caused by the higher number of CACT acquisitions in some patients. In those patients the region of interest had not been captured by the first CACT acquisition, mainly due to the limited field of view.

Since CACT acquisitions have to be performed with the radiologist inside the angiography suite [15, 17, 20], consequent radioprotection with aprons, thyroid shields, eyeglasses, ceiling-mounted lead shields, and mobile lead barriers is of utmost importance. If there is separated space within the angio suite with open view protected by lead glass, there will be no radiation exposure during CACT acquisition.

There are multiple advantages of cone-beam CT-based electromagnetic navigation of biopsy procedures. In many institutions CT units must have a high throughput of patients. Availability of those units for CT-guided interventions may be limited. As a consequence, performance of biopsy procedures in the angiography suite may improve the availability of CT units for the daily routine. Usually, there are better sterile conditions in an angiography suite. In addition, patient comfort was felt to be higher during

cone-beam CT-based electromagnetic navigation with the interventional radiologists standing next to the patient during the whole biopsy procedure. Moreover, patients were not placed within the CT gantry that may lead to claustrophobia. Another benefit of an EMT system may be the possibility of planning of the biopsy path prior to the procedure. This may lead to better histopathological outcomes with fewer complications.

One disadvantage of cone-beam CT-based electromagnetic navigation of biopsy procedures is its cost. In this context, the purchase price for the EMT system is about 100 000 € and the cost of each deployed coaxial tracking needle is about 120 €. Nevertheless, cost has to be considered in relative terms, since transfer of biopsy procedures from the CT unit to the angiography suite may result in an increase of routine CT examinations and a higher throughput of patients. However, this hypothesis needs to be proven in a cost-benefit analysis. Aside from this aspect, the problem of expensive coil-integrated coaxial needles may be generally overcome by using a stereotactic aiming device [29–31]. Another important factor is that CACT-based electromagnetic navigation procedures may be associated with a learning curve concerning patient positioning, positioning of the reference frame, individual CACT acquisition, and biopsy performance. As expressed by the range of CACT acquisitions in our study, scanning may be very demanding, since the field of view is generally restricted [15–17, 19–26].

The wide range of core biopsy specimen numbers in our study has to be attributed to the fact that in some cases fragmentation of biopsy specimens was observed. Generally, fragmented biopsy specimens may have an impact on adequate histopathological examination [32].

The complications (pneumothorax, hemoptysis) that occurred in our study are common in the context of lung biopsies. They relate to the lung and have to be designated as organ-specific. In comparison, generic complications refer to those that are common to all biopsies [21].

There are three main limitations of our study. First, our study is limited by the small sample size of 53 consecutive patients, preventing us from generalizing the results. As a consequence, we consider the results of our study preliminary. Second, the study was retrospective and lacked randomization. A prospective randomized trial would be beneficial for defining the exact value of CACT/EMT-guided biopsies compared with MSCT guidance. However, the major drawback of this study is the heterogeneity of target location resulting in difficulty generalizing the technical advantage of this combined approach regarding potential benefits such as time, dose reduction, and the accuracy of targeted biopsy.

CACT combined with EMT appears to be an effective technique for the guidance of percutaneous biopsies with a low rate of therapeutically relevant complications. However, this technique requires further prospective randomized evaluation with larger patient populations to fully assess its potential in comparison with MSCT guidance.

Clinical Relevance of the Study

- ▶ The combination of CACT and EMT presents a feasible and innovative technique in the guidance of percutaneous biopsies.
- ▶ CACT/EMT-guided percutaneous biopsy approaches are associated with a good technical success rate of lesion targeting.
- ▶ CACT coupled with EMT seems to be a relatively safe guidance technique for percutaneous biopsies.

Conflict of interest: This work has been partially funded by Siemens AG, Healthcare Sector, Forchheim, Germany.

References

- 1 Haaga JR, Alfydi RJ. Precise biopsy localization by computed tomography. *Radiology* 1976; 118: 603–607
- 2 Welch TJ, Sheedy PF, Johnson CD et al. CT-guided biopsy: prospective analysis of 1000 procedures. *Radiology* 1989; 171: 493–496
- 3 Gazelle GS, Haaga JR. Guided percutaneous biopsy of intraabdominal lesions. *Am J Roentgenol Am J Roentgenol* 1989; 153: 929–935
- 4 Silverman SG, Bloom DA, Seltzer SE et al. Needle-tip localization during CT-guided abdominal biopsy: comparison of conventional and spiral CT. *Am J Roentgenol Am J Roentgenol* 1992; 159: 1095–1097
- 5 Haramati LB. CT-guided automated needle biopsy of the chest. *Am J Roentgenol Am J Roentgenol* 1995; 165: 53–55
- 6 Yankelevitz DF, Henschke CI, Davis SD. Angulated needle placement in CT-guided percutaneous needle biopsy of the thorax. *Clin Imaging* 1993; 17: 124–125
- 7 Sheafor DH, Paulson EK, Simmons CM et al. Abdominal percutaneous interventional procedures: comparison of CT and US guidance. *Radiology* 1998; 207: 705–710
- 8 Dupuy DE, Rosenberg AE, Punyatabandhu T et al. Accuracy of CT-guided needle biopsy of musculoskeletal neoplasms. *Am J Roentgenol Am J Roentgenol* 1998; 171: 759–762
- 9 de Mey J, Op de Beeck B, Freson M et al. Computed tomography-guided diagnostic puncture in abdominal pathology. *J Radiol* 1999; 80: 11–16
- 10 Ghaye B, Dondelinger RF, Dewe W. Percutaneous CT-guided lung biopsy: sequential versus spiral scanning. A randomized prospective study. *Eur Radiol* 1999; 9: 1317–1320
- 11 Wutke R, Schmid A, Fellner F et al. CT-guided percutaneous core biopsy: effective accuracy, diagnostic utility and effective costs. *Fortschr Röntgenstr* 2001; 173: 1025–1033
- 12 Lopez HE, Vogl TJ, Ricke J et al. CT-guided percutaneous core biopsies of pulmonary lesions. Diagnostic accuracy, complications and therapeutic impact. *Acta Radiol* 2001; 42: 151–155
- 13 Kirchner J, Kickuth R, Laufer U et al. CT-fluoroscopy-assisted puncture of thoracic and abdominal masses: a randomized trial. *Clin Radiol* 2002; 57: 188–192
- 14 Muehlstaedt M, Bruening R, Diebold J et al. CT/fluoroscopy-guided transthoracic needle biopsy: sensitivity and complication rate in 98 procedures. *J Comput Assist Tomogr* 2002; 26: 191–196
- 15 Wallace MJ, Kuo MD, Glaiberman C et al. Three-dimensional C-arm cone-beam CT: applications in the interventional suite. *J Vasc Interv Radiol* 2009; 20: S523–S537
- 16 Braak SJ, van Strijen MJL, van Leersum M et al. Real-time 3D fluoroscopy guidance during needle interventions: technique, accuracy, and feasibility. *Am J Roentgenol Am J Roentgenol* 2010; 194: W445–W451
- 17 Meyer BC, Wolf KJ, Wacker FK. Flat-detector CT-based electromagnetic navigation. *Radiologe* 2009; 49: 856–861
- 18 Vogl TJ, Balzer JO, Mack MG et al. Interventional MDCT. *Eur Radiol* 2003; 13: M139–M145
- 19 Tselikas L, Joskin J, Roquet F et al. Percutaneous bone biopsies: comparison between flat-panel cone-beam CT and CT-scan guidance. *Cardiovasc Intervent Radiol* 2015; 36: 167–176
- 20 Meyer BC, Peter O, Nagel M et al. Electromagnetic field-based navigation for percutaneous punctures on C-arm CT: experimental evaluation and clinical application. *Eur Radiol* 2008; 18: 2855–2864
- 21 Gupta S, Wallace MJ, Cardella JF et al. Quality improvement guidelines for percutaneous needle biopsy. *J Vasc Interv Radiol* 2010; 21: 969–975
- 22 Wallace MJ, Gupta S, Hicks ME. Out-of-plane computed-tomography-guided biopsy using a magnetic-field-based navigation system. *Cardiovasc Intervent Radiol* 2006; 29: 108–113
- 23 Appelbaum L, Sosna J, Nissenbaum Y et al. Electromagnetic navigation system for CT-guided biopsy of small lesions. *Am J Roentgenol Am J Roentgenol* 2011; 196: 1194–1200
- 24 Braak SJ, Herder GJ, van Heeswijk JP et al. Pulmonary masses: initial results of cone-beam CT guidance with needle planning software for percutaneous lung biopsy. *Cardiovasc Intervent Radiol* 2012; 35: 1414–1421
- 25 Braak SJ, van Melick HH, Onaca MG et al. 3D cone-beam CT guidance, a novel technique in renal biopsy – results in 41 patients with suspected renal masses. *Eur Radiol* 2012; 22: 2547–2552
- 26 Hwang HS, Chung MJ, Lee JW et al. C-arm cone-beam CT-guided percutaneous transthoracic lung biopsy: usefulness in evaluation of small pulmonary nodules. *Am J Roentgenol Am J Roentgenol* 2010; 195: W400–W407
- 27 Clifford MA, Banovac F, Levy E et al. Assessment of hepatic motion secondary to respiration for computer assisted interventions. *Comp Aid Surg* 2002; 7: 291–299
- 28 Bhasin DK, Rana SS, Chandail VS. The Pancreas and Respiration: Oblivious to the Obvious! *JOP* 2006; 7: 578–583
- 29 Schullian P, Widmann G, Lang TB et al. Accuracy and diagnostic yield of CT-guided stereotactic liver biopsy of primary and secondary liver tumors. *Comput Aided Surg* 2011; 16: 181–187
- 30 Toporek G, Wallach D, Weber S et al. Cone-beam computed tomography-guided stereotactic liver punctures: a phantom study. *Cardiovasc Intervent Radiol* 2013; 36: 1629–1637
- 31 Widmann G, Wallach D, Toporek G et al. Angiographic C-arm CT- versus MDCT-guided stereotactic punctures of liver lesions: nonrigid phantom study. *Am J Roentgenol Am J Roentgenol* 2013; 201: 1136–1140
- 32 Cholongitas E, Senzolo M, Standish R et al. A Systematic Review of the Quality of Liver Biopsy Specimens. *Am J Clin Pathol* 2006; 125: 710–721