

Epileptic Encephalopathies in Childhood: The Role of Genetic Testing

Johannes R. Lemke, MD¹ Steffen Syrbe, MD²

¹Institute of Human Genetics, University of Leipzig, Leipzig, Germany
²Department of Women and Child Health, Hospital for Children and Adolescents, University of Leipzig, Leipzig, Germany

Address for correspondence Johannes R. Lemke, MD, Institute of Human Genetics, University Hospital Leipzig, Philipp-Rosenthal-Str. 55, D-04103 Leipzig, Germany (e-mail: johannes.lemke@medizin.uni-leipzig.de).

Semin Neurol 2015;35:310–322.

Abstract

The epileptic encephalopathies comprise a heterogeneous group of neurodevelopmental disorders characterized by marked epileptic activity associated with developmental regression. The genetic confirmation and classification of a clinical diagnosis in an individual may provide certainty in treatment decisions, prognosis, and evaluation of seizure recurrence risks and may also prevent unnecessary diagnostic investigations. Furthermore, without genetic testing it is challenging to classify the epileptic encephalopathies based on clinical and electroencephalogram features alone.

Keywords

- ▶ epileptic encephalopathy
- ▶ infantile epilepsy
- ▶ molecular genetic testing

The significant gain of knowledge of the past few years associated with improvement in genetic analyses allows for precise diagnoses in an increasing number of patients. As a consequence, known encephalopathies have been associated with even broader phenotypic ranges and novel entities constantly expand the spectrum of these disorders. Accordingly, many entities of this heterogeneous spectrum escape a precise classification using current nomenclatures.

Epileptic encephalopathies comprise a spectrum of disorders manifesting epilepsy and consequent psychomotor delay. According to the International League Against Epilepsy (ILAE), the epileptic activity itself most likely contributes to the severe cognitive and behavioral impairments, above and beyond that expected from the underlying pathology alone.¹ Many forms of epileptic encephalopathy worsen over time and are refractory to pharmacotherapy.

Here we provide an overview of the growing field of epileptic encephalopathies that have no detectable structural brain lesions or metabolic abnormalities during the neonatal period, infancy, and childhood. Furthermore, we discuss a classification based on the clinical phenotype and onset versus a classification based on the genetic background of this group of disorders.

The ILAE classification is based primarily on the age of seizure onset, and it differentiates epileptic encephalopathy entities that have a specific clinical appearance or a particular pattern on electroencephalogram (EEG)¹:

- Neonatal period
 - Early myoclonic encephalopathy
 - Ohtahara syndrome
- Infancy
 - Epilepsy of infancy with migrating focal seizures
 - West syndrome
 - Dravet syndrome
 - Myoclonic encephalopathy in nonprogressive disorders
- Childhood
 - Epilepsy with myoclonic atonic seizures
 - Lennox–Gastaut syndrome
 - Epileptic encephalopathy with continuous spike-and-wave during sleep
 - Landau–Kleffner syndrome

Epileptic encephalopathies that have no recognizable EEG pattern, particular seizure semiology, or additional specific features are not covered by the current ILAE classification.

Table 1 List of the known early infantile epileptic encephalopathy (EIEE) phenotypes according to Online Mendelian Inheritance in Man (OMIM), their respective causative genes, and the number of mutations listed in the Human Gene Mutation Database (HGMD)

OMIM entity	Gene	No. of published mutations in HGMD (as of May 6, 2015)	Allelic phenotypes (in addition to EIEE)
EIEE1	<i>ARX</i>	69	Hydranencephaly with abnormal genitalia, X-linked lissencephaly 2, X-linked mental retardation 29, Partington syndrome, Proud syndrome
EIEE2	<i>CDKL5</i>	216	Angelman syndrome-like
EIEE3	<i>SLC25A22</i>	3	
EIEE4	<i>STXBP1</i>	79	
EIEE5	<i>SPTAN1</i>	10	
EIEE6	<i>SCN1A</i>	1098	Dravet syndrome, Generalized epilepsy with febrile seizures plus type 2, Familial febrile seizures 3A, Familial hemiplegic migraine 3
EIEE7	<i>KCNQ2</i>	148	Benign neonatal seizures 1 (BFNS), Myokymia
EIEE8	<i>ARHGEF9</i>	8	
EIEE9	<i>PCDH19</i>	121	
EIEE10	<i>PNKP</i>	8	
EIEE11	<i>SCN2A</i>	77	Benign familial infantile seizures 3
EIEE12	<i>PLCB1</i>	7	
EIEE13	<i>SCN8A</i>	27	Cognitive impairment with or without cerebellar ataxia
EIEE14	<i>KCNT1</i>	15	Nocturnal frontal lobe epilepsy 3
EIEE15	<i>ST3GAL3</i>	3	Autosomal recessive mental retardation 12
EIEE16	<i>TBC1D24</i>	21	DOOR syndrome Autosomal recessive deafness 86 Familial infantile myoclonic epilepsy
EIEE17	<i>GNAO1</i>	6	
EIEE18	<i>SZT2</i>	4	
EIEE19	<i>GABRA1</i>	12	Childhood absence epilepsy, Juvenile myoclonic epilepsy, Dravet syndrome
EIEE20	<i>PIGA</i>	8	
EIEE21	<i>NECAP1</i>	1	
EIEE22	<i>SLC35A2</i>	8	
EIEE23	<i>DOCK7</i>	4	
EIEE24	<i>HCN1</i>	7	Idiopathic generalized epilepsy
EIEE25	<i>SLC13A5</i>	4	
EIEE26	<i>KCNB1</i>	4	
EIEE27	<i>GRIN2B</i>	26	Autism spectrum disorders
EIEE28	<i>WWOX</i>	18	
EIEE29	<i>AARS</i>	6	
EIEE30	<i>SIK1</i>		

In contrast to the ILAE, Online Mendelian Inheritance in Man (OMIM; www.ncbi.nlm.nih.gov/omim) does not discriminate between clinical phenotypes, but classifies early-

infantile epileptic encephalopathies exclusively according to the causative gene. This rapidly growing catalogue lists 30 such phenotypes (by May 2015). Some have so far only been

reported as very rare and isolated cases, whereas others significantly overlap or form part of a continuum with different epileptic encephalopathies.

The allelic phenotypes include both incontrovertible monogenetic associations such as *SCN1A* and Dravet syndrome and as yet unproven risk alleles for complex phenotypes such as *GABRA1* and juvenile myoclonic epilepsy.

The number of HGMD-listed mutations shows how often the disorder is diagnosed in the scientific literature. Due to allelic phenotypes, not all these mutations are associated with early infantile epileptic encephalopathy; for example, a minority of *SCN1A* mutations is associated with GEFS+ or hemiplegic migraine, and on the contrary, most *KCNQ2* and *SCN2A* mutations cause benign familial epilepsy disorders—not early infantile epileptic encephalopathy (►Table 1).

Neonatal Period

Early Myoclonic Encephalopathy

Clinical Description

Early (or neonatal) myoclonic encephalopathy, together with Ohtahara syndrome, shows a characteristic burst-suppression pattern on EEG. Phenotypic similarities can make it difficult to distinguish these disorders, and some authors consider them as a fluid continuum.² Aicardi and Goutières first described early myoclonic encephalopathy in 1978.³ It usually starts in the first days of life with predominantly myoclonic seizures. Recurrent familial cases have been attributed mainly to inherited disorders of metabolism, especially nonketotic hyperglycinemia, pyridoxine, and pyridoxal phosphate-dependent epilepsy, sulfite-oxidase deficiency, and Menkes disease, as well as brain malformations.^{4–6} The seizures are usually described as myoclonic or erratic myoc-

lonus. Although shifting focal myoclonias that affect different parts of the body, including the face and eyelids, are regarded as nonepileptic, focal motor seizures occur in more than 80% of patients and can include autonomic ictal manifestations and apnea (►Figs. 1 and 2).^{7,8} A neonatal burst-suppression pattern may evolve into hypsarrhythmia within the first months of life. The prognosis is very poor, with severe global developmental delay and a mortality rate of up to 50% during the first 2 years of life.^{2,6,7} Functional cortico-subcortical deafferentation from diffuse brain damage involving the brainstem and the white matter is regarded as the common underlying pathology, causing cortical hyperexcitability in early myoclonic encephalopathy.^{6,9,10}

Genetics

The genetic background of early myoclonic encephalopathy is unclear. There is a single report of a patient carrying a de novo reciprocal chromosomal translocation with consecutive disruption of the *ERBB4* gene, being putatively involved in neuromigration.¹¹ Another report associated mutations in *PIGA* with early myoclonic encephalopathy and other forms of epileptic encephalopathy.¹²

Ohtahara Syndrome or Early Infantile Epileptic Encephalopathy

Clinical Description

Ohtahara and colleagues first described early infantile epileptic encephalopathy in 1976 as a disorder starting during the first 3 months of infancy.¹³ It primarily differs from epileptic encephalopathy of infantile onset (e.g., West syndrome) because of dominating tonic spasms, the variable seizure types including focal motor seizures, and its specific EEG pattern (►Fig. 3).¹⁴ The cardinal EEG feature of Ohtahara

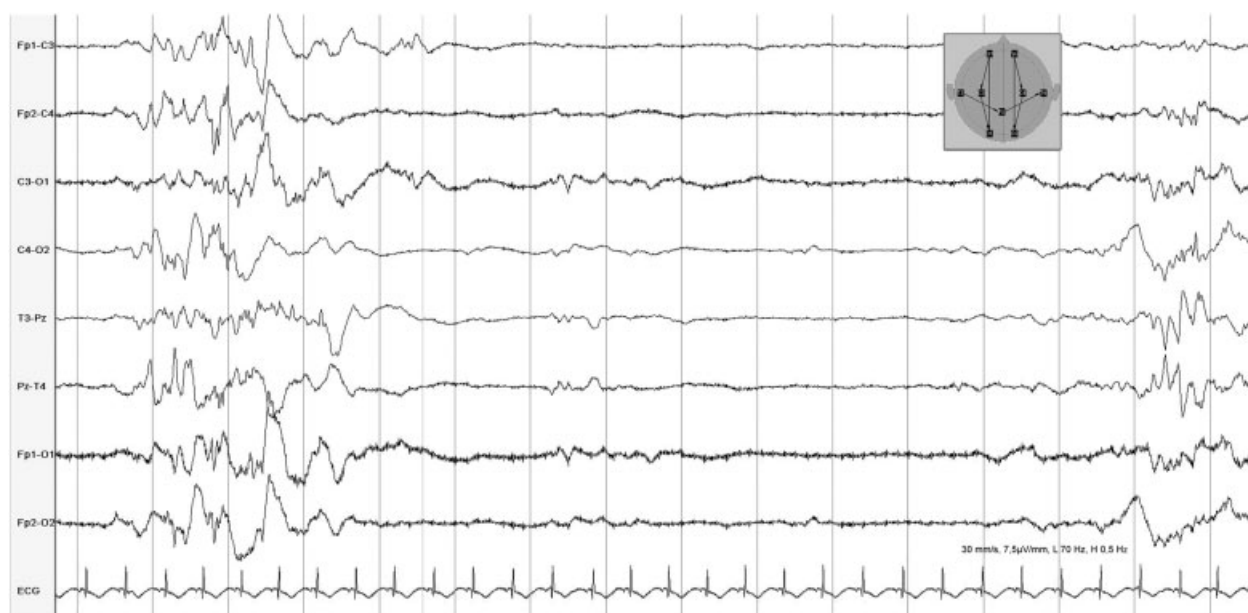


Fig. 1 Burst-suppression pattern in a patient with early myoclonic encephalopathy due to nonketotic hyperglycinemia. The patient showed shifting myoclonia, subtle seizures, and myoclonia including repetitive singultus. The burst-suppression pattern is more prominent during sleep.

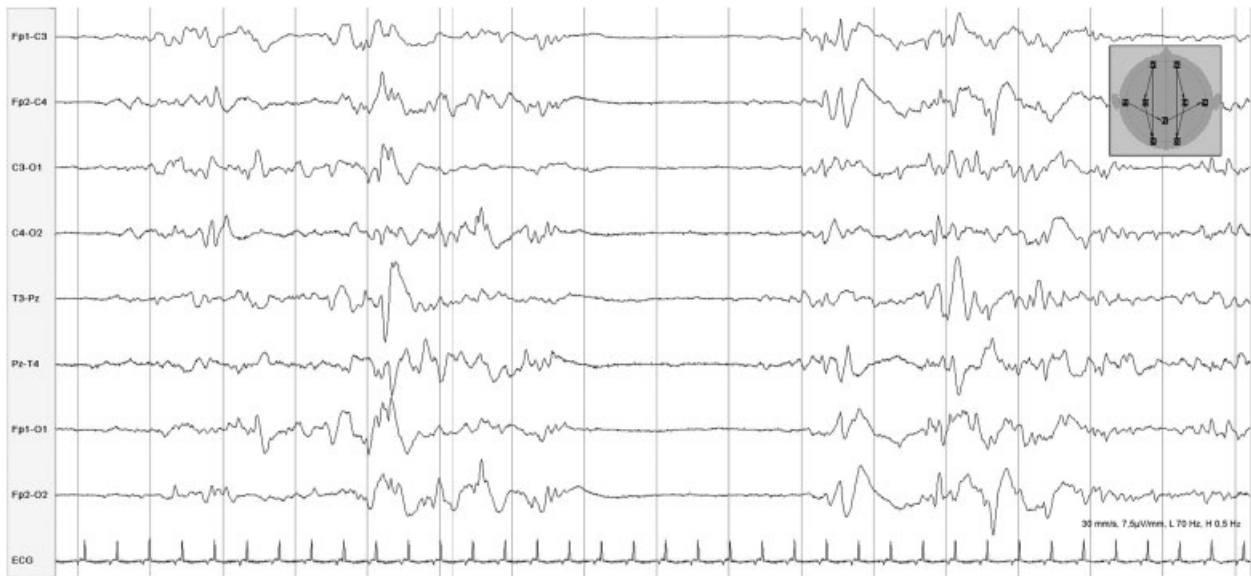


Fig. 2 Burst-suppression pattern in a girl with early myoclonic encephalopathy of unclear etiology. She presented with near-constant myoclonus and increased muscle tone associated with multifocal myoclonia as well as frequent seizure-related apnea. Brain magnetic resonance imaging showed cerebellar hypoplasia and progressive global atrophy.

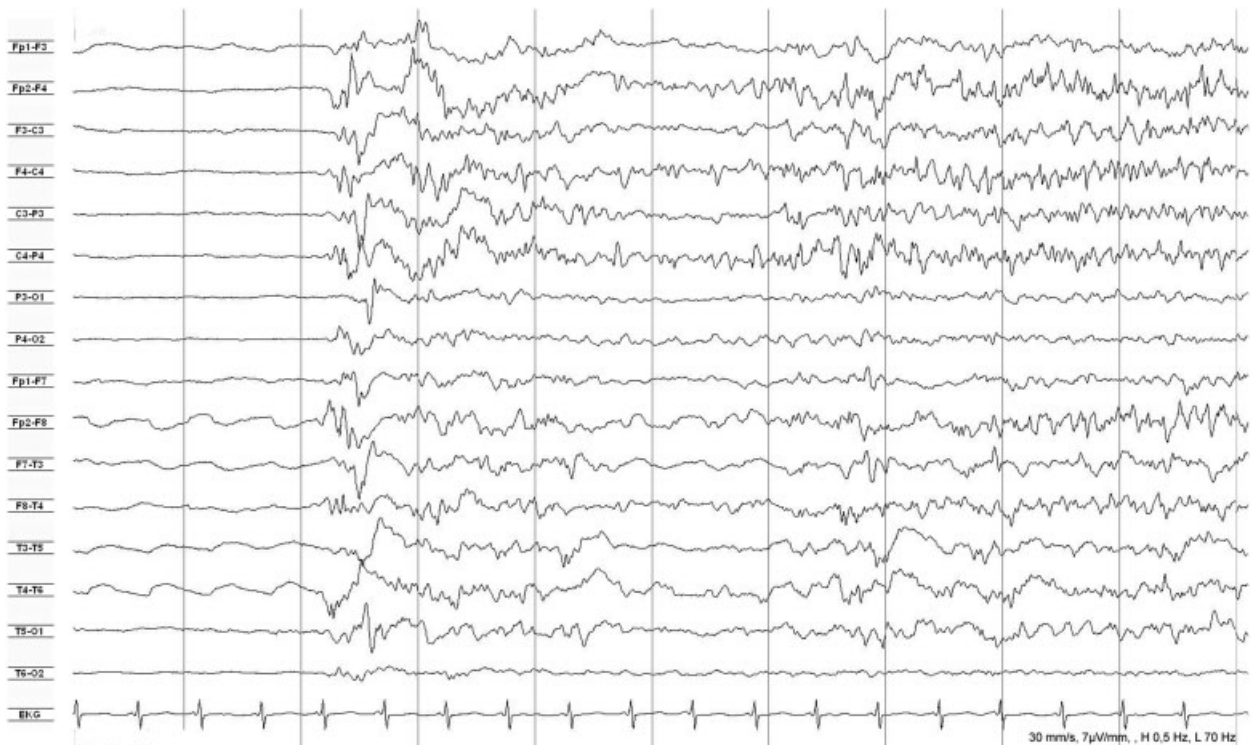


Fig. 3 Suppression period, followed by a burst of epileptic discharges that mark the onset of an ictal pattern in a 4-month-old girl with Ohtahara syndrome. Tonic seizures occurred at age 2 months, followed by multiple, predominantly focal seizure types. Brain magnetic resonance imaging showed severe brain atrophy during the first year of life. At 7 years old, she is severely impaired and has occasional seizures.

Table 2 Ohtahara syndrome

Mutation	Phenotype
<i>ARX</i>	Male patients with additional malformations, such as hypospadias, agenesis of corpus callosum, lissencephaly, ¹⁷ progressive microcephaly, ¹⁶ or choreatic dystonia ¹⁸
<i>STXBP1</i>	Patients without significant malformations or dysmorphism, but frequently with early-onset movement disorders. Seizure frequency may sometimes decrease during infancy. Patients with focal cortical dysplasia may benefit from epilepsy surgery. ¹⁹ There were mutations in 2 out of 6 (33%) Ohtahara patients and 12 out of 266 (4.5%) of early infantile epileptic encephalopathy patients. ^{19,20}
<i>KCNQ2</i>	No significant malformations or dysmorphism. Seizure frequency may sometimes decrease during infancy. There were mutations in 19 out of 164 (11.6%) of EIEE patients. ^{21,22} Majority of <i>KCNQ2</i> mutation carriers do not develop early infantile epileptic encephalopathy, but develop benign neonatal seizures.
<i>CASK</i>	Male patients with microcephaly and pontocerebellar hypoplasia. ²³
<i>GNAO1</i>	Patients may present with movement disorders including dystonia, chorea, and athetosis. ²⁴
<i>Copy number variations</i>	Variable phenotypes; usually individual microdeletions

syndrome is a constant burst-suppression pattern during wakefulness and sleep.¹⁰ Trials with pyridoxine and pyridoxalphosphate are recommended, and phenobarbital, vigabatrin, or adrenocorticotrophic hormone are used among others, but the seizures are usually refractory to pharmacotherapy and most patients have severely impaired development. Many patients die within the first months of life; others may evolve into West and Lennox–Gastaut syndrome during the course.^{6,8,14,15} Metabolic causes appear to be rare. Some patients demonstrate structural brain anomalies on magnetic resonance imaging (MRI), such as lissencephaly, hemimegalencephaly, or agenesis of the corpus callosum.¹⁶

Genetics

There are no published large-scale studies on the mutational spectrum of Ohtahara syndrome. Thus, our current knowledge is based upon small cohorts or isolated single case reports (–Table 2).

Epilepsy of Infancy with Migrating Focal Seizures

Clinical Description

Coppola and colleagues first described the rare syndrome of malignant migrating partial seizures or epilepsy in infancy (MMPSI) in 1995.²⁵ There are three well-characterized distinct stages of the disease:

1. Sporadic seizures usually occur within the first 6 months of life: These are mainly focal with rapid secondary generalization, often with autonomic features. The EEG at this early stage shows nonspecific diffuse slowing of background activity.
2. After a few weeks to months, the second “stormy” phase follows, with clusters of up to 30 focal polymorphic seizures per day that are often lateralized with deviation of the head and eyes as well as tonic and clonic jerks of extremities. During this phase, the EEG typically shows focal discharges that are “migrating” between cortical

areas or develop independently in different areas of the same or opposite hemisphere. In general, seizures are resistant to therapy. Seizure phenotypes usually correlate with localization of ictal activity on EEG, thus producing clinical and electroencephalographic complex multifocal status epilepticus.

3. In the third period, at ages 2 to 5 years, seizures remit or occur only occasionally (sometimes triggered by illnesses), whereas severe developmental impairment becomes more prominent.^{25–27}

Genetics

Epilepsy of infancy with migrating focal seizures has recently been associated with heterozygous mutations in *KCNT1* (in up to 40% of cases) as well as compound heterozygous mutations in *TBC1D24*. Thus, MMPSI is heterogeneous and comprises both autosomal dominant and recessive entities.^{27–29} Single cases have shown mutations in *PLCB1*, *SCN8A*, *SLC25A22*, *SCN2A*, and *SCN1A*, whereas other studies could not confirm mutations in *SCN1A*, *SCN2A*, *KCNQ2*, and *KCNQ3*, as well as *CLCN2* as major causes of epilepsy of infancy with migrating focal seizures.^{30–33}

Infancy

Infantile Spasms and West Syndrome

Clinical Description

Infantile (or epileptic) spasms (ISs) are flexor spasms with bilateral tonic contractions. They are classified as a distinct seizure type, defined as unknown if generalized or focal according to the 2010 classification of the ILAE.¹ The term West syndrome describes the triad of ISs together with a hypsarrhythmia pattern on EEG and behavioral or mental regression (–Fig. 4).^{1,34} In West syndrome, ISs appear in clusters (with up to 150 spasms) up to 30 times per day, starting between 3 and 9 months of age, with an incidence of 3 to 5 per 10,000 live births.^{8,34} Hypsarrhythmia is the typical

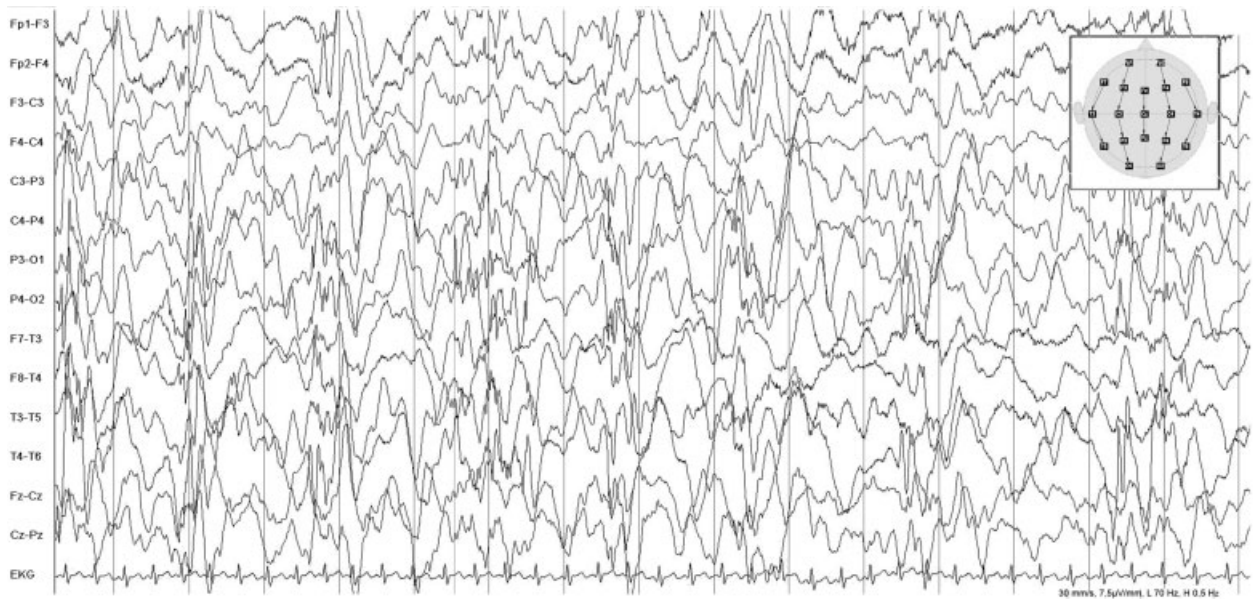


Fig. 4 Interictal electroencephalogram (EEG) in a 5-month-old girl with infantile spasms in the context of Aicardi syndrome. The EEG shows hypsarrhythmia (high-amplitude slow waves with irregular interspersed spikes and polyspikes) with right hemispheric dominance.

interictal EEG pattern consisting of chaotic generalized asynchronous high-amplitude slow and sharp waves with interspersed multifocal irregular spikes and polyspikes. Given the co-occurrence of developmental regression, West syndrome is the prototypical epileptic encephalopathy, arguing for a causal relationship between epileptic activity and progressive psychomotor deterioration. Recent studies in tuberous sclerosis complex-related West syndrome provided evidence that prophylactic treatment of epileptic discharges in EEG before the onset of epilepsy can help both mental development and epilepsy outcome.³⁵ Adrenocorticotropic hormone or vigabatrin are the drugs of choice in West syndrome, controlling seizures in about two-thirds of patients.⁸

Genetics

The etiology of West syndrome and IS relate mainly to structural (e.g., due to tuberous sclerosis complex [TSC], hypoxic/ischemic encephalopathy, cortical dysgenesis) or metabolic abnormalities. Only 25% of cases are of unknown origin.³⁶ In tuberous sclerosis complex—a multi-system or-

gan disease often involving brain anomalies—West syndrome develops in 30% to 40% of patients; therefore, it is the single most prevalent genetic cause of West syndrome, accounting for around 7% of cases.^{37,38}

In the remainder of idiopathic cases, only a minority of genes have been repeatedly associated with West syndrome (→ **Table 3**). Additionally, several isolated cases have been associated with mutations in a plethora of genes: *CDKL5*, *SLC25A22*, *SPTAN1*, *PLCB1*, *ST3GAL3*, *HDAC4*, and others.^{39–42} By only regarding clinical aspects (IS) or EEG features (hypsarrhythmia), this spectrum of genes is even wider and will most likely increase in the near future.

Dravet Syndrome and Severe Myoclonic Epilepsy of Infancy

Clinical Description

Charlotte Dravet initially described Dravet syndrome (DS) as severe myoclonic epilepsy of infancy in 1978.⁴⁵ Dravet syndrome manifests in otherwise normal infants aged 3 to

Table 3 West syndrome

Mutation	Phenotype
<i>ARX</i>	Often associated with brain malformations; see also Ohtahara syndrome
<i>STXBP1</i>	Patients without significant malformations or dysmorphic features. Mutations were found in 1 out of 65 (2%) of patients with West syndrome. ¹⁹ Four out of 6 (67%) <i>STXBP1</i> mutation carriers developed West syndrome. ²⁰
<i>DNM1</i>	Severe psychomotor delay, no speech, muscular hypotonia. Mutations were found in 5 out of 356 epileptic encephalopathy patients (1.4%). All 5 patients had infantile spasms, 3 had hypsarrhythmia. ^{42,43}
<i>GRIN2B</i>	Severe psychomotor delay, no speech, muscular hypotonia ⁴⁴
Copy number variations	Variable phenotypes; usually individual microdeletions

12 months, usually with febrile unilateral clonic or tonic-clonic seizures and sometimes hemiclonic status epilepticus. Focal dyscognitive seizures and atypical absences also occur until 4 years of age. Most children show myoclonic seizures as originally described, differentiating between the classic severe myoclonic epilepsy of infancy phenotype and the borderline forms of Dravet syndrome.^{46,47}

Seizures are commonly triggered by fever, infections, vaccination, hyperthermia, or photic stimulation. Interictal EEG is usually normal at onset. About 20% to 25% show generalized spike waves after photic stimulation.^{48,49} After 3 years of age, most affected children show EEG abnormalities; however, the interictal EEG can retain a normal background activity and many cases show no epileptiform activity.^{8,46,47}

In general the brain MRI is normal, though occasionally there is hippocampal sclerosis or brain atrophy.^{46,47} Patients seem to benefit from early antiepileptic treatment, most often a combination of antiepileptic drugs, including valproic acid, benzodiazepines, bromide, topiramate, and stiripentol. However, it is essential to avoid sodium channel blockers, such as carbamazepine or lamotrigine, as these can worsen epilepsy and nonepileptic movement disorders.^{46,47}

Vagus nerve stimulation and the ketogenic diet have recently been shown to be an alternative treatment option in epileptic encephalopathy including Dravet syndrome with minimal side effects and increasing quality of life.⁵⁰ Children with Dravet syndrome typically show a slight delay in walking and clumsiness; the gait often becomes ataxic and some develop a spastic-like crouch pattern later in life.⁵¹ The seizures typically persist and intellectual outcome is unfavorable.⁴⁷

Genetics

Dravet syndrome is caused by mutations in *SCN1A* in at least 75% of cases.⁵² Several other genes have been associated with Dravet or Dravet-like phenotypes, such as *PCDH19* (females only)⁵³ or less frequent in *SCN1B*, *SCN2A*, and *GABRG2*. More recently, mutations in *GABRA1* and *STXBPI* have been associated with classic Dravet syndrome,⁵⁴ whereas mutations in *CHD2* have been detected in late-onset cases.⁵⁵ Mutations in *HCN1* have been found in patients diagnosed with Dravet syndrome, but presenting with a different progression and a more severe degree of intellectual deficit.⁵⁶

Thus, *SCN1A*-negative Dravet (-like) patients show a high genetic heterogeneity; it is proposed that the term Dravet syndrome be reserved for *SCN1A* mutation carriers only.

Variants in *SCN9A* have been described as putatively disease-modifying factors in addition to mutations in *SCN1A*.⁵⁷ However, this and other putative modifiers remain to be replicated in large cohorts. Because the quality and sensitivity of molecular genetic diagnostics have significantly improved in the last decade, it may be reasonable to question "old" negative *SCN1A* results in patients with classic Dravet syndrome. Several false-negative findings have been reported recently due to improvement of sequencing techniques.⁵⁸

Childhood and School Age

Lennox–Gastaut Syndrome

Clinical Description

The description of a severe childhood epilepsy and its electroencephalographic features described by Lennox and Davis in 1950 and by Gastaut et al in 1966 led to the definition of Lennox–Gastaut syndrome as part of the epileptic encephalopathies in childhood.^{59,60} The diagnostic criteria of typical Lennox–Gastaut syndrome consist of

1. Multiple epileptic seizures including axial tonic, atonic, and atypical absence seizures
2. Electroencephalogram abnormalities with frontally accentuated bursts of slow spike-waves during wakefulness and bursts of fast rhythmic activity during sleep
3. A slowness in intellectual growth and associated personality disorders^{8,61}

The age at onset is 3 to 6 years. Lennox–Gastaut syndrome may be preceded by nonepileptic and/or epileptic encephalopathy, such as Ohtahara or West syndrome. Drop attacks from axial tonic or (myoclonic-) atonic seizures are among the predominating seizure types together with atypical absence seizures and nonconvulsive status epilepticus.^{8,61} Nearly all patients have severe intellectual disability and refractory epilepsy. In addition, there may be significant overlap with other epileptic encephalopathies, such as Dravet syndrome, epilepsy with myoclonic-atonic seizures, Angelman syndrome, and others.

As pharmacoresistance is a predominant feature of Lennox–Gastaut syndrome, a combination of several antiepileptic drugs is usually inevitable with valproic acid, lamotrigine, topiramate, and benzodiazepines being of value, as well as rufinamide (and the cautiously used felbamate) are frequently prescribed drugs.⁶¹ The literature about pharmacotherapy in Lennox–Gastaut syndrome seems to reflect more the innovations of the antiepileptics than a formal therapeutic approach, and it is still debatable whether to reduce or increase the antiepileptic medications in affected individuals with refractory seizures.⁸

Genetics

The etiology of Lennox–Gastaut syndrome comprises a broad range of structural, metabolic, and primarily monogenetic pathologies, as well as tumor, infection, trauma, and intoxication. However, both structural malformations (e.g., cortical dysgenesis, neuronal migration disorders) and metabolic disorders (including mitochondriopathies) may similarly have been caused by monogenetic defects.

Genes that have been repeatedly associated with Lennox–Gastaut syndrome comprise *SCN1A*, *GABRB3*, *CHD2*, and *DNM1*.^{42,43,62} Single Lennox–Gastaut syndrome cases have also been reported to show mutations in *MAPK10*, *ALG13*, *SCN2A*, *SCN8A*, *RYR3*, and *ST3GAL3*. Some of those genes have been associated with West syndrome too, reflecting its transition into Lennox–Gastaut syndrome.

Epilepsy with Myoclonic–Atonic Seizures (Doose Syndrome, MAE)

Clinical Description

Epilepsy with myoclonic–atonic seizures is a generalized epilepsy and belongs to the myoclonic epilepsies of childhood.¹ It was first described by Kruse (1968) and Doose (1970) and occurs with an explosive onset in otherwise healthy children with a male predominance.^{63,64} Myoclonic seizures that can be subtle and difficult to recognize followed by an atonic, postmyoclonic phase are the hallmark of the syndrome, leading to typical drop attacks or head-nodding attacks. Patients also display generalized tonic–clonic, tonic, and atypical absence seizures (►Fig. 5). The onset is usually around age 1 to 5 years.⁶⁵ The seizures are often difficult to treat, and besides valproic acid and ethosuximide, ketogenic diet has shown to help in epilepsy with myoclonic–atonic seizures. The seizure outcome is very good, with 90% of patients becoming seizure free within 3 years. The cognitive outcome is highly variable, with up to 40% developing mild to severe intellectual disability.⁶⁵

Genetics

Little is known on the etiology of epilepsy with myoclonic–atonic seizures. Fourteen to 32% of affected children have a family history of idiopathic epilepsy.⁶⁶ A few children resembling epilepsy with myoclonic–atonic seizures belong to large

GEFS+ families carrying *SCN1B* missense mutations.⁶⁷ Other cases may carry mutations in *SLC2A1*.⁶⁸ A recent study identified six individuals carrying *de novo* mutations in *SLC6A1* among 160 MAE patients (4%).⁶⁹ Additionally, one out of 39 MAE patients (2.5%) was found to carry a *de novo* mutation in *KCNA2*.⁷⁰

Epileptic Encephalopathy with Continuous Spike-and-Wave during Sleep and Landau–Kleffner Syndrome

Clinical Description

This is a disorder with intellectual disability and language deficits associated with a subclinical EEG pattern during sleep, first described by Patry et al in 1971, and referred to “epileptic encephalopathy with continuous spike-and-wave during sleep” by Tassinari et al in 1977.^{71–73} Together with the acquired epileptic aphasia / Landau–Kleffner syndrome, continuous spike-and-wave during sleep is recognized as an electroclinical syndrome by the ILAE.¹ Both syndromes share the main features of marked sleep activation of mainly focal epileptic discharges into a continuous or near-continuous spike-and-wave pattern together with a regression in different aspects of development.⁸ The degree of bioelectrical status during sleep remains a controversial topic. The diagnosis is considered in patients with (1) spike-and-wave pattern occupying more than 85% of nonrapid eye-movement sleep for more than a month, or (2) a significant increase of

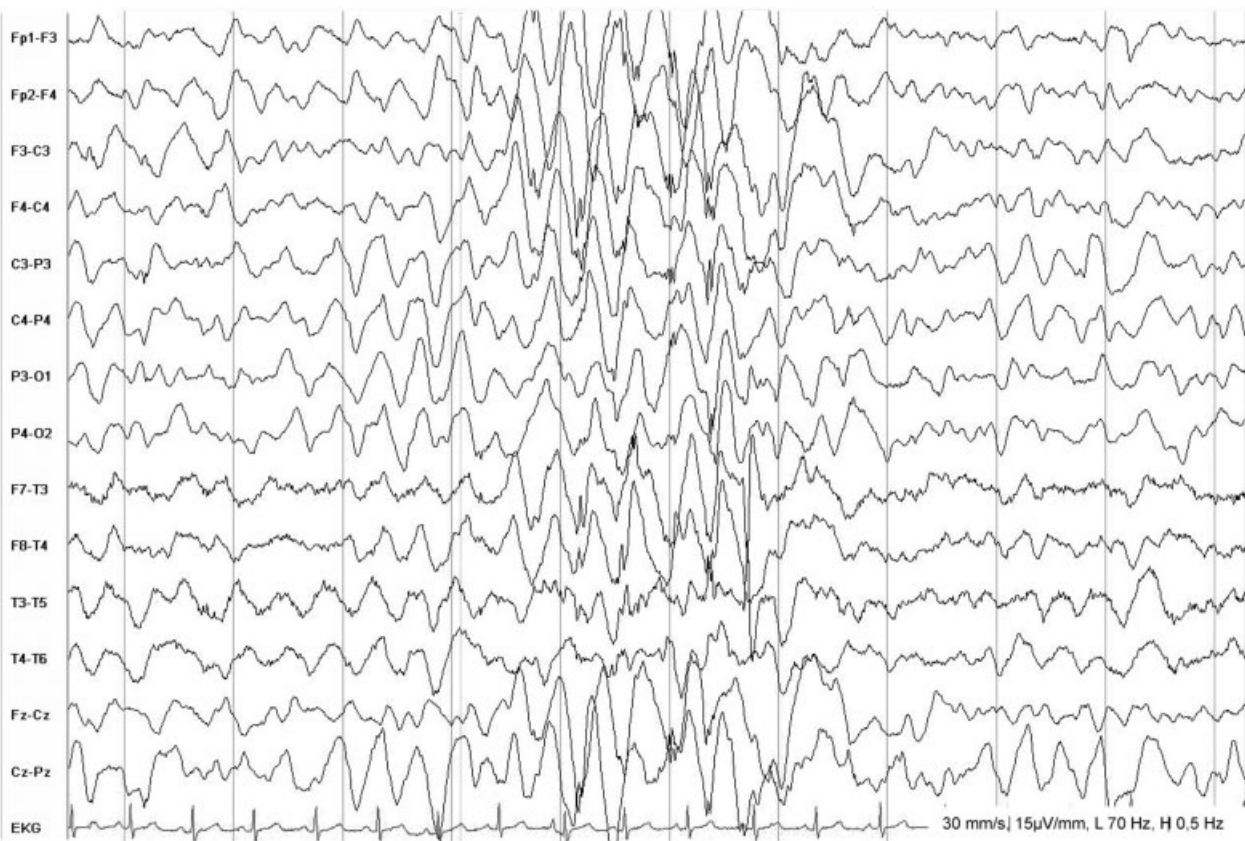


Fig. 5 Electroencephalogram (EEG) of a 4-year-old girl with idiopathic epilepsy with myoclonic–atonic seizures displaying slowing of background activity and typical generalized spikes and polyspikes. Polyspikes are the EEG correlate of myoclonic seizures while the following slow wave correlates with the atonic component.

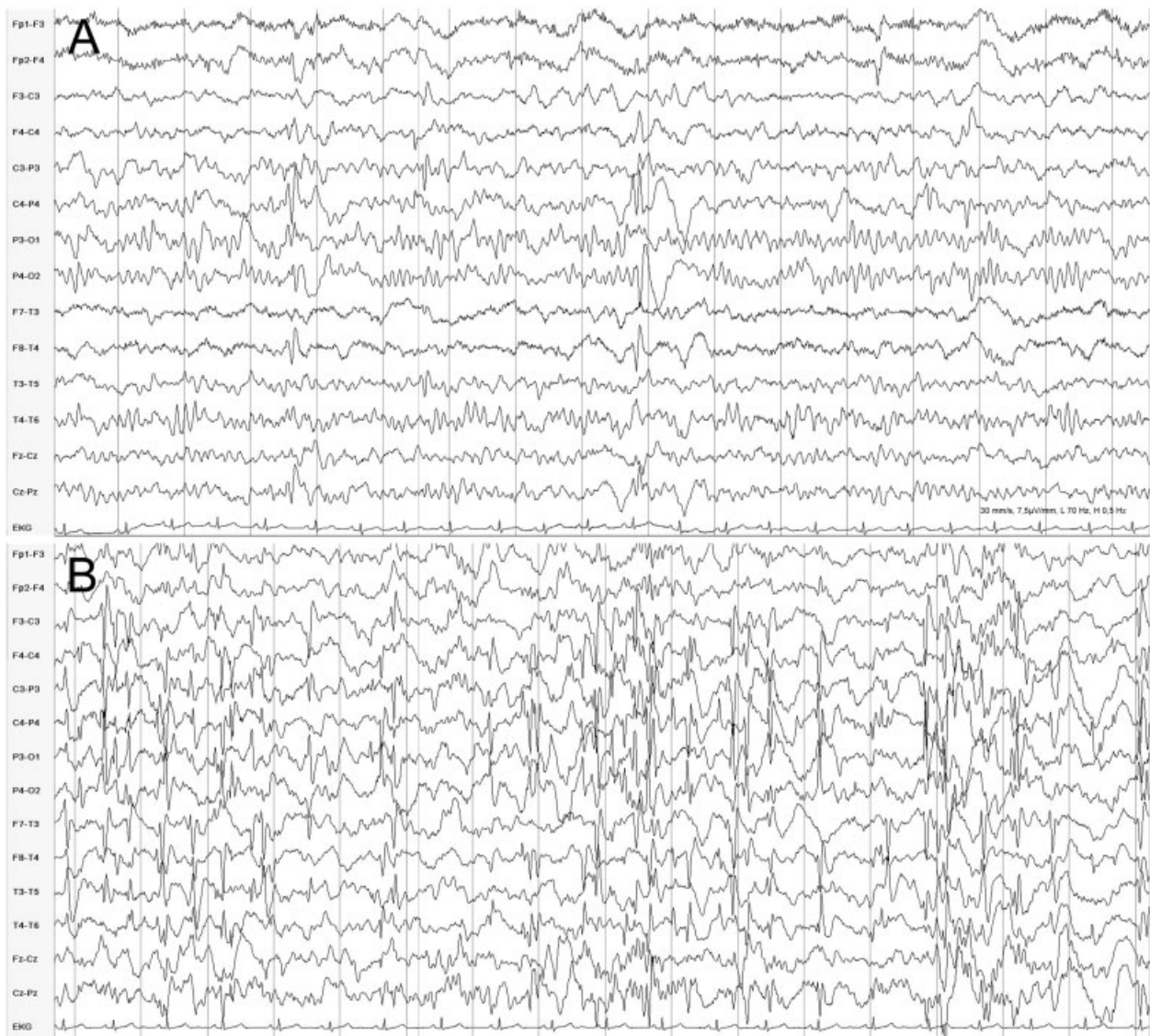


Fig. 6 Electroencephalogram during wakefulness (A) and sleep in a 7-year-old boy, initially referred for attention-deficit-hyperactivity disorder. Multifocal singular sharp waves (A) are markedly activated during sleep into a pattern of near-continuous spike-and-wave activity (B). Despite several treatment trials including sulthiame, levetiracetam, oxcarbazepine, and methylprednisolone, the continuous spike-and-wave during sleep pattern remained. His learning disabilities became apparent and school performance declined significantly. The genetic diagnosis remains unclear.

EEG abnormalities during sleep associated with intellectual and behavioral impairment, as well as language deficits and transient motor impairment (► Fig. 6).^{8,72,73}

Continuous spike-and-wave during sleep and Landau-Kleffner syndrome belong to the spectrum of genetic focal epilepsies of childhood with overlap to benign epilepsy with centrotemporal (rolandic) spikes.⁷⁴ One-third to one-half of children with continuous spike-and-wave during sleep have neurologic abnormalities before disease onset, with mainly pre- or perinatally acquired brain lesions.^{8,72,73} In the other half, genetic factors most likely contribute to the phenotype. Landau-Kleffner syndrome occurs in previously healthy children aged 2 to 8 years. Half of affected children develop seizures as the first symptom of disease; the other half show exclusively progressive linguistic disturbances that commonly start with an inability

to understand spoken words that evolves into sensory and expressive aphasia (► Fig. 7).

Seizures are infrequent in continuous spike-and-wave during sleep and Landau-Kleffner syndrome. This is particularly so in continuous spike-and-wave during sleep, where they can occur before and after diagnosis with mainly nocturnal focal seizures but also generalized tonic-clonic and absence seizures. Treatment options include all classical antiepileptic medications; however, most authors suggest trying sulthiame, benzodiazepines alone, or combined with valproic acid and corticosteroids.⁷³ The continuous spike-and-wave during sleep pattern and seizures usually remit in puberty. Simultaneously, neuropsychological function may improve; residual impairment correlates with the length of continuous spike-and-wave during sleep and early age at diagnosis.^{8,72}

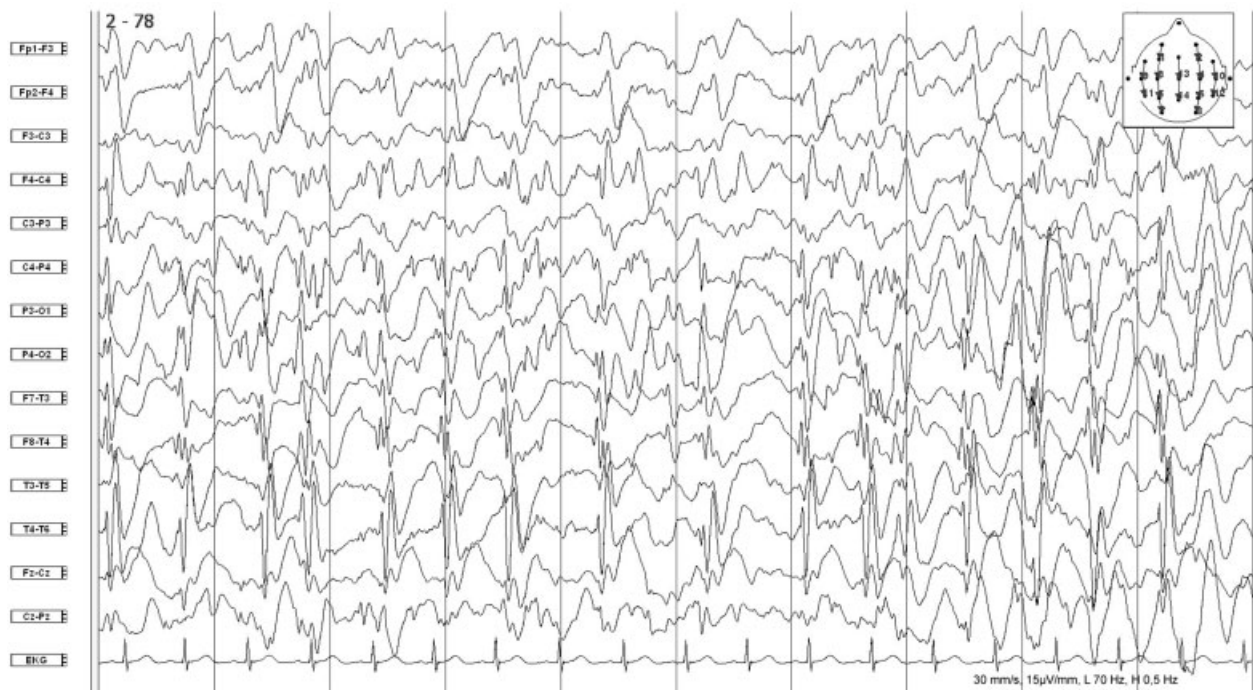


Fig. 7 Continuous spike-and-wave pattern during sleep-onset nonrapid eye-movement sleep in a boy with Landau-Kleffner syndrome. At the age of 4 years the caregivers observed progressive limitation of speech recognition followed by deterioration of expressive speech. Communication was finally restricted to manual gestures. After use of sulthiame, levetiracetam, and dexamethasone over 2 years, the continuous spike-and-wave during sleep pattern resolved and verbal communication resumed. At the age of 14, although his electroencephalogram is normal, he has mild speech and mental impairment.

Genetics

Individuals with idiopathic focal epilepsy may also have relatives with epilepsy. However, the severity and clinical presentation may vary considerably between affected individuals, even within the same family. Mutations in *GRIN2A*, a gene encoding the NMDA receptor subunit GluN2A has recently been identified to account for up to 20% of cases with continuous spike-and-wave during sleep and Landau-Kleffner syndrome.^{75–77} Mutation detection rates were higher in familial compared with isolated cases. In 5 to 10% of cases with milder epilepsies of the same spectrum, such as atypical partial epilepsy and benign epilepsy with centrotemporal spikes, the individual disorder has similarly been assigned to mutations in *GRIN2A*.⁷⁵

Discussion

The ILAE classification is a pragmatic grouping of the heterogeneous spectrum of epileptic encephalopathies defined by clinical and electroclinical characteristics that are “reliably identified,” but do not reflect the specific etiology.¹ There is no differentiation of channelopathies, synaptopathies, or epileptic encephalopathies due to structural anomalies, though this could have significant implications for prognosis and therapeutic decisions. As an example, seizures in Ohtahara syndrome due to *STXBP1* or *KCNQ2* mutations may reduce in frequency during infancy, and they may require other therapeutic strategies when compared with *ARX*-related burst-suppression epilepsy associated with abnormal gyration. Likewise, the transition from Ohtahara into West

syndrome and from West into Lennox-Gastaut syndrome has been well described in numerous cases. Thus, a patient with Lennox-Gastaut syndrome may previously have had Ohtahara and West syndrome, and may therefore be etiologically very different from other Lennox-Gastaut syndrome patients without such history. Hence, without genetic classification of an epileptic encephalopathy, the prognosis on the individual course and treatment outcome of the disorder remains empirical. Furthermore, physicians are often confronted with patients suffering from less distinct epileptic encephalopathy phenotypes that can barely be assimilated into the current ILAE schemes.

The phenotypic series of early infantile epileptic encephalopathy according to OMIM represents a quite different way to group epileptic encephalopathies. In contrast to Ohtahara et al, OMIM uses the term early infantile epileptic encephalopathy not only for neonatal epilepsy with a specific EEG pattern and marked developmental delay,¹³ but for a far broader spectrum of disorders with onset within the first year of life (→ **Table 1**). Within this phenotypic series, epilepsy aspects are barely considered, allowing for a more comprehensive delineation of the phenotype (beyond epilepsy) attributed to a specific gene. As an example, early infantile epileptic encephalopathy-4 (EIEE4) is caused by mutations in *STXBP1* and may result in (1) Ohtahara syndrome, (2) West syndrome, (3) Dravet syndrome, (4) severe epilepsy without distinct EEG features, (5) nonsyndromal intellectual disability without seizures, and (6) autism spectrum disorders and others.^{20,54,78} The OMIM phenotypic series does not include epileptic encephalopathy phenotypes with onset beyond the

first year of life. Therefore, both the ILAE and the OMIM classification only depict a narrow spectrum out of the broad group of epileptic encephalopathies.

An alternative to established classifications might be a system primarily focusing on genetic aspects and only secondarily, on phenotypic features. Onset, phenotypic appearance, and severity would have less importance compared with pathophysiology and its implications on possible therapeutic aspects as well as prognostic assertions. Overlap and transition of different phenotypes within one genetic entity would also be better acknowledged by a classification primarily considering genetic etiology. Moreover, emphasis on pathophysiology reflects the increasing importance of personalized therapy in patients with epileptic encephalopathy. Several therapies can help by specifically targeting individual genetic defects, such as quinidine in *KCNT1* encephalopathy,^{79,80} retigabine in *KCNQ2* encephalopathy,⁸¹ memantine in *GRIN2A* encephalopathy,⁸² and the ketogenic diet in *SLC2A1*-related epilepsy. Thus, genetic testing can significantly influence clinics and therapy of epileptic encephalopathy; it can be expected that this development will increasingly gain importance in the years to come.

References

- Berg AT, Berkovic SF, Brodie MJ, et al. Revised terminology and concepts for organization of seizures and epilepsies: report of the ILAE Commission on Classification and Terminology, 2005-2009. *Epilepsia* 2010;51(4):676-685
- Mizrahi EMM. Early severe neonatal and infantile epilepsies. In: Bureau M, Genton P, Dravet CH, Delgado-Escueta AV, Tassinari CA, Thomas P, Wolf P, eds. *Epileptic Syndromes in Infancy, Childhood and Adolescence*. 5th ed. London: John Libbey Eurotext Ltd; 2012
- Aicardi J, Goutieres F. [Neonatal myoclonic encephalopathy (author's transl)]. *Rev Electroencephalogr Neurophysiol Clin* 1978; 8(1):99-101
- Aicardi J. Epilepsy in brain-injured children. *Dev Med Child Neurol* 1990;32(3):191-202
- Plecko B. Pyridoxine and pyridoxalphosphate-dependent epilepsies. *Handb Clin Neurol* 2013;113:1811-1817
- Ohtahara S, Yamatogi Y. Epileptic encephalopathies in early infancy with suppression-burst. *J Clin Neurophysiol* 2003;20(6): 398-407
- Murakami N, Ohtsuka Y, Ohtahara S. Early infantile epileptic syndromes with suppression-bursts: early myoclonic encephalopathy vs. Ohtahara syndrome. *Jpn J Psychiatry Neurol* 1993; 47(2):197-200
- Panayiotopoulos CP. *The epilepsies: seizures, syndromes and management*. Oxfordshire, UK: Bladon Medical Publishing; 2005
- Hirose M, Haginoya K, Yokoyama H, et al. Functional cortical deafferentation from the subcortical structures in a patient with early myoclonic encephalopathy: a functional neuroimaging study. *Epilepsia* 2010;51(4):699-702
- Ohtahara S, Yamatogi Y. Ohtahara syndrome: with special reference to its developmental aspects for differentiating from early myoclonic encephalopathy. *Epilepsy Res* 2006;70(Suppl 1): S58-S67
- Backx L, Ceulemans B, Vermeesch JR, Devriendt K, Van Esch H. Early myoclonic encephalopathy caused by a disruption of the neuregulin-1 receptor ErbB4. *Eur J Hum Genet* 2009;17(3): 378-382
- Kato M, Saito H, Murakami Y, et al. PIGA mutations cause early-onset epileptic encephalopathies and distinctive features. *Neurology* 2014;82(18):1587-1596
- Ohtahara S, Ishida T, Oka E, Yamatogi Y, Inoue H. On the specific age dependent epileptic syndrome: the early-infantile epileptic encephalopathy with suppression-burst. *No To Hattatsu* 1976; 8:270-279
- Yamatogi Y, Ohtahara S. Early-infantile epileptic encephalopathy with suppression-bursts, Ohtahara syndrome; its overview referring to our 16 cases. *Brain Dev* 2002;24(1):13-23
- Kato M, Saito H, Kamei A, et al. A longer polyalanine expansion mutation in the ARX gene causes early infantile epileptic encephalopathy with suppression-burst pattern (Ohtahara syndrome). *Am J Hum Genet* 2007;81(2):361-366
- Giordano L, Sartori S, Russo S, et al. Familial Ohtahara syndrome due to a novel ARX gene mutation. *Am J Med Genet A* 2010; 152A(12):3133-3137
- Uyanik G, Aigner L, Martin P, et al. ARX mutations in X-linked lissencephaly with abnormal genitalia. *Neurology* 2003;61(2): 232-235
- Guerrini R, Moro F, Kato M, et al. Expansion of the first PolyA tract of ARX causes infantile spasms and status dystonicus. *Neurology* 2007;69(5):427-433
- Weckhuysen S, Holmgren P, Hendrickx R, et al. Reduction of seizure frequency after epilepsy surgery in a patient with STXBP1 encephalopathy and clinical description of six novel mutation carriers. *Epilepsia* 2013;54(5):e74-e80
- Deprez L, Weckhuysen S, Holmgren P, et al. Clinical spectrum of early-onset epileptic encephalopathies associated with STXBP1 mutations. *Neurology* 2010;75(13):1159-1165
- Weckhuysen S, Mandelstam S, Suls A, et al. *KCNQ2* encephalopathy: emerging phenotype of a neonatal epileptic encephalopathy. *Ann Neurol* 2012;71(1):15-25
- Weckhuysen S, Ivanovic V, Hendrickx R, et al; *KCNQ2* Study Group. Extending the *KCNQ2* encephalopathy spectrum: clinical and neuroimaging findings in 17 patients. *Neurology* 2013;81(19): 1697-1703
- Saito H, Kato M, Osaka H, et al. CASK aberrations in male patients with Ohtahara syndrome and cerebellar hypoplasia. *Epilepsia* 2012;53(8):1441-1449
- Nakamura K, Koderia H, Akita T, et al. De Novo mutations in GNAO1, encoding a Gαo subunit of heterotrimeric G proteins, cause epileptic encephalopathy. *Am J Hum Genet* 2013;93(3):496-505
- Coppola G, Plouin P, Chiron C, Robain O, Dulac O. Migrating partial seizures in infancy: a malignant disorder with developmental arrest. *Epilepsia* 1995;36(10):1017-1024
- Coppola G. Malignant migrating partial seizures in infancy: an epilepsy syndrome of unknown etiology. *Epilepsia* 2009;50 (Suppl 5):49-51
- McTague A, Appleton R, Avula S, et al. Migrating partial seizures of infancy: expansion of the electroclinical, radiological and pathological disease spectrum. *Brain* 2013;136(Pt 5):1578-1591
- Barcia G, Fleming MR, Deligniere A, et al. De novo gain-of-function *KCNT1* channel mutations cause malignant migrating partial seizures of infancy. *Nat Genet* 2012;44(11):1255-1259
- Ishii A, Shioda M, Okumura A, et al. A recurrent *KCNT1* mutation in two sporadic cases with malignant migrating partial seizures in infancy. *Gene* 2013;531(2):467-471
- Ohba C, Kato M, Takahashi S, et al. Early onset epileptic encephalopathy caused by de novo *SCN8A* mutations. *Epilepsia* 2014; 55(7):994-1000
- Poduri A, Heinzen EL, Chitsazzadeh V, et al. *SLC25A22* is a novel gene for migrating partial seizures in infancy. *Ann Neurol* 2013; 74(6):873-882
- Dhamija R, Wirrell E, Falcao G, Kirmani S, Wong-Kisiel LC. Novel de novo *SCN2A* mutation in a child with migrating focal seizures of infancy. *Pediatr Neurol* 2013;49(6):486-488

- 33 Coppola G, Veggiotti P, Del Giudice EM, et al. Mutational scanning of potassium, sodium and chloride ion channels in malignant migrating partial seizures in infancy. *Brain Dev* 2006;28(2):76–79
- 34 Lux AL, Osborne JP. A proposal for case definitions and outcome measures in studies of infantile spasms and West syndrome: consensus statement of the West Delphi group. *Epilepsia* 2004;45(11):1416–1428
- 35 Jóźwiak S, Kotulska K, Domańska-Pakieła D, et al. Antiepileptic treatment before the onset of seizures reduces epilepsy severity and risk of mental retardation in infants with tuberous sclerosis complex. *Eur J Paediatr Neurol* 2011;15(5):424–431
- 36 Nabbutt R, Dulac O. Epileptic encephalopathies: a brief overview. *J Clin Neurophysiol* 2003;20(6):393–397
- 37 Mettin RR, Merckenschlager A, Bernhard MK, et al. Wide spectrum of clinical manifestations in children with tuberous sclerosis complex—follow-up of 20 children. *Brain Dev* 2014;36(4):306–314
- 38 Osborne JP, Lux AL, Edwards SW, et al. The underlying etiology of infantile spasms (West syndrome): information from the United Kingdom Infantile Spasms Study (UKISS) on contemporary causes and their classification. *Epilepsia* 2010;51(10):2168–2174
- 39 Paciorkowski AR, Thio LL, Dobyns WB. Genetic and biologic classification of infantile spasms. *Pediatr Neurol* 2011;45(6):355–367
- 40 Kurian MA, Meyer E, Vassallo G, et al. Phospholipase C beta 1 deficiency is associated with early-onset epileptic encephalopathy. *Brain* 2010;133(10):2964–2970
- 41 Edvardson S, Baumann AM, Mühlhoff M, et al. West syndrome caused by ST3Gal-III deficiency. *Epilepsia* 2013;54(2):e24–e27
- 42 Allen AS, Berkovic SF, Cossette P, et al; Epi4K Consortium; Epilepsy Phenome/Genome Project. De novo mutations in epileptic encephalopathies. *Nature* 2013;501(7466):217–221
- 43 Euro E-RESC; EuroEPINOMICS-RES Consortium; Epilepsy Phenome/Genome Project; Epi4K Consortium. De novo mutations in synaptic transmission genes including DNM1 cause epileptic encephalopathies. *Am J Hum Genet* 2014;95(4):360–370
- 44 Lemke JR, Hendrickx R, Geider K, et al. GRIN2B mutations in West syndrome and intellectual disability with focal epilepsy. *Ann Neurol* 2014;75(1):147–154
- 45 Dravet C. Les epilepsies graves de l'enfant. *Vie Med* 1978;8:543–548
- 46 Brunklaus A, Ellis R, Reavey E, Forbes GH, Zuberi SM. Prognostic, clinical and demographic features in SCN1A mutation-positive Dravet syndrome. *Brain* 2012;135(Pt 8):2329–2336
- 47 Dravet C, Bureau M, Oguni H, Cokar O, Guerrini R. Dravet syndrome. (Severe myoclonic epilepsy in infancy). In: Bureau M, Genton P, Dravet CH, Delgado-Escueta AV, Tassinari CA, Thomas P, Wolf P, eds. *Epileptic Syndromes in Infancy, Childhood and Adolescence*. 5th ed. London: John Libbey Eurotext Ltd; 2012
- 48 Dalla Bernardina B, Capovilla G, Gattoni MB, Colamaria V, Bondavalli S, Bureau M. [Severe infant myoclonic epilepsy (author's transl)]. *Rev Electroencephalogr Neurophysiol Clin* 1982;12(1):21–25
- 49 Bureau M, Dalla Bernardina B. Electroencephalographic characteristics of Dravet syndrome. *Epilepsia* 2011;52(Suppl 2):13–23
- 50 Orosz I, McCormick D, Zamponi N, et al. Vagus nerve stimulation for drug-resistant epilepsy: a European long-term study up to 24 months in 347 children. *Epilepsia* 2014;55(10):1576–1584
- 51 Rodda JM, Scheffer IE, McMahon JM, Berkovic SF, Graham HK. Progressive gait deterioration in adolescents with Dravet syndrome. *Arch Neurol* 2012;69(7):873–878
- 52 Claes L, Del-Favero J, Ceulemans B, Lagae L, Van Broeckhoven C, De Jonghe P. De novo mutations in the sodium-channel gene SCN1A cause severe myoclonic epilepsy of infancy. *Am J Hum Genet* 2001;68(6):1327–1332
- 53 Depienne C, Bouteiller D, Keren B, et al. Sporadic infantile epileptic encephalopathy caused by mutations in PCDH19 resembles Dravet syndrome but mainly affects females. *PLoS Genet* 2009;5(2):e1000381
- 54 Carvill GL, Weckhuysen S, McMahon JM, et al. GABRA1 and STXBPI1: novel genetic causes of Dravet syndrome. *Neurology* 2014;82(14):1245–1253
- 55 Suls A, Jaehn JA, Kecskés A, et al; EuroEPINOMICS RES Consortium. De novo loss-of-function mutations in CHD2 cause a fever-sensitive myoclonic epileptic encephalopathy sharing features with Dravet syndrome. *Am J Hum Genet* 2013;93(5):967–975
- 56 Nava C, Dalle C, Rastetter A, et al; EuroEPINOMICS RES Consortium. De novo mutations in HCN1 cause early infantile epileptic encephalopathy. *Nat Genet* 2014;46(6):640–645
- 57 Singh NA, Pappas C, Dahle EJ, et al. A role of SCN9A in human epilepsies, as a cause of febrile seizures and as a potential modifier of Dravet syndrome. *PLoS Genet* 2009;5(9):e1000649
- 58 Lemke JR, Riesch E, Scheurenbrand T, et al. Targeted next generation sequencing as a diagnostic tool in epileptic disorders. *Epilepsia* 2012;53(8):1387–1398
- 59 Lennox WG, Davis JP. Clinical correlates of the fast and the slow spike-wave electroencephalogram. *Pediatrics* 1950;5(4):626–644
- 60 Gastaut H, Roger J, Soulayrol R, et al. [Epileptic encephalopathy of children with diffuse slow spikes and waves (alias “petit mal variant”) or Lennox syndrome]. *Ann Pediatr (Paris)* 1966;13(8):489–499
- 61 Crespel A, Gelisse P, Nikanorova M, Ferlazzo E, Genton P. Lennox-Gastaut syndrome. In: Bureau M, Genton P, Dravet CH, Delgado-Escueta AV, Tassinari CA, Thomas P, Wolf P, eds. *Epileptic Syndromes in Infancy, Childhood and Adolescence*. 5th ed. London: John Libbey Eurotext Ltd; 2012
- 62 Lund C, Brodtkorb E, Øye AM, Røsbj O, Selmer KK. CHD2 mutations in Lennox-Gastaut syndrome. *Epilepsy Behav* 2014;33:18–21
- 63 Kruse R. [The myoclonic astatic petit mal. Clinical course of small epileptic seizures in childhood. With an introduction by Prof. Dr. Dietrich Janz]. *Monogr Gesamtgeb Neurol Psychiatr* 1968;124:1–126
- 64 Doose H, Gerken H, Leonhardt R, Völzke E, Völz C. Centrencephalic myoclonic-astatic petit mal. Clinical and genetic investigation. *Neuropadiatrie* 1970;2(1):59–78
- 65 Oguni H, Tanaka T, Hayashi K, et al. Treatment and long-term prognosis of myoclonic-astatic epilepsy of early childhood. *Neuropediatrics* 2002;33(3):122–132
- 66 Kaminska A, Ickowicz A, Plouin P, Bru MF, Dellatolas G, Dulac O. Delineation of cryptogenic Lennox-Gastaut syndrome and myoclonic astatic epilepsy using multiple correspondence analysis. *Epilepsy Res* 1999;36(1):15–29
- 67 Wallace RH, Wang DW, Singh R, et al. Febrile seizures and generalized epilepsy associated with a mutation in the Na⁺-channel beta1 subunit gene SCN1B. *Nat Genet* 1998;19(4):366–370
- 68 Mullen SA, Suls A, De Jonghe P, Berkovic SF, Scheffer IE. Absence epilepsies with widely variable onset are a key feature of familial GLUT1 deficiency. *Neurology* 2010;75(5):432–440
- 69 Carvill GL, McMahon JM, Schneider A, et al. Mutations in the GABA transporter SLC6A1 cause epilepsy with myoclonic-astatic seizures. *Am J Hum Genet* 2015;96(5):808–815
- 70 Syrbe S, Hedrich UB, Riesch E, et al. De novo loss- or gain-of-function mutations in KCNA2 cause epileptic encephalopathy. *Nat Genet* 2015;4(4):393–399
- 71 Patry G, Lyagoubi S, Tassinari CA. Subclinical “electrical status epilepticus” induced by sleep in children. A clinical and electroencephalographic study of six cases. *Arch Neurol* 1971;24(3):242–252
- 72 Tassinari CA, Daniele O, Gambarelli F, Bureau-Paillas M, Robaglia L, Cicerata F. [Excessive 7-14-sec positive spikes during REM sleep in monozygotic non-epileptic twins with speech retardation (author's transl)]. *Rev Electroencephalogr Neurophysiol Clin* 1977;7(2):192–193

- 73 Tassinari CA. Encephalopathy related to status epilepticus during slow sleep (ESES) including Landau-Kleffner syndrome. In: Bureau M, Genton P, Dravet CH, Delgado-Escueta AV, Tassinari CA, Thomas P, Wolf P, eds. *Epileptic Syndromes in Infancy, Childhood and Adolescence*. 5th ed. London: John Libbey Eurotext Ltd; 2012
- 74 Tovia E, Goldberg-Stern H, Ben Zeev B, et al. The prevalence of atypical presentations and comorbidities of benign childhood epilepsy with centrotemporal spikes. *Epilepsia* 2011;52(8):1483–1488
- 75 Lemke JR, Lal D, Reinthaler EM, et al. Mutations in GRIN2A cause idiopathic focal epilepsy with rolandic spikes. *Nat Genet* 2013;45(9):1067–1072
- 76 Lesca G, Rudolf G, Bruneau N, et al. GRIN2A mutations in acquired epileptic aphasia and related childhood focal epilepsies and encephalopathies with speech and language dysfunction. *Nat Genet* 2013;45(9):1061–1066
- 77 Carvill GL, Regan BM, Yendle SC, et al. GRIN2A mutations cause epilepsy-aphasia spectrum disorders. *Nat Genet* 2013;45(9):1073–1076
- 78 Rauch A, Wieczorek D, Graf E, et al. Range of genetic mutations associated with severe non-syndromic sporadic intellectual disability: an exome sequencing study. *Lancet* 2012;380(9854):1674–1682
- 79 Milligan CJ, Li M, Gazina EV, et al. KCNT1 gain of function in 2 epilepsy phenotypes is reversed by quinidine. *Ann Neurol* 2014;75(4):581–590
- 80 Bearden D, Strong A, Ehnott J, DiGiovine M, Dlugos D, Goldberg EM. Targeted treatment of migrating partial seizures of infancy with quinidine. *Ann Neurol* 2014;76(3):457–461
- 81 Orhan G, Bock M, Schepers D, et al. Dominant-negative effects of KCNQ2 mutations are associated with epileptic encephalopathy. *Ann Neurol* 2014;75(3):382–394
- 82 Pierson TM, Yuan H, Marsh ED, et al; PhD for the NISC Comparative Sequencing Program. GRIN2A mutation and early-onset epileptic encephalopathy: personalized therapy with memantine. *Ann Clin Transl Neurol* 2014;1(3):190–198