

The History of Pseudotumor Cerebri Syndrome among “Courses” and “Recourses”

Martino Ruggieri¹ Vincenzo Salpietro^{2,3} Conrad E. Johanson⁴

¹Department of Clinical and Experimental Medicine, University of Catania, Catania, Italy

²Department of Pediatric Neurology, Chelsea and Westminster Hospital, Imperial College, London, United Kingdom

³Department of Pediatrics, University of Messina, Messina, Italy

⁴Department of Neurosurgery, Brown University, Providence, Rhode Island, United States

Address for correspondence Martino Ruggieri, BA, MD, PhD, Department of Clinical and Experimental Medicine, University of Catania, via Santa Sofia 78, Catania, Italy (e-mail: m.ruggieri@unict.it).

J Pediatr Neurol 2015;13:3–7.

Abstract

The terms “pseudotumor cerebri” and “benign intracranial hypertension,” respectively, introduced by Nonne in 1904 and Foley in 1955, were originally used to describe patients with raised intracranial pressure in whom no tumor was found and whose course was considered to be relatively benign. In the modern era of medicine, the natural history of this condition has proved to be not always benign, as some patients with “benign intracranial hypertension” developed permanent blindness. Therefore, Buchheit in 1969 challenged the terms “benign” and “pseudotumor” and the denomination was then changed to “idiopathic intracranial hypertension.” The recently updated diagnostic criteria for this syndrome reintroduced the original terminology and proposed to define the condition as “pseudotumor cerebri syndrome.” The aim of this umbrella term is to encompass all the potential etiologies, primary and secondary, of increased intracranial pressure not associated with intracranial mass and/or anomalies of the brain parenchyma. In this article, we briefly review the history of pseudotumor cerebri syndrome.

Keywords

- ▶ idiopathic intracranial hypertension
- ▶ pseudotumor cerebri
- ▶ history

Introduction

The disease now most frequently referred to as pseudotumor cerebri syndrome (PTCS), according to the most recent diagnostic criteria,¹ has been known by various names since its first clinical descriptions: pseudotumor cerebri, benign intracranial hypertension (BIH), and idiopathic intracranial hypertension (IIH).² These terms were introduced, respectively, by Nonne,³ Foley,⁴ and Buchheit et al.⁵ The variation in nomenclature reflects the unclear etiology of this syndrome. From a historical point of view, the initial recognition of the disease depended on the following two critical steps: (1) invention of the ophthalmoscope by von Helmholtz in 1851⁶ and its application in medical practice and (2) introduction by Quincke⁷ of lumbar puncture, a technique that finally lead

to rigorous measurement of the cerebrospinal fluid (CSF) pressure.

Earliest Descriptions of Pseudotumor Cerebri Syndrome

Authors had previously summarized the first description of this syndrome.^{8,9} One historic key manuscript is a monograph that focused on diseases of the optic nerve, published by The Transactions of the Ophthalmological Society, United Kingdom, in 1880.¹⁰ At that time lumbar puncture was not yet utilized to assess the CSF opening pressure, which later became a fundamental criterion in the diagnosis of PTCS. The earliest descriptions of the PTCS syndrome, lacking the evaluation of CSF pressure, might be regarded as presumptive.

received
November 29, 2014
accepted after revision
February 3, 2015

Issue Theme Pediatric Pseudotumor Cerebri Syndrome; Guest Editors: Vincenzo Salpietro, MD, Martino Ruggieri, PhD, and Conrad E. Johanson, PhD

Copyright © 2015 Georg Thieme Verlag KG Stuttgart · New York

DOI <http://dx.doi.org/10.1055/s-0035-1555144>.
ISSN 1304-2580.

However, some of the early reports were highly suggestive of PTCS, because of the description of the typical symptoms (e.g., headache, diplopia) in the context of specific fundoscopic findings (i.e., papilledema) on the background of known PTCS-related risk factors (e.g., female gender, obesity, endocrine derangements).¹⁰ Notably, in the 19th century, papilledema was usually referred to as optic neuritis.^{8,11}

From a long chapter published in 1880,¹⁰ we know that Dr. Hughlings Jackson¹⁰ mentioned reports regarding "...a recoverable optic neuritis in young women suffering from uterine derangement..." In 1881, Gowers¹² described "optic neuritis," likely associated with iron deficiency anemia, a disorder now identified as an important risk factor for PTCS. In an article published in 1900,¹³ Williamson and Roberts¹³ reported 100 cases of "double optic neuritis" associated with headache; in this group of patients they assessed a higher prevalence of female gender, obesity, and menstrual irregularities. However, the earliest clinical descriptions pointing to PTCS seem to have been authored by Sir William Broadbent,¹⁴ a neurologist born in 1835 in West Yorkshire. Indeed, Dr. Broadbent¹⁴ described in 1872, a 12-year-old girl admitted to St. Mary hospital in London because of a 2-year history of headache and papilledema (referred by him as "choked disc" [→Fig. 1]), on a background of menstrual irregularities. Her symptoms resolved after menstrual regularity was restored, although she remained blind from the sequel of the papilledema.

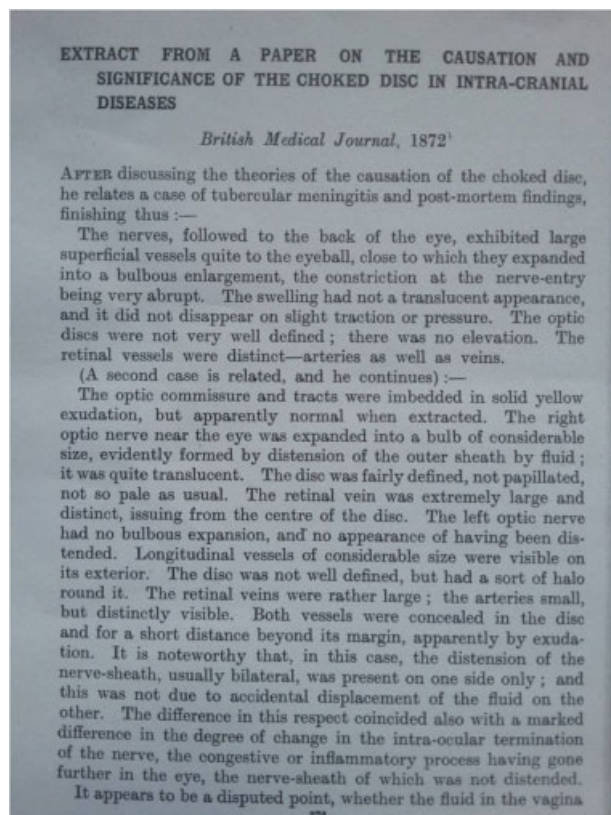


Fig. 1 Extract from a paper on the cause and significance of the choked disc in intracranial diseases published by Sir William Henry Broadbent in the *British Medical Journal* in 1872.

Sir William Broadbent (→Fig. 2) studied Medicine in the Royal School of Medicine in Manchester and worked for most of his career at St Mary's Hospital in London (1859–1896). Broadbent was a leading British authority at that time in the field of cardiology and neurology. In 1881, he was elected President of the London Medical Society and in 1887, the President of the Clinical Society of London. In 1891, Broadbent¹⁵ helped to save the life of Prince George (the future King George V) from typhoid fever. In 1893, he was created a Baronet by Queen Victoria and, later, was appointed a Knight Commander of the Royal Victorian Order in March 1901.¹⁵

The History of a Syndrome among Courses and Recourses

The articles by Quincke^{16,17} and Nonne,³ spanning the years 1893 to 1904, initiated the concept of PTCS as a specific disease entity. Despite the earliest description of a non-tumor-related increase of intracranial pressure (ICP) (see section *Earliest Descriptions of PTCS*), the first report of PTCS, documented by elevated CSF opening pressure during lumbar puncture, was ascribed to Quincke¹⁶; he described it in 1893 under the name "meningitis serosa." Quincke (→Fig. 3) was born in Frankfurt-an-der-Oder. He studied Medicine in Berlin, Wurzburg and Heidelberg, and became a doctor in 1863. Virchow was his most important mentor. Quincke was the first to characterize anaphylaxis-related angioedema, a condition that was later defined as "Quincke edema."

Quincke was also the pioneer of lumbar puncture: he described this procedure at the 10th Congress of Internal




Fig. 2 Sir William Henry Broadbent (January 23, 1835, Huddersfield, West Yorkshire–July 10, 1907, London).



Fig. 3 Dr. Heinrich Irenaeus Quincke (August 26, 1842, Frankfurt an der Oder–May 19, 1922, Frankfurt am Main).



Fig. 4 Dr. Max Nonne (January 13, 1861, Hamburg–August 12, 1959, Hamburg).

Medicine in Wiesbaden during April 1891.⁷ Through lumbar puncture, he was also the first clinician able at that time to measure intracranial pressure.¹⁸ He deeply studied the CSF circulation and, by injecting the red sulfide of mercury into the subarachnoid space of rabbits, was also the first to demonstrate the CSF flow.^{9,18} Quincke attributed the clinical features of headache and visual disturbance, of what is today known as PTCS, to an elevation of ICP. He also thought that increased CSF production was the cause of the observed rise of ICP. Finally, he also understood some of the first PTCS-related comorbidities/risk factors, including head injury, pregnancy, infections, and otitis media.¹⁰ Patients followed up by Quincke¹⁶ complained of headache and visual disturbances, coupled with papilledema and increased ICP pressure, as documented by lumbar puncture. Overall, Quincke¹⁷ reported 10 cases suggestive of PTCS (seven females, three males) and remarked on the female preponderance.

Max Nonne (→**Fig. 4**) was a German neurologist in Hamburg. His most important mentor was Wilhelm Heinrich Erb, the neurologist who first described brachial plexus palsy, also known as “Erb-Duchenne” palsy. In the history of PTCS, Nonne had the distinction of introducing his original work by the still-remaining term “pseudotumor cerebri” (→**Fig. 5**); this term described the constellation of signs and symptoms related to raised ICP but without any intracranial tumor.³ He reported in 1904 on 18 patients with signs suggesting PTCS,¹⁹

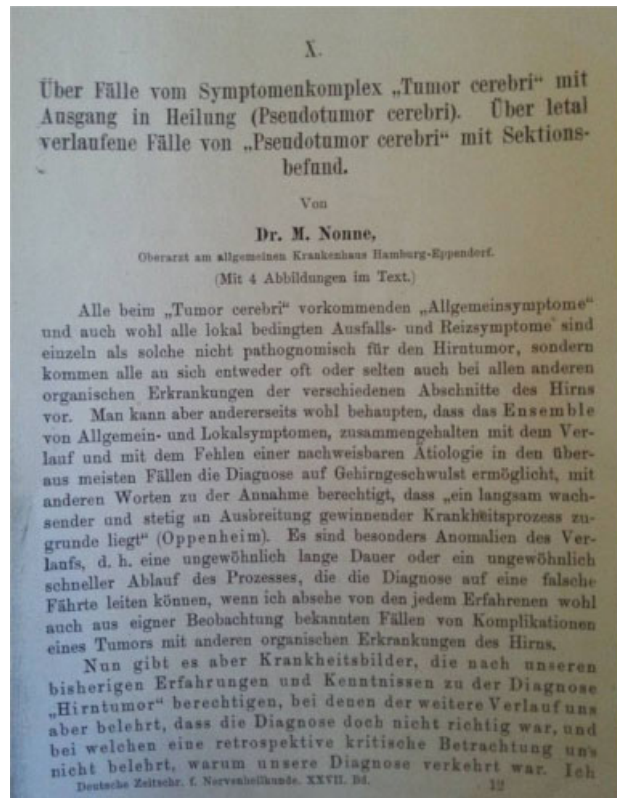


Fig. 5 Title page of the original article published by Dr. Max Nonne in 1904, where he introduced for the first time the term “pseudotumor cerebri.”

although their clinical characteristics did not fulfill the actual diagnostic criteria.

In the 1930s, Symonds²⁰ reported on children who developed signs of elevated ICP in association with middle ear infection. He was strongly impressed by the large amount of CSF drained by lumbar puncture. Symonds²⁰ hypothesized that an “increased ICP due to the presence of an excess of normal CSF” might follow a middle ear disease which impairs sinus venous drainage. He, therefore, defined this condition as “otitic hydrocephalus,” reflecting the increase in CSF volume in the ventricular system.⁸ He also recommended diversion of CSF by lumbar puncture as the best treatment choice in these patients.²⁰

In subsequent years, the introduction of radiological techniques, such as ventriculography and angiography, allowed the exclusion of any significant expansion in the ventricular system of these patients.⁸ In fact, Dyke and Davidoff²¹ were the first to describe a series of adult and pediatric patients, with signs and symptoms suggestive of PTCS, in whom the lack of any ventricular dilatation on ventriculography was demonstrated. They used the term “hypertensive meningeal hydrops”²¹ to define the condition of intracranial hypertension characterized by normal findings on ventriculography, in place of the term “otitic hydrocephalus” coined by Symonds. Dandy²² also reported a large series of patients with signs and symptoms of intracranial hypertension in whom ventriculography showed the absence of ventricular dilatation. He, therefore, confirmed the conclusion of Dyke and Davidoff. Dandy used the term “intracranial pressure without brain tumor” to describe the disease and was the first to propose diagnostic criteria for this condition.²³ He also hypothesized on the underlying pathophysiology and proposed that changes in cerebral circulation were responsible for the raised ICP, rather than an increase of CSF volume.

The first author who recognized a possible metabolic-endocrine pathophysiological basis for the condition was Thomas²⁴ in 1933; he understood that obese young women were particularly prone to develop this raised ICP syndrome, likely, due to some endocrine disturbances affecting CSF and cerebral circulation dynamics. Joynt and Sahs²⁵ in 1957 demonstrated intracellular and extracellular edema on brain biopsy samples obtained from patients with raised ICP syndrome. Following their study, there was a growing perception of cerebral edema as the cause of intracranial hypertension. Accordingly, diuretics (acetazolamide) and corticosteroids were started in the treatment of these patients.

Foley⁴ in 1955 introduced the term “BIH,” which became the most commonly term used to define this condition in the next several decades. In the subsequent years, with progress in neuro-ophthalmological examinations, the natural history of this condition proved to be not always benign, as some patients with “BIH” developed permanent blindness; consequently, the conventional designation at that time was changed to “IIH.”⁵ Ironically, in recent years, the nomenclature of this syndrome has been changed from “IIH” to “PTCS,”¹ the original term used by Nonne more than a century ago.

Notably, in 1955, Foley outlined some of the peculiar findings of PTCS: “The most important symptoms being headache of moderate degree, obscurations of vision, diplopia, and sometimes tinnitus; marked papilledema and abducens palsies are the only signs, the CSF is normal in composition and the prognosis is almost invariably good, the condition subsiding within a few weeks or months.” Interestingly, Foley was also interested in explaining the underlying pathophysiology of the syndrome and in 1955 suggested that: “...an underlying endocrine imbalance, with presumably a disturbance of electrolytes, is in some way connected with the alteration of intracranial pressure.”⁴ These concepts became meaningful again in contemporary times. In fact, recently great attention has been directed toward the role of CSF electrolyte imbalances due to endocrine derangements in PTCS. Indeed, some authors suggest that an impaired endocrine-metabolic homeostasis plays an universal etiological role in explaining most cases of primary PTCS related to well known risk factors (e.g., female gender, obesity, adrenal disorders, recombinant growth hormone therapy, and vitamin A imbalance).^{26–28} However, further studies are needed to explain the elevation of ICP in this historically mysterious but yet fascinating and challenging disease.

References

- 1 Friedman DI, Liu GT, Digre KB. Revised diagnostic criteria for the pseudotumor cerebri syndrome in adults and children. *Neurology* 2013;81(13):1159–1165
- 2 Peng KP, Fuh JL, Wang SJ. High-pressure headaches: idiopathic intracranial hypertension and its mimics. *Nat Rev Neurol* 2012; 8(12):700–710
- 3 Nonne M. “Über fälle vom symptomkomplex “tumor cerebri” mit ausgang in heilung (pseudotumor cerebri). *Dtsch Z Nervenheilkd* 1904;27:169–216
- 4 Foley J. Benign forms of intracranial hypertension; toxic and otitic hydrocephalus. *Brain* 1955;78(1):1–41
- 5 Buchheit WA, Burton C, Haag B, Shaw D. Papilledema and idiopathic intracranial hypertension. *N Engl J Med* 1969;280(17): 938–942
- 6 Lepore FE. Toward a definition of papilledema: a historical review, 1851–1911. *Surg Neurol* 1982;17(3):178–180
- 7 Quincke HI. Die technik der lumbalpunktion. *Verh Dtsch Ges Inn Med* 1891;10:321–331
- 8 Johnston I. The historical development of the pseudotumor concept. *Neurosurg Focus* 2001;11(2):E2
- 9 Pearce JM. From pseudotumor cerebri to idiopathic intracranial hypertension. *Pract Neurol* 2009;9(6):353–356
- 10 Hughlings J. Discussion on the relation between optic neuritis and intracranial disease. *Trans Ophthalmol Soc U K* 1880–1881;(1): 60–115
- 11 Taylor J. Diseases of the optic nerve. *Trans Ophthalmol Soc U K* 1894;(14):105–119
- 12 Gowers WR. Optic neuritis in chlorosis. *BMJ* 1881;1(1064): 796–797
- 13 Williamson RT, Roberts E. Remarks on the diagnosis and prognosis in 100 cases of double optic neuritis with headache. *Lancet* 1900; (1):1350–1352
- 14 Broadbent WH. On the causation and significance of the choked disc in intracranial diseases. *BMJ* 1872;1(598):633–635
- 15 Broadbent ME. London: John Murray; 1909

- 16 Quincke H. Meningitis serosa. Sammi Klin Vortr, Leipzig, No 67. *Inn Med* 1893;23:655–662
- 17 Quincke H. Ueber Meningitis serosa und verwandte Zustände. *Dtsch Z Nervenheilkd* 1897;9:149–168
- 18 Pearce JMS. *Fragments of neurological history*. London: Imperial College Press; 2003
- 19 Nonne M. Über fälle vom symptomkomplex “tumor cerebri” mit ausgang in heilung (pseudotumor cerebri). Ü ber letal verlaufene fälle von “pseudotumor cerebri” mit sektionsbefund. *J Neurol* 1904;27(3–4):169–216
- 20 Symonds CP. Otitic hydrocephalus. *Brain* 1931;54(1):55–71
- 21 Davidoff LM, Dyke CG. Hypertensive meningeal hydrops: syndrome frequently following infection in the middle ear or elsewhere in the body. *Am J Ophthalmol* 1937;20(9):908–927
- 22 Dandy WE. Intracranial pressure without brain tumor: diagnosis and treatment. *Ann Surg* 1937;106(4):492–513
- 23 Spennato P, Ruggiero C, Parlato RS, et al. Pseudotumor cerebri. *Childs Nerv Syst* 2011;27(2):215–235
- 24 Thomas WA. Generalised edema occurring only at the menstrual period. *JAMA* 1933;(101):1126–1127
- 25 Joynt RJ, Sahs AL. Brain swelling of unknown cause. *Neurology* 1956;6(11):801–803
- 26 Salpietro V, Polizzi A, Di Rosa G, et al. Adrenal disorders and the paediatric brain: pathophysiological considerations and clinical implications. *Int J Endocrinol* 2014;2014:282489
- 27 Salpietro V, Ruggieri M. Pseudotumor cerebri pathophysiology: the likely role of aldosterone. *Headache* 2014;54(7):1229
- 28 Sheldon CA, Kwon YJ, Liu GT, McCormack SE. An integrated mechanism of pediatric pseudotumor cerebri syndrome: evidence of bioenergetic and hormonal regulation of cerebrospinal fluid dynamics. *Pediatr Res* 2015;77(2):282–289