

Functional Outcomes of Nerve Reconstruction in Severe Obstetric Brachial Plexus Palsy

P. S. Bhandari¹

¹Department of Plastic and Reconstructive Surgery, Army Hospital (Research and Referral), Udhampur, Jammu and Kashmir, India

Address for correspondence P. S. Bhandari, MCh (Plastic Surgery), Department of Plastic and Reconstructive Surgery, Army Hospital (Research and Referral), Udhampur, Jammu and Kashmir 182101, India (e-mail: doctorbhandari@hotmail.com).

Indian J Neurotrauma 2015;12:41–48.

Abstract

Background Microsurgical era has brought a renewed interest in the management of birth-related brachial plexus palsy. There is a general agreement that severe obstetric palsy should be treated by an early nerve reconstruction.

Patients and Methods This report is an experience in the primary nerve reconstruction in 32 cases of obstetric brachial plexus lesions in the age group 3.5 to 23 months. Parietal injuries were most commonly associated with truncal neuromas. Conducting neuromas were subjected to neurolysis, whereas nonconducting neuromas were treated by resection and nerve grafting. Restoration of hand functions was a priority in total lesions. In total palsy, a viable root stump if available was connected with nerve grafts to the distal nerve, primarily targeted toward the hand, and nerve transfers were performed for shoulder and elbow.

Results A total of 20 patients had C5, C6 injuries and 5 had an associated C7 injury. Seven patients presented with total palsy. The follow-up period ranged from 14 to 42 months. Patients with partial palsy and early surgical intervention produced good functional results in relation to the elbow and shoulder. Recovery in hand function in total palsy was satisfactory to poor.

Conclusion Microsurgical reconstruction is indicated for those infants who fail to recover antigravity biceps flexion by 4 to 6 months of age. An early intervention by 3 months is desirable in total palsy.

Keywords

- ▶ obstetric palsy
- ▶ nerve reconstruction
- ▶ functional outcomes

Introduction

Obstetric brachial plexus palsy (OBPP) is a traction neural injury sustained during the course of the birth process. The severity of injury can fall within a wide spectrum and is the key determinant of prognosis and the need for intervention. The incidence of OBPP ranges globally from 0.5 to 2 per 1,000 births¹ with the higher numbers in under developed countries. Perinatal risk factors include high-birth-weight infants with macrosomia, multiparous pregnancies, assisted (vacuum or forceps) deliveries, and shoulder dystocia.^{2,3} A majority of them progress to complete recovery. Others may improve slowly but incompletely.

The rate of complete, spontaneous recovery varies in the literature from 30 to 95%.^{2,4} This variation correlates directly with the different injury types.

Narakas⁵ have categorized OBPP in four groups. Group I refers to C5 and C6 involvement, the classic Erb palsy. Majority of the cases (46%) fall in this group and is associated with the most favorable prognosis. Group II occurs approximately in 30% of the cases and refers to C5, C6, and C7 involvement. Group II injury carries an inferior prognosis than C5 and C6 injuries alone. Group III refers to a total paralysis with flail extremity and occurs in approximately 20% of patients. Group IV injury, the most severe form, is characterized by a flail extremity with Horner syndrome, and carries the worst prognosis.

received
November 19, 2014
accepted
November 26, 2014
published online
December 10, 2014

© 2015 Neurotrauma Society of India

DOI <http://dx.doi.org/10.1055/s-0035-1555661>.
ISSN 0973-0508.

Microsurgical treatment of obstetrical brachial plexus lesions is a relatively young field of surgical expertise. There is a great disparity among experts in the determination of surgical indications in partial palsy. This is attributed to relatively incomplete understanding of the natural history of obstetric palsy. Physicians still advise the parents to adhere to the physiotherapy program that ultimately leaves many children with significant disabilities.^{1,6} Contrary to this, in total palsy, the general consensus is toward an early surgical reconstruction.

This study highlights the functional gains achieved following microsurgical reconstruction in severe grades of obstetric brachial plexus injuries.

Patients and Methods

Patients

This report is an experience in the primary nerve reconstruction of 32 cases of severe obstetric brachial plexus lesions, in the age group 3.5 to 23 months. These babies with no significant improvement were treated in a tertiary care center in the period between February 2007 and June 2012. Vaginal route with vertex presentation was the most common mode of delivery. The average birth weight at the time of delivery was 3.6 kg. The inclusion criteria for surgical exploration and reconstruction consisted of babies in Narakas groups I and II with absent biceps function at 4 months of age, and all babies having total palsy with or without Horner syndrome (Narakas groups III and IV grades). Babies with partial lesions showing steady recovery were excluded from the study.

Preoperative Assessment

Each baby was subjected to a detailed clinical examination. Plain X-ray films of the cervical spine, clavicle, humerus, and chest were obtained. Magnetic resonance imaging (MRI) of the supra- and infraclavicular brachial plexus, with babies under mild sedation, was utilized as one of the main diagnostic tools. All babies were investigated by myelography using Siemens magnetom 3T in which three-dimensional (3D) data were reconstructed with 1 mm sections in axial, coronal, and sagittal planes. Presence of pseudomeningoceles indicated root avulsions. The diagnostic accuracy was 78% when 3D MRI reports were compared with intraoperative findings. MRI study also delineated extraforaminal lesions, such as, neuroma, ruptures, and perineural edema.

Motor power in affected limb was assessed according to Toronto Muscle Grading System (–Table 1).

No objective sensory assessment was done as we believe that loss of sensory function is a rarity or nonexistent in obstetric palsy. Relevant clinical and surgical details were noted for all the cases.

Surgical Procedure

With the baby placed in supine position, an exploration of brachial plexus was performed under general anesthesia through a reverse C-shaped incision starting along the

Table 1 Toronto muscle grading system

Muscle grade ^a	Description
0	No contraction
1	Contraction—no motion
2	Motion \leq ½ range, gravity eliminated
3	Motion $>$ ½ range, gravity eliminated
4	Full motion, gravity eliminated
5	Motion \leq ½ range, against gravity
6	Motion $>$ ½ range, against gravity
7	Full motion, against gravity

^aA muscle grade is given to every joint movement at the shoulder, elbow, forearm, wrist, fingers, and thumb.

posterior border of lower part of sternocleidomastoid muscle and then continuing above and parallel to the clavicle (–Fig. 1). General anesthesia was maintained with short-acting muscle relaxants. A nerve stimulator was used at 0.5, 1.0, and 2.0 mA to identify the motor branches throughout the surgical exploration. The upper brachial plexus spinal nerves were generally present in the space between the anterior and middle scalene muscles. Their absence suggested root avulsions. This was correlated with the presence of characteristic pseudomeningoceles on magnetic resonance myelography (–Fig. 2). A common finding was presence of neuroma-in-continuity (–Fig. 3). Use of nerve stimulator helped in establishing their proximal integrity. For the infraclavicular exposure, an incision was made in the deltopectoral groove and extended to the medial aspect of proximal arm. Clavicular osteotomies were not performed in any of the case.

Nerve-Related Procedures

Neurolysis

Neurolysis was indicated for neuroma-in-continuity which was conducted on electrical stimulation.

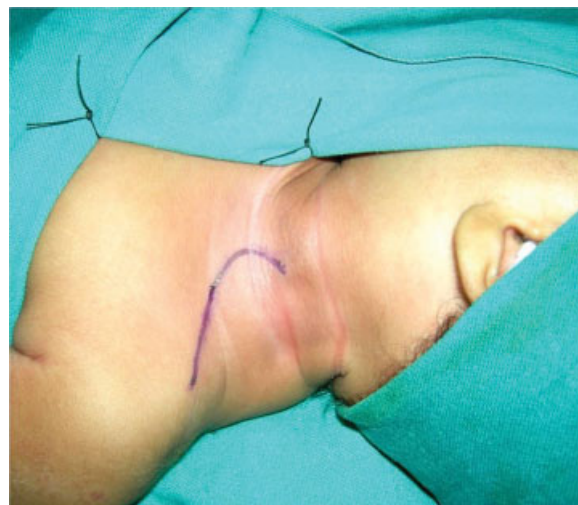

Fig. 1 Incision for supraclavicular exploration.

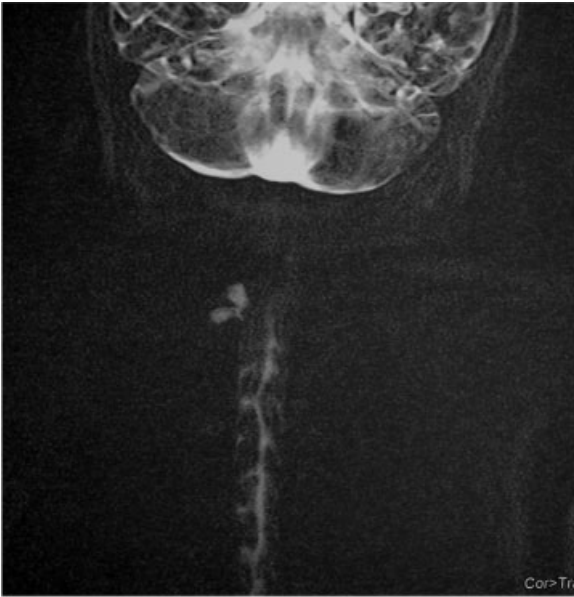

Fig. 2 Magnetic resonance myelography showing pseudomeningoceles.

Nerve Grafts

Nerve grafts were used to bridge the nerve defects, once the nonconducting neuromas were resected (→**Fig. 4**). Sural nerves harvested from one or both legs provided adequate quantity of the graft material. In C5 and C6 injuries, to prevent cocontractions, grafts were preferably directed from C5 nerve root to the posterior division and C6 nerve root to the anterior division of the upper trunk. In high grade injuries, grafts were placed between the intact nerve root or roots and the distal infraclavicular targets. Fibrin glue was used in graft fixation.⁷

Nerve Transfers

Nerve transfers were indicated in avulsion and irreparable nerve root injuries. Multiple donor nerves were used to reactivate the distal targets. Spinal accessory nerve (SAN) was routinely transferred through a dorsal approach to the

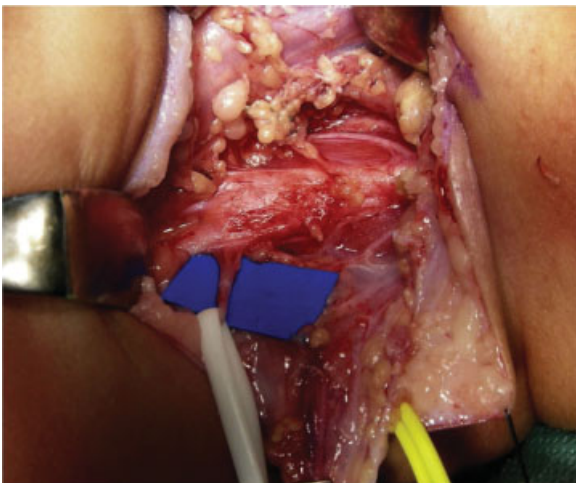


Fig. 3 Neuroma-in-continuity.

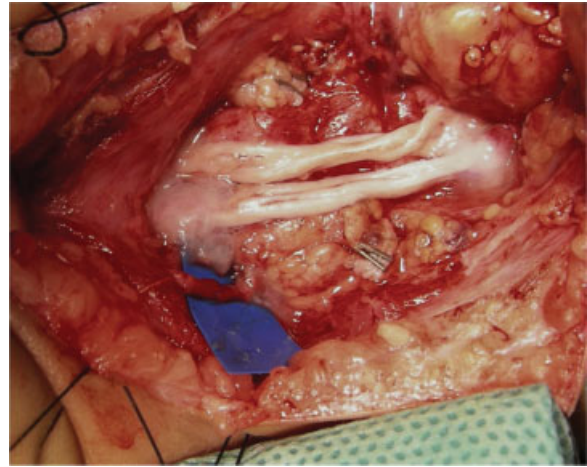


Fig. 4 Intraplexal nerve grafting.

suprascapular nerve (SSN) in restoration of shoulder abduction and external rotation (→**Fig. 5**). This approach⁸ allows nerve transfer close to the target muscles (supraspinatus and infraspinatus muscles) without affecting upper trapezius muscle function. In four cases, 4 to 6 mm nerve segments obtained from the proximal cut end of SAN were submitted for neuropathological and histomorphometric studies to evaluate the adequacy of the myelinated fibers.

Infraclavicular plexus was explored through an incision just medial to the deltopectoral groove and extending into the inner arm. Exposure of the cords and their terminal branches required the division of pectoralis major and minor muscles. For the identification of posterior cord and the axillary nerve, the axillary artery was taped and pulled aside. A semicircular incision was extended from the wound at the anterior border of the axilla on to the infra-areolar region to gain access to the intercostal nerves.⁹ The deep central branches of the third, fourth, and fifth intercostal nerves were used for transfer to the musculocutaneous nerve.

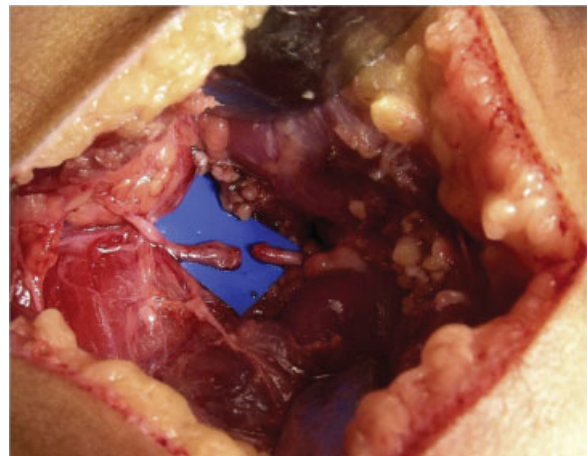


Fig. 5 Spinal accessory nerve to suprascapular nerve transfer by dorsal approach.

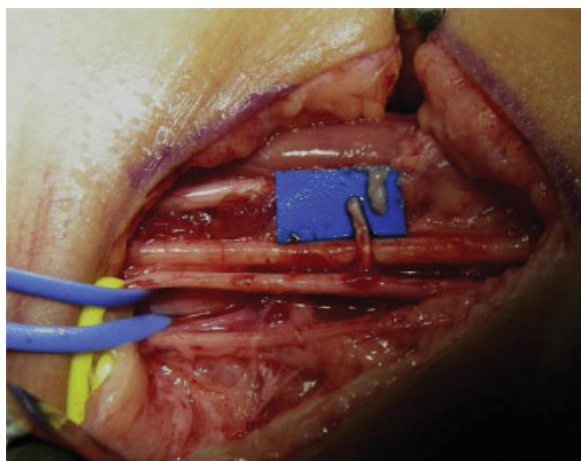


Fig. 6 Oberlin nerve transfer.

Oberlin transfer (partial transfers of the ulnar nerve) was made through a longitudinal incision on the anteromedial aspect of upper arm.¹⁰ The musculocutaneous nerve was identified after it had traversed the coracobrachialis muscle. The ulnar nerve was identified at the same level, and a longitudinal epineurotomy was made. One or two ulnar nerve fascicles were minimally dissected, sectioned (→**Fig. 6**), and coapted to the biceps motor branch with 10–0 nylon suture or fibrin glue.

In all the cases, nerve dissections were performed under $\times 4$ loupe magnification, and nerve coaptations were made under the operating microscope with 10–0 nylon sutures or fibrin glue.

Postoperative Care and Assessment

Postoperatively, the baby was immobilized in a custom made plaster helmet with the arm flexed and strapped to the chest for a period of 4 weeks. After that gradually increasing passive exercises were started in the shoulder, elbow, wrist, and finger joints.

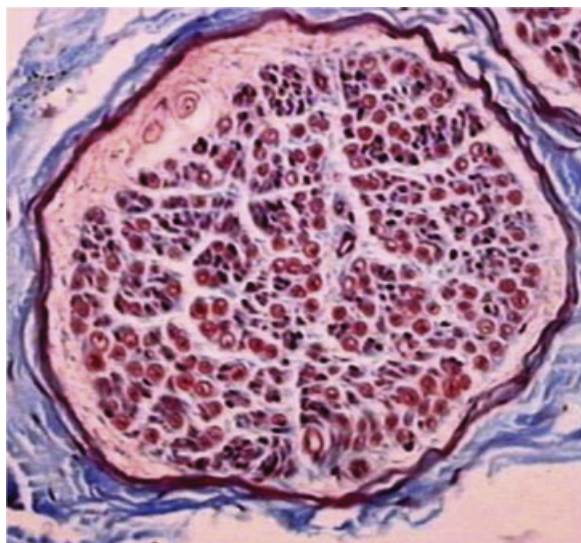


Fig. 7 Hematoxylin and Eosin staining of axons in distal spinal accessory nerve.

Assessment of Shoulder Function

We used the modified Mallet scale, as described by Al-Qattan¹¹ for assessing shoulder external/internal rotation, and a modified Medical Research Council System for assessing other shoulder movements. In the older children, range of abduction was measured with a goniometer by measuring the angle formed between the arm axis and parallel to the spinal cord axis. External rotation was measured with the child standing and completely internally rotating the shoulder, with elbow flexed and forearm placed transversally over the abdomen.

Assessment of Elbow, Forearm, Wrist, and Hand Functions

The range of motion for elbow flexion was measured with a goniometer. Modified Medical Research Council System was used to assess flexion and extension at the elbow and wrist. Hand functions were graded 0 to 5, as described by Al-Qattan.¹¹ Electromyographic (EMG) examinations were not performed because we firmly believe that there is a poor correlation between EMG interference pattern and clinical assessment.

Results

Nerve grafts and nerve transfers were the most common operative procedures, performed in 32 cases with different grades of injuries. Spinal accessory to SSN transfer was performed by dorsal or posterior approach.

Hematoxylin and eosin and Kulschitzky Pal (K Pal) stains were used to assess the myelinated axons in the distal part of SAN (→**Figs. 7** and **8**). A computerized digital photomicrograph system (Digi Eye 330 digital photomicrography camera [Dewinter Optical Inc., New Delhi, India] and Biowizard 4.2 Image analysis software) was utilized to obtain high-resolution photomicrograph of the entire transverse sections of the histopathology specimens. At least, three serial sections of each of the nerve specimens were evaluated. All the myelinated axons present in each of

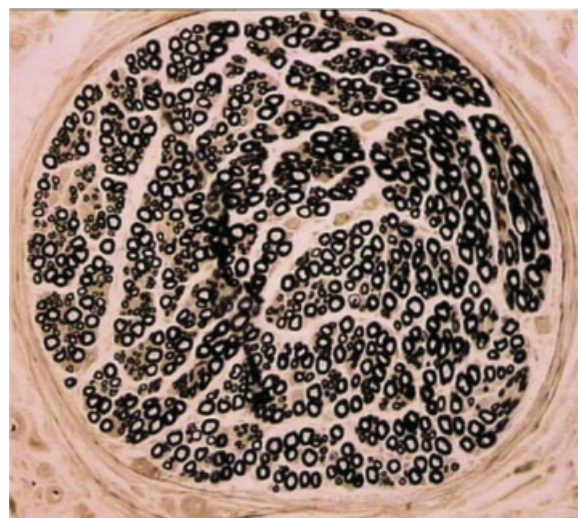


Fig. 8 K Pal stain for myelin status.

Table 2 Histomorphometric analysis of distal spinal accessory nerve (N = 4)

Case number	Number of fascicles	Number of myelinated axons
4	2	1,482
7	3	1,720
9	2	1,650
14	3	1,775

the three serial sections were counted at least three times and an average was considered. Histomorphometric analysis revealed an average axonal count of 1,656 (►Table 2).

In C5 and C6 groups, most of the rupture injuries were located at trunk levels (►Table 3). Results in shoulder and elbow were more favorable when multiple short nerve grafts were placed in the upper truncal region following resection of nonconducting neuromas. Results were far superior with anatomical reconstructions, when nerve grafts were directed from C5 spinal nerve to the posterior division and C6 nerve root to the anterior division of the

Table 3 Patient details and nerve procedures (N = 32)

Case No	Age Months	Diagnosis	Nerve reconstruction
1	4	C5, C6 root ruptures	Anatomical reconstruction
2	5	Upper trunk neuroma, nonconducting	Anatomical reconstruction
3	3.5	Total palsy, C5 root intact	SAN to SSN, 3rd, 4th, and 5th ICN to MCN C5-ng—median nerve
4	6	Extensive fibrosis C5, C6 spinal nerves	SAN to SSN, ulnar nerve fascicle to biceps branch
5	4	C5, C6, C7 ruptured	Anatomical reconstruction SAN to SSN
6	7	Upper trunk neuroma, conducting	Neurolysis, ulnar nerve fascicle to biceps branch
7	23	Total palsy with extensive fibrosis of all roots	SAN to SSN, 3rd, 4th, and 5th ICN to MCN
8	4	Upper trunk neuroma, nonconducting	Anatomical reconstruction, SAN to SSN, ulnar nerve fascicle to biceps branch
9	6	Upper and middle trunk neuroma	Neurolysis upper and middle trunks SAN to SSN
10	9	Total palsy with C5 root intact, C6, C7, C8 avulsed, T1 contused	SAN to SSN, 3rd, 4th, and 5th ICN to MCN C5-ng—median nerve
11	4	Upper trunk neuroma, nonconducting	Anatomical reconstruction
12	7	C5, C6 roots fibrosis	SAN to SSN, ulnar nerve fascicle to biceps branch
13	6	Upper trunk neuroma conducting	Neurolysis
14	5	Upper and middle trunk neuromas	Anatomical reconstruction SAN to SSN
15	6	C5, C6 root ruptures	Anatomical reconstruction
16	5	C5, C6 root fibrosis	SAN to SSN, ulnar nerve fascicle to biceps branch
17	4	Upper trunk neuroma, nonconducting	SAN to SSN, graft reconstruction, ulnar nerve fascicle to biceps branch
18	4	Extensive fibrosis C5, C6, C7 spinal nerves	SAN to SSN, ulnar nerve fascicle to biceps branch
19	11	C5, C6 ruptured	Anatomical reconstruction
20	7	Upper trunk neuroma, conducting	Neurolysis, ulnar nerve fascicle to biceps branch
21	10	Total palsy with extensive fibrosis of all roots	SAN to SSN, 3rd, 4th, and 5th ICN to MCN
22	5	Upper trunk neuroma, nonconducting	Anatomical reconstruction, SAN to SSN, ulnar nerve fascicle to biceps branch
23	6	Total palsy with C5 root intact, C6, C7, C8 avulsed, T1 contused	SAN to SSN, 3rd, 4th, and 5th ICN to MCN C5-ng—median nerve
24	8	Upper trunk neuroma, nonconducting	Anatomical reconstruction
25	6	Upper trunk neuroma, nonconducting	Anatomical reconstruction
26	5	C5, C6 ruptured	Anatomical reconstruction
27	6	Upper trunk conducting neuroma	Neurolysis
28	4	Upper and middle trunk neuromas	Anatomical reconstruction SAN to SSN
29	6	Total palsy with extensive fibrosis of all roots	SAN to SSN, 3rd, 4th, and 5th ICN to MCN
30	6	Upper and middle trunk neuromas	Neurolysis upper and middle trunks SAN to SSN
31	4	Total palsy with C5 root intact, C6, C7, C8 avulsed, T1 contused	SAN to SSN, 3rd, 4th, and 5th ICN to MCN C5-ng—median nerve
32	5	Upper trunk neuroma, nonconducting	Anatomical reconstruction

Abbreviations: ICN, intercostal nerve; MCN, musculocutaneous nerve; Ng, nerve graft; SAN, spinal accessory nerve; SSN, suprascapular nerve.

Table 4 Functional outcomes following nerve reconstruction.

Type	No. of cases	Mean follow-up	Nerve procedure	Results
C5, C6 injury	20	14 mo	Ns, Ng, Nt	At least M3/M5 biceps (94%) shoulder (80%)
C5, C6, C7 injury	5	29 mo	Ns, Ng, Nt	Biceps (75%) shoulder (68%)
C5–T1 injury	7	30 mo	Ng, Nt	Biceps (70%) shoulder (62%)

Abbreviations: Ng, nerve grafting, Ns, neurolysis; Nt, nerve transfer.

upper trunk. However, in both situations, a significant number of patients had developed cocontractions between shoulder and elbow movements. Long nerve grafts interposed between the proximal nerve roots to the distal infraclavicular targets provided poor results. Lesions with extensive fibrosis in C5 and C6 nerve roots were treated by multiple nerve transfers. However, the functional results were inferior to those obtained in “rupture” groups.

In C5, C6, and C7 groups, conducting neuromas were neurolysed, whereas nonconducting neuromas were treated by resection and grafting. In this group, SAN was routinely transferred to the suprascapular nerve. Results in shoulder and

elbow functions were inferior to those obtained in C5 and C6 groups.

In total palsy group (C5–T1), axonal outputs from the available nerve root were directed to the median nerve to regain hand function. In all root avulsions, nerve transfers were performed targeted toward the suprascapular and musculocutaneous nerve. Recovery in elbow flexion was better than shoulder abduction. In hand function, four patients scored 2, one patient scored 3, and remaining two patients scored 1, as per the scoring system described by Al-Qattan.¹¹ Functional results are depicted in ►Table 4 and ►Figs. 9–14.

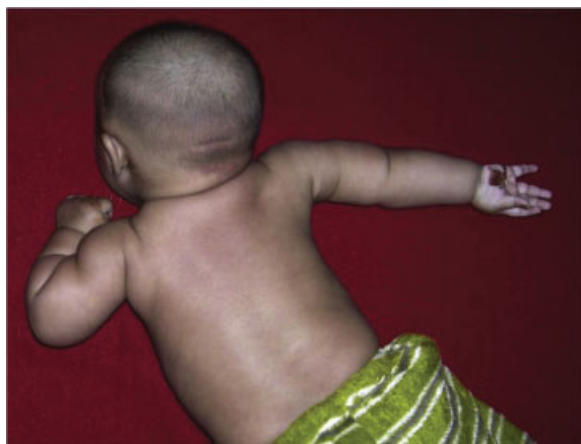

Fig. 9 Erb palsy (right).

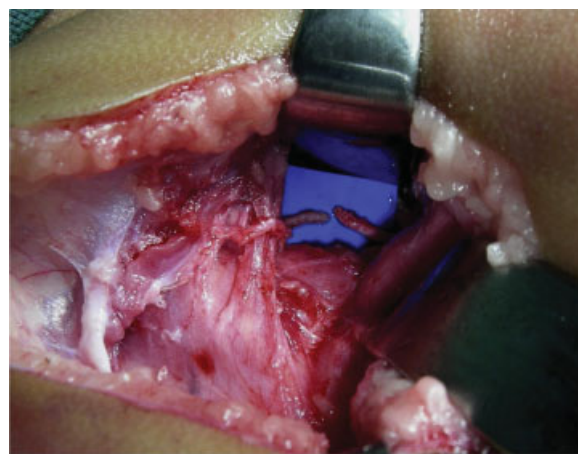


Fig. 11 Spinal accessory to suprascapular nerve transfer by dorsal approach.

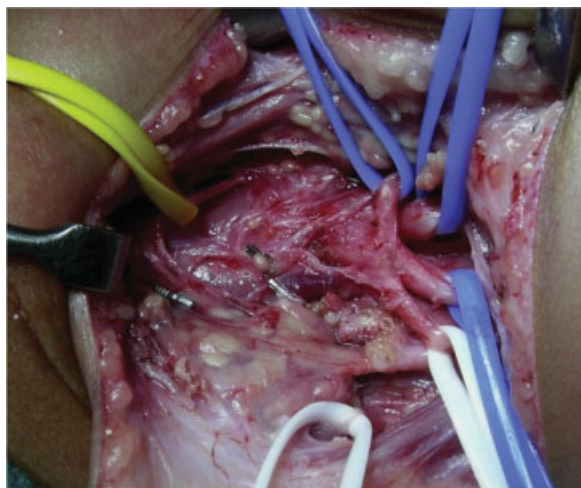


Fig. 10 Extensive fibrosis in C5, C6 roots and upper trunk.

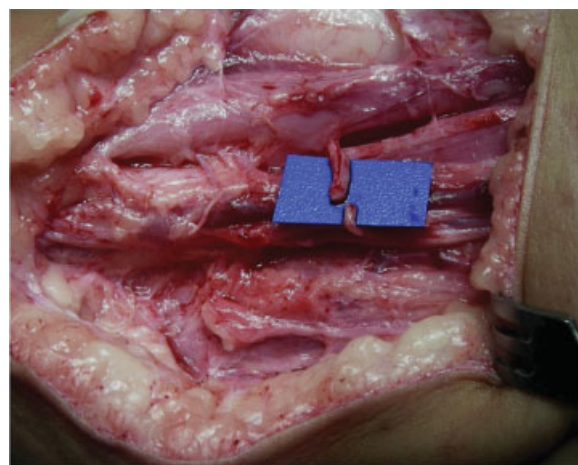


Fig. 12 Oberlin nerve transfer.

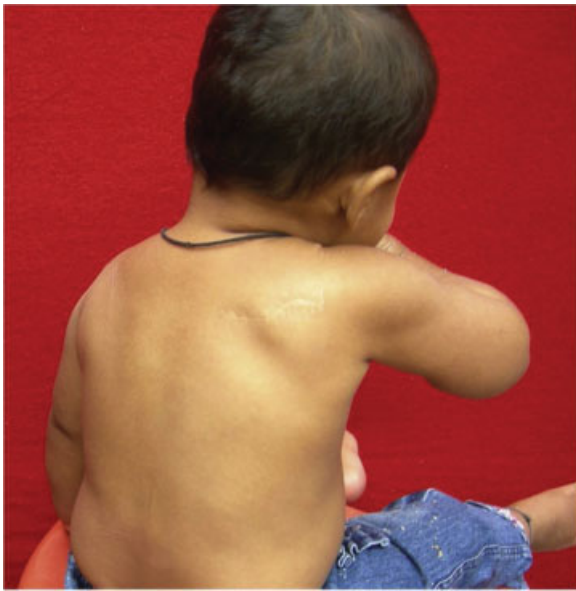

Fig. 13 Restoration of M3 elbow flexion.



Fig. 14 Restoration of good range of shoulder abduction.

Discussion

Historically, OBPP was treated conservatively because a large percentage of patients improve spontaneously and surgical intervention produced poor functional results.¹² Late surgical results were unsatisfactory because there is a critical time period of approximately 2 years during which motor fibres must innervate the appropriate muscles. Hence, inappropriate timing of primary surgery (usually too late) coupled with poor surgical techniques yielded suboptimal functional recovery.

In OBPP, timing of primary surgery is critical, and although most of the injuries improve spontaneously with good functional results, the temptation to wait is outweighed by the time constraints imposed by degenerative changes in the motor end plates. Therefore, children who will ultimately require surgery should be treated as early as possible to optimize reinnervation of denervated muscles. Over the years, surgeons have devised clinical algorithms to guide them in deciding whether and when surgical intervention is required. Gilbert et al^{13,14} concluded that if there is no biceps function at the 3 months of age, surgical intervention should not be delayed further. Other surgeons prefer to operate at 4 months of age.¹⁵ After 12 months of age, the results are disappointing. Therefore, indications for the primary repair are total root avulsion without recovery by 3 months of age, absent motor function in one or more muscle units (deltoid, biceps, and triceps) at 4 to 6 months of age, and muscle grades I to II with no progress at 6 months of age.

Our protocol in obstetric brachial plexus palsy consists of an early repair in total palsy with positive Horner sign. Such babies are explored as early as 3 months of age. In these cases, hand function takes priority and best motor outputs are directed toward the inferior trunk or the median nerve. Those with upper trunk involvement are operated at the age of 4 to 6 months if return in biceps function is poor. We believe that indications for neurolysis in OBPP are very few. Results are far superior with resection of neuroma followed by nerve grafting.¹⁶

An interesting aspect of OBPP is that children presenting as late as 1.5 years also improve following primary nerve reconstruction. At this age group, we prefer anatomical reconstruction supplemented with distal nerve transfers.

Conclusion

We believe that an upper truncal injury with weak elbow flexion but good hand function is not an urgent indication for early exploration. These cases should be observed for 4 to 6 months period of time. However, total hand palsy with positive Horner sign is an urgent indication for an early nerve surgery within 3 months.

Conflicts of Interest

The author has no conflicts of interest to declare.

References

- 1 Eng GD, Binder H, Getson P, et al. Obstetrical brachial plexus palsy (OBPP) outcome with conservative management. *Muscle Nerve* 1996;19:884–891
- 2 Hoeksma AF, ter Steeg AM, Nelissen RG, van Ouwerkerk WJ, Lankhorst GJ, de Jong BA. Neurological recovery in obstetric brachial plexus injuries: an historical cohort study. *Dev Med Child Neurol* 2004;46:76–83
- 3 Water PM. Obstetric brachial plexus injuries: evaluation and management. *J Am Acad Orthop Surg* 1997;5:205–214
- 4 Greenwald AG, Schute PC, Shiveley JL. Brachial plexus birth palsy: a 10 year report on the incidence and prognosis. *J Pediatr Orthop* 1984;4:689–692
- 5 Narakas AO. Injuries of the brachial plexus and neighboring peripheral nerves in vertebral fractures and other trauma of the cervical spine. *Orthopade* 1987;16:81–86
- 6 Rust RS. Congenital brachial plexus palsy: where have we been, and where are we now? *Semin Paediatr Neurol* 2000;7:58–63
- 7 Bhandari PS. Use of fibrin glue in the repair of brachial plexus and peripheral nerve injuries. *Indian J Neurotrauma* 2013; 10:30–32
- 8 Bhandari PS, Deb P. Dorsal approach in transfer of the distal spinal accessory nerve into the suprascapular nerve; histomorphometric analysis and clinical results in 14 cases of upper brachial plexus injuries. *J Hand Surg* 2011;36A:1182–1190
- 9 Bhandari PS, Sadhotra LP, Bhargava P, et al. Effectiveness of intercostal nerves in restoration of elbow flexion in devastating brachial plexus injuries. *Indian J Neurotrauma* 2009;6:53–58
- 10 Bhandari PS, Deb P. Fascicular selection for nerve transfers: the role of the nerve stimulator when restoring elbow flexion in brachial plexus injuries. *J Hand Surg* 2011;36A:2002–2009
- 11 Al-Qattan MM. Obstetric brachial plexus palsy: an experience from Saudi Arabia. *Semin Plast Surg* 2004;18:265–274
- 12 Robotti E, Longhi P, Verna G, Bocchiotti G. Brachial plexus surgery: a historical perspective. *Hand Clin* 1995;11:517–533
- 13 Gilbert A, Razaboni R, Amar-Khodija S. Indications and end results of brachial plexus surgery in obstetrical palsy. *Orthop Clin North Am* 1988;19:91–105
- 14 Gilbert A, Brockman R, Carlioz H. Surgical treatment of brachial plexus birth palsy. *Clin Orthop* 1991;264:39–47
- 15 Michelow BJ, Clarke HM, Curtis CG, Zuker RM, Seifu Y, Andrews DF. The natural history of obstetric brachial plexus palsy. *Plast Reconstr Surg* 1994;94:675–680
- 16 Capek L, Clarke HM, Curtis CG. Neuroma-in-continuity resection: early outcome in obstetric brachial plexus palsy. *Plast Reconstr Surg* 1998;102:1555–1562