

Epidermal Inclusion Cyst after Carpal Tunnel Release: A Case Report

Ho Youn Park, MD¹ Yoo Joon Sur, MD, PhD¹ Yoon Vin Kim, MD¹

¹Department of Orthopedic Surgery, Uijeongbu St. Mary's Hospital, College of Medicine, The Catholic University of Korea, Uijeongbu, Gyeonggi-do, Republic of Korea

Address for correspondence Yoo Joon Sur, MD, PhD, Department of Orthopedic Surgery, Uijeongbu St. Mary's Hospital, College of Medicine, The Catholic University of Korea, 271 Cheonbo-ro, Uijeongbu, Gyeonggi-do, 480-717, Republic of Korea (e-mail: yoojoon@catholic.ac.kr).

J Wrist Surg 2016;5:67–70.

Abstract

Background Carpal tunnel release is one of most commonly performed procedures in upper extremity surgery, with low complication rates.

Case Description We report a case of epidermal inclusion cyst that occurred in a 44-year old man after carpal tunnel release. The epidermal inclusion cyst formed beneath the previous operation scar and induced recurrent carpal tunnel syndrome. Symptoms resolved completely after excision of the cyst.

Literature Review Epidermal inclusion cysts are the third most common type of hand tumors. Although repeated minor trauma is the most frequent cause, surgical procedures can induce an epidermal inclusion cyst. One case report of epidermal inclusion cyst after carpal tunnel release was found in literature. Etiology, treatment, and prevention methods are reviewed.

Clinical Relevance We hope this case report alerts physicians to the possibility of development of epidermal inclusion cyst after carpal tunnel release and the importance of basic surgical skills, such as gentle handling of a surgical wound, profuse saline irrigation, and careful wound closure with precise approximation of skin edges.

Keywords

- ▶ carpal tunnel syndrome
- ▶ carpal tunnel release
- ▶ epidermal inclusion cyst

Carpal tunnel release is one of the most frequently performed surgical procedures in the field of hand and upper extremity surgery and is known to be very effective and safe, with low complication rates.^{1–3} Reported complications include injuries to the recurrent motor branch and palmar cutaneous branch of the median nerve, hypertrophic scar formation, pillar pain, laceration of the superficial palmar arterial arch, incomplete release of the transverse carpal ligament, tendon adhesion, wound infection, finger stiffness, and recurrence.¹ The percentages of structural complications to nerves, arteries, or tendons have been reported to be less than 0.5%.²

Epidermal inclusion cysts can result from various surgical procedures that lead to implantation of epidermal cells into deeper tissues under the dermis, but there are few reports of postoperative occurrences of epidermal inclusion cysts in the hand and wrist. To the best of our knowledge, an epidermal

inclusion cyst caused by carpal tunnel release has been described only once before.⁴

Here we describe a case of epidermal inclusion cyst that occurred after carpal tunnel release. The aim of this report is to introduce this rare complication of carpal tunnel release and emphasize the importance of basic surgical skills, such as gentle handling of a surgical wound, profuse saline irrigation, and careful wound closure with precise approximation of skin edges.

Case Report

A 44-year-old, right-handed man presented with a 1-year history of bilateral (left hand greater than right hand) numbness and pain in the median nerve distribution. Symptoms had aggravated in the 3 months prior to presentation. Electromyography and nerve conduction studies indicated

received

March 18, 2015

accepted

March 21, 2015

published online

November 21, 2015

Copyright © 2016 by Thieme Medical Publishers, Inc., 333 Seventh Avenue, New York, NY 10001, USA.
Tel: +1(212) 584-4662.

DOI <http://dx.doi.org/10.1055/s-0035-1556859>.
ISSN 2163-3916.

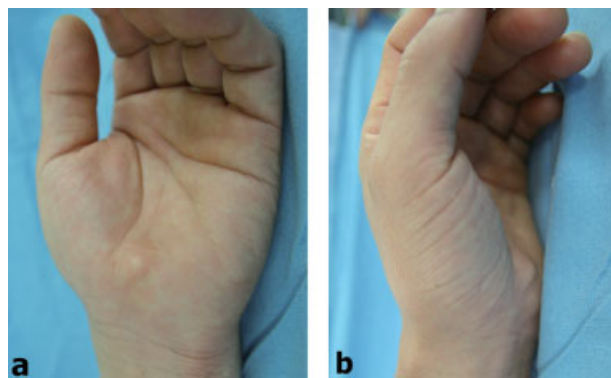


Fig. 1 Preoperative photographs showing an oval, firm, protruding mass on the scar of the previous carpal tunnel release.

bilateral median neuropathies at the wrist with more severe involvement of the left side. We performed mini-open carpal tunnel release on the left side as usual, and the surgical wound was closed with vertical mattress sutures of 3-0 nylon. The postoperative course was uneventful, and the patient stopped follow-up visits with complete resolution of his symptoms 4 months after the surgery. However, 20 months after surgery, he revisited with complaints of a palpable mass at the previous operation site and a tingling sensation in the medial nerve distribution. The mass grew insidiously, and he denied any traumatic episode involving the left hand or wrist after the previous operation. Physical examination revealed a mass beneath the previous operation scar (→ **Fig. 1**). The mass was palpable and firm without signs of infection and had a positive Tinel sign. Ultrasonography demonstrated a 1.0 × 0.8-cm round, well-demarcated, irregular echogenic soft tissue mass under the dermis (→ **Fig. 2**).

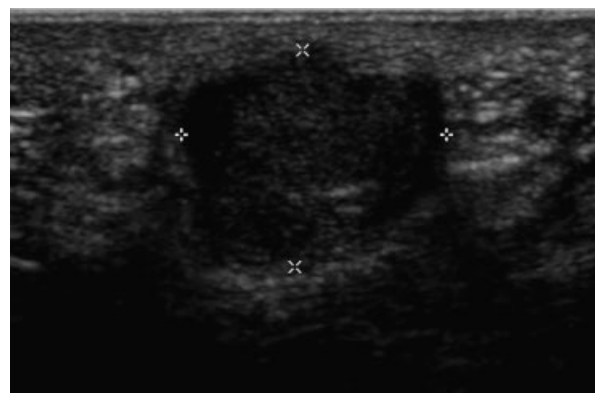

Fig. 2 Ultrasonography showing a round, well-demarcated, irregular echogenic mass under the dermis.

We decided to perform surgical exploration and made a 2-cm skin incision along the previous operation scar. A shiny, white, well-demarcated round mass was found in the subcutaneous tissue layer (→ **Fig. 3**). The mass was easily pulled out. The wound was copiously irrigated and then closed with vertical mattress sutures of 3-0 nylon. Histological examination

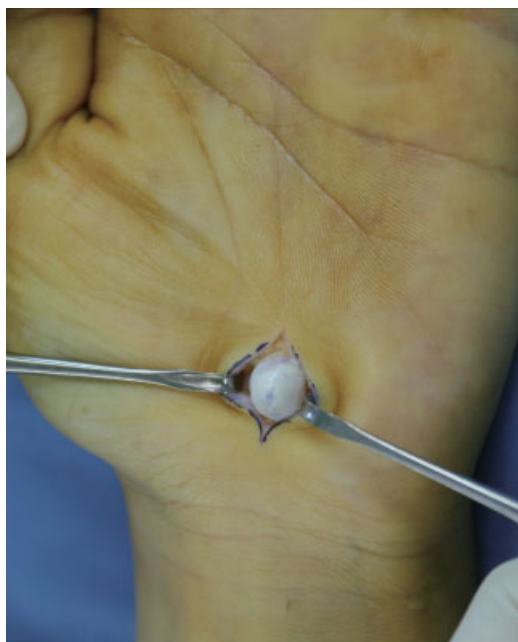

Fig. 3 Intraoperative photographs showing a well-demarcated, round whitish yellow mass.

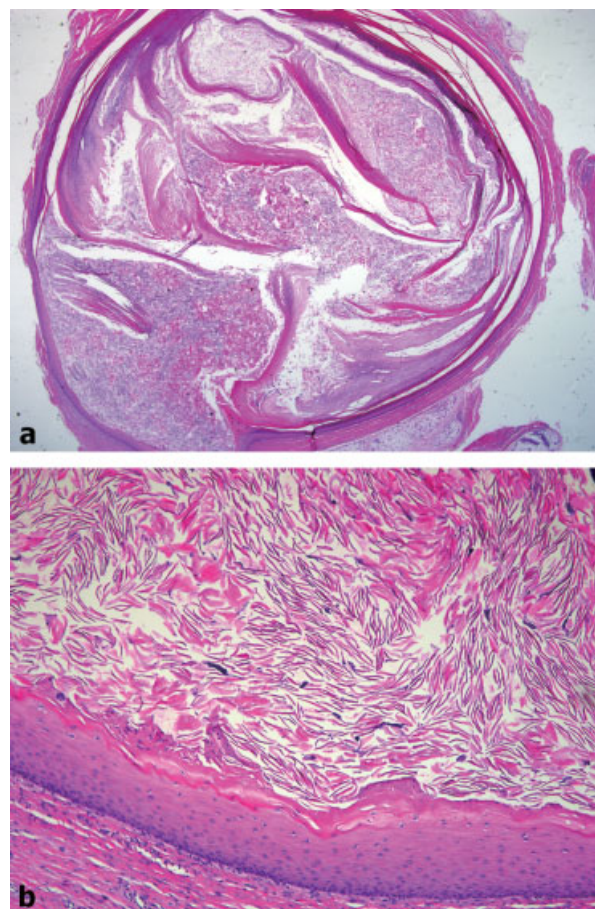


Fig. 4 Photomicrographs of biopsy specimen demonstrating stratified squamous cell epithelial lining and eosinophilic keratin debris in the cystic cavity. (a) Hematoxylin-eosin stain, magnification ×10. (b) Magnification × 100.

confirmed the diagnosis of an epidermal inclusion cyst (► Fig. 4). The patient had an uneventful postoperative course, and his preoperative symptoms disappeared. Six months following the excision, there was no evidence of recurrence and the patient remained free of symptoms.

Discussion

Epidermal inclusion cysts, also known as epidermoid inclusion cysts, epidermal cysts, epithelial cysts, keratin cysts, implantation cysts, infundibular cysts, or sebaceous cysts, are unilocular cysts without septation that are encapsulated with fibrous tissue and lined by true epidermis, which is stratified, keratinized squamous epithelium with a granular layer as found on the skin surface and in the infundibulum of hair follicles. Because these cysts do not involve sebaceous glands and do not contain sebum, the term “sebaceous cyst” is a misnomer.⁵ The cysts contain central, eosinophilic, keratinaceous material comprising accumulations of cutaneous products, the debris of keratin, proteins, cholesterol, and cell membrane lipids. The contents usually look like a chunk of cheese and have a foul smell. Cysts can be skin-colored, yellow, or white and are usually slow-growing and asymptomatic. However, polymicrobial infection of cysts with aerobic or anaerobic organisms may occur, and malignant transformation, although very rare, has been reported.⁶ Epidermal inclusion cysts are, strictly speaking, epidermoid cysts of traumatic origin.⁷ The proposed mechanisms of development of epidermoid cysts include incomplete cleavage of cutaneous ectoderm at the embryonic stage, squamous metaplasia of the columnar epithelial cells within dilated ducts, downward growth of epidermal cells with inflammation after obstruction of the hair follicle, human papillomavirus infection, and growth of implanted fragments of the epidermis within deep tissue after trauma or surgical procedures.^{4,5,8,9} Epidermoid cysts of nontraumatic origin are commonly located on hair-bearing areas of the upper chest, upper back, neck or head, while epidermoid cysts of traumatic origin—epidermal inclusion cysts—are more common on nonfollicular areas such as the palms, soles, or buttocks.

Epidermal inclusion cysts are the third most common type of tumor of the hand, after ganglion cysts and giant cell tumors of the tendon sheath.¹⁰ They are more frequently seen in male manual laborers who are subject to repeated minor trauma to the hand. They are usually located in the dermis or subcutaneous tissue layer of the volar surface, especially the distal portion of the digits, as a solitary lesion. However, multiple lesions and deep tissue involvement, such as tendon and bone, have been reported also.^{11,12} Lincoski et al⁸ reported the largest series of epidermal inclusion cysts of the hand. They experienced 101 cysts (94 patients) among 623 hand tumors (16%) over a period of 27 years. Of these patients, 83% were male and 56% were manual laborers. Mean age was 46 years old. Forty-eight percent recalled a definite traumatic event prior to cyst development, and three cases had cysts that occurred after prior unrelated surgery. However, detailed

information about the nature of previous operations was not provided. Seventy-two cysts (71%) were located on the volar surface. Four cysts (0.04%) were intraosseous, and four cases (0.04%) were multiple. There were 11 cases (11%) of recurrence. Lucas¹³ also reported 58 patients (60 cases) with epidermal inclusion cysts of the hand. In that study, 85% were male (49 patients), and 91% (53 patients) were manual laborers. Forty-seven percent (27 patients) recalled a traumatic event. Cysts were intraosseous in two patients (0.03%), and recurrence occurred in 10 patients (17%).

Although repeated minor trauma is a frequent cause of epidermal inclusion cysts in the hand, postoperative occurrence of epidermal inclusion cysts in the hand has been rarely reported. We found only two cases in the English-language medical literature.^{4,14} One was due to dermofasciectomy and full-thickness skin graft to treat Dupuytren's contracture,¹⁴ while the other was due to mini-open carpal tunnel release.⁴ Low et al⁴ presented a case of epidermal inclusion cyst after carpal tunnel release and presumed that subcuticular suture with braided polyglactin implanted epidermal tissue into the deep tissue. In our case, we had closed the operation wound with vertical mattress sutures of 3–0 monofilament nylon. It is therefore unclear how epidermal tissue was implanted in our case.

As mentioned previously, all kinds of surgical and invasive procedures can induce epidermal inclusion cysts. To prevent development of epidermal inclusion cysts, surgeons should use a fresh, sharp scalpel and should be careful not to make invaginations of skin edges.⁷ Moreover, when sharp instruments or powered instruments are used, surgeons should be careful not to push epithelium into the deeper tissues. Profuse irrigation of the operation wound is also important to wash out epithelial debris.⁷ Although carpal tunnel release is a relatively safe procedure and is widely performed, surgeons have to keep in mind these recommendations to prevent the occurrence of epidermal inclusion cysts.

Conflict of Interest

None.

References

- 1 Cranford CS, Ho JY, Kalainov DM, Hartigan BJ. Carpal tunnel syndrome. *J Am Acad Orthop Surg* 2007;15(9):537–548
- 2 Benson LS, Bare AA, Nagle DJ, Harder VS, Williams CS, Visotsky JL. Complications of endoscopic and open carpal tunnel release. *Arthroscopy* 2006;22(9):919–924, 924.e1–924.e2
- 3 Louie DL, Earp BE, Collins JE, et al. Outcomes of open carpal tunnel release at a minimum of ten years. *J Bone Joint Surg Am* 2013; 95(12):1067–1073
- 4 Low HL, Sivasamy VP, Griffiths AP, Redfern RM. Recurrent carpal tunnel syndrome owing to an implantation epidermoid cyst after carpal tunnel decompression: case report. *Neurosurgery* 2007; 60(5):E956, discussion E956
- 5 Thomas VD, Snavely NR, Lee KK, Swanson NA. Benign epithelial tumors, hamartomas, and hyperplasias. In: Goldsmith LA, ed. *Fitzpatrick's Dermatology in General Medicine*. 8th ed. New York, NY: McGraw-Hill; 2012:1333–1334

- 6 Ziadi S, Trimeche M, Hammedi F, et al. Squamous cell carcinoma arising from an epidermal inclusion cyst: A case report. *N Am J Med Sci* 2010;2(1):46-47
- 7 Farrer AK, Forman WM, Boike AM. Epidermal inclusion cysts following minimal incision surgery. *J Am Podiatr Med Assoc* 1992;82(10):537-541
- 8 Lincoski CJ, Bush DC, Millon SJ. Epidermoid cysts in the hand. *J Hand Surg Eur Vol* 2009;34(6):792-796
- 9 Goebel SX, Rasi LM, Stern PJ. Multiple epidermal inclusion cysts in a patient with rheumatoid arthritis: a case report. *J Hand Surg Am* 2000;25(4):768-771
- 10 Nahra ME, Bucchieri JS. Ganglion cysts and other tumor related conditions of the hand and wrist. *Hand Clin* 2004;20(3):249-260, v
- 11 Simon K, Leithner A, Bodo K, Windhager R. Intraosseous epidermoid cysts of the hand skeleton: a series of eight patients. *J Hand Surg Eur Vol* 2011;36(5):376-378
- 12 O'Hara JJ, Stone JH. An intratendinous epidermoid cyst after trauma. *J Hand Surg Am* 1990;15(3):477-479
- 13 Lucas GL. Epidermoid inclusion cysts of the hand. *J South Orthop Assoc* 1999;8(3):188-192
- 14 Henry FP, Healy CE, O'Broin E. Epidermoid cyst post dermofasciectomy. *J Plast Reconstr Aesthet Surg* 2010;63(1):e44-e45