

A Case of Facial Spasm Associated with Ipsilateral Cerebellopontine Angle Arachnoid Cyst

Hiroshi Ogawa¹ Satoru Hiroshima¹ Kyousuke Kamada¹

¹Department of Neurosurgery, Asahikawa Medical University, Asahikawa, Hokkaido, Japan

Surg J 2015;1:e38–e40.

Address for correspondence Hiroshi Ogawa, MD, Department of Neurosurgery, Graduate School of Medicine, Asahikawa Medical University, 2-1, Midorigaoka-Higashi, Asahikawa, Hokkaido, 078-8510, Japan (e-mail: a040010@gmail.com).

Abstract

Keywords

- ▶ cerebellopontine angle arachnoid cyst
- ▶ hemifacial spasm
- ▶ microvascular decompression

The authors report a rare case of right cerebellopontine angle cyst related to hemifacial spasm. The patient was a 66-year-old woman with a 3-year history of right hemifacial spasm. The cyst was diagnosed preoperatively by T2-weighted magnetic resonance imaging, which demonstrated a hyperintense area in the right cerebellopontine angle. A small artery was displaced by the cyst and compressed the root exit zone of the facial nerve. Decompression of the cyst and the vasculature using a microsurgical technique resulted in total recovery from hemifacial spasm.

The most common case of hemifacial spasm was reported to be vascular compression at the root exit zone (REZ) of the facial nerve.¹ Vascular compression was usually caused by the anterior inferior cerebellar artery (AICA), posterior inferior cerebellar artery, or vertebral artery.² Other causes of hemifacial spasms were known as posterior circulation aneurysms,³ arteriovenous malformations,⁴ and cerebellopontine angle (CPA) tumors,⁵ but these cases are rarely observed. Among these cases, CPA arachnoid cyst is very rare, and we have never experienced a case. Herein, we report our experience on hemifacial spasm associated with CPA arachnoid cyst.

Case Report

This study was approved by the Ethics Committee of Asahikawa Medical University.

A 66-year-old woman was admitted to our hospital with a chief complaint of twitching of the right facial muscle for 3 years. The spasm originated particularly in the inferior orbicularis oculi and did not extend to lower part of the face. The patient previously had Botox therapy at another hospital, but it was ineffective. Except for facial spasm, no neurologic abnormality, including hearing deficit, was observed. Preoperative T2-weighted magnetic resonance imaging demonstrated hyperintense area resembling an arachnoid cyst in the right CPA. The image also indicated that the REZ of

the facial nerve was compressed by the AICA, which was displaced by the cyst (▶ Fig. 1).

We performed cyst and microvascular decompression by a right suboccipital lateral approach. The cyst wall was clear and transparent. Upon excision of the cyst wall, we detected normal-looking cranial nerves VII and VIII. A branch of the AICA compressed the REZ of the facial nerve rostrally. The artery was separated from the REZ to completely decompress the facial nerve (▶ Fig. 2). To maintain the decompression, we attached the artery on tentorium cerebelli using Teflon felt and bioadhesion (blood-clotting factors). After surgery, the patient was immediately relieved of hemifacial spasm, and no neural complications such as facial paresis, hypoacusis, and dysphasia were observed. The surgical scar was also in good condition without any infections. On pathologic diagnosis, the cyst wall was revealed to be a typical arachnoid membrane.

The patient was discharged 8 days after surgery in good condition. At follow-up 6 months after surgery, the patient was still symptom-free without any complications.

Discussion

We present the occurrence of hemifacial spasm and CPA arachnoid cyst in a patient who was fully treated by decompression of the cyst and microvascular structures. This case suggested that CPA arachnoid cysts can also play an important

received
June 22, 2015
accepted after revision
August 12, 2015
published online
September 16, 2015

DOI <http://dx.doi.org/10.1055/s-0035-1564341>.
ISSN 2378-5128.

Copyright © 2015 by Thieme Medical Publishers, Inc., 333 Seventh Avenue, New York, NY 10001, USA.
Tel: +1(212) 584-4662.

License terms



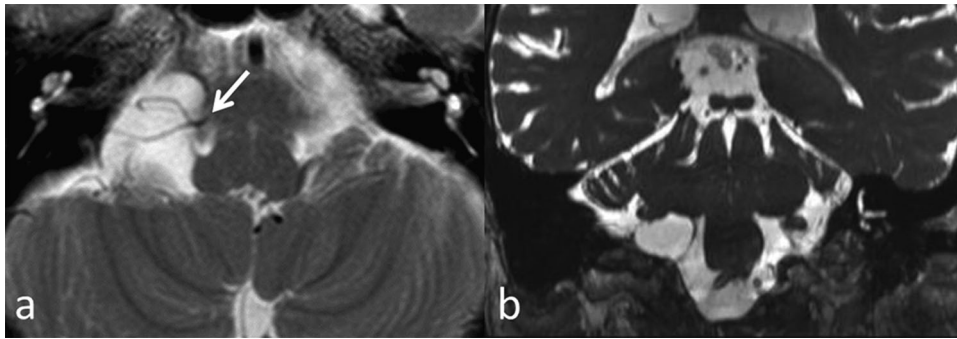


Fig. 1 The axial T2-weighted (a) and coronal (b) images show high-intensity area on the right cerebellopontine angle. The branches of anterior inferior cerebellar artery are displaced by the cyst and compress the root exit zone of the facial nerve (solid arrow).

role in displacing the artery and can contribute to hemifacial spasm.

The overall frequency of occurrence of arachnoid cyst is 0.1 to 0.3%⁶; in the posterior cranial fossa, particularly in the CPA, arachnoid cyst was found in ~10% of all cases.⁷ The clinical symptoms caused by CPA cysts are similar to the acoustic tumor symptoms, including sensorineural hearing deficit.⁸ However, in this case, the patient suffered from only hemifacial spasm. Previous studies reported that compression at a point where the myelin sheath changes from oligodendroglia to Schwann cell was the main cause of facial spasm.^{9,10} From this point of view, the hemifacial spasm associated with arachnoid cysts should be caused mainly by compression of the facial nerve REZ by the arteries displaced

by the cyst. In a report of a similar case, evacuation of the arachnoid cyst alone had no beneficial effects, and additional microvascular decompression led to complete relief of hemifacial spasm.¹¹ Thus, CPA arachnoid cyst alone would not cause hemifacial spasm; a combination of microvascular displacement and compression of the facial nerve REZ would be necessary. Other cases of hemifacial spasm associated with CPA arachnoid cyst were also treated effectively by removal or decompression of the cyst and of the facial nerve.¹²⁻¹⁴ Treatment outcomes were no different between partial excision and total excision of the arachnoid cyst,¹¹⁻¹⁴ and no recurrence of arachnoid cyst and hemifacial spasm was reported. Therefore, hemifacial spasm associated with CPA arachnoid cyst can be effectively treated with

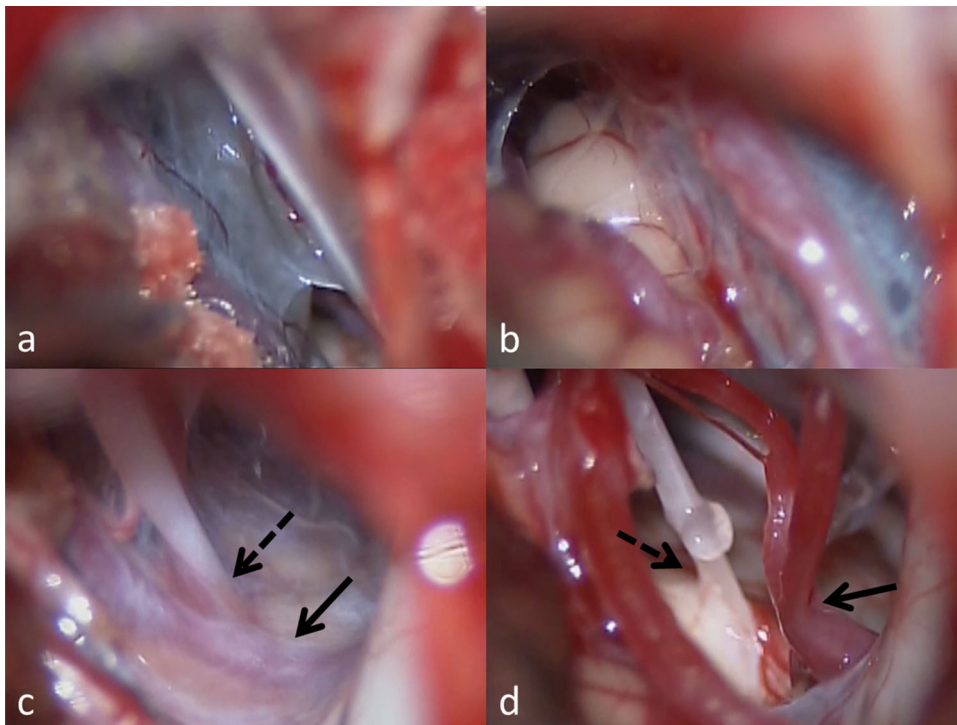


Fig. 2 (a) Intraoperative view showing cerebellopontine angle arachnoid cyst after opening dura. (b) The arteries are running on the wall of the cyst and are displaced. (c) After opening the cyst, the root exit zone (REZ) of the facial nerve (dotted arrow) is compressed by a branch of the displaced anterior inferior cerebellar artery (AICA; solid arrow). (d) After separating the AICA (solid arrow), the REZ of facial nerve (dotted arrow) was completely decompressed.

decompression of both the cyst and the artery at the REZ of the facial nerve.

Conflicts of Interest

The authors declare no conflict of interest.

Acknowledgments

The authors thank the patient for participating in this study and Enago for the English language review.

References

- 1 Campos-Benitez M, Kaufmann AM. Neurovascular compression findings in hemifacial spasm. *J Neurosurg* 2008;109(3):416–420
- 2 McLaughlin MR, Jannetta PJ, Clyde BL, Subach BR, Comey CH, Resnick DK. Microvascular decompression of cranial nerves: lessons learned after 4400 operations. *J Neurosurg* 1999;90(1):1–8
- 3 Nakagawa I, Takayama K, Kurokawa S, et al. Hemifacial spasm due to contralateral aneurysmal compression of the facial nerve successfully treated with endovascular coil embolization: case report. *Neurosurgery* 2011;69(3):E768–E771, discussion E771–E772
- 4 Pierry A, Cameron M. Clonic hemifacial spasm from posterior fossa arteriovenous malformation. *J Neurol Neurosurg Psychiatry* 1979;42(7):670–672
- 5 Sprik C, Wirtschafter JD. Hemifacial spasm due to intracranial tumor. An international survey of botulinum toxin investigators. *Ophthalmology* 1988;95(8):1042–1045
- 6 Katzman GL, Dagher AP, Patronas NJ. Incidental findings on brain magnetic resonance imaging from 1000 asymptomatic volunteers. *JAMA* 1999;282(1):36–39
- 7 Samii M, Carvalho GA, Schuhmann MU, Matthies C. Arachnoid cysts of the posterior fossa. *Surg Neurol* 1999;51(4):376–382
- 8 Babu R, Murali R. Arachnoid cyst of the cerebellopontine angle manifesting as contralateral trigeminal neuralgia: case report. *Neurosurgery* 1991;28(6):886–887
- 9 Jannetta PJ. Trigeminal neuralgia and hemifacial spasm—etiology and definitive treatment. *Trans Am Neurol Assoc* 1975;100:89–91
- 10 Jannetta PJ. Observations on the etiology of trigeminal neuralgia, hemifacial spasm, acoustic nerve dysfunction and glossopharyngeal neuralgia. Definitive microsurgical treatment and results in 117 patients. *Neurochirurgia (Stuttg)* 1977;20(5):145–154
- 11 Higashi S, Yamashita J, Yamamoto Y, Izumi K. Hemifacial spasm associated with a cerebellopontine angle arachnoid cyst in a young adult. *Surg Neurol* 1992;37(4):289–292
- 12 Altinörs N, Kars Z, Cepoğlu C. Rare causes of hemifacial spasm. Report of two cases. *Clin Neurol Neurosurg* 1991;93(2):155–158
- 13 Takano S, Maruno T, Shirai S, Nose T. Facial spasm and paroxysmal tinnitus associated with an arachnoid cyst of the cerebellopontine angle—case report. *Neurol Med Chir (Tokyo)* 1998;38(2):100–103
- 14 Mastronardi L, Taniguchi R, Caroli M, Crispo F, Ferrante L, Fukushima T. Cerebellopontine angle arachnoid cyst: a case of hemifacial spasm caused by an organic lesion other than neurovascular compression: case report. *Neurosurgery* 2009;65(6):E1205, discussion E1205