

Spinal Metastasis from Subcutaneous Sacrococcygeal Ependymoma: A Case Report with Long-Term Follow-Up

Katsuhito Yoshioka¹ Hideki Murakami¹ Satoru Demura¹ Satoshi Kato¹ Norio Kawahara¹
Katsuro Tomita¹ Hiroyuki Tsuchiya¹

¹Department of Orthopaedic Surgery, Kanazawa University, Kanazawa, Japan

Address for correspondence Katsuhito Yoshioka, MD, Department of Orthopaedic Surgery, Kanazawa University, 13-1 Takara-machi, Kanazawa 920-8641, Japan (e-mail: ortho1976ky@yahoo.co.jp).

Surg J 2015;1:e50–e53.

Abstract

Objective To present a previously unreported patient with recurrent spinal metastasis from subcutaneous sacrococcygeal ependymoma who was followed for 16 years.

Methods A 50-year-old man who had T9 metastasis from subcutaneous sacrococcygeal ependymoma underwent piecemeal total T9 excision at a local hospital. He was referred to our institute because of weakness in both legs and bowel–bladder dysfunction with the presence of recurrent spinal metastasis at levels T9–T11. Additional tumor excision was performed circumferentially around the dura, along with spinal reconstruction via a posterior-anterior-posterior approach. Subsequently, the patient could walk again. Thereafter, this patient was treated by repeated surgical resection, instrumentation, and bone grafting for thoracic spinal metastases, and an additional 14 thoracic nerve root transections (bilateral T6–T12) as a result of eight operations.

Results These repeated operations have prevented paralysis and allowed the patient to maintain activities of daily living for 16 years.

Conclusions We illustrated the feasibility of repeated surgical resection of thoracic spinal metastases, involving eight operations over 16 years. We believe that this case emphasizes the need to repeatedly resect this type of tumor before the onset of paralysis to maintain normal activity levels.

Keywords

- ▶ subcutaneous sacrococcygeal ependymoma
- ▶ spinal metastasis
- ▶ repeated surgical resection
- ▶ long-term follow-up

Myxopapillary ependymomas are typically primary, intradural tumors of ependymal origin that arise from the filum terminale. In rare instances, they may arise in the sacrococcygeal region as a primary subcutaneous tumor, and there are few case reports involving long-term follow-up.^{1–4} However, no reports have described the outcomes of this type of tumor following spinal metastasis. In the present report, we describe a patient with recurrent spinal metastasis from subcutaneous sacrococcygeal ependymoma who was followed for 16 years.

Case Report

A 43-year-old man experienced swelling in the sacrococcygeal region lasting more than 30 years. The tumor was excised and histologic examination indicated the presence of a subcutaneous sacrococcygeal ependymoma. Seven years after the operation, metastasis was detected at the T9 level, and piecemeal total excision was performed at a local hospital. However, 20 months after this second operation, the patient complained of weakness in both legs and bowel–bladder dysfunction. Tumor recurrence was detected at levels

received
July 2, 2015
accepted
September 25, 2015
published online
November 23, 2015

DOI <http://dx.doi.org/10.1055/s-0035-1567878>.
ISSN 2378-5128.

Copyright © 2015 by Thieme Medical Publishers, Inc., 333 Seventh Avenue, New York, NY 10001, USA.
Tel: +1(212) 584-4662.

License terms



T9–T11, and S2. High sacral amputation was performed, and the patient was then referred to our institute because of the presence of recurrent spinal metastasis at the T9, T10, and T11 levels (►Fig. 1). An additional tumor excision was performed circumferentially around the dura, along with spinal reconstruction using a cage with an autograft via a posterior-anterior-posterior approach. Subsequently, the patient could walk again. However, hypoesthesia developed 2 years after the revision surgery. Magnetic resonance imaging indicated spinal tumor recurrence around the cage, dura, and aorta. Multiple small lung metastases were also detected at this time. The patient underwent another, thorough tumor excision with spinal reconstruction, as the tumor was not considered a high-grade malignancy. After this third thoracic surgery, the patient could live independently and resumed his daily social activities. However, he complained of gait disturbance after another 2 years. Another recurrent tumor was found to have invaded the dura, and cerebrospinal fluid had accumulated at the surgical site (►Fig. 2A). The border between the dura and cage had become indistinguishable because of the presence of scar tissue (►Fig. 2B). Tumor curettage was performed, followed by application of an artificial dural patch (►Fig. 2C). The tumor grew slowly through the T9 to T11 vertebral bodies over the subsequent years, and we became concerned about spinal instability following a pathologic fracture. On the basis of the findings made during the previous operation, removal of the cage was considered impossible. The patient therefore underwent tumor excision with morcellated bone autografts via a trans-thoracic approach at his fifth thoracic surgery. Thereafter, tumor curettage and bone grafting was repeatedly performed for each new occurrence of neurologic dysfunction (American Spinal Injury Association impairment scale grade C or D) resulting from tumor recurrence of the thoracic spine (►Fig. 3A, B, C, D). We performed a total of nine thoracic revision operations and an additional 14 thoracic nerve root transections (bilateral T6–T12) as a result of multiple

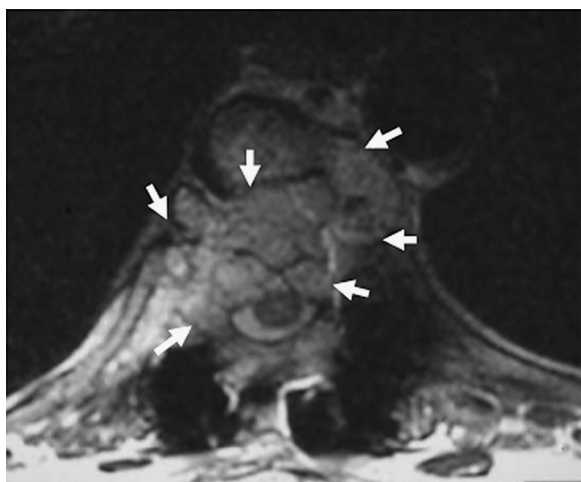


Fig. 1 T2-weighted axial magnetic resonance image shows recurrent tumor at T10 vertebral. The tumor compressed the spinal cord from anterior (arrows).

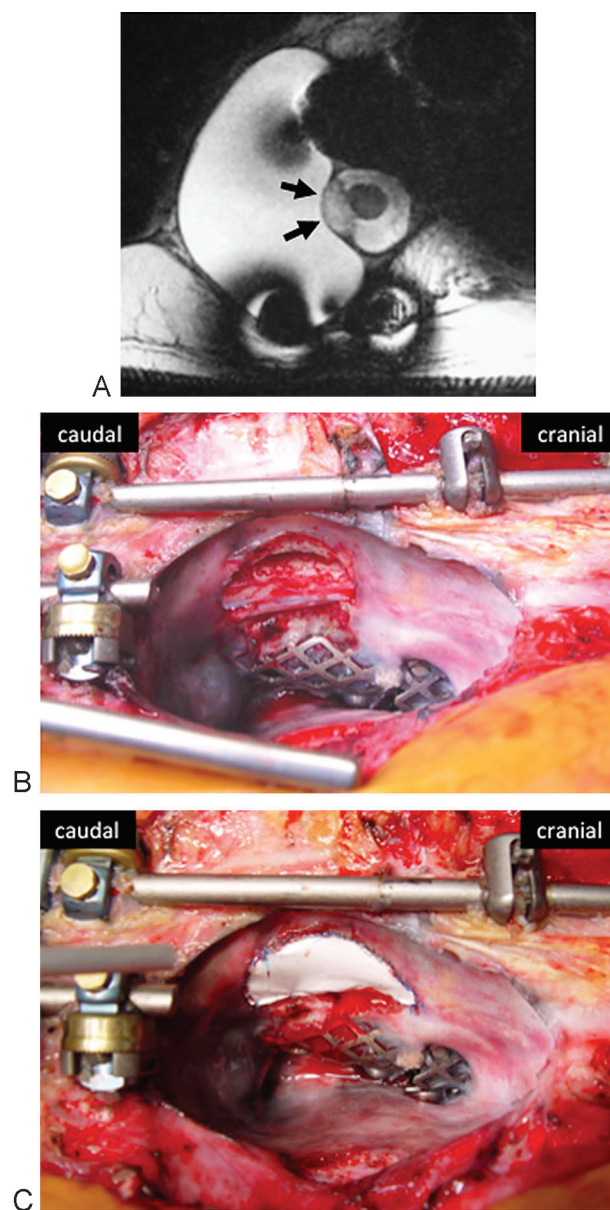


Fig. 2 (A) T2-weighted axial magnetic resonance image. Recurrent tumor invaded intradural space (arrows). Cerebrospinal fluid accumulated at the surgical site. (B) Exposed spinal cord after tumor resection. The border between the dura and cage had become indistinguishable because of the presence of scar tissue. (C) Artificial dural patch was sutured to scar tissue or dura to cover the spinal cord.

surgeries (►Table 1). These repeated operations have prevented paralysis and allowed the patient to maintain activities of daily living. He is still able to walk without a cane.

The patient and his family were asked if data from the case could be submitted for publication, and they gave their informed consent.

Discussion

In general, complete excision of a subcutaneous sacrococcygeal ependymoma is considered the best treatment option.^{3–6} However, extraspinal ependymomas tend to metastasize more

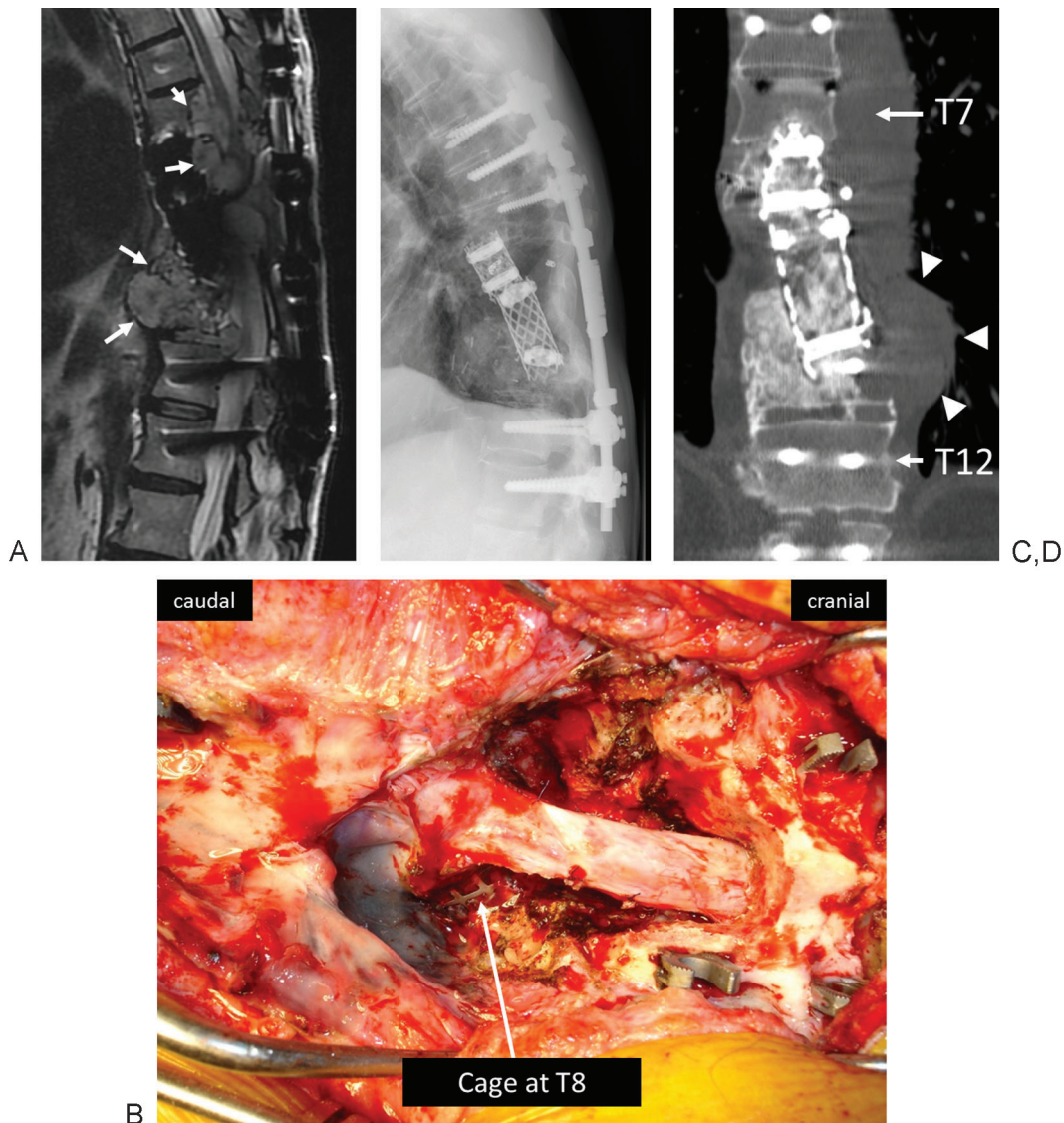


Fig. 3 (A) T2-weighted sagittal magnetic resonance image. Recurrent tumor was located from T7 to T11 2 years after the patient's sixth thoracic surgery (arrows). (B) Curettage the recurrent tumor with bilateral T6–T7 nerve roots transection at seventh surgery. Postoperative X-ray (C) and computed tomography coronal reconstructed image (D) after tenth thoracic surgery. Residual tumor grows at the left side of T10–T11 levels (arrowhead). However, morcellated bone autografts already bridged between T11 vertebral body and grafted bone inside the cage and spinal stability was preserved during the follow-up period.

frequently than their intrameningeal counterparts that originate in the cauda.^{7,8} Furthermore, following the recurrence of metastasis, the disease progresses slowly, but relentlessly. There have been some reported cases of pulmonary or lymph node metastases.^{1–3,6,7,9,10} However, no detailed reports have been published regarding spinal metastasis from subcutaneous sacrococcygeal ependymoma. Spinal metastasis could affect activities of daily living through impaired spinal cord function and spinal stability. Chemotherapy is of no benefit for this tumor.^{11,12} Adjuvant radiotherapy may instead be an option in cases of an incompletely resected tumor.^{3,13} However, this case involved local recurrence around the dura after surgery, leading us to believe that a complete cure would be impossible. It is also impossible to perform repeated radiation treatments over time to preserve the spinal cord. Thus, repeated surgical resection of thoracic spinal metastases was the only procedure that can

maintain the patient's quality of life. Surgeons are often reluctant to perform multiple procedures for a recurrent spinal tumor because they are difficult, so there is a possibility that surgical treatment will be delayed or abandoned. This case indicates that repeated tumor curettage and bone grafting before the onset of severe paralysis (American Spinal Injury Association scale grade C) can contribute to the maintenance of neurologic function and spinal stability for at least 16 years after spinal metastasis.

We have to be particularly aware of the following possibilities in cases involving a recurrent spinal tumor: (1) a tumor around the spinal cord can affect spinal cord function, (2) a tumor from the anterior spinal column can compress the aorta and esophagus, (3) a tumor inside the cage and vertebral body can affect spinal stability, and (4) a tumor at the site of the high sacral amputation could potentially invade the intestinal tract.

Table 1 Surgical treatments

Age (y)	Diagnosis	Approach	Surgical treatments	Operative time (min)	Intraoperative blood loss (mL)
43	Subcutaneous sacrococcygeal ependymoma	P	Tumor excision	N/A	
50	T9 metastasis	PA	Total spondylectomy of T9	N/A	
52	S2–S3 metastasis	P	High sacral amputation	N/A	
53	T9–T11 recurrence	PAP	Debulking, posterior instrumentation, and anterior reconstruction at T9	1,135	4,050
55	T8–T10 recurrence, lung metastases	PAP	Debulking, posterior instrumentation, and anterior reconstruction at T8	855	2,530
56	L5–S1 metastasis	P	Tumor excision	125	65
57	T9 recurrence	P	Curettage, duraplasty, posterior instrumentation	420	200
59	T9–T12 recurrence	A	Curettage, bone graft, intercostal muscle flap	510	1,030
61	T8–T11 recurrence	P	Curettage, replacement of instrument	359	70
63	T6–T7 recurrence	P	Curettage, additional posterior stabilization	467	1,700
65	T11–T12 recurrence	P	Curettage, bone graft, additional posterior stabilization	380	1,780

Abbreviations: A, anterior approach; P, posterior approach; PA, posteroanterior double approach; PAP, posterior-anterior-posterior approach.

Although further treatment will be more challenging, we have to assess the situation of the patient carefully to determine the best time for additional surgery.

Conclusion

This patient was treated by repeated surgical resection of thoracic spinal metastases, involving eight operations over 16 years. We believe that this case emphasizes the need to repeatedly resect this type of tumor before the onset of paralysis to maintain normal activity levels.

References

- Helwig EB, Stern JB. Subcutaneous sacrococcygeal myxopapillary ependymoma. A clinicopathologic study of 32 cases. *Am J Clin Pathol* 1984;81(2):156–161
- Wolff M, Santiago H, Duby MM. Delayed distant metastasis from a subcutaneous sacrococcygeal ependymoma. Case report, with tissue culture, ultrastructural observations, and review of the literature. *Cancer* 1972;30(4):1046–1067
- Kramer GW, Rutten E, Sloof J. Subcutaneous sacrococcygeal ependymoma with inguinal lymph node metastasis. Case report. *J Neurosurg* 1988;68(3):474–477
- Johnson JM, Jessurun J, Leonard A. Sacrococcygeal ependymoma: case report and review of the literature. *J Pediatr Surg* 1999;34(9):1405–1407
- Lee KJ, Min BW, Seo HJ, Cho CH. Subcutaneous sacrococcygeal myxopapillary ependymoma in Asian female: a case report. *J Clin Med Res* 2012;4(1):61–63
- Ma YT, Ramachandra P, Spooner D. Case report: primary subcutaneous sacrococcygeal ependymoma: a case report and review of the literature. *Br J Radiol* 2006;79(941):445–447
- Vagaiwala MR, Robinson JS, Galicich JH, Gralla RJ, Helson L, Beattie EJ Jr. Metastasizing extradural ependymoma of the sacrococcygeal region: case report and review of literature. *Cancer* 1979;44(1):326–333
- Sonneland PR, Scheithauer BW, Onofrio BM. Myxopapillary ependymoma. A clinicopathologic and immunocytochemical study of 77 cases. *Cancer* 1985;56(4):883–893
- Kline MJ, Kays DW, Rojiani AM. Extradural myxopapillary ependymoma: report of two cases and review of the literature. *Pediatr Pathol Lab Med* 1996;16(5):813–822
- Gupta RK, Pratap D. Metastasising congenital subcutaneous sacrococcygeal ependymoma. *Indian J Cancer* 1992;29(2):76–81
- Ilhan I, Berberoglu S, Kutluay L, Maden HA. Subcutaneous sacrococcygeal myxopapillary ependymoma. *Med Pediatr Oncol* 1998;30(2):81–84
- Miralbell R, Louis DN, O'Keefe D, Rosenberg AE, Suit HD. Metastatic ependymoma of the sacrum. *Cancer* 1990;65(10):2353–2355
- Domingues RC, Mikulis D, Swearingen B, Tompkins R, Rosen BR. Subcutaneous sacrococcygeal myxopapillary ependymoma: CT and MR findings. *AJNR Am J Neuroradiol* 1991;12(1):171–172