

Resection of a large rectal polyp with the simultaneous combination of snare polypectomy and full-thickness resection device resection

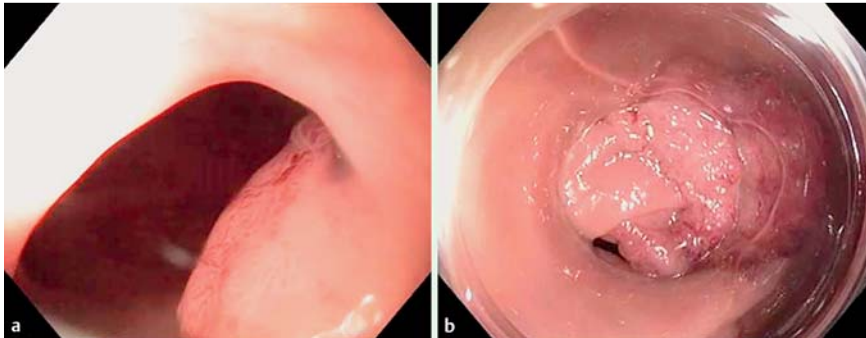


Fig. 1 Flexible endoscopy in a 59-year old woman referred for further treatment after incomplete polypectomy of a large rectal polyp, described as a tubulovillous adenoma harboring high grade dysplasia. **a** With a standard colonoscopy, only part of the polyp remnant is visible. **b** Visualization of the true extent of the polyp remnant is improved with the mounted distance cap.

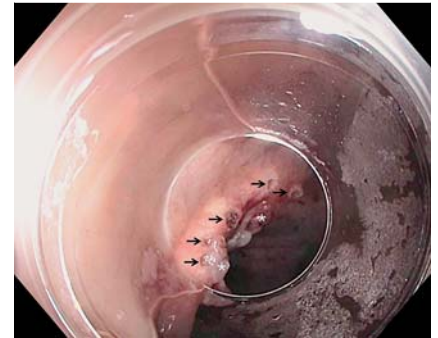

Fig. 2 Endoscopic view of the polyp base after snare resection. The lateral margins of small polyp remnants (asterisks) have been marked with the coagulation probe (arrows) included in the package of the full-thickness resection device.

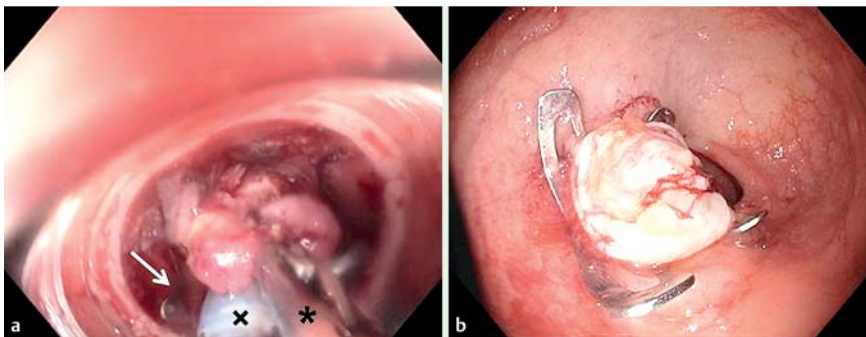


Fig. 3 Resection with the full-thickness resection device (FTRD). **a** The polypectomy site with visible small remnants of the polyp is pulled into the FTRD cap with the grasper (asterisk) included in the package. The polypectomy snare is preloaded on the FTRD cap (cross), and an over-the-scope clip (OTSC; arrow) is also loaded on the FTRD cap. **b** Full-thickness resection site with the OTSC in situ.

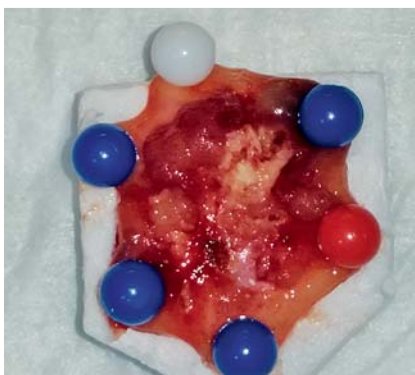


Fig. 4 The full-thickness resection specimen includes the R2 margin of the snare polypectomy. Based on the histological examination result, R0 resection was achieved.

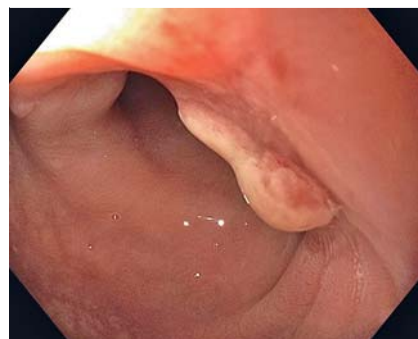

Fig. 5 Scar at 8 weeks after resection with the full-thickness resection device (FTRD). The clip has detached spontaneously. There is some granulation tissue in the center of the scar, typically seen early after FTRD resection.

A new device for full-thickness colorectal resection, the so-called full-thickness resection device (FTRD; Ovesco Endoscopy, Tübingen, Germany) has been available

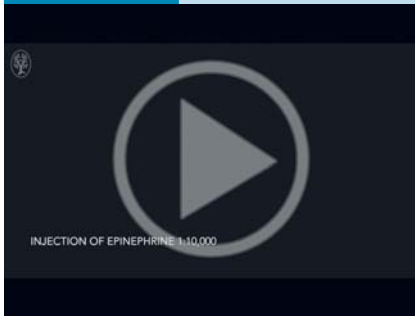
since November of 2014. It is the first commercial system based on the over-the-scope clip (OTSC) principle. The FTRD consists of a modified 14t OTSC mounted

on a transparent cap, which has a monofilament polypectomy snare preloaded on its tip. The FTRD can be mounted over a standard colonoscopy [1]. Because the volume of the transparent FTRD cap is greater than that of the OTSC cap (3 cm³ vs. 0.9 cm³), full-thickness specimens with a median resection surface of 5 cm² (range 1.6 cm² – 12.9 cm²) can be obtained [2].

A 59-year old patient was referred for further treatment after incomplete polypectomy of a large rectal polyp. Histologically, a tubulovillous adenoma harboring high grade dysplasia was described. The index endoscopic procedure demonstrated a villous polyp in the rectosigmoid curve that was difficult to visualize. With a mounted transparent distance cap (MAJ-663; Olympus, Tokyo, Japan), better visualization was possible, and a large, broad-based villous polyp remnant about 3 cm in diameter was seen (Fig. 1).

After the patient had provided informed consent, polypectomy of the polyp remnant was performed close to its base with a standard snare (FlexSnare; Medwork, Höchststadt/Aisch, Germany; Fig. 2). Then, the FTRD was mounted on a colonoscopy (CF-H180AI, Olympus), and a full-thickness resection of the entire polypectomy site was carried out uneventfully (Fig. 3). The snare polypectomy remnant and the FTRD specimen measured 3 × 2 × 1 cm and 3.1 × 2.5 × 0.8 cm, respec-

Video 1



Resection of a large rectal polyp with the simultaneous combination of snare polypectomy and full-thickness resection device resection.

tively (• Fig. 4). The entire procedure is presented in • Video 1.

Histological examination confirmed full-thickness resection. The polyp remnant contained low grade dysplasia, and the FTRD remnant contained parts of the tubulovillous adenoma with negative resection margins. At follow-up 8 weeks later, the OTSC had detached spontaneously. A normal scar with some granulation tissue (typical after FTRD resection) was seen (• Fig. 5).

To our knowledge, this is the first report of simultaneous snare polypectomy and FTRD resection. The volume of the polyp

was too large for FTRD resection alone, and it would not have fit into the FTRD cap. After the snare resection, clearly no RO resection had been obtained. We decided on the simultaneous snare polypectomy and FTRD resection in order to avoid scarring and the development of tissue fibrosis. For successful FTRD resections comparable to OTSC treatment [3], tissue mobilization into the FTRD cap is crucial. At a later time, this might be complicated or even prevented by the healing process after the resection of a large polyp [1–3]. In conclusion, if incomplete snare polypectomy can be expected, additional resection of the polyp base remnant with the FTRD in the same session may be reasonable. Informed consent should be obtained before the procedure, and the necessary materials must be available.

Endoscopy_UCTN_Code_TTT_1AQ_2AD

Competing interests: None

Andreas Fischer, Richard F. Knoop, Christine Walker, Robert Thimme, Hans-Jürgen Richter-Schrag

University Hospital Freiburg, Interdisciplinary Gastrointestinal Endoscopy, Department of Medicine II, Freiburg, Germany

References

- 1 Schmidt A, Bauerfeind P, Gubler C et al. Endoscopic full-thickness resection in the colon with a novel over-the-scope device: first experience. *Endoscopy* 2015; 47: 719–725
- 2 Richter-Schrag HJ, Walker C, Thimme R et al. Full thickness resection device (FTRD): experience and outcome for benign neoplasms of the rectum and colon [in German]. *Chirurg* 2015 Oct 5. [Epub ahead of print]
- 3 Haito-Chavez Y, Law JK, Kratt T et al. International multicenter experience with an over-the-scope clipping device for endoscopic management of GI defects (with video). *Gastrointest Endosc* 2014; 80: 610–622

Bibliography

DOI <http://dx.doi.org/10.1055/s-0035-1569658>
Endoscopy 2015; 47: E607–E608
 © Georg Thieme Verlag KG
 Stuttgart · New York
 ISSN 0013-726X

Corresponding author

Andreas Fischer, MD
 Interdisciplinary Gastrointestinal Endoscopy
 Hugstetterstr. 55
 79106 Freiburg
 Germany
 Fax: +49-761-27025411
andreas.fischer@uniklinik-freiburg.de