

Reconstruction of the Lower Extremity with Cross-Leg Free Flaps

Ozlenen Ozkan, MD¹ Anı Cinpolat, MD² Gamze Bektas, MD² Arzu Akcal, MD¹ Harun Simsek, MD¹
Polat Bicici, MD¹ Seckin Aydın Savas, MD¹ Kerim Unal, MD¹ Omer Ozkan, MD¹

¹Department of Plastic, Reconstructive and Aesthetic Surgery, Akdeniz University School of Medicine, Antalya, Turkey

²Private Practice, Ataturk bul. Gokay Plaza no 1 konyaalti, Antalya, Turkey

Address for correspondence Ozlenen Ozkan, MD, Department of Plastic, Reconstructive and Aesthetic Surgery, Akdeniz University School of Medicine, Dumlupınar Bulvarı, 07058 Konyaalti/Antalya, Turkey (e-mail: ozlenend@yahoo.com).

J Reconstr Microsurg Open 2016;1:12–18.

Abstract

Background The absence of suitable adjacent recipient vessels for microvascular anastomosis due to trauma poses a major challenge to the reconstructive surgeon. The anterior and posterior tibial vessels of the contralateral leg are the two other alternatives for use as recipient vessels for microvascular anastomosis. This method is known as the cross-leg free flap.

Methods Twenty-seven patients (20 males, 7 females) underwent cross-leg free flap operations due to absence of a suitable adjacent recipient vessel between 2007 and 2015. The mean soft tissue defect dimension was 12 × 11 cm (smallest: 6 × 7 cm; largest: 20 × 14 cm). Gustilo type 3B tibia fractures were present in 19 patients, but no fractures were present in the other 8. Six different flaps were used: 14 anterolateral thigh flaps, 6 latissimus dorsi flaps, 3 gracilis muscle flaps, 2 vastus lateralis musculocutaneous flaps, 1 tensor fasciae latae flap, and 1 deep inferior epigastric perforator flap.

Results Two anterolateral thigh flaps failed, while the rest of the flaps survived completely. There were no donor-site complications.

Conclusion We think that the cross-leg free flap method can be safely and successfully used with all flap types in complex lower extremity injuries in which the adjacent recipient vessel option is unavailable.

Keywords

- ▶ cross-leg
- ▶ lower extremity reconstruction
- ▶ vein grafts

Lower limb defects may be present due to various causes, such as infections, vascular diseases, tumor resections, and crush or avulsion injuries. If a defect in the lower extremity cannot be reconstructed with a skin graft, the choice of defect reconstruction will favor local flaps and free tissue transfers.^{1–5} In appropriate cases, skin graft and local flaps can be well tolerated by both patients and surgeons. However, lower limb defects need to be reconstructed using free flaps, and suitable vessels need to be present in the same extremity. In some cases, it is not possible to locate suitable vessels, particularly in cases of trauma such as crush or avulsion injuries.⁶ Dissection toward the proximal site of the damaged

vessels may require finding a suitable zone for microvascular anastomosis. However, a vein graft or a long flap vascular pedicle may be required in such cases.

Vein grafts also pose some distinctive problems, such as limited application and the risk of thrombosis and collapse.^{7–10} Long vascular pedicled free flaps are also generally inadequate. The cross-bridge method, described by Taylor et al in 1979, prevents recipient vessels problems. That was the first report to demonstrate that the vascular pedicle of the free flap can be anastomosed to the recipient vessels in the contralateral leg and then divided after adequate neovascularization of the flap.¹¹ Subsequent researchers have reported

received
August 17, 2015
accepted after revision
November 28, 2015
published online
February 15, 2016

DOI <http://dx.doi.org/10.1055/s-0036-1571278>.
ISSN 2377-0813.

Copyright © 2016 by Thieme Medical Publishers, Inc., 333 Seventh Avenue, New York, NY 10001, USA.
Tel: +1(212) 584-4662.

License terms



various successful cross-leg free flaps, including deep circumflex iliac artery flaps, latissimus dorsi (LD) muscle flaps, and rectus abdominis muscle flaps.^{12–15}

The purpose of this study is to describe our experience with the cross-leg free flap in 27 patients for the reconstruction of severely damaged lower extremities with no suitable adjacent recipient vessels available for microvascular anastomosis.

Materials and Methods

The study data were collected between 2007 and 2015, from cases involving the use of cross-leg free flaps to reconstruct soft tissue defects of the lower extremities in 27 patients (20 male and 7 female) with a mean age of 37.4 years (range, 7–54) at the Department of Plastic and Reconstructive Surgery at the Akdeniz University, Faculty of Medicine, Turkey. The etiology of the injuries consisted of traffic accidents in 22 patients, fire gun injuries in 2, electrical burns in 2, and Marjolin ulcer in 1. Mean defect dimension was 11.5 × 12 cm

(smallest: 6 × 7 cm; largest: 20 × 14 cm). Gustilo type 3B tibia fracture was present in 19 patients, but no fractures were present in the other 8. Seventeen patients had a history of smoking. No patients had any significant comorbidity, such as peripheral artery disease or diabetes, in their medical histories. Preoperatively, arterial angiography was performed on all patients. Cases in which no sufficient recipient vessels existed in the regions surrounding the defect were identified. Twenty-seven cross-leg free flap transfers were performed. The details of each case are summarized in **Table 1**.

Surgical Technique

The posterior tibial vessels of the contralateral leg were prepared as recipient vessels for all patients. Following debridement, the flap was harvested and sutured with the soft tissue of the recipient site. End-to-end anastomoses of the vessels were performed. Both lower extremities were fixed using external fixators in 24 patients, while plasters were used in 3 patients. Donor sites of 10 anterolateral thigh

Table 1 Patient Summary

Patient	Etiology	Defect localization	Defect size	Flap choice
1	Traffic accident	Left tibia anterior	10 × 6 cm	ALT
2	Traffic accident	Right tibia anterior	10 × 12 cm	ALT
3	Traffic accident	Right lateral malleolus	10 × 13 cm	VL MF
4	Traffic accident	Left tibia anterior	10 × 15 cm	VL MCF
5	Traffic accident	Left heel	8 × 9 cm	Gracilis MF
6	Traffic accident	Bilateral femur	15 × 17 cm	LAT MCF
7	Fire gun injury	Left tibia anterior	20 × 14 cm	LAT MCF
8	Marjolin ulcer	Left tibia anterior	10 × 8 cm	ALT
9	Traffic accident	Right tibia anterior	15 × 16 cm	ALT
10	Traffic accident	Right heel	6 × 7 cm	Gracilis MF
11	Traffic accident	Left tibia anterior	8 × 9 cm	ALT
12	Traffic accident	Right tibia anterior	18 × 16 cm	LAT MCF
13	Traffic accident	Left tibia anterior	10 × 9 cm	DIEP
14	Traffic accident	Right tibia anterior	22 × 10 cm	TFL
15	Traffic accident	Right tibia anterior	17 × 19 cm	LAT MCF
16	Traffic accident	Right tibia posterior	11 × 12 cm	ALT
17	Traffic accident	Left tibia medial	8 × 7 cm	ALT
18	Traffic accident	Left tibia anterior	10 × 12 cm	LAT MCF
19	Electrical burn	Right foot dorsum	8 × 10 cm	ALT
20	Electrical burn	Left foot dorsum	10 × 9 cm	Gracilis MF
21	Traffic accident	Right tibia medial	10 × 15 cm	ALT
22	Fire gun injury	Right tibia anterior	10 × 9 cm	ALT
23	Traffic accident	Left tibia anterior	10 × 15 cm	ALT
24	Traffic accident	Right tibia anterior	18 × 10 cm	ALT
25	Traffic accident	Left tibia anterior	25 × 12 cm	ALT
26	Traffic accident	Right heel	8 × 5 cm	LAT MCF
27	Traffic accident	Left tibia anterior	8 × 8 cm	ALT

Abbreviations: ALT, anterolateral thigh; DIEP, deep inferior epigastric perforator; LAT, latissimus dorsi; MCF, musculocutaneous flap; MF, muscle flap; TFL, tensor fascia lata; VL, vastus lateralis.

(ALT) flaps were covered by skin grafts, while the remaining donor sites were closed primarily. All patients were hospitalized during this period and received acetylsalicylic acid 100 mg/day. After 1 week, in-bed mobilization of the extremities was permitted. After 21 days, the vascular pedicle was divided. Physiotherapy was started on the second day postoperatively to prevent joint stiffness.

Results

Twenty-seven cross-leg free flap transfers were performed. The most frequently performed flap was the ALT flap, used in 14 cases. Six LD flaps, three gracilis muscle flaps, two vastus lateralis (VL) musculocutaneous flaps, one tensor fascia lata (TFL) flap, and one deep inferior epigastric perforator (DIEP) flap were also used. Two ALT flaps were lost due to thrombosis of the arterial pedicle 5 days after surgery. We changed the failed ALT flaps to LD flaps, and no further complications developed. Venous congestion occurred on the second postoperative day in one patient undergoing reconstruction with a free cross-leg VL musculocutaneous flap. Necrosis of the distal part of the flap developed and was subsequently healed by secondary intention. No local infection, hematoma, or seroma was observed in the recipient site. No complications occurred in the donor area, and no pathology associated with bone union was observed in the patients with bone fractures. Cosmetically satisfactory results with reconstructed areas and equal limb lengths were achieved in all patients.

Case Reports

Case 1

A 19-year-old patient was admitted for surgery by the orthopedics department for left lower limb fractures resulting from a motorcycle accident. The fracture in the left medial malleolus was repaired with K-wire, an internal fixator was applied to the left tibia fracture, and a semicircular laceration between the two malleoli was sutured. A necrotic area 8 cm × 9 cm in size developed postoperatively. Angiography was performed, but no appropriate recipient vessel was identified, and a cross-leg free flap was planned. The tibialis posterior artery and vein in the contralateral leg were prepared as recipient vessels. Anastomosis was performed after placing the gracilis flap on the defect site. The muscle flap was covered superiorly with a partial-thickness skin graft. Both lower extremities were fixated with plaster splints. The flap

was divided in the third postoperative week. Physiotherapy was initiated 3 months later, and the patient experienced no problems with walking after 6 months (►Figs. 1A–C).

Case 2

A 28-year-old male patient was successfully operated by the orthopedic team for Gustilo type 3B right tibia fracture following a traffic accident. At presentation, soon after the injury, a 10 cm × 6 cm open soft tissue defect was observed on the anterior aspect of the tibia (►Fig. 2A). The tibialis posterior artery was uninjured, and pulsation was present in the right leg. However, pulsation in the peroneal and tibialis anterior arteries was detected using angiography. There were no problems with circulation in the foot, such as pallor or coldness. The wound was debrided three times. The defect was reconstructed with an ALT cross-leg free flap 32 days after the initial injury. The tibialis anterior artery was dissected to the proximal, but no competent vessels were identified for anastomosis. The distal part of the contralateral tibialis posterior artery was therefore prepared for anastomosis with the vascular pedicle of the free flap. Simultaneously, another team harvested the ALT flap. The ALT pedicle was subsequently anastomosed with the contralateral tibialis posterior artery (TPA). Both legs were fixed with an external fixator, Schanz screws were used for immobilization, and the flap was placed on the defect (►Fig. 2B). No complications were encountered postoperatively, such as anastomosis problems, partial necrosis, tension on the pedicle, or osteomyelitis of the noninjured leg due to the tibial Schanz screw. The vascular pedicle was divided, and the Schanz screws were removed from the left tibia under sedation at the end of the third week of reconstruction. Surgery time was 20 minutes (►Fig. 2C). The patient was ambulant on the same day, and no problems were encountered with the flap circulation. The patient was discharged 2 days later (►Fig. 2D).

Case 3

A 7-year-old boy was referred to the emergency department following a traffic accident. The bilateral legs were amputated from the distal part of the femur, and the proximal part of the right femur was broken. The right femur was fixed with plates, and avulsed skin parts were excised due to insufficient skin circulation. Wound care was performed for 10 days. At the end of 10 days, the bilateral distal parts of the femur and plates were exposed (►Fig. 3A). The distal part of the left femoral vessels was prepared for anastomosis with the

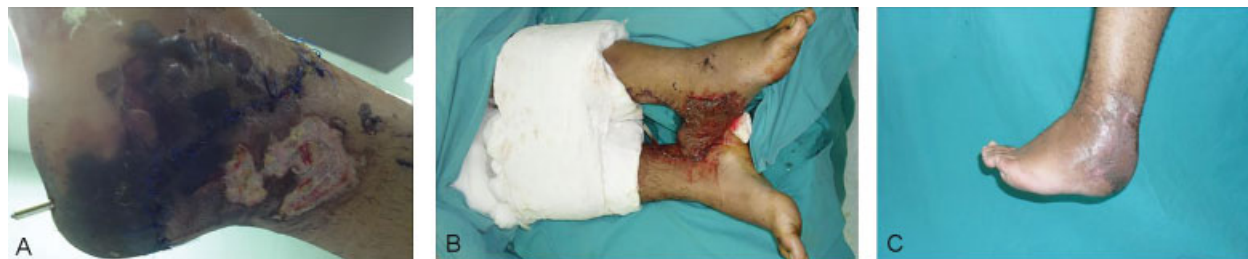

Fig. 1 (A) Preoperative appearance of a necrotic region in the left heel. (B) Early postoperative appearance of the gracilis muscle cross-leg free flap. (C) Postoperative sixth month appearance.

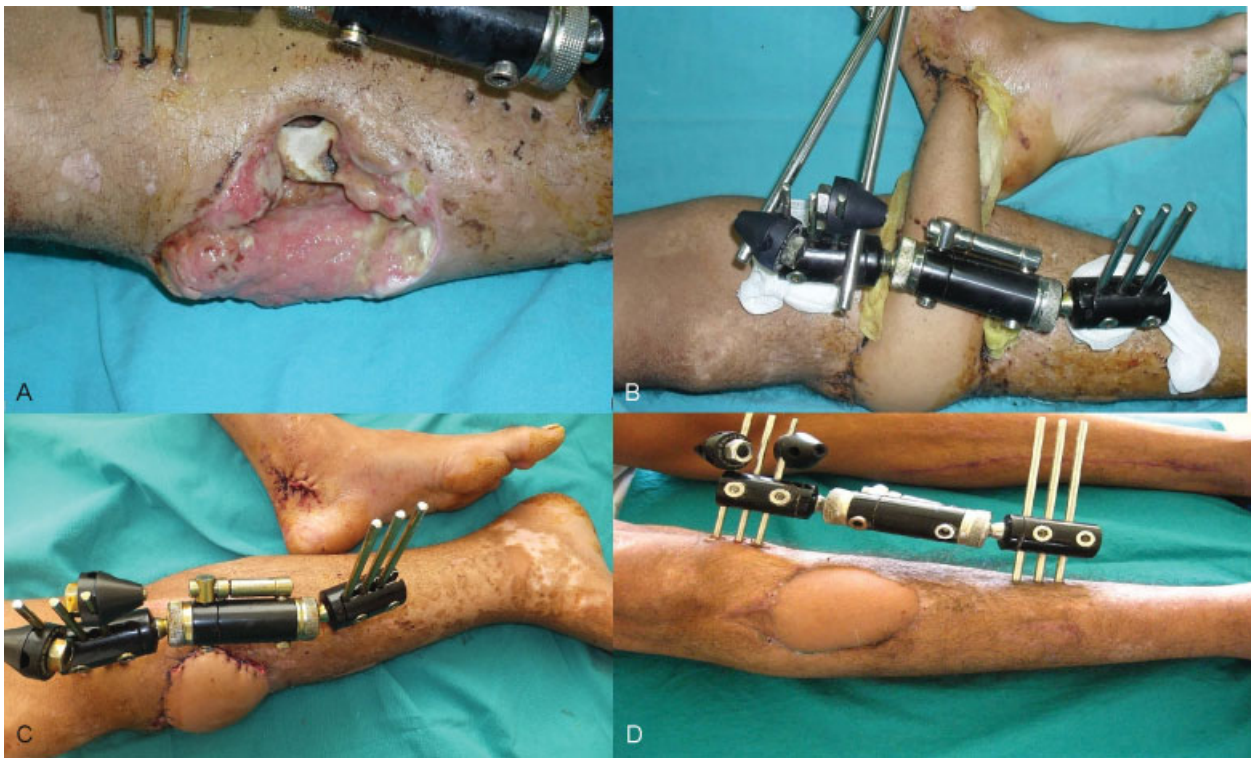


Fig. 2 (A) Preoperative appearance of the tibial bone and soft tissue defects. (B) Postoperative appearance of the ALT cross-leg free flap (10th day). (C) Appearance of the ALT flap and TPA anastomosis site on the second day after pedicle cutting. (D) Postoperative sixth month appearance.

pedicle of the free flap. Simultaneously, another team harvested the free LD flap (→Fig. 3B). The pedicle of the flap was subsequently anastomosed with the left femoral vessels (→Fig. 3C), and the two amputation stumps were fixed with K-wires for immobilization. The flap was placed on the bilateral soft tissue defect (→Fig. 3D). The remaining thigh defects were covered with a split-thickness skin graft. Both the flap and skin graft survived completely.

Three weeks later, the pedicle was divided, and the K-wires were removed. The patient, who was in Turkey as a tourist, subsequently returned to his home country following completion of acute treatment.

Discussion

The widespread use of free flaps has made it possible to repair complex soft tissue defects of the lower limb. A successful repair is achieved not only by appropriate convenient flap planning and with an experienced microsurgery team, but also by identifying a suitable donor vessel. Suitable donor vessels frequently cannot be found for soft tissue defects of the lower extremity where joints, tendons, nerves, or vessels are open or where fracture lines and bone defects accompany periosteal bone structures. The pedicled cross-leg fasciocutaneous flap, long vein graft assistance in addition to recipient vessel elongation, and cross-leg free flaps represent the repair options in these difficult defects.¹⁶ Pedicled cross-leg flaps are usually insufficient in closing large defects.⁶ Vein grafts are currently most commonly used to obtain healthy recipient vessels in the reconstruction of extremities. The most

frequently encountered problem in the use of long vein grafts is the creation of a kink and a high risk of thrombosis.^{7-10,17} Lin et al reported a case series of 65 traumatic limb injuries reconstructed with free tissue transfers using vein grafts of significant length (>20 cm for the arterial gap). They used vein grafts for arterial defects, and a temporary arteriovenous loop in the case of both artery and vein defect. They observed a higher re-exploration rate associated with greater graft length, although this did not achieve statistical significance.¹⁸

The vascular pedicle of the free flap can be temporarily anastomosed to the recipient vessels in the contralateral healthy leg and then divided after adequate neovascularization of the flap that constitutes the wound bed. In this way, it has been possible to use the “cross-leg free flap,” first described by Taylor et al in 1979, to repair skin and bone defects in the lower leg with a free osteocutaneous flap.¹¹ Various successful results have been published using the cross-leg method.¹⁹⁻³⁰ Yu et al published an 85-case series using the cross-bridge method and reported a success rate of 95.29%.²⁰ The advantages of reconstruction with cross-leg free flaps include the possibility of preparation with the required tissue components such as bone and muscle of the requisite sizes and allowing the anastomosis line to be completely outside the trauma zone.

The most important advantage of the cross-leg free flap is the possibility of saving the limb by transferring well-vascularized tissue to the leg in injuries with serious defects, even when amputation is considered. This method is especially suitable for patients with sensation in the soles of the feet and with a stable bone skeleton. Additionally, proximal and distal

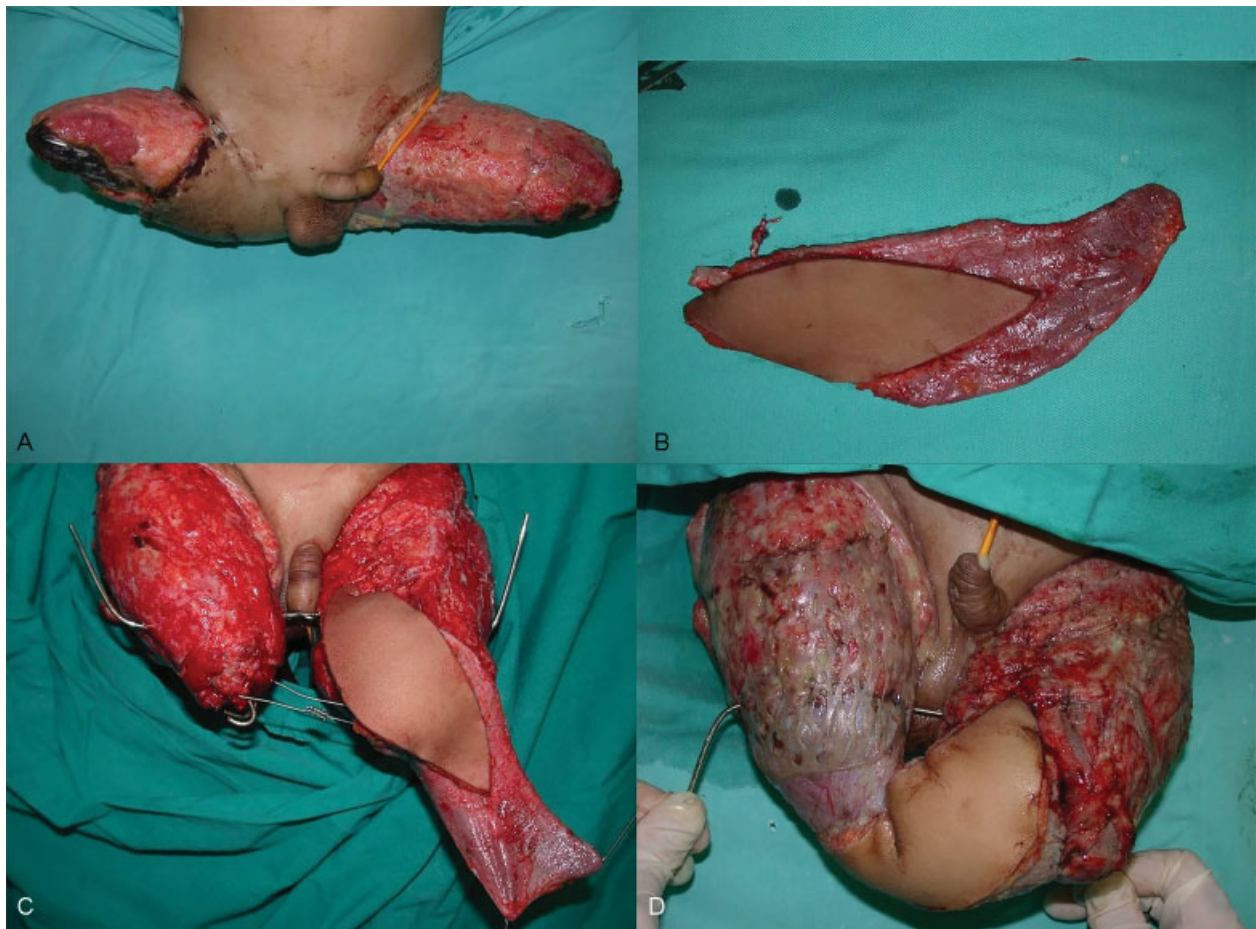

Fig. 3 (A) Preoperative appearance of the bilateral amputation stump. (B) Latissimus dorsi flap, intraoperative appearance. (C) Appearance of the latissimus dorsi flap after vascular anastomosis. (D) Immediate postoperative appearance.

neovascularization develops from these flaps in the long term, even if the dominant artery of the limb is not present.²⁷ As the cross-leg free flap is regarded as one of the last reconstruction options, everything possible for successful anastomosis should be performed in a seriously injured leg. However, end-to-side anastomosis may harm the vascularization of the damaged leg, and the posterior tibial vessels of the contralateral leg were prepared as recipient vessels for all our patients. We elected to use posterior tibial end-to-end anastomosis in our cases due to ease of positioning and anastomosis safety. Although using vessels from the healthy leg might be perceived as a disadvantage in the first stage, saving a lower extremity that could not be repaired by any other method of reconstruction represents the major advantage of the technique. Two pairs of major arteries and veins provide circulation in the leg, and when one of these is used, the other major artery and collaterals provide sufficient blood circulation to that limb.²⁰ The cross-leg free flap is therefore a safe option for both transported free tissue and the donor leg.

Separation time of the cross-leg free flap pedicle depends on the tissue included in the flap (muscle or fasciocutaneous), the size, and recipient bed vascularization.¹⁴ One experimental study with 25 dogs demonstrated that approximately a period of 3 weeks is sufficient to establish revascularization of

a random pedicled flap.¹⁹ We separated the flap pedicle 3 weeks after the first operation in all cases. During the first operation, clamps were placed on the pedicles to confirm flap circulation. No problem in flap circulation after clamp application was observed in any of the cases. Some authors advise a delay before flap separation; however, superficial necrotic areas have been reported in flaps subjected to delay.³¹ It should also not be forgotten that the muscle flap and fasciocutaneous flap have different circulation patterns.¹⁷ As skin flaps demonstrate better neovascularization due to the presence of the subdermal plexus, neovascularization is a gradual process in muscle flaps, for which reason preoperative clamping has an important role to play. Ischemic preconditioning is defined as a brief period of ischemia followed by tissue reperfusion, thereby increasing ischemic tolerance for a longer ischemic period. Some studies have reported that the ischemic preconditioning for the early division of a flap's vascular pedicle can be applied extensively with minimal discomfort.^{26,32} This is also an option for surgeons to consider. In theory, all types of free flaps can be applied in cross-leg free flaps. A suitable flap should therefore be selected for reconstruction based on the patient's condition.¹² We applied various different types of free flaps for reconstruction, such as the LD myocutaneous flap, ALT

flap, TFL flap, gracilis flap, DIEP flap and, VL myocutaneous flap as examples of cross-leg free flaps. Our series therefore supports this theory.

We generally prefer external fixators for leg stabilization. Placing a shunt through the healthy tibia and potential subsequent development of osteomyelitis might be considered a disadvantage of external fixators. However, osteomyelitis rarely develops, even in fractures stabilized by external fixators, if the surgical technique is performed correctly. Additionally, information about the process was provided and patient education was given at preoperative meetings with families. Patients were informed about not only possible postoperative pressure ulcer formation, but also how to perform regular daily nursing tasks. Another potential disadvantage was contracture in the healthy extremity due to immobilization. This was resolved by effective application of physiotherapy following flap separation. Although the cross-leg free flap is a well-known technique, it is usually not widely used in clinical practice. Our case series includes various types of flaps, such as fasciocutaneous flaps, muscle flaps, and perforator flaps. This report shows that cross-leg free flap method can be used safely when there are no suitable vessels for anastomosis in the same leg. It also shows that different kinds of flap can be employed in the cross-leg free technique.

Conclusion

We conclude that “the cross-leg free flap method” is a difficult but not unsafe technique for patient and surgeons. This report may encourage reconstructive surgeons to use the cross-leg free flap method when recipient vessel problems arise.

Conflict of Interest

None of the authors of this manuscript have any commercial association that might pose or create a conflict of interest with the information presented in the submitted manuscript. This includes: consultancies, stock ownership, or other equity interests, patent licensing arrangements, and payments for conducting or publicizing the study described in the manuscript.

Acknowledgment

The authors thank the Akdeniz University Scientific Research Project Unit for their support for this article.

References

- 1 Scott LL, Baumeister S. Lower extremity. In: Wei FC, Mardini S, eds. *Flaps and Reconstructive Surgery*. Philadelphia, PA: Saunders; 2009:62–70
- 2 Economides JM, Patel KM, Evans KK, Marshall E, Attinger CE. Systematic review of patient-centered outcomes following lower extremity flap reconstruction in comorbid patients. *J Reconstr Microsurg* 2013;29(5):307–316
- 3 Cho EH, Garcia RM, Blau J, et al. Microvascular anastomoses using end-to-end versus end-to-side technique in lower extremity free tissue transfer. *J Reconstr Microsurg* 2016;32(2):114–120
- 4 Kolbenschlag J, Hellmich S, Germann G, Megerle K. Free tissue transfer in patients with severe peripheral arterial disease: functional outcome in reconstruction of chronic lower extremity defects. *J Reconstr Microsurg* 2013;29(9):607–614
- 5 Fischer JP, Wink JD, Nelson JA, et al. A retrospective review of outcomes and flap selection in free tissue transfers for complex lower extremity reconstruction. *J Reconstr Microsurg* 2013;29(6):407–416
- 6 Chen H, El-Gammal TA, Wei F, Chen H, Noordhoff MS, Tang Y. Cross-leg free flaps for difficult cases of leg defects: indications, pitfalls, and long-term results. *J Trauma* 1997;43(3):486–491
- 7 Bayramiçlı M, Tetik C, Sönmez A, Gürünlüzöğlü R, Baltacı F. Reliability of primary vein grafts in lower extremity free tissue transfers. *Ann Plast Surg* 2002;48(1):21–29
- 8 Whitney TM, Buncke HJ, Lineaweaver WC, Alpert BS. Multiple microvascular transplants: a preliminary report of simultaneous versus sequential reconstruction. *Ann Plast Surg* 1989;22(5):391–404
- 9 Luo SK, Gao JH, Luo JH. A case report of cross-leg free latissimus dorsi myocutaneous flap transplantation. *Eur J Plast Surg* 1999;22:329–330
- 10 Khouri RK, Shaw WW. Reconstruction of the lower extremity with microvascular free flaps: a 10-year experience with 304 consecutive cases. *J Trauma* 1989;29(8):1086–1094
- 11 Taylor GI, Townsend P, Corlett R. Superiority of the deep circumflex iliac vessels as the supply for free groin flaps. *Clinical work. Plast Reconstr Surg* 1979;64(6):745–759
- 12 Yu L, Tan J, Cai L, et al. Repair of severe composite tissue defects in the lower leg using two different cross-leg free composite tissue flaps. *Ann Plast Surg* 2012;68(1):83–87
- 13 Yu ZJ, Tang CH, He HG. Cross-bridge transplantation of free latissimus dorsi skin flap in one case. *Chin Med J (Engl)* 1983;96(10):772–776
- 14 Townsend PLG. Indications and long-term assessment of 10 cases of cross-leg free DCIA flaps. *Ann Plast Surg* 1987;19(3):225–233
- 15 Yu ZJ, Tang CH, Ho HG. Cross-bridge free skin flap transfer: case report. *J Reconstr Microsurg* 1985;1(4):309–311
- 16 Akyürek M, Safak T, Ozkan O, Keçik A. Technique to re-establish continuity of the recipient artery after end-to-end anastomoses in cross-leg free flap procedure. *Ann Plast Surg* 2002;49(4):430–433
- 17 Brenman SA, Barber WB, Pederson WC, Barwick WJ. Pedicled free flaps: indications in complex reconstruction. *Ann Plast Surg* 1990;24(5):420–426
- 18 Lin CH, Mardini S, Lin YT, Yeh JT, Wei FC, Chen HC. Sixty-five clinical cases of free tissue transfer using long arteriovenous fistulas or vein grafts. *J Trauma* 2004;56(5):1107–1117
- 19 Yu ZJ, Huang MJ, Zheng L. Influence of pedicle severance at different time on the survival of canine skin flap. *Chin Med J (Engl)* 1984;64:449
- 20 Yu ZJ, Zeng BF, Huang YC, et al. Application of the cross-bridge microvascular anastomosis when no recipient vessels are available for anastomosis: 85 cases. *Plast Reconstr Surg* 2004;114(5):1099–1107
- 21 Kobus K. Free transplantation of tissues: problems and complications. *Ann Plast Surg* 1988;20(1):55–74
- 22 Hao YB. Free flap transfer by bridge vascular anastomosis. *Chin J Plast Burn Surg* 1981;7:271
- 23 Liu ZX. Repair of tissue defects with free latissimus dorsi myocutaneous flap transfer by bridge vascular anastomosis: Report of three cases. *Chin J Microsurg* 1990;13:38
- 24 Lai CS, Lin SD, Chou CK, Cheng YM. Use of a cross-leg free muscle flap to reconstruct an extensive burn wound involving a lower extremity. *Burns* 1991;17(6):510–513

- 25 Sharma RK, Kola G. Cross leg posterior tibial artery fasciocutaneous island flap for reconstruction of lower leg defects. *Br J Plast Surg* 1992;45(1):62–65
- 26 Cinpolat A, Bektas G, Coskunfirat N, Rizvanovic Z, Coskunfirat OK. Comparing various surgical delay methods with ischemic preconditioning in the rat TRAM flap model. *J Reconstr Microsurg* 2014;30(5):335–342
- 27 Pei GX, Xie CP, Li QD. Musculocutaneous flap transfer bridged by the posterior tibial vessels from the healthy limb in the reconstruction of severe lower limb trauma. *Chin J Traumatol* 1992;8:266
- 28 Topalan M. A new and safer anastomosis technique in cross-leg free flap procedure using the dorsalis pedis arterial system. *Plast Reconstr Surg* 2000;105(2):710–713
- 29 Yamamoto M, Kaji S, Mrakami Y, Yamanobe Y, Nakamura M. The use of a crossleg free flap for the repair of an extensive injury of the lower extremities. *Jpn J Plast Reconstr Surg* 1992;35:539
- 30 Ding SY. Treatment of chronic osteomyelitis of leg with free latissimus dorsi musculocutaneous flap anastomosed to contralateral leg vessels [in Chinese]. *Zhonghua Zheng Xing Shao Shang Wai Ke Za Zhi* 1993;9(2):106–107, 159
- 31 Yamada A, Harii K, Ueda K, Asato H, Tanaka H. Versatility of a cross-leg free rectus abdominis flap for leg reconstruction under difficult and unfavorable conditions. *Plast Reconstr Surg* 1995;95(7):1253–1257
- 32 Cheng MH, Chen HC, Wei FC, Su SW, Lian SH, Brey E. Devices for ischemic preconditioning of the pedicled groin flap. *J Trauma* 2000;48(3):552–557